*Jap. J. vet. Res.*, **18**, 43-46 (1970)

# EOSINOPHILS OF CANINE PERIPHERAL BLOOD IN ELECTRON MICROSCOPY

Mitsuo SONODA and Kōsaku KOBAYASHI
*Department of Veterinary Internal Medicine*
*Faculty of Veterinary Medicine*
*Hokkaido University, Sapporo, Japan*

(Received for publications, December 23, 1969)

The eosinophils of the canine peripheral blood were studied with the use of an electron microscope. The results thus obtained are summarized as follows.

1 The maculous appearances of the nuclear lobes are evident as those of the canine neutrophils.
2 The basic type of the canine eosinophilic granules is the round dense osmiophilic one without any structures, however, there are a lot of variable ones in the structure.
3 At the margins of the granules or inside them, there are seen new moon-like or quite round defects in some granules.

## INTRODUCTION

It has been well known that the fine structures of the eosionophils, especially the internal structures of their specific granules are very variable in accordance with the difference of the animal species[16,17,27].

Up to the present time, there is only an observation on the canine eosinophils in electron microscopy by SCHIVELY et al. However, their description is not so detailed.

In this report, the fine structures of the eosinophils in the peripheral blood obtained from clinically healthy dogs will be described in more detail.

## MATERIALS AND METHODS

The materials and methods of the observations used in this experiments were just the same as those reported elsewhere[22].

## RESULTS OF THE OBSERVATIONS

In the visual fields, the very large, highly osmiophilic granules of the eosinophils make it easy to identify them from any other leucocytes.

### I Nucleus

The nuclei of the eosinophils appear as one to several nuclear lobes in the cytoplasms on the visual fields of the cut planes. The form and size of the nuclear lobes are variable

in accordance with the cut directions. They are oval, round, short club-like or irregular in form. The numbers of the nuclear lobes in each of the cells are two or three most frequently. In the nuclear lobes, there are observed two parts of high dense and less dense. The high dense ones are distributed along the perinuclear membrane and penetrate into the central areas at some parts of them and have a moderately clear maculous appearance.

## II Cytoplasm

The margins of the cytoplasm have somewhat irregular saw-toothed appearance caused by many small pseudopodic projections.

The backgrounds of the cytoplasm are filled with a number of fine dust-like particles and they look gray in the micrographs. Additionally, there are a lot of ribosomes distributed sparsely in the cytoplasm. In the central areas of the cytoplasm, there are badly or moderately developed Golgi complexes consisting of small vesicles and lamellar structures.

A lot of small vesicles with or without contents are distributed in the whole cytoplasm. There are also seen several small or large vacuoles near the areas of the cell membrane in the cytoplasm.

Sometimes, a small number of endoplasmic reticulum with granules are observed in the cytoplasm. The specific granules of the eosinophils are easily discriminated by their extremely high electron densities. They number several to twenty or so in each of the cytoplasm on the cut planes.

The forms of the granules on the cut planes are fundamentally quite round, however, some of them are oval, short rod-like or gourd-shaped. Very rarely, they are distributed in the cytoplasm as like wastes of the irregularly cut belts in form.

In some of the granules, the sharply round defects are observed. When the defects are at the edges of the granules, they look like new moons and when they are located in the granules perfectly separated from the margins of the granules, they look like doughnuts with empty round holes. The contents of the defected parts are the same as those of the cytoplasm or perfectly empty. In the measurements of 100 round granules, they range between 0.12–1.33 $\mu$ in size and their average is 0.69 $\mu$ in diameter.

The granules are lineated with clear unit membranes. The internal structures of the granules are variable considerably by each of the granules even on the same cells. The homogeneously compact dense ones without special structures are observed most often in the cytoplasm. In some of the granules, there is a narrow less osmiophilic peripheral zone in the granule. Furthermore, in the granules, they have also a core with higher density and they look like a wheel with triple concentric zones. In some granules, there are lighter, fibrous or perfectly empty holes in parts of the centers of the dense cores. A small number of the granules look like a ball of knitting wool in general appearance. The variable densities inside the granules depend on the conditions of the amount and minuteness of these particles, viz., the parts where the fine granular materials are present compactly, they look darker, and where they are present in smaller numbers and with less minuteness, they look lighter in the micrographs.

Anywhere in the cytoplasms, a few round or elongated or oval mitochondria with characteristic cristae may always be seen. The size of the round ones range between 0.23

and 0.40 $\mu$, and 0.31 $\mu$ on the average.

A considerable or a small number of flattened rough surfaced endoplasmic reticulum are seen in the parts near the nuclei and among the specific granules.

## CONSIDERATIONS

It has been clarified that there are many interesting internal structures in the granules of eosinophils of the human and other animals.

The internal structures of the granules are different depending on the different species of the animals. However, on the basis of the fine structures of the granules, they may be classified into four basic types. Namely, the granules having so-called middle plates as for example in the human[6,14,16,17,25,27], rabbits [17,27,28], guinea pigs[11,12,17,26,27] and mice[19], the ones having so-called middle trunk with circular lamellar structures as in cats[3,4,5,17,27], the ones with two or three concentric layers as in minks[15,23] and cattle[13,24] and the ones with no special structures as in horses[7,8,17,21] and swine[18].

On the canine eosinophils, SHIVELY et al. reported that there were osmiophilic dense granules with or without less dense peripheral zones and a few moderately osmiophilic granules with or without dense osmiophilic peripheral ring. In our observations, of course, the granules like those reported by SHIVELY et al. occur. However, as described by the authors already, other granules with variable internal structures are observed, too. Although there are granules with several variable internal structures in our observations, on the basis of the appearance rates of each type of granule, their basic structures may be said to be of the round dense osmiophilic type with no special structures.

Recently, the specific granules of the neutrophils and eosinophils have been recognized as one of the lysosomes, and the granules may be solved at the time of phagocytosis[1,2,10,29]. At the present time, it is, of course, very difficult to suppose the functions of the granules from the morphology obtained by the authors.

Allowing the imaginations, it may be said that the specific granules of the eosinophils repeat the fullness and output of the internal materials, the defective parts like the round and new moon are the exits outputting the internal materials, and the granules having structures like the ball of knitting wool and fibrous structures are the remnants after the perfect output of the internal materials. Or, other theories will be made for example that these variable structures of the granules are the figures showing the degenerating process or maturating process of each of the granules in the cytoplasm. On the correlations between morphology and the functions of the granules, further studies will be needed in the near future.

## REFERENCES


1) ARCHER, G. T. & HIRSCH, J. G. (1963): *J. exp. Med.*, **118**, 277
2) ARCHER, G. T. & HIRSCH, J. G. (1963): *Ibid.*, **118**, 287
3) BARGMANN, W. & KNOOP, A. (1956): *Zellforsch. mikrosk. Anat.*, **44**, 282
4) BARGMANN, W. & KNOOP, A. (1956): *Ibid.*, **44**, 692
5) BARGMANN, W. & KNOOP. A. (1958): *Ibid.*, **46**, 130
6) BESSIS, M. & THIERY, J. (1961): *Int. Rev. Cytol.*, **12**, 199
7) BOCCIARELLI, D., TENTORI, L. & VIVALDI, G. (1959): *Rc. Ist sup. Sanità*, **22**, 1059
8) BRAUNSTEINER, H. & PAKESCH, F. (1962): *Acta haemat.*, **28**, 163
9) FEY, F. (1966): *Folia haemat.*, **86**, 1
10) HIRSCH, J. G. (1962): *J. exp. Med.*, **116**, 827
11) HUDSON, G. (1966): *Expl. Cell Res.*, **41**, 265
12) HUDSON, G. (1967): *Ibid.*, **46**, 121
13) KNOCKE, K.-W. (1963): *Folia haemat.*, N. F. **7**, 130
14) LOW. F. N. & FREEMAN, J. A. (1958): Electron microscopic atlas of normal and leukemic human blood, 1 ed., New York, Toronto, London: McGraw-Hill Book Company, Inc.
15) LUTZNER, M. A., TIERNEY, J. H. & BENDITT, E. P. (1965): *Lab. Invest.*, **14**, 2063
16) MILLER, F., DEHARVEN, E. & PALLADE, G. E. (1966): *J. Cell Biol.*, **31**, 349
17) OSAKO, R. (1959): *Folia haemat. jap.*, **22**, 134 (in Japanese with English summary)
18) SCHULZE, P. (1967): *Arch. exp. VetMed.*, **21**, 1305
19) SHELDON, H. & ZETTERQUIST, H. (1955): *Bull Johns Hopkins Hosp.*, **96**, 135
20) SHIVELY, N., FELDT, C. & DAVIS, D. (1969): *Am. J. vet. Res.*, **30**, 893
21) SONODA, M. (1963): Proceeding of the 55th Meeting of the Japanese Society of Veterinary Science, *Jap. J. vet. Sci.*, **25**, 394 (Summary in Japanese)
22) SONODA, M. & KOBAYASHI, K. (1970): *Jap. J. vet. Res*, **18**, 37
23) SONODA, M., MATSUMOTO, H. & KOBAYASHI, K. (1969): Proceeding of the 67th Meeting of the Japanese Society of Veterinary Science, *Jap. J. vet. Sci.*, **31**, 119 (Summary in Japanese)
24) SONODA, M., MIFUNE, Y. & OHYA, M. (1964): Proceeding of the 57th Meeting of the Japanese Society of Veterinary Science, *Ibid* **26**, 440 (Summary in Japanese)
25) WATANABE, I., DONAHUE, S. & HOGGATT, N. (1967): *J. Ultrastruct. Res.*, **20**, 366
26) WATANABE, Y. (1954): *J. Electron Microsc.*, Chiba Cy, **2**, 34
27) WATANABE, Y. (1956): *Acta haemat. jap.*, **19**, 327 (in Japanese with English summary)
28) WETZEL, B. K., HORN, R. G. & SPICER, S. S. (1967): *Lab. Invest.*, **16**, 349
29) ZUCKER-FRANKLIN, D. & HIRSCH, J. G. (1964): *J. exp. Med.*, **120**, 569

## Explanations of plates

### Plates I and II

Fig. 1~12 × 10,000

General figures of the eosinophils are shown in these figures. The maculous appearances on the nuclear lobes are evident. The specific granules with high electron density are variable in form, size and internal structures. In the central areas of almost all of the cells, badly or moderately developed Golgi complexes are seen. Several numbers of mitochondria are present in the cytoplasm in all the cells.

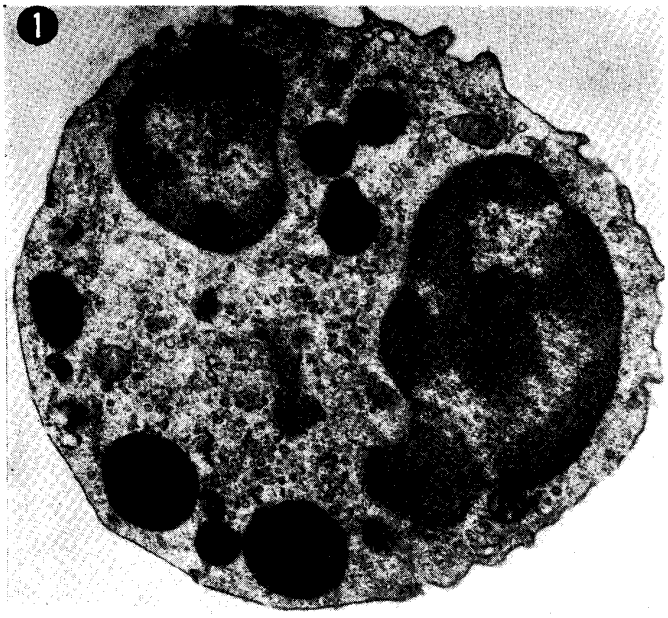
1

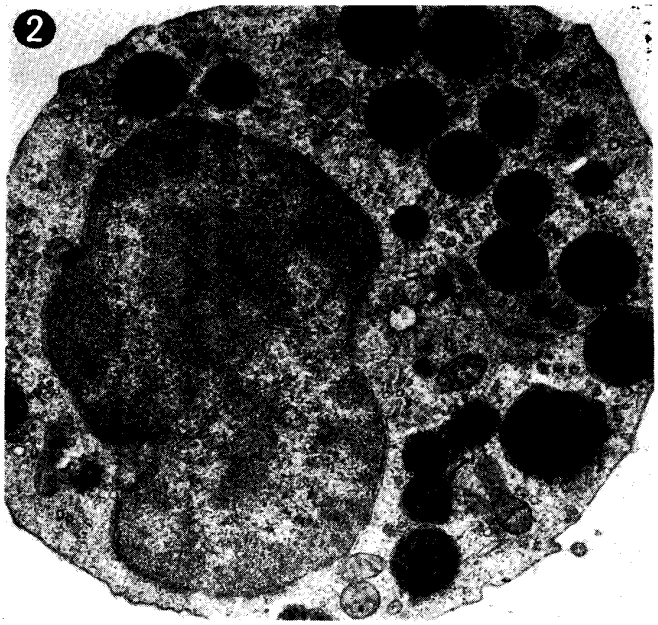
2

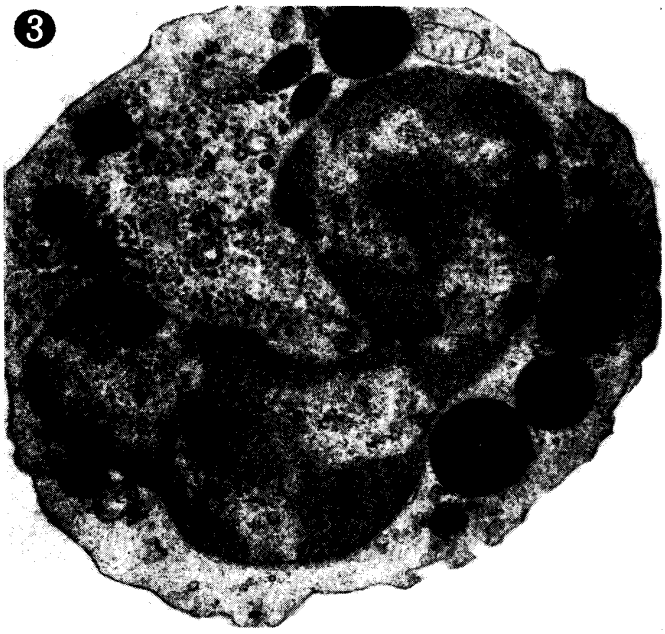
3

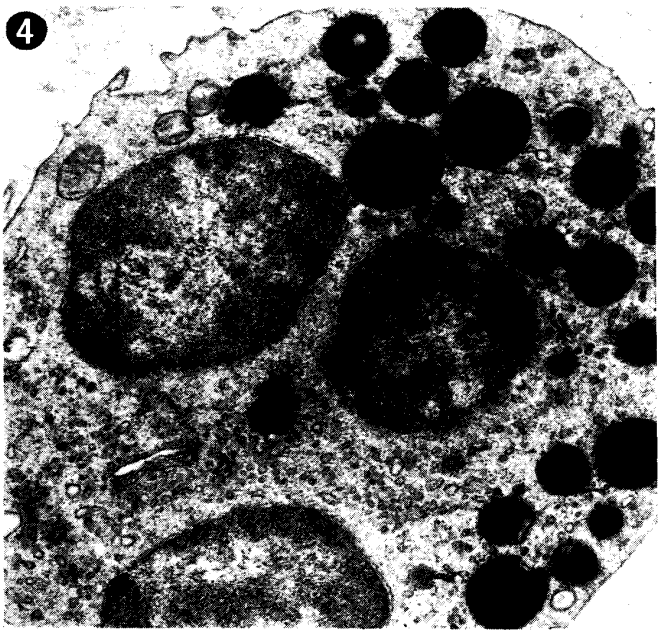
4

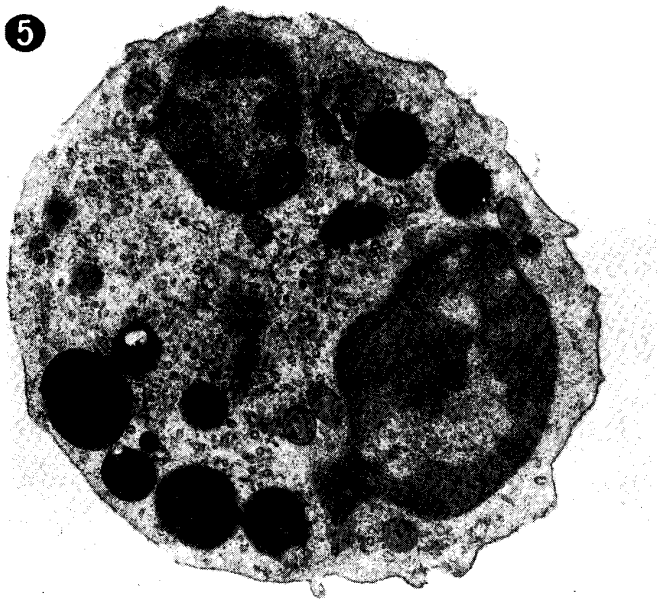
5

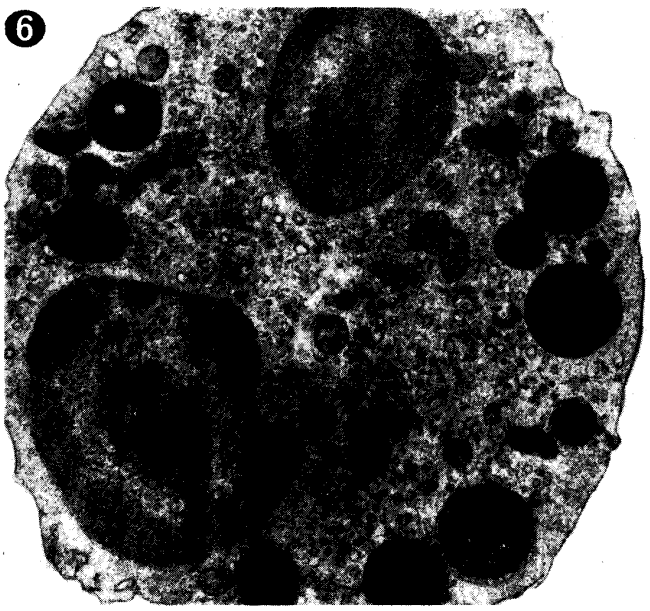
6

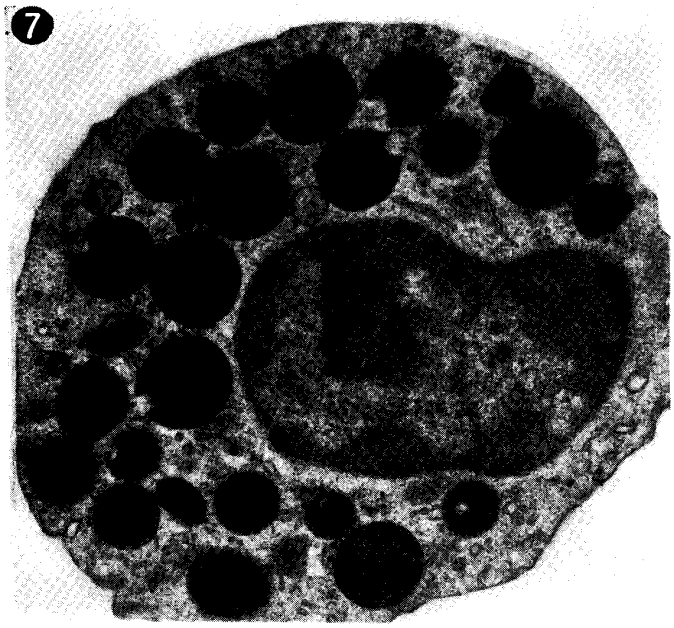
7

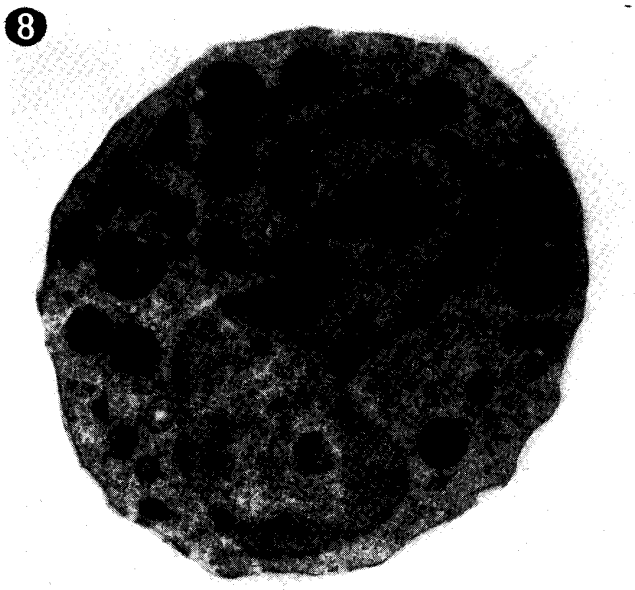
8

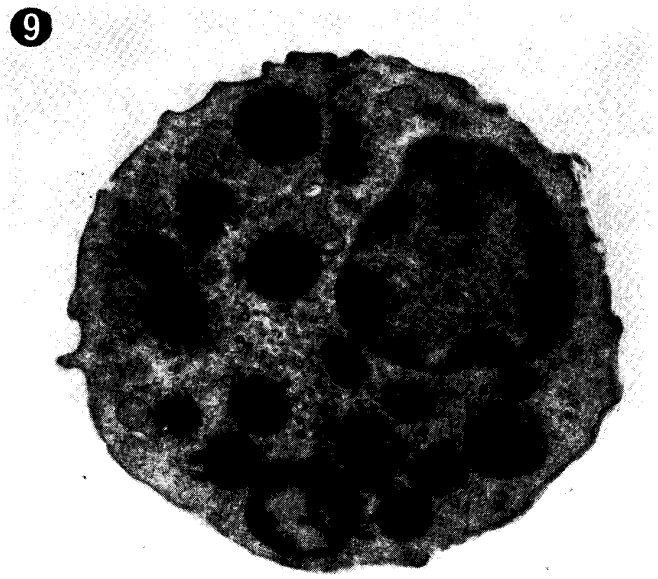
9

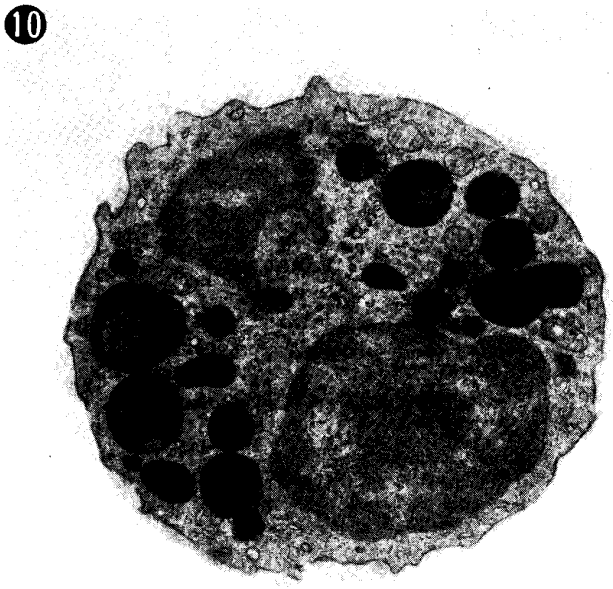
10

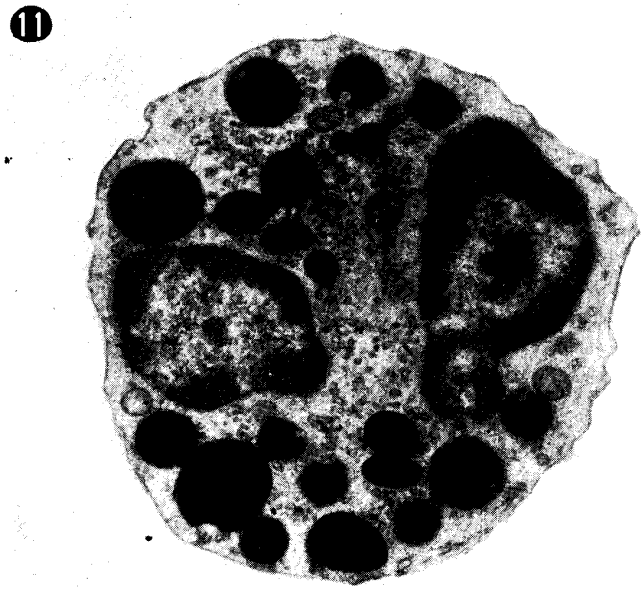
11

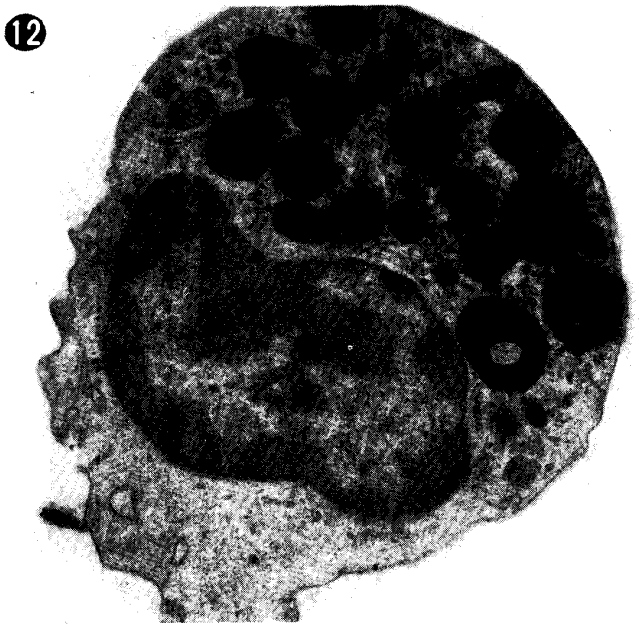
12

## PLATE III

Fig. 13 × 30,000

An enlarged general figure of an eosinophil is shown. There are many specific granules with high osmiophilic density of various size in the cytoplasm. Some of them have less dense peripheral rings. In the central area, a Golgi complex consisting of many vesicles is present (G). A small number of mitochondria with clear cristae and rough surfaced endoplasmic reticulum are seen in the cytoplasm.

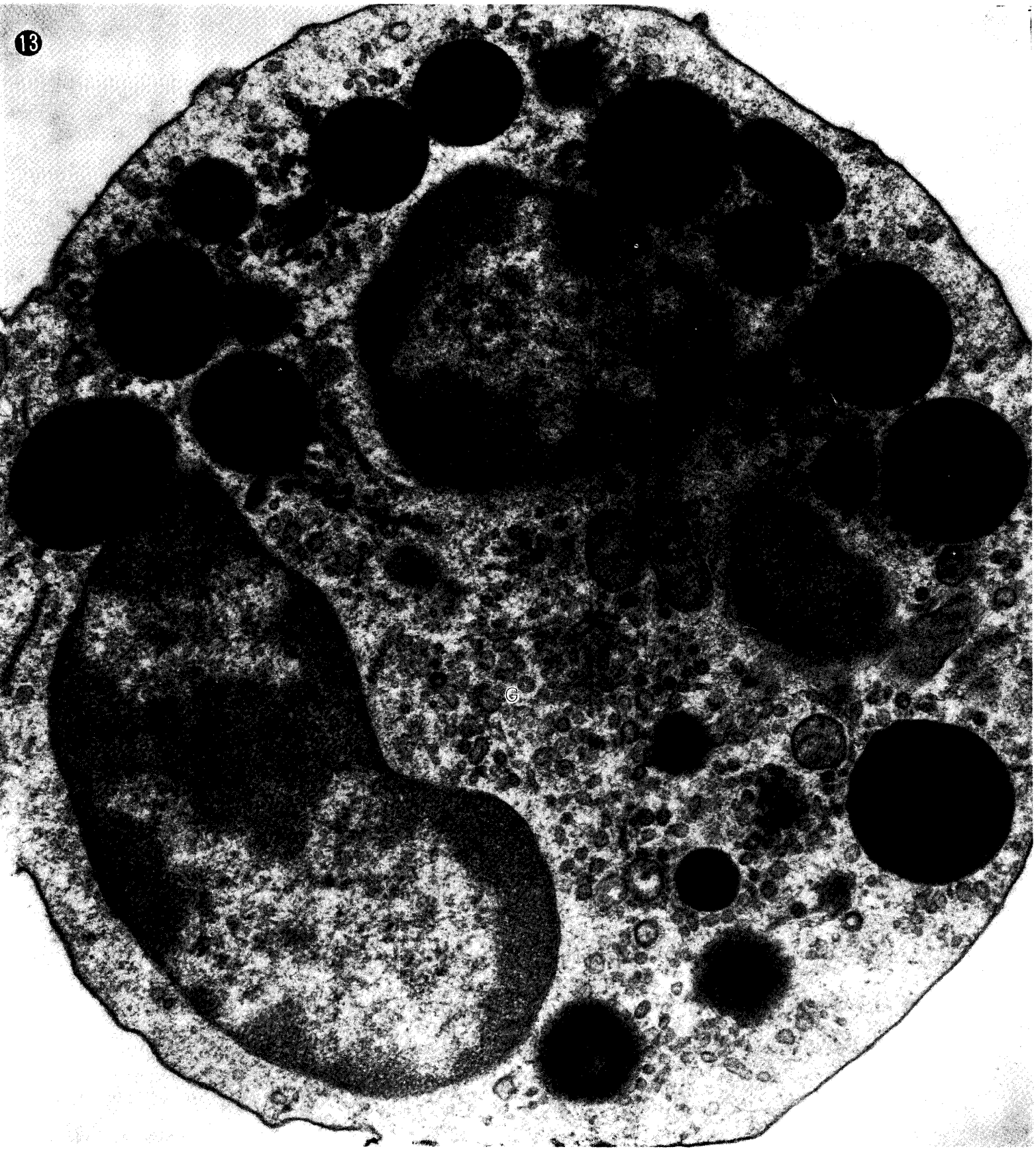
13
G

PLATE IV

Fig. 14~17 × 30,000

Several types of granules are shown in these figures. Quite round defects are at the margins of some granules.

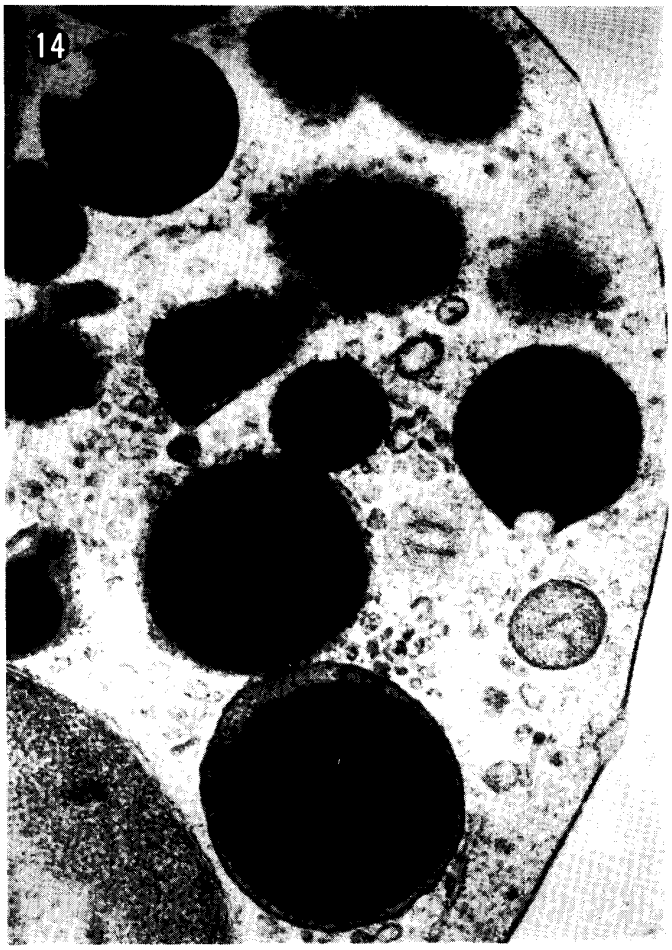
14

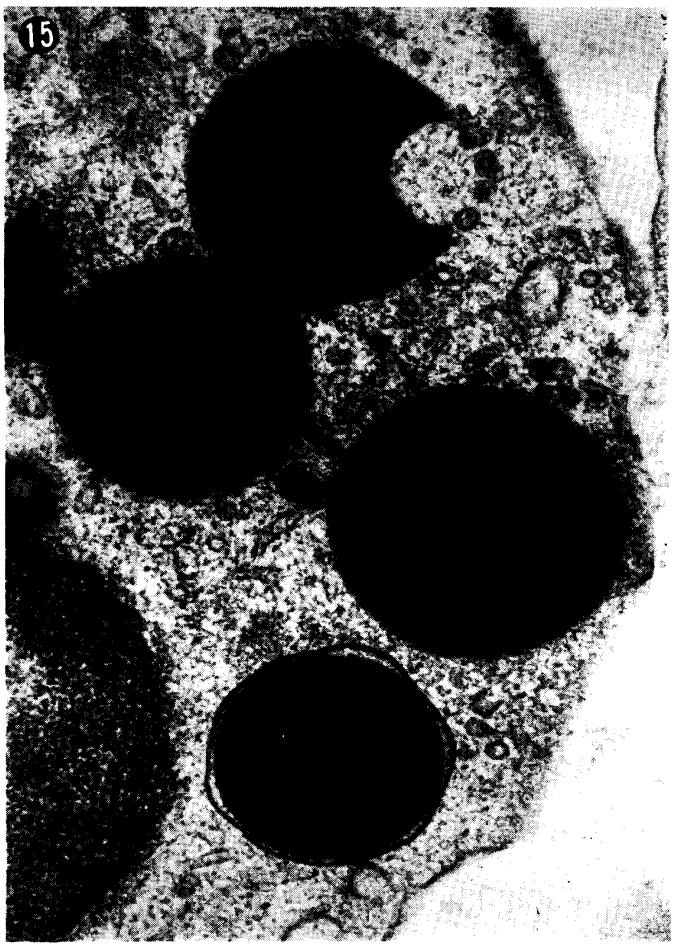
15

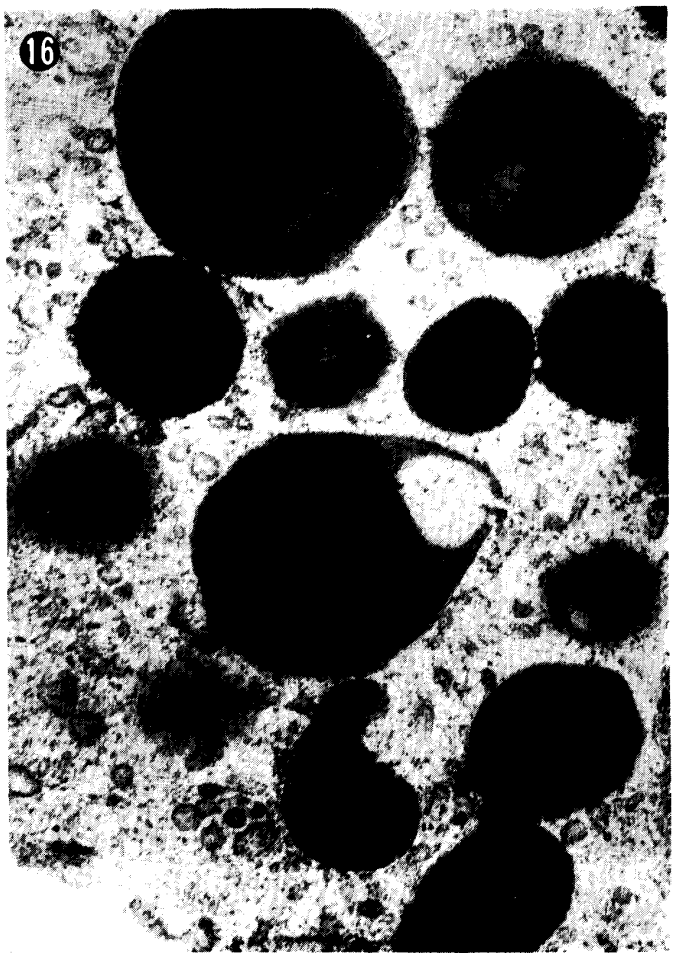
16

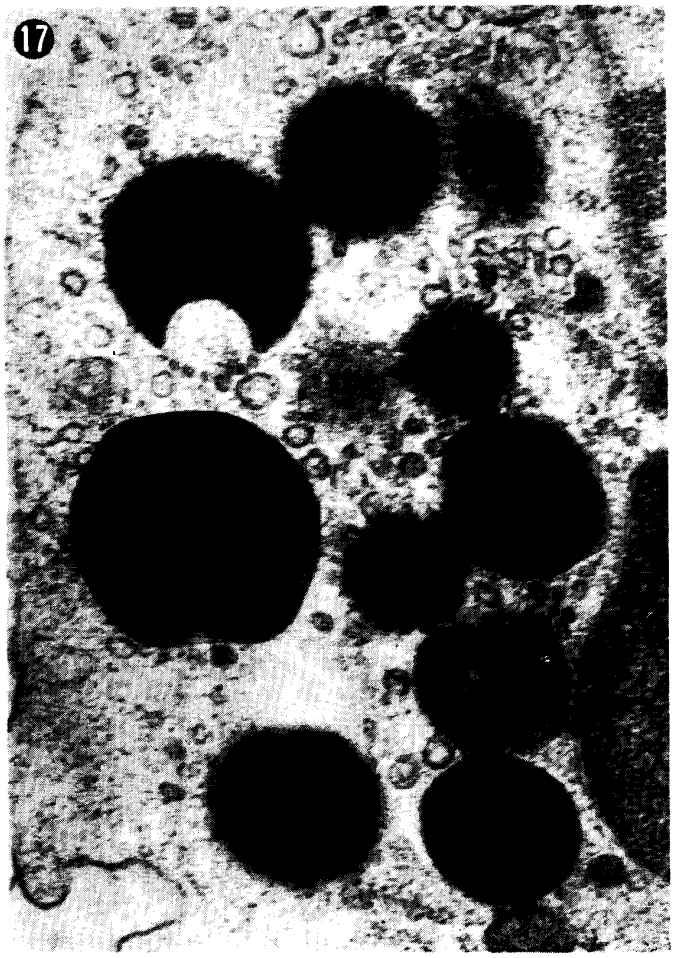
17

PLATE V

Fig. 18~21 × 30,000

Several types of the granules are shown in these figures. There are round defects inside of some of the granules. A granule with clear triple layers is seen in fig. 21.


18

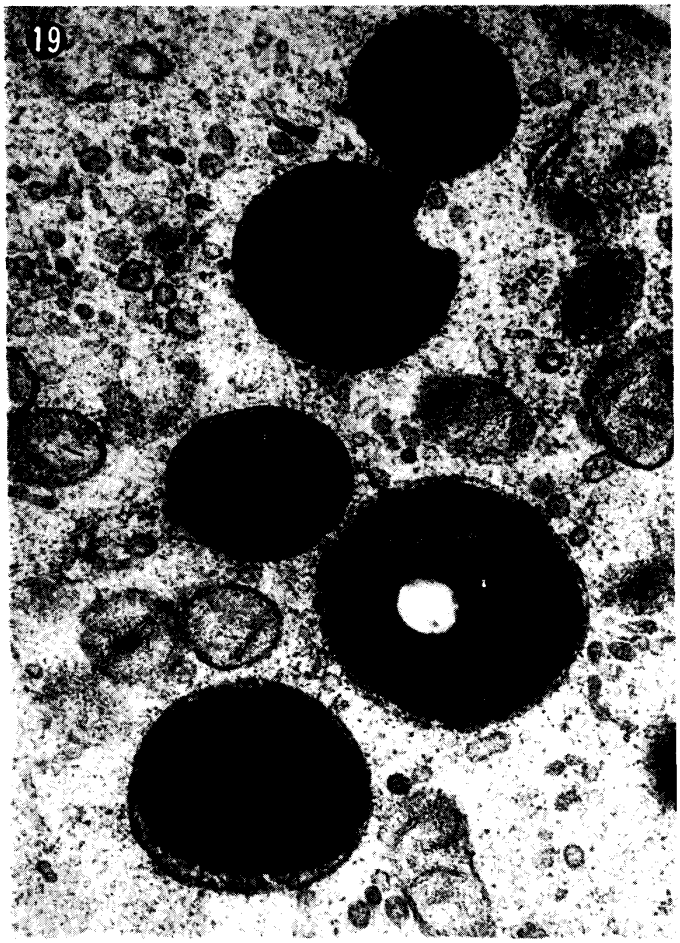
19


20

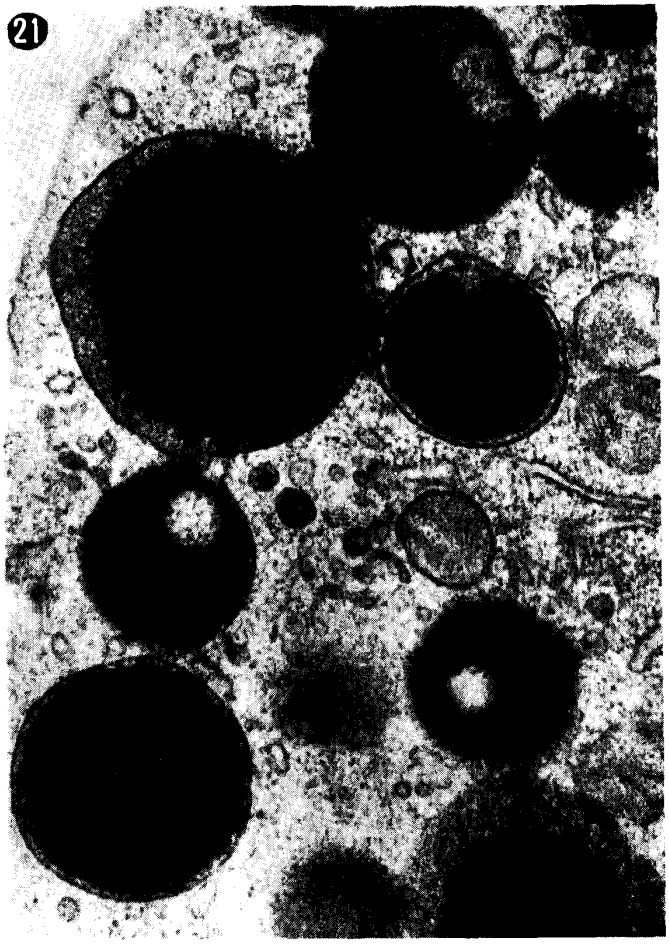
21

PLATE VI

Fig. 22~25 × 30,000

Several types of the granules are shown in these figures. The granules with a fibrous structure and the granules like a ball of knitting wool in general appearance are seen in fig. 24 and 25, respectively.


22


23


24

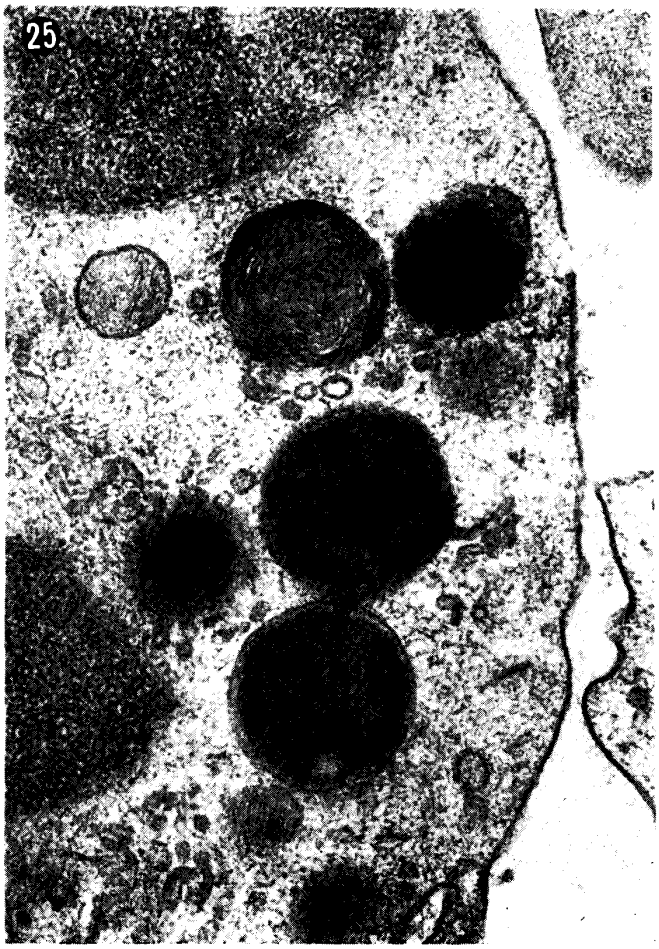
25

## Plate VII

Fig. 26 & 27 × 30,000

Very irregular granules just look like wastes of the belts cut irregularly are seen in the cytoplasm.

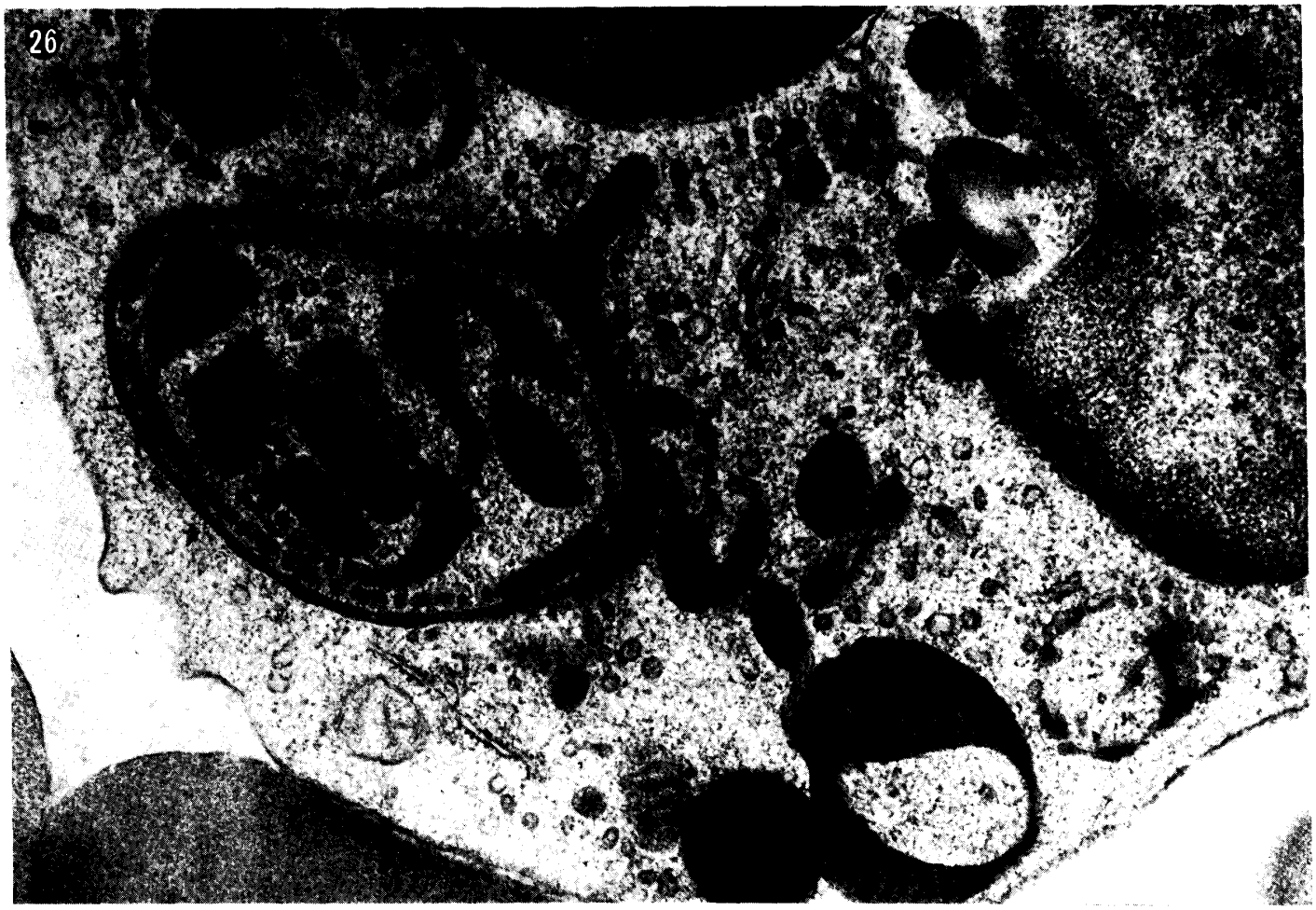
26


27

PLATE VIII

Fig. 28 × 140,000

A round defect with clear unit membrane is near the peripheral area of the granule. The materials inside the round defect are just the same as those of the cytoplasm.

Fig. 29 × 70,000

The granules are lineated with clear unit membranes. One of them consists of three layered structures. Another one has a clear defect near the margins of the granule.

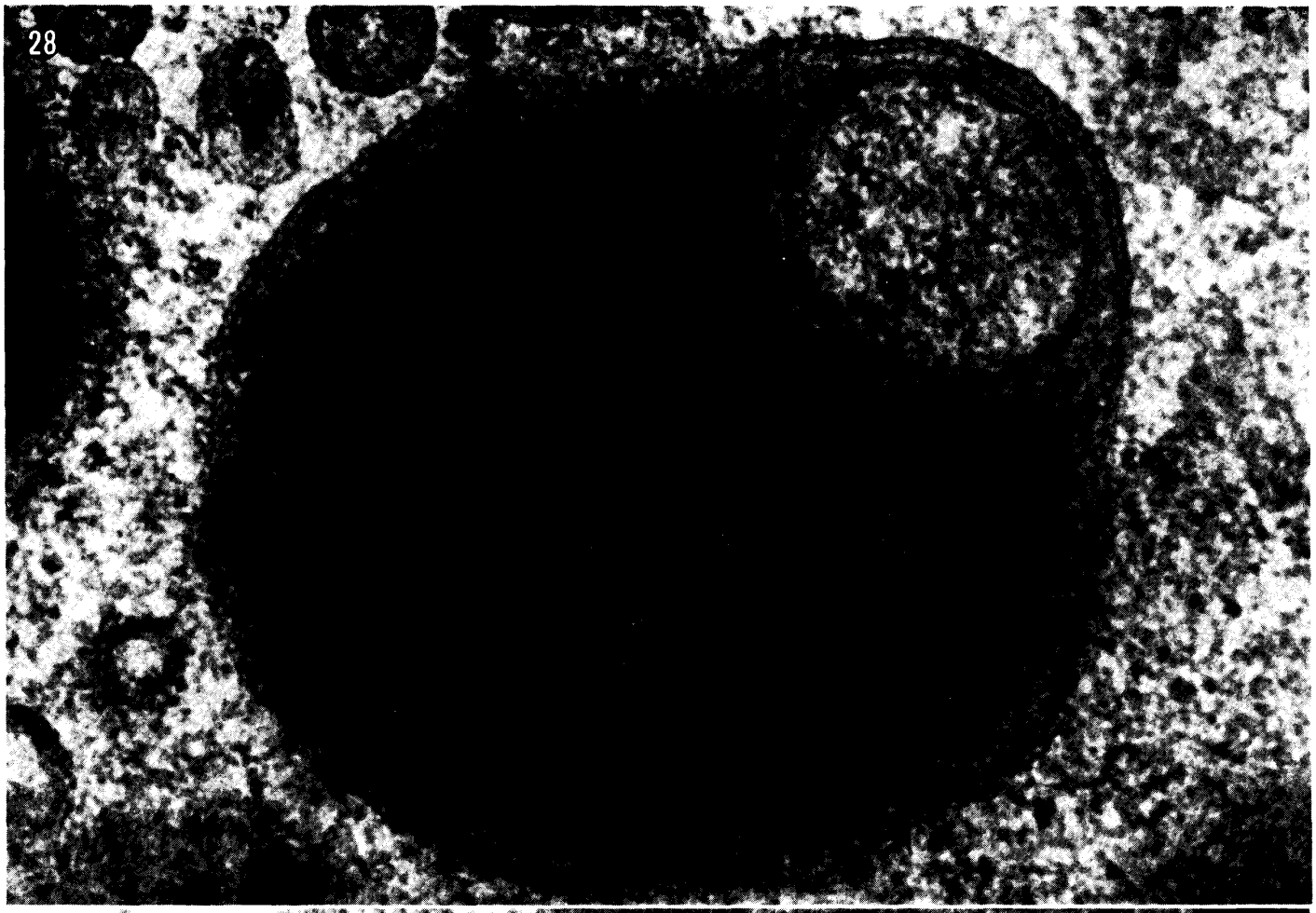
28

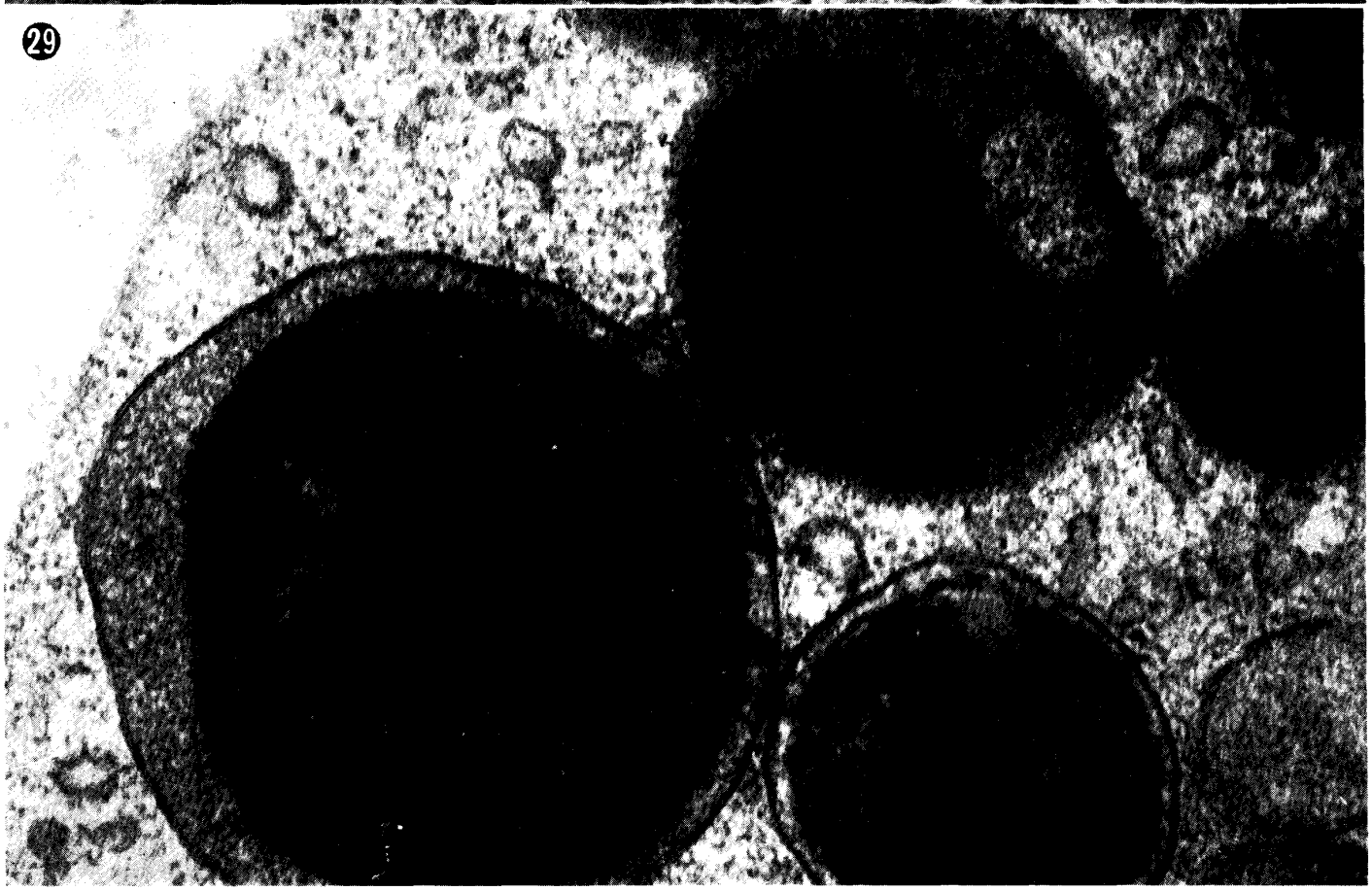
29