



Title	Keratin 1 Gene Mutation Detected in Epidermal Nevus with Epidermolytic Hyperkeratosis
Author(s)	Tsubota, Akiko; Akiyama, Masashi; Sakai, Kaori; Goto, Maki; Nomura, Yukiko; Ando, Satomi; Abe, Masataka; Sawamura, Daisuke; Shimizu, Hiroshi
Citation	Journal of Investigative Dermatology, 127(6), 1371-1374 https://doi.org/10.1038/sj.jid.5700712
Issue Date	2007-06
Doc URL	http://hdl.handle.net/2115/30282
Rights	Nature Publishing Group, JOURNAL OF INVESTIGATIVE DERMATOLOGY, 127(6), 2007, pp.1371-1374.
Type	article (author version)
File Information	JID127-6.pdf



[Instructions for use](#)

Mutation Report

**Keratin 1 Gene Mutation Detected in Epidermal Nevus with
Epidermolytic Hyperkeratosis**

Akiko Tsubota, Masashi Akiyama^{*}, Kaori Sakai, Maki Goto, Yukiko
Nomura, Satomi Ando, Masataka Abe, Daisuke Sawamura, Hiroshi
Shimizu^{*}

Department of Dermatology, Hokkaido University Graduate School of
Medicine, Sapporo, Japan.

***Co-corresponding authors:**

Masashi Akiyama and Hiroshi Shimizu

Department of Dermatology

Hokkaido University Graduate School of Medicine

North 15 West 7, Kita-ku, Sapporo 060-8638, Japan

Telephone: +81-11-716-1161, ext. 5962

Fax: +81-11-706-7820

e-mail akiyama@med.hokudai.ac.jp

shimizu@med.hokudai.ac.jp

Short title: Keratin 1 mutation in epidermal nevus

Key words: bullous congenital ichthyosiform erythroderma / epidermolytic
hyperkeratosis / granular degeneration / mosaicism / palmoplantar
keratoderma

Abbreviations: BCIE, bullous congenital ichthyosiform erythroderma; EH,
epidermolytic hyperkeratosis; K1, keratin 1; K10, keratin 10; LA-PCR,
long and accurate PCR

Abstract

Since 1994, four cases of epidermal nevus with epidermolytic hyperkeratosis (EH) caused by K10 gene mutations have been reported, although no K1 gene mutation has yet been reported. We detected a K1 gene (*KRT1*) mutation in epidermal nevus with EH in a 10-year-old Japanese male. The patient showed well-demarcated verrucous, hyperkeratotic plaques mainly on the trunk, covering 15 % of the entire body surface. No hyperkeratosis was seen on the palms or soles. He had no family history of skin disorders. His lesional skin showed typical granular degeneration and, ultrastructurally, clumped keratin filaments were observed in the upper epidermis. Direct sequence analysis of genomic DNA extracted from lesional skin revealed a heterozygous 5' donor splice site mutation c.591+2T>A in *KRT1*. This mutation was not detected in genomic DNA samples from patient's peripheral blood leukocytes or those of other family members. The identical splice mutation was previously reported in a family with palmoplantar keratoderma and mild ichthyosis, and was demonstrated to result in a 22 amino acid deletion p.Val175_Lys196del in the H1 and 1A domains of K1. The present patient is the first reported case of epidermal nevus associated with EH caused by a K1 gene mutation in a mosaic pattern.

INTRODUCTION

Epidermal nevi are skin hamartomatous lesions comprised of keratinocytes. Their clinical features include circumscribed verrucous lesions of any size, single or multiple in nature, and they can occur at any site, frequently following Blaschko's lines. Epidermal nevi are thought to reflect a genetic mosaicism and, it has been often hypothesized that epidermal nevi with epidermolytic hyperkeratosis (EH) reflect differentiation specific, suprabasal keratin gene mutations. The term "EH" in this case means pathological changes seen in bullous congenital ichthyosiform erythroderma (BCIE), a keratin 1 (K1)/keratin 10 (K10) disease, although EH is a histological feature of more than one disease. Indeed, K10 gene mutations were reported in four cases of epidermal nevi with EH (Paller *et al.*, 1994; Moss *et al.*, 1995), although no K1 gene mutation has yet been reported. A mosaic mutation in the V1 domain of keratin 16 was reported to underlie unilateral palmoplantar verrucous nevus with vacuolar degeneration of keratinocytes in the upper epidermis (Terrinoni *et al.*, 2000).

A diverse range of subtly different phenotypes including classical BCIE has been described with mutations in K1 (reviewed in Lane and McLean, 2004). Splice site mutations affecting the K1 peptide 1A or 2B domain caused epidermolytic palmoplantar keratoderma (PPK) (reviewed in Terron-Kwiatkowski *et al.*, 2002). Now a total of 47 different mutations have been reported in K1 (The Human Intermediate Filament Database). Here we report that a splice site mutation in the K1 gene, previously reported in a case of PPK and mild ichthyosis, was associated with the epidermal nevus with EH disease phenotype. As far as we know, the

present case is the first reported patient of epidermal nevus with EH associated with a K1 gene mutation.

RESULTS

Clinical features

A 10-year-old Japanese male showed well-demarcated verrucous, hyperkeratotic plaques mainly on the trunk, covering 15 % of his entire body surface. They distributed following the Blaschko's lines (Figure 1). No hyperkeratosis was seen on the palms and soles. The other family members including his parents and elder brother had neither BCIE nor epidermal nevus.

Typical granular degeneration and clumped keratin filaments were seen in the epidermal nevus

Light microscopy of the skin samples from the nevus on the trunk revealed typical granular degeneration with large keratohyalin granules in the upper epidermis (data not shown). Electron microscopy showed clumped keratin filaments in the upper epidermal keratinocytes (data not shown). Some of those keratinocytes with abnormal keratin clumps were undergoing degeneration.

A splice site mutation in K1 gene (*KRT1*) was identified in lesional skin but not in peripheral blood

Mutation analysis of the entire 1-9 exons including the intron-exon boundaries of the K1 gene (*KRT1*) revealed a heterozygous T>A substitution at base position 591+2, in intron 1 (c.591+2T>A) (Figure 2).

This mutation disrupts the *KRT1* exon 1 donor splice site. This mutation was not detected in genomic DNA samples from patient's peripheral blood leukocytes (Figure 2a) or those of his family members. No other mutation was found in the entire exon and intron/exon borders of the K1 and K10 genes. The mutation was not found in 100 normal, unrelated Japanese alleles (50 healthy unrelated Japanese individuals) by sequence analysis, and was unlikely to be a polymorphism (data not shown).

By mutant allele specific amplification analysis (Hasegawa *et al.*, 1995; Xu *et al.*, 2003), a 102 bp fragment derived from the mutant allele was amplified from the genomic DNA sample extracted from the lesional skin (Figure 2b). The 102 bp fragment was sequenced and it was confirmed that the fragment was derived from the targeted region of K1 gene, *KRT1*. The mutant allele specific amplification showed no PCR product bands from the peripheral blood cell DNA samples from the patient, any other family members or controls.

K1 expression was weak and keratin 2e (K2e) expression was upregulated in the epidermal nevus lesion

Immunofluorescence studies revealed that K1 and K10 were present in the lesional epidermal suprabasal layers, although K1 expression was weaker than that in the normal control skin (Figure S1a-d). In the regions showing granular degeneration, abnormal, large granules in the degenerated keratinocytes were positive for K1 and K10. K2e was expressed only in the uppermost spinous and the granular layers of epidermis in normal control skin (Figure S1f). In the patient's lesional skin, K2e expression was seen in the almost all suprabasal epidermal

layers, suggesting an upregulated expression of K2e in the lesional epidermis (Figure S1e).

DISCUSSION

All the reported causative mutations underlying epidermal nevus with EH affected the K10 gene (Paller *et al.*, 1994; Moss *et al.*, 1995). As far as we know, the present case is the first reported case of epidermal nevus with EH caused by a K1 gene mutation.

K2e expression increased in the lesional epidermis of the present case. Although we do not have any direct evidence, K2e expression might be upregulated compensatively in the epidermis with disrupted keratin network. Indeed, increased K2e expression was also observed in the lesional epidermis with disturbed keratin network of ichthyosis bullosa of Siemens patients (Akiyama *et al.*, 2005).

In our case, the causative K1 mutation was detected only in the lesional skin, but not in the peripheral blood cells, as previously reported in K10 mutations in epidermal nevus with EH (Paller *et al.*, 1994; Moss *et al.*, 1995). Our findings further support that the mutation detection of K1 as well as K10 in epidermal nevus can be reliably performed only from direct examination of lesional skin, not from analysis of other tissue or peripheral blood cells.

As epidermal nevus is a disease caused by somatic mosaicism, widespread

skin lesions increase the risk of germ-line transmission (Paller *et al.*, 1994). In case causative K1 or K10 mutations are transmitted in germ-line, a half of the children from patients with epidermal nevus with EH are expected to be affected with ichthyosis on the whole body. Mutation analysis using a patient's sperm gives us information on germ-line transmission (Zlotogora, 1998; Rantamaki *et al.*, 1999). If the germ-line transmission is confirmed, prenatal genetic screening may be applied for the offspring of the patient as previously reported in the prenatal diagnosis of BCIE by molecular analysis (Rothnagel *et al.*, 1994; Tsuji-Abe *et al.*, 2004).

The K1 gene mutation detected in the present case was a splice donor site mutation c.591+2T>A. According to Splice Site Prediction by Neural Network software (http://www.fruitfly.org/seq_tools/splice.html) (Tal *et al.*, 2005; Wessagowit *et al.*, 2005; Wessagowit *et al.*, 2006), a consequence of this mutation is predicted with the highest probability, we can expect a splice variant with an upstream cryptic splice donor site resulting in a 66 bp deletion (22 amino acid deletion; p.Val175-Lys196del). The second highest probability, an alternative splice pattern activating a cryptic donor site 22 bp downstream of the mutation with the subsequent insertion of 8 amino acids into the 1A rod domain was predicted. Indeed, in a patient with PPK with the same K1 gene mutation as in the present case, mRNA expression analysis by *in vitro* splicing assay clearly indicated that the splice site mutation c.591+2T>A results in a partial deletion of the H1 and 1A domains of K1 (p.Val175_Lys196del) (Terron-Kwiatkowski *et al.*, 2002), as predicted by the highest probability using the software model. Concerning reported mutations in the adjacent nucleotide as our mutation

in the K1 gene, i.e. splice donor site mutations c.591+1T>A and c.591+3T>A were reported to lead to the same 22 amino acid deletions (Vitanen *et al.*, 2003; Tal *et al.*, 2005). Thus, we may expect an identical 22 amino acid deletion p.Val175_Lys196del in K1 peptides as a consequence of the *KRT1* mutation c.591+2T>A in lesional keratinocytes from the present patient.

Interestingly, the *KRT1* mutation that had been reported to cause PPK (Terron-Kwiatkowski *et al.*, 2002) led to an epidermal nevus with EH phenotype distributed on the trunk and the extremities in our case. In the previous PPK patient with an identical mutation, only mild hyperkeratosis was found over limited body areas and it was speculated that loss of the protein motif in the helix boundary that is essential for the interaction of keratin filaments (Steinert *et al.*, 1993) have a less disruptive effect on normal keratin filament assembly (Terron-Kwiatkowski *et al.*, 2002). A similar mechanism can be expected in deletions at either end of the K1 rod domain. Indeed, a splice site mutation in K1 that leads to the insertion of 18 amino acids into the 2B domain led to a mild epidermolytic PPK phenotype (reviewed in Terron-Kwiatkowski *et al.*, 2002). However, in our case, the mosaicism of the mutation showed an epidermal nevus phenotype even on the trunk and the extremities. The precise mechanism of how identical splice site mutations can result in a different severity of the lesions on the trunk remains unclear.

Until the present report, all the reported mosaic mutations causing

epidermal nevus with EH had been due to K10 mutations that would have resulted in BCIE if every cell in the body were affected (Paller *et al.*, 1994; Moss *et al.*, 1995). In conclusion, the present case clearly indicated that K1 mutations with genetic mosaicism also cause epidermal nevus with EH. The present K1 mosaicism might have led to PPK with mild hyperkeratotic lesions if all the epidermal cells were affected over the entire body surface (Terron-Kwitkowski *et al.*, 2002).

MATERIALS AND METHODS

Mutation detection Mutation analysis was performed using genomic DNA extracted from the lesional epidermal nevus skin and peripheral blood leukocytes from the patient. In the other family members and normal controls, genomic DNA isolated from peripheral blood leukocytes was used for the analysis. Briefly, genomic DNA samples were subjected to PCR amplification, followed by direct automated sequencing using an ABI PRISM 3100 genetic analyzer (ABI Advanced Biotechnologies, Columbia, MD, U.S.A.). The oligonucleotide primers were designed using the website program (primer3_www.cgi v 0.2). The primers used for amplification of exon 1 were as follows; forward, gtggacgtggtagtggcttt; reverse, ctttagtcgaccaccaacc. The entire coding region including the intron/exon boundaries for both forward and reverse strands were sequenced. For normal controls, 50 healthy unrelated Japanese individuals (100 normal alleles) were studied.

Mutant allele specific amplification analysis Long and accurate (LA)-PCR was done using primers, forward primer ex1F1;

aggaggtgggagatttt and a reverse primer ex2R; catgctgcttcgatcttagc. For the verification of the mutation, using LA-PCR products as a template, mutant allele specific amplification analysis was performed with mutant allele specific primers carrying the substitution of two bases at the 3'-end (Linard *et al.*, 2002; Sapio *et al.*, 2006), as follows; forward, gcctccttcattgacaagaa; reverse, ttcaaacctgcgtgtgttttgactgcaccgatccc. PCR conditions were as follows; 94°C for 5 min after (hot-start procedure) and then 94°C for 1 min, 56°C for 1 min, 72°C for 1 min during 35 cycles, followed by 72°C for 7 min. Only the 102 bp fragment derived from the mutant allele was amplified with these primers and the PCR condition.

Ultrastructural observations Epidermal nevus on the trunk was biopsied for morphological observation. Skin biopsy samples were fixed in 2% glutaraldehyde solution, post-fixed in 1% OsO₄, dehydrated, and embedded in Epon 812. The samples were sectioned at 1 µm thickness for light microscopy and thin sectioned for electron microscopy (70 nm thick). The thin sections were stained with uranyl acetate and lead citrate and examined in a transmission electron microscope.

Antibodies Polyclonal anti-K1 antiserum (DAKO, Glostrup, Denmark), anti-K2e antibody (Progen Biotechnick, Heidelberg, Germany) and anti-K10 antiserum (Novocastra, New Castle upon Tyne, England) were used in the present study.

Immunofluorescent labeling Immunofluorescent labeling was performed as described previously (Akiyama *et al.*, 2000). Briefly,

6- μ m-thick sections of freshly frozen patient's skin was cut using a cryostat. The sections were incubated in primary antibody solution for 30 min at 37°C. Antibody dilutions were as follows; 1/10 for anti-K1 antiserum, 1/50 for anti-K2e antibody and 1/100 for anti-K10 antibody. The sections were then incubated in fluorescein isothiocyanate-conjugated to rabbit anti-mouse immunoglobulins and FITC-conjugated goat anti-mouse immunoglobulins diluted 1:100 (DAKO, Glostrup, Denmark) for 30 min at 37°C. The sections were extensively washed with phosphate-buffered saline between incubations. The stained sections were then mounted with a cover slip and observed using a confocal laser scanning microscope.

The medical ethical committee at Hokkaido University and Hokkaido Cancer Institute approved all described studies. The study was conducted according to the Declaration of Helsinki Principles. Participants gave their written, informed consent.

Conflict of Interest

The authors state no conflict of interest.

ACKNOWLEDGEMENTS

We thank Ms. Megumi Sato and Ms. Akari Nagasaki for their technical assistance on this project. We also thank Prof. James R. McMillan for proofreading this manuscript. This work was supported in part by Grants-in-Aid from the Ministry of Education, Science, Sports, and Culture of Japan to M. Akiyama (Kiban B 18390310) and to H. Shimzu (Kiban A

17209038).

SUPPLEMENTARY MATERIALS

Figure S1. Immunofluorescent staining for K1 was weak, although K2e expression was upregulated in the epidermal nevus.

REFERENCES

Akiyama M, Smith LT, Shimizu H (2000) Changing patterns of localization of putative stem cells in developing human hair follicles. *J Invest Dermatol* **114**: 321-7

Akiyama M, Tsuji-Abe Y, Yanagihara M, Nakajima K, Kodama H, Yaosaka M, Abe M, Sawamura D, Shimizu H (2005) Ichthyosis bullosa of Siemens: its correct diagnosis facilitated by molecular genetic testing. *Br J Dermatol* **152**: 1353-6

Hasegawa Y, Takeda S, Ichii S, Koizumi K, Maruyama M, Fujii A, *et al.* (1995) Deletion of K-ras mutations in DNAs isolated from faces of patients with colorectal tumors by mutant-allele-specific-amplification (MASA). *Oncogene* **10**: 1441-5

Lane EB, Mclean WHI (2004) Keratins and skin disorders. *J Pathol* **204**: 355-66

Linard B, Bezieau S, Benlalam H, Labarrere N, Guilloux Y, Diez E, *et al.* (2002) A ras-mutated peptide targeted by CTL infiltrating a human melanoma lesion. *J Immunol* **168**:4802-8

Moss C, Jones DO, Blight A, Bowden PE (1995) Birthmark due to cutaneous mosaicism for keratin 10 mutation. *Lancet* **345**: 596

Paller AS, Syder AJ, Chan YM, Yu QC, Hutton E, Tadini G, *et al.* (1994)

Genetic and clinical mosaicism in a type of epidermal nevus. *N Engl J Med* **331**:1408-15

Rantamaki T, Kaitila I, Syvanen A-C, Lukka M, Peltonen L (1999)
Recurrence of Marfan syndrome as a result of parental germ-line
mosaicism for an FBN1 mutation. *Am J Hum Genet* **64**: 993-1001

Rothnagel JA, Longley MA, Holder RA, Kuster W, Roop DR (1994)
Prenatal diagnosis of epidermolytic hyperkeratosis by direct gene
sequencing. *J Invest Dermatol* **102**:13-6

Sapio MR, Posca SD, Trocone G, Pettinato G, Palombini L, Rossi G, *et al.*
(2006) Detection of BRAF mutation in thyroid papillary carcinomas
by mutant allele-specific PCR amplification (MASA). *Eur J*
Endocrinol **154**: 341-8

Steinert PM, Yang JM, Bale SJ, Compton JG (1993) Concurrence between
the molecular overlap regions in keratin intermediate filaments and the
locations of keratin mutations in genodermatoses. *Biochem Biophys*
Res Commun **197**: 840-8

Tal O, Bergman R, Alcalay J, Indelman M, Sprecher E (2005)
Epidermolytic hyperkeratosis type PS-1 caused by aberrant splicing of
KRT1. *Clin exp dermatol* **30**:64-7

Terrinoni A, Puddu P, Didona B, De Laurenzi V, Candi E, Smith FJ,
McLean WH, Melino G (2000) A mutation in the V1 domain of K16 is

responsible for unilateral palmoplantar verrucous nevus. *J Invest Dermatol* **114**: 1136-40

Terron-Kwiatkowski A, Paller AS, Compton J, Atherton DJ, McLean WH, Irvine AD (2002) Two cases of primarily palmoplantar keratoderma associated with novel mutations in keratin 1. *J Invest Dermatol* **119**: 966-71

Tsuji-Abe Y, Akiyama M, Nakamura H, Takizawa Y, Sawamura D, Matsunaga K, *et al.* (2004) DNA-based prenatal exclusion of bullous congenital ichthyosiform erythroderma at the early stage, 10-11 weeks' of pregnancy in two consequent siblings. *J Am Acad Dermatol* **51**: 1008-11

Vitanen M, Smith SK, Gedde-Dahl Jr T, Vahlquist A, Bowden PE (2003) Splice site and deletion mutations in keratin (KRT1 and KRT10) genes: Unusual phenotypic alterations in scandinavian patients with epidermolytic hyperkeratosis. *J Invest Dermatol* **121**: 1013-20

Wessagowit V, Kim SC, Woong OS, McGrath JA (2005) Genotype-phenotype correlation in recessive dystrophic epidermolysis bullosa: when missense doesn't make sense. *J Invest Dermatol* **124** : 863-6

Wessagowit V, Nalla VK, Rogan PK, McGrath JA (2006) Normal and abnormal mechanisms of gene splicing and relevance to inherited skin disease. *J Dermatol Sci* **40**: 73-84

Xu X, Quiros RM, Gattuso P, Ain KB, Prinz RA (2003) High prevalence of BRAF gene mutation in papillary thyroid carcinomas and thyroid tumor cell lines. *Cancer Res* **63**: 4561-7

Zlotogora J. Germ line mosaicism (1998) *Hum Genet* **102**: 381-6

FIGURE LEGENDS

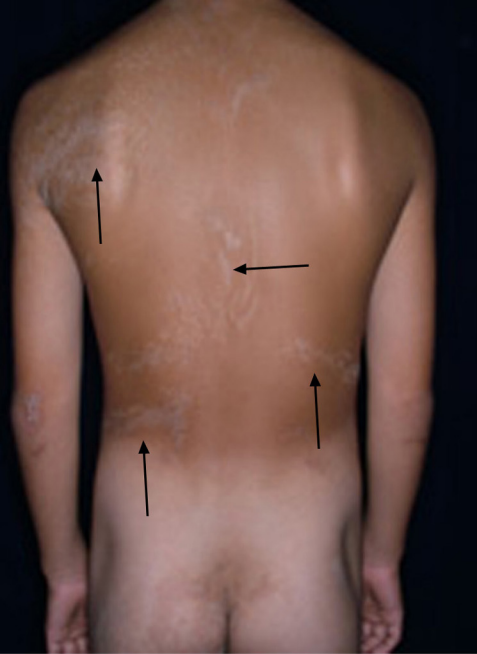Figure 1. Clinical features of epidermal nevi at the age of 10

Well-demarcated verrucous, hyperkeratotic plaques, light to dark brown in color, were seen on the back (a), axilla (b) and abdomen (c).

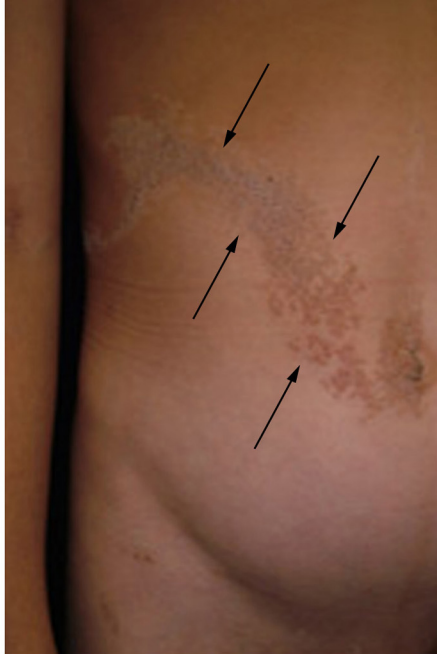Figure 2. A splice site mutation c.591+2T>A was detected in the lesional skin

(a) Direct sequencing of *KRT1* exon 1 PCR products derived from patient's lesional skin revealed heterozygous donor splice site mutation c.591+2T>A. This mutation was not detected in genomic DNA samples from the patient's peripheral blood leukocytes.

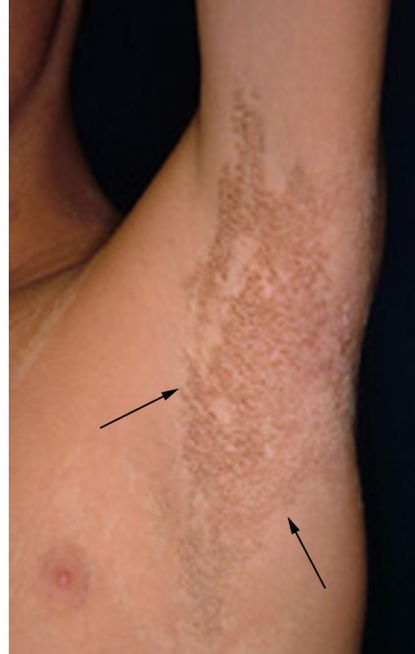(b) Mutant allele specific amplification analysis showed the amplification band from the mutant allele as a 102 bp fragment only from the DNA sample from the patient's lesional skin, confirming the presence of the mutation c.591+2T>A in the patient's epidermal nevus.



a

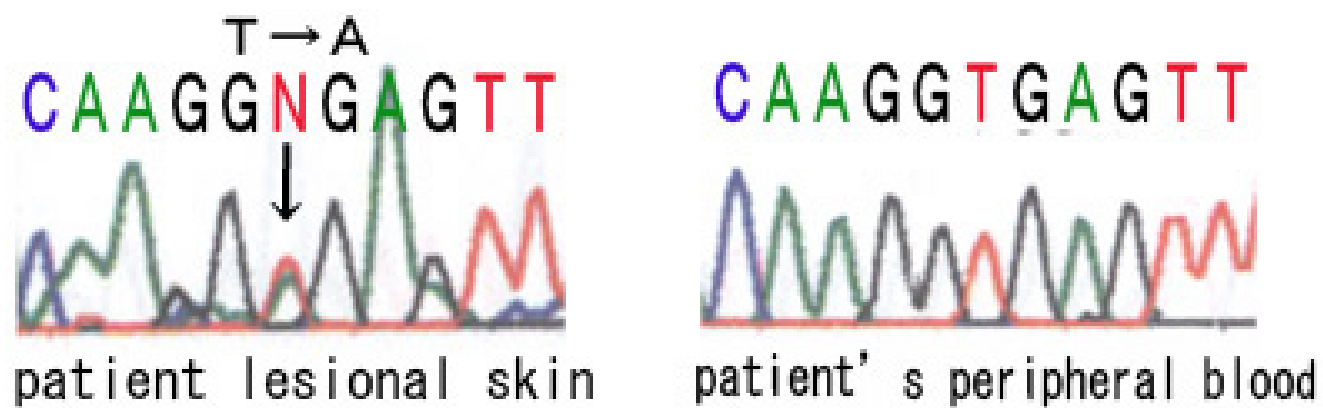


b




c

a



b

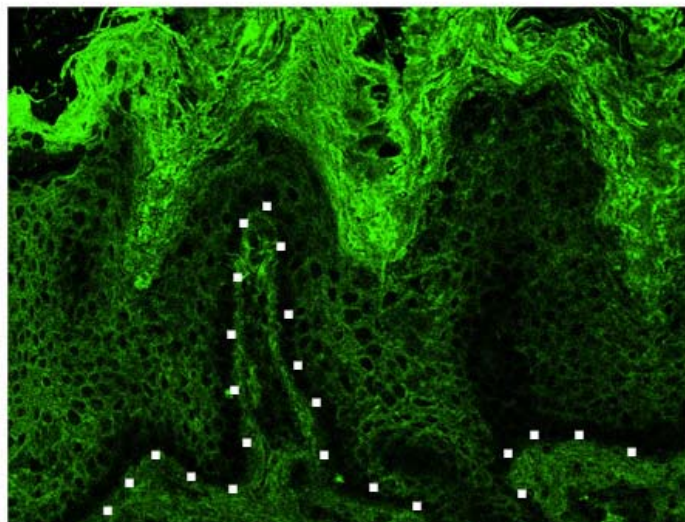


patient

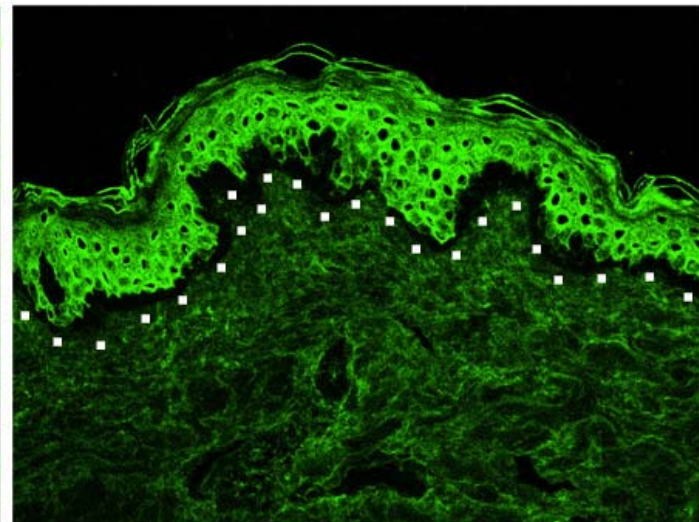
normal control

a

K1

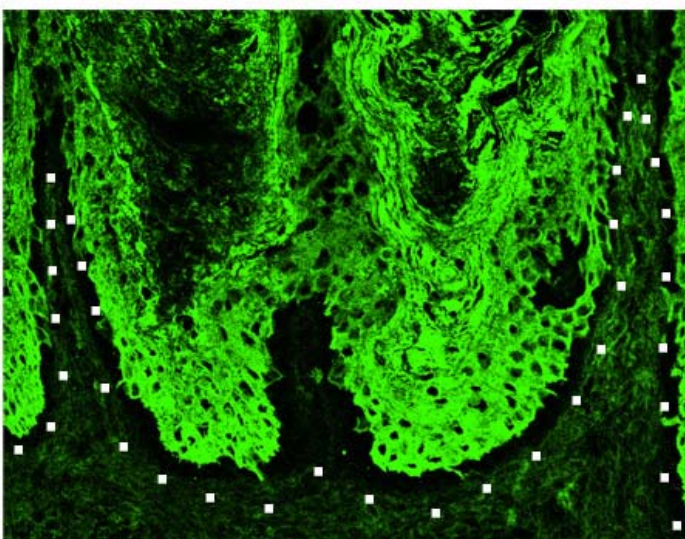


b

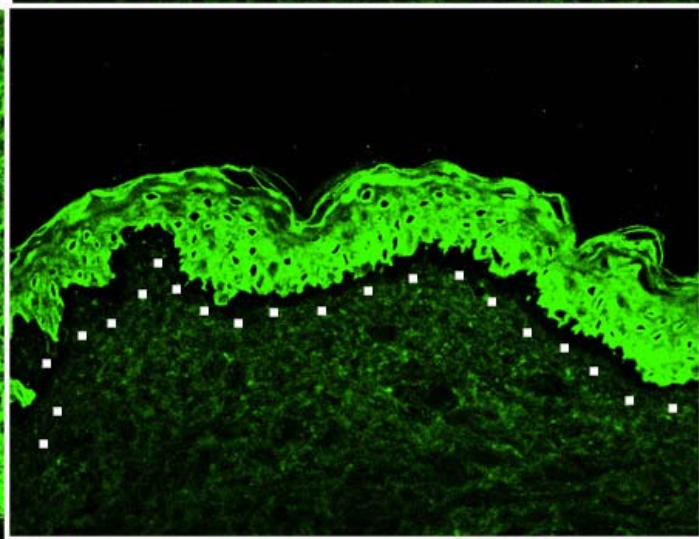


c

K10

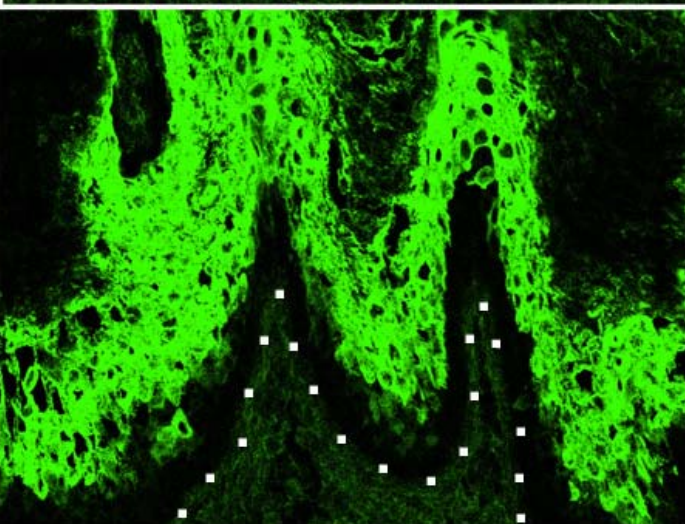


d



e

K2e



f

