HOKKAIDO UNIVERSITY

Title	Autologous Osteochondral Mosaicplasty for Osteochondritis Dissecans of the Elbow in Teenage Athletes
Author(s)	Iwasaki, Norimasa; Kato, Hiroyuki; Ishikawa, Jyunichi; Masuko, Tatsuya; Funakoshi, Tadanao; Minami, Akio
Citation	Journal of Bone and Joint Surgery (American), 91(10), 2359-2366 https://doi.org/10.2106/JBJS.H.01266
Issue Date	2009-10-01
Doc URL	http://hdl.handle.net/2115/39625
Rights	Copyright © 2009 by the Journal of Bone and Joint Surgery, Incorporated
Type	article
File Information	JBJSA91-10_p2359-2366.pdf

Instructions for use

Hokkaido University Collection of Scholarly and Academic Papers : HUSCAP

THE JOURNAL OF BONE & JOINT SURGERY

JB&JS

This is an enhanced PDF from The Journal of Bone and Joint Surgery

The PDF of the article you requested follows this cover page.

Autologous Osteochondral Mosaicplasty for Osteochondritis Dissecans of the Elbow in Teenage Athletes

Norimasa Iwasaki, Hiroyuki Kato, Jyunichi Ishikawa, Tatsuya Masuko, Tadanao Funakoshi and Akio Minami
J Bone Joint Surg Am. 2009;91:2359-2366. doi:10.2106/JBJS.H.01266

This information is current as of October 27, 2009

Supplementary material Commentary and Perspective, data tables, additional images, video clips and/or translated abstracts are available for this article. This information can be accessed at **http://www.ejbjs.org/cgi/content/full/91/10/2359/DC1**

Reprints and Permissions Click here to **order reprints or request permission** to use material from this article, or locate the article citation on jbjs.org and click on the [Reprints and Permissions] link.

Publisher Information The Journal of Bone and Joint Surgery
20 Pickering Street, Needham, MA 02492-3157
www.jbjs.org

COPYRIGHT © 2009 BY THE JOURNAL OF BONE AND JOINT SURGERY, INCORPORATED

Autologous Osteochondral Mosaicplasty for Osteochondritis Dissecans of the Elbow in Teenage Athletes

By Norimasa Iwasaki, MD, PhD, Hiroyuki Kato, MD, PhD, Jyunichi Ishikawa, MD, PhD, Tatsuya Masuko, MD, PhD, Tadanao Funakoshi, MD, PhD, and Akio Minami, MD, PhD

Investigation performed at the Department of Orthopaedic Surgery, Hokkaido University School of Medicine, Sapporo, and the Department of Orthopaedic Surgery, Shinsyu University School of Medicine, Matsumoto, Japan

Background: Although autologous osteochondral mosaicplasty is widely used as a procedure for osteochondritis dissecans lesions, the effectiveness of this procedure in elbow lesions remains unclear. Our aim was to clarify the surgical efficacy of mosaicplasty for teenage athletes with advanced lesions of capitellar osteochondritis dissecans.

Methods: From 2001 to 2006, nineteen teenage male patients who were competitive athletes and had advanced lesions of capitellar osteochondritis dissecans underwent mosaicplasties. The mean age of the patients was 14.2 years. The surgical technique involved obtaining small-sized cylindrical osteochondral grafts with a mean diameter of 3.5 mm from the lateral periphery of the femoral condyle at the level of the patellofemoral joint and transplanting the grafts (mean, 3.3 grafts) to prepared osteochondral defects. The patients were evaluated clinically and radiographically at a mean of forty-five months after surgery.

Results: Eighteen patients were free from elbow pain, and one had mild pain occasionally. The mean total arc of elbow motion and standard deviation increased significantly from 112° ± 17° preoperatively to 128° ± 12° postoperatively ($p < 0.005$). The mean clinical score described by Timmerman and Andrews (with a maximum of 200 points) improved significantly from 131 ± 23 points preoperatively to 191 ± 15 points postoperatively ($p < 0.0001$). All patients except one had an excellent or good clinical result. All donor knees were graded as excellent on the basis of the Lysholm knee scoring system. All patients except two returned to a competitive level of the sport they had previously played. Neither loose-body formation nor secondary osteoarthritic changes were found in any patient.

Conclusions: The current midterm results indicate that mosaicplasty can provide satisfactory clinical outcomes for teenage athletes with advanced capitellar osteochondritis dissecans lesions.

Level of Evidence: Therapeutic Level IV. See Instructions to Authors for a complete description of levels of evidence.

Osteochondritis dissecans is an idiopathic lesion affecting the articular surface, which involves separation of the cartilage and the subchondral bone. Most cases affecting the elbow involve the humeral capitellum and frequently occur in teenage athletes, especially baseball players. Because of the limited potential of the articular cartilage for self-repair, the treatment of advanced capitellar osteochondritis dissecans lesions is challenging. Although various surgical options such as removal of the loose bodies with or without drilling or curettage, abrasion chondroplasty, and the reattachment of fragments have been advocated for treating advanced osteochondritis dissecans lesions, these procedures have been shown to provide only temporary relief of symptoms and osteoarthritis can still be the result[1-5].

The goals for treating capitellar osteochondritis dissecans, especially in young athletes, are to allow patients to

Disclosure: The authors did not receive any outside funding or grants in support of their research for or preparation of this work. Neither they nor a member of their immediate families received payments or other benefits or a commitment or agreement to provide such benefits from a commercial entity. No commercial entity paid or directed, or agreed to pay or direct, any benefits to any research fund, foundation, division, center, clinical practice, or other charitable or nonprofit organization with which the authors, or a member of their immediate families, are affiliated or associated.

A video supplement to this article will be available from the *Video Journal of Orthopaedics*. A video clip will be available at the JBJS web site, www.jbjs.org. The *Video Journal of Orthopaedics* can be contacted at (805) 962-3410, web site: www.vjortho.com.

Fig. 1-A

Fig. 1-B

Figs. 1-A and 1-B Anteroposterior plain radiographs of two elbows with each showing a fragment (white arrow) displaced from the capitellum. **Fig. 1-A** A lesion in the center of the capitellum (central type). **Fig. 1-B** A lesion in the lateral portion of the capitellum (lateral type).

return to their previous level of sporting activities and to avoid the subsequent development of osteoarthritis. One way to achieve these goals may be to resurface the osteochondral defects with normal hyaline cartilage. Autologous osteochondral mosaicplasty (mosaicplasty) is an innovative technique designed to provide hyaline repair of articular cartilage defects[6-8]. This procedure has provided successful treatment of osteochondral defects in the knee and ankle joints[7-9].

For the past several years, a few studies have indicated the effectiveness of mosaicplasty in treating advanced lesions of capitellar osteochondritis dissecans as well as osteochondral defects in the knee and ankle joints[4,10-14]. However, most have described only short-term follow-up of a small number of patients[4,10-13], including a mean two-year follow-up report on eight of the patients in the present series[11]. Consequently, the ability of mosaicplasty to prevent the progression of capitellar osteochondritis dissecans is not yet widely acknowledged. In particular, there is little agreement as to the efficacy of this procedure in treating this lesion in adolescent athletes. As mentioned above, the goal of treatment for capitellar osteochondritis dissecans in such patients is not to improve symptoms temporarily, but to return the patients to their previous sports activities without functional disturbance. The purpose of this study was to clarify the clinical and radiographic results of mosaicplasty performed on teenage athletes with advanced capitellar osteochondritis dissecans lesions after a minimum of two years.

Materials and Methods

From 2001 to 2006, nineteen consecutive male patients with advanced lesions of capitellar osteochondritis dissecans underwent mosaicplasty at our institute (see Appendix). All patients had been engaged in competitive sports and were unable to perform their sports activities at the time of surgery because of severe elbow pain. The mean age of the patients at the time of surgery was 14.2 years (range, eleven to nineteen years). Indications for this surgery included failure of more than six months of conservative treatment or evidence on plain radiographs and magnetic resonance imaging of unstable lesions, such as displaced or detached fragment(s). Conservative treatment consisted of advising against heavy use of the affected elbow, including throwing and carrying heavy loads. Any patient with an open growth plate of the capitellum or a lesion of <5 mm in diameter was excluded. During this period, all patients who met the above criteria underwent mosaicplasty. All such patients were followed for a minimum of twenty-four months postoperatively and were included in this case series. Informed consent was obtained preoperatively from the patients and parents on the basis of the surgical indication as determined at our institute, and the patients returned for follow-up evaluation postoperatively. All operations were performed by two senior authors (N.I. and H.K.). Small cylindrical osteochondral grafts were obtained from the knee joint. Then, the grafts were transplanted into the osteochondral defects in the capitellum with use of a mosaicplasty system (Acufex Mosaicplasty DP; Smith and Nephew, Andover, Massachusetts).

Patient Demographics

In all patients, the dominant side was affected. Only one patient had previous surgery on the elbow: drilling of the osteochondritis dissecans lesion three years before mosaicplasty. Preop-

erative symptoms consisted of pain with sports activities in all nineteen patients, limited range of motion in five patients, and elbow catching in three patients. Plain radiographs showed displaced fragments in seven patients, whereas detached fragments were found in twelve patients. According to the radiographic classification system of Minami et al.[4,15], all elbows had a displaced or detached fragment (grade III). Ten lesions were located in the center of the capitellum (Fig. 1-A), and nine lesions were in the lateral portion (Fig. 1-B). On the basis of the magnetic resonance imaging criteria of unstable osteochondritis dissecans lesions described by De Smet et al.[16], T2-weighted images showed an unstable lesion in all patients. Nine lesions showed an articular fracture indicated by a high signal passing through the subchondral bone plate (Fig. 2-A), and eight lesions demonstrated a focal osteochondral defect (Fig. 2-B). The remaining two showed a line of high signal deep to the fragment and a discrete round area of high signal intensity beneath the osteochondritis dissecans lesion, indicating a cyst.

Operative Technique

Under general anesthesia, the patient is placed supine and the affected arm is brought across the chest. In the early six cases of this series, the operation was performed through the Kocher lateral approach between the anconeus and the extensor carpi ulnaris. To achieve a better operative field, in the last thirteen cases, we used a posterior approach to the capitellar lesion as described here. A 4 to 6-cm longitudinal skin incision is made just ulnar to the posterior aspect of the proximal radioulnar joint. Then, the fascia over the anconeus muscle is incised. The proximal radiohumeral joint is exposed posteriorly by splitting the anconeus muscle fibers. The capsule is incised just over the capitellar lesion from the posterior edge of the lateral epicondyle to the proximal edge of the anular ligament (Fig. 3-A). A limited local synovectomy is easily performed with use of this approach. Even though the osteochondritis dissecans lesion exists in the anterior part of the capitellum, the lesion can be well visualized with extreme flexion of the elbow. Through this approach, damage to the lateral collateral ligament can be prevented during the operation. In patients with severe restriction of elbow flexion, the anterior part of the osteochondritis dissecans lesion cannot be visualized and should be treated with use of the Kocher lateral approach.

First, the osteochondritis dissecans lesion is assessed directly. The detached or dislocated fragment is raised with use of a chisel, and the subchondral fibrous tissue is curetted. Its edges are also débrided to healthy hyaline cartilage. By tapping a drill-guide down to viable subchondral bone, the optimal depth of filling of the defect can be determined.

To harvest cylindrical grafts, a lateral parapatellar mini-arthrotomy of the knee contralateral to the involved elbow is then performed. With use of an appropriately sized tubular chisel and a special device (Acufex Mosaicplasty DP; Smith and Nephew), small-sized (mean, 3.5 mm in diameter; range, 2.7 to 6.0 mm in diameter and 10 to 15 mm in length) cylindrical

Fig. 2-A

Fig. 2-B

Sagittal T2-weighted magnetic resonance imaging scans demonstrate an articular fracture indicated by a high signal passing through the subchondral bone (arrow in Fig. 2-A) and a focal osteochondral defect (arrow in Fig. 2-B).

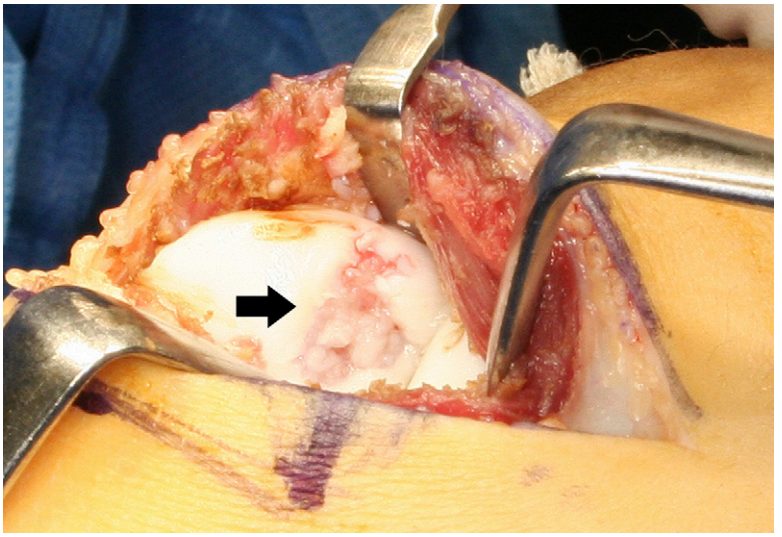

Fig. 3-A

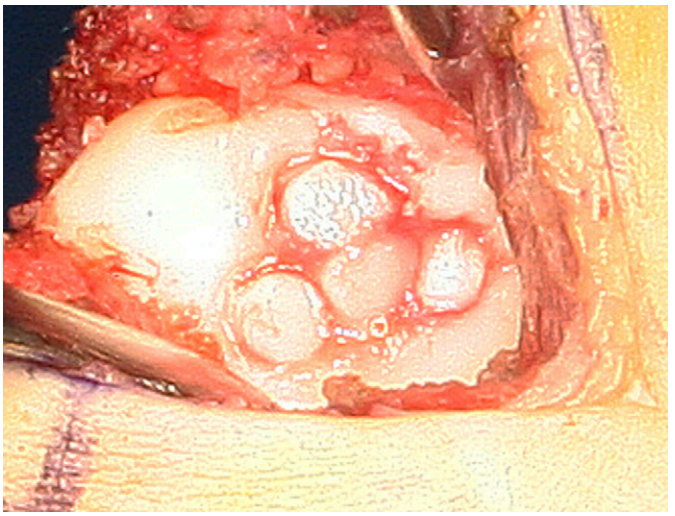

Fig. 3-B

Figs. 3-A and 3-B Operative technique. **Fig. 3-A** The capitellar lesion (arrow) is exposed through a posterior approach by splitting the anconeus muscle. **Fig. 3-B** Placement of the 3.5-mm-diameter cylindrical osteochondral grafts by press-fitting them flush into the prepared osteochondral defect.

osteochondral grafts are obtained from the lateral periphery of the femoral condyle at the level of the patellofemoral joint. The lateral periphery bears less weight, which means there is less contact pressure[17]. For patients with an open growth plate of the distal end of the femur, we harvest shorter grafts to avoid damage to the plate. The harvested grafts are transplanted to prepared osteochondral defects in the capitellum (Fig. 3-B). We attempt to leave the grafts protruding slightly in the lateral lesions and to place them flush with the surrounding articular surface in the central lesions. Each donor site is packed with bone wax to prevent postoperative bleeding. Drains are left in both the elbow and knee joints. The incised capsule of both joints is tightly sutured, and the wounds are closed. The drains are removed between twenty-four and forty-eight hours after surgery.

Postoperatively, the elbow is immobilized in 90° of flexion with the forearm in a neutral position for two weeks to promote soft-tissue healing. Regarding the knee joint, the patients are instructed to begin partial weight-bearing at two days and they are allowed to walk freely at seven days postoperatively. We do not direct the patients to do any specific rehabilitation for the knee. The patient begins active and assisted passive motion exercises of the elbow and forearm immediately after removal of the splint. Strengthening exercises of the elbow and forearm are allowed at three months postoperatively. If the patient does not have any symptoms in the elbow joint, we allow him to begin throwing activity at six months after surgery and he is permitted to return to his previous level of throwing activity at eight to twelve months postoperatively. Specifically, we instruct baseball players to return to their previous level at eight months for fielders and at twelve months for pitchers.

Postoperative Assessment

Postoperative assessment included the clinical rating system of Timmerman and Andrews[18] (see Appendix), functional evaluation of the donor knee, completion of a questionnaire regarding the athlete's return to sports, and an evaluation of the radio-

graphs. The clinical rating system consisted of both subjective (pain, swelling, locking and/or catching, and activities) and objective (range-of-motion) evaluations. On the basis of the clinical scores, overall clinical results were classified into the following four categories: excellent (a score of 180 to 200), good (a score of 160 to 179), fair (a score of 120 to 159), or poor (a score of <120). Two observers (N.I. and H.K.) independently examined the clinical findings at the time of follow-up. The knee evaluation consisted of local findings of the donor knee, a Lysholm knee scoring scale[19], and the completion of an International Knee Documentation Committee (IKDC) standard evaluation form (objective)[20]. The magnetic resonance imaging evaluation focused on evidence of graft loosening, which included graft displacement or migration, or fluid surrounding the graft on the T2-weighted images. The quality of the repair was semiquantitatively assessed on the basis of the magnetic resonance imaging findings according to the scoring system of Roberts et al.[21] (see Appendix). The score was based on the review of a postoperative magnetic resonance imaging scan by a musculoskeletal radiologist who was blinded to the clinical outcomes.

Statistical Analysis

All data are presented as the mean and the standard deviation. Statistical comparisons between preoperative and postoperative results were performed with use of paired t tests. The level of significance was set at a probability value of <0.05.

Source of Funding

The authors did not receive any outside funding or grants in support of their research for or presentation of this work.

Results

Operative Findings

A fragment with macroscopically intact cartilage was found in all nineteen patients. According to the International Cartilage Repair Society (ICRS) classification of osteochondritis dissecans (OCD) lesions (see Appendix)[22], our macroscopic intraoperative findings were classified as ICRS OCD III in seven lesions and as ICRS OCD IV in twelve lesions. The size of each defect was calculated, and the mean defect size was 147 mm^2 (range, 49 to 300 mm^2). The patients received a mean of 3.3 grafts. In one patient, six grafts were used for reconstruction; in three patients, five grafts; in three patients, four grafts; in six patients, three grafts; and in six patients, two grafts were used.

Clinical Evaluation of the Elbow

At a mean follow-up interval of 45.1 months (range, twenty-four to eighty-seven months), the mean Timmerman and Andrews score improved significantly from 131 ± 23 points (subjective, 59 ± 9 points; objective, 71 ± 19 points) to 191 ± 15 points (subjective, 99 ± 2 points; objective, 91 ± 14 points) postoperatively ($p < 0.0001$). The overall evaluation was excellent in seventeen patients, good in one patient, and fair in one patient (see Appendix). Eighteen of the nineteen patients were free from elbow pain, and the remaining one occasionally had mild pain. The mean range of elbow motion increased significantly from 112° ± 17° (extension, −13° ± 10°; flexion, 124° ± 13°) to 128° ± 12° (extension, −4° ± 9°; flexion, 133° ± 7°) postoperatively ($p < 0.005$). The mean total arc of elbow motion compared with that on the contralateral side was

Fig. 4-A

Fig. 4-B

Plain radiographs of the patient depicted in Figures 3-A and 3-B, made at the time of the thirty-six-month follow-up, reveal graft incorporation. No loose bodies or secondary degenerative changes can be seen.

Fig. 5-A

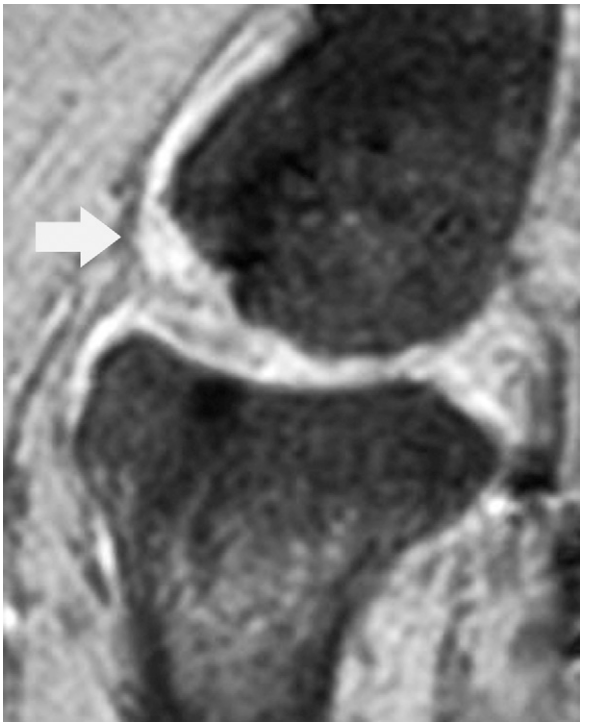

Fig. 5-B

A sagittal T2-weighted magnetic resonance imaging scan made at thirty-six months postoperatively shows that the cartilage signal intensity of the osteochondritis dissecans lesion has returned to normal (arrow in Fig. 5-A). The grafted cartilage appeared thicker than the adjacent cartilage (arrow in Fig. 5-B) in eleven of our nineteen patients.

92% ± 9% postoperatively. Five patients had a loss of extension of ≥5°. The mean total arc of pronation and supination did not change significantly from 164° ± 8° (pronation, 78° ± 7°; supination, 88° ± 4°) preoperatively to 165° ± 9° (pronation, 79° ± 6°; supination, 85° ± 5°) postoperatively. There was no apparent restriction of forearm rotation in any patient.

Functional Evaluation of the Donor Knee

At the time of follow-up, only one patient had any symptoms or local findings in the donor knee. This patient had mild anterior knee pain with stair-climbing. No restriction in the range of knee motion was found in any patient. The mean Lysholm knee score was 99.6 ± 5 points (range, 96 to 100 points), and all knees were graded as excellent. According to the IKDC evaluation form, all knees were characterized as normal.

Return to Sports Activities

Seventeen of the nineteen patients, including all baseball pitchers, returned to a competitive level of the sports they had previously played. They had no disturbances in the involved elbow or donor knee during their competitive sports activities. The remaining two patients did not return to baseball. Instead, they simply chose to play rugby and soccer, respectively, despite acceptable clinical results.

Radiographic Evaluation

Plain radiographs made at the time of follow-up revealed graft incorporation in all patients (Figs. 4-A and 4-B). No loose bodies or secondary osteoarthritic changes were seen in any patient, and no radiograph showed an increase in radial head diameter. Ectopic new-bone formation lateral to the capitellum was recognized in two patients with a lateral type of lesion. However, no symptoms related to these lesions were reported. The mean postoperative magnetic resonance imaging score, according to the system of Roberts et al., was 3.0 ± 0.8 points (maximum possible, 4 points). The preoperative heterogeneity of the lesions seen on magnetic resonance imaging disappeared in all patients. All osteochondral grafts were well seated within the recipient sites, without magnetic resonance imaging evidence of graft loosening. With regard to the surface integrity of the articular cartilage and changes in the underlying bone, all patients except one had nearly normal findings. One patient had irregularity of the interface between the grafts and the recipient bed, and subchondral bone cysts were also present. The cartilage signal intensity of the grafted site returned to normal or nearly normal in all patients (Fig. 5-A). In eleven of the nineteen patients, the grafted cartilage appeared thicker than the adjacent cartilage (Fig. 5-B). In terms of the donor knee, plain radiographs demonstrated no abnormal findings in any patient.

Discussion

Our results at a mean follow-up of four years show the efficacy of mosaicplasty for the treatment of advanced lesions of capitellar osteochondritis dissecans in teenage athletes. In the clinical assessment, eighteen of the nineteen patients achieved excellent or good results after this procedure. Magnetic resonance imaging depicted both graft viability and the resurfacing of osteochondritis dissecans lesions with normal or nearly normal cartilage. No evidence of sequential osteoarthritic changes was found in any patient. On the other hand, Bauer et al.[1] reported that 42% of thirty-one osteochondritis dissecans lesions of the elbow treated with removal of loose bodies had pain symptoms, with 61% showing subsequent osteoarthritic changes at the time of follow-up. Woodward and Bianco[23] as well as Tivnon et al.[5] showed that most of their patients treated with fragment removal by drilling were not able to return to their previous sports activities. Byrd and Jones[24] reported on ten adolescent baseball players with capitellar osteochondritis dissecans lesions treated with arthroscopic chondroplasty, abrasion arthroplasty, or loose body removal. Although all had good or excellent results at a mean follow-up of 3.9 years, only four of the ten could return to organized baseball. Shaughnessy and Bianco[25] reported that subsequent collapse and deformation of the capitellar cartilage occurred after fixation of the loose fragment with Kirschner wires. In addition, a closing wedge osteotomy of the capitellum for teenage baseball players with osteochondritis dissecans lesions led to minimal osteoarthritic changes in all seven patients at seven to twelve years postoperatively[26]. In our series of young athletes, mosaicplasty had better clinical outcomes and encouraging radiographic findings compared with these previous procedures.

To date, several authors have reported successful results after autologous osteochondral grafts for capitellar osteochondritis dissecans lesions (see Appendix)[10-14]. However, regarding sample size and follow-up interval, only one study, by Yamamoto et al.[14], is comparable with ours. They described osteochondral autograft transplantation for capitellar osteochondritis dissecans in eighteen juvenile baseball players who had a good outcome after a minimum of twenty-four months (mean, forty-five months)[14]. We previously reported that seven of eight patients in the current series had excellent or good clinical results according to the clinical rating system of Timmerman and Andrews[18] at a minimum of fourteen months (mean, twenty-four months)[11]. The results of the current midterm follow-up study are comparable with our short-term follow-up results, indicating that mosaicplasty can provide satisfactory outcomes for young athletes with advanced capitellar osteochondritis dissecans lesions.

A reasonable strategy for the treatment of osteochondritis dissecans lesions must be resurfacing with hyaline or hyaline-like cartilage that is supported by normal subchondral bone. Although the exact etiology of osteochondritis dissecans remains unclear, compression forces applied to the humeral capitellum by valgus stress to the elbow during throwing probably lead to the capitellar osteochondritis dissecans lesions[25,27]. To achieve a durable load-bearing joint against this stress, subchondral bone reconstruction that provides mechanical support for the articular surface should be considered. For this purpose, an osteochondral graft is an ideal option because it can simultaneously provide hyaline cartilage resurfacing and subchondral osseous support.

A considerable disadvantage in performing mosaicplasty is the potential adverse effect on donor sites. Particularly when grafts from a normal knee are transplanted into the elbow joint, donor site complications must be avoided. Our results suggest no unfavorable effect on the donor knee from harvesting the small grafts we used. There have been a few studies focusing on donor-site morbidity after mosaicplasty[28,29]. Reddy et al.[29] suggested that osteochondral harvest from normal knees for the treatment of talar osteochondral lesions led to a decline in knee function. Compared with their data, the patients in our study were younger and the size of osteochondral grafts was smaller. The difference between their results and ours could be attributed to these factors.

In terms of graft size selection, Ahmad et al.[30] showed that a donor site of 8 mm in diameter at the intercondylar notch was filled with fibrous tissue with material properties inferior to those of normal cartilage. We harvested osteochondral grafts from the superolateral periphery of the femoral condyle at the level of the patellofemoral joint. On the basis of a biomechanical study, Garretson et al.[17] recommended graft harvesting from the distal lateral femoral trochlea. On the other hand, a cadaver study by Simonian et al.[31] demonstrated substantial contact pressure in this area. It is still controversial which area of the patellofemoral articular surface is the best for harvesting osteochondral plugs. A longer duration of follow-up with a greater number of subjects will allow us to better understand the effects of graft size and harvest area on morbidity in donor knees.

There are some limitations to this study. First, the minimum follow-up period was two years. While the radiographic findings at the time of follow-up showed no evidence of osteoarthritic changes in the elbow, longer follow-up is needed to confirm this point. Second, neither arthroscopic second-look observation nor histological examination of the grafted areas was performed in this study. Therefore, we could not directly demonstrate hyaline repair of the osteochondritis dissecans lesions. Finally, this study did not include concurrent controls, and consequently we compared our results with unmatched results reported by previous authors.

From our encouraging clinical and radiographic results at a mean follow-up of four years, we may conclude that mosaicplasty is a very good option for treating advanced capitellar osteochondritis dissecans lesions in teenage athletes. On the basis of our results, the risk of doing a two-joint procedure appears to be minimal. Finally, the favorable results obtained by mosaicplasty can successfully return such patients to their competitive sports activities.

Appendix

eA Tables presenting details on all study patients, a summary of articles previously published on this subject, and the specifics of the International Cartilage Repair Society classification, the Timmerman and Andrews clinical rating system, and the magnetic resonance imaging scoring system of Roberts et al.

are available with the electronic versions of this article, on our web site at jbjs.org (go to the article citation and click on "Supplementary Material") and on our quarterly CD/DVD (call our subscription department, at 781-449-9780, to order the CD or DVD). ■

Norimasa Iwasaki, MD, PhD
Jyunichi Ishikawa, MD, PhD
Tatsuya Masuko, MD, PhD
Tadanao Funakoshi, MD, PhD
Akio Minami, MD, PhD
Department of Orthopaedic Surgery,
Hokkaido University School of Medicine,
Kita 15, Nishi 7, Sapporo 060-8638, Japan.
E-mail address for N. Iwasaki: niwasaki@med.hokudai.ac.jp

Hiroyuki Kato, MD, PhD
Department of Orthopaedic Surgery,
Shinsyu University School of Medicine,
Asahi 3-1-1, Matsumoto 390-8621, Japan

References

1. Bauer M, Jonsson K, Josefsson PO, Linden B. Osteochondritis dissecans of the elbow. A long-term follow-up study. Clin Orthop Relat Res. 1992;284:156-60.

2. McManama GB Jr, Micheli LJ, Berry MV, Sohn RS. The surgical treatment of osteochondritis of the capitellum. Am J Sports Med. 1985;13:11-21.

3. Takahara M, Ogino T, Sasaki I, Kato H, Minami A, Kaneda K. Long term outcome of osteochondritis dissecans of the humeral capitellum. Clin Orthop Relat Res. 1999;363:108-15.

4. Takahara M, Mura N, Sasaki J, Harada M, Ogino T. Classification, treatment, and outcome of osteochondritis dissecans of the humeral capitellum. J Bone Joint Surg Am. 2007;89:1205-14.

5. Tivnon MC, Anzel SH, Waugh TR. Surgical management of osteochondritis dissecans of the capitellum. Am J Sports Med. 1976;4:121-8.

6. Hangody L, Feczkó P, Bartha L, Bodó G, Kish G. Mosaicplasty for the treatment of articular defects of the knee and ankle. Clin Orthop Relat Res. 2001;391 Suppl:S328-36.

7. Hangody L, Füles P. Autologous osteochondral mosaicplasty for the treatment of full-thickness defects of weight-bearing joints. Ten years of experimental and clinical experience. J Bone Joint Surg Am. 2003;85 Suppl 2:25-32.

8. Hangody L, Ráthonyi GK, Duska Z, Vásárhelyi G, Füles P, Módis L. Autologous osteochondral mosaicplasty. Surgical technique. J Bone Joint Surg Am. 2004;86 Suppl 1:65-72.

9. Kodama N, Honjo M, Maki J, Hukuda S. Osteochondritis dissecans of the talus treated with the mosaicplasty technique: a case report. J Foot Ankle Surg. 2004;43:195-8.

10. Ansah P, Vogt S, Ueblacker P, Martinek V, Woertler K, Imhoff AB. Osteochondral transplantation to treat osteochondral lesions in the elbow. J Bone Joint Surg Am. 2007;89:2188-94.

11. Iwasaki N, Kato H, Ishikawa J, Saitoh S, Minami A. Autologous osteochondral mosaicplasty for capitellar osteochondritis dissecans in teenaged patients. Am J Sports Med. 2006;34:1233-9.

12. Shimada K, Yoshida T, Nakata K, Hamada M, Akita S. Reconstruction with an osteochondral autograft for advanced osteochondritis dissecans of the elbow. Clin Orthop Relat Res. 2005;435:140-7.

13. Tsuda E, Ishibashi Y, Sato H, Yamamoto Y, Toh S. Osteochondral autograft transplantation for osteochondritis dissecans of the capitellum in nonthrowing athletes. Arthroscopy. 2005;21:1270.

14. Yamamoto Y, Ishibashi Y, Tsuda E, Sato H, Toh S. Osteochondral autograft transplantation for osteochondritis dissecans of the elbow in juvenile baseball players: minimum 2-year follow-up. Am J Sports Med. 2006;34:714-20.

15. Minami M, Nakashita K, Ishii S, Usui M, Muramatsu I, Ogino T, Fukuda K, Sugawara M. Twenty-five cases of osteochondritis dissecans of the elbow. Rinsho Seikei Geka (Japan). 1979;14:805-10.

16. De Smet AA, Ilahi OA, Graf BK. Reassessment of the MR criteria for stability of osteochondritis dissecans in the knee and ankle. Skeletal Radiol. 1996;25:159-63.

17. Garretson RB 3rd, Katolik LI, Verma N, Beck PR, Bach BR, Cole BJ. Contact pressure at osteochondral donor sites in the patellofemoral joint. Am J Sports Med. 2004;32:967-74.

18. Timmerman LA, Andrews JR. Arthroscopic treatment of posttraumatic elbow pain and stiffness. Am J Sports Med. 1994;22:230-5.

19. Tegner Y, Lysholm J. Rating system in the evaluation of knee ligament injuries. Clin Orthop Relat Res. 1985;198:43-9.

20. Anderson AF. Rating scales. In: Fu FH, Harner CD, Vince KG, editors. Knee surgery. Baltimore: Williams and Wilkins; 1994. p 275-96.

21. Roberts S, McCall IW, Darby AJ, Menage J, Evans H, Harrison PE, Richardson JB. Autologous chondrocyte implantation for cartilage repair: monitoring its success by magnetic resonance imaging and histology. Arthritis Res Ther. 2003;5:R60-73.

22. International Cartilage Repair Society. ICRS Cartilage Injury Evaluation Package. 2000. http://www.cartilage.org/_files/contentmanagement/ICRS_evaluation.pdf.

23. Woodward AH, Bianco AJ Jr. Osteochondritis dissecans of the elbow. Clin Orthop Relat Res. 1975;110:35-41.

24. Byrd JW, Jones KS. Arthroscopic surgery for isolated capitellar osteochondritis dissecans in adolescent baseball players: minimum three-year follow-up. Am J Sports Med. 2002;30:474-8.

25. Shaughnessy WJ, Bianco AJ. Osteochondritis dissecans. In: Morrey BF, editor. The elbow and its disorders. 2nd ed. Philadelphia: WB Saunders; 1993. p 282-7.

26. Kiyoshige Y, Takagi M, Yuasa K, Hamasaki M. Closed-wedge osteotomy for osteochondritis dissecans of the capitellum. A 7- to 12-year follow-up. Am J Sports Med. 2000;28:534-7.

27. King JW, Brelsford HJ, Tullos HS. Analysis of the pitching arm of the professional baseball pitcher. Clin Orthop Relat Res. 1969;67:116-23.

28. Iwasaki N, Kato H, Kamishima T, Suenaga N, Minami A. Donor site evaluation after autologous osteochondral mosaicplasty for cartilaginous lesions of the elbow joint. Am J Sports Med. 2007;35:2096-100.

29. Reddy S, Pedowitz DI, Parekh SG, Sennett BJ, Okereke E. The morbidity associated with osteochondral harvest from asymptomatic knees for the treatment of osteochondral lesions of the talus. Am J Sports Med. 2007;35:80-5.

30. Ahmad CS, Guiney WB, Drinkwater CJ. Evaluation of donor site intrinsic healing response in autologous osteochondral grafting of the knee. Arthroscopy. 2002;18:95-8.

31. Simonian PT, Sussmann PS, Wickiewicz TL, Paletta GA, Warren RF. Contact pressures at osteochondral donor sites in the knee. Am J Sports Med. 1998;26:491-4.