HOKKAIDO UNIVERSITY

Title	Management for squamous cell carcinoma of the nasal cavity and ethmoid sinus : A single institution experience
Author(s)	Homma, Akihiro; Nakamaru, Yuji; Sakashita, Tomohiro; Onimaru, Rikiya; Terasaka, Shunsuke; Tsuchiya, Kazuhiko; Yoshida, Daisuke; Yasuda, Koichi; Hatakeyama, Hiromitsu; Furusawa, Jun; Mizumachi, Takatsugu; Kano, Satoshi; Shirato, Hiroki; Fukuda, Satoshi
Citation	Auris nasus larynx, 42(5), 377-381 https://doi.org/10.1016/j.anl.2015.02.005
Issue Date	2015-10
Doc URL	http://hdl.handle.net/2115/62918
Rights	© 2015. This manuscript version is made available under the CC-BY-NC-ND 4.0 license http://creativecommons.org/licenses/by-nc-nd/4.0/
Rights(URL)	http://creativecommons.org/licenses/by-nc-nd/4.0/
Type	article (author version)
File Information	manuscript.pdf

Instructions for use

Hokkaido University Collection of Scholarly and Academic Papers : HUSCAP

Management for squamous cell carcinoma of the nasal cavity and ethmoid sinus: a single institution experience

Akihiro Homma[1], Yuji Nakamaru[1], Tomohiro Sakashita[1], Rikiya Onimaru[2], Syunsuke Terasaka[3], Kazuhiko Tsuchiya[2], Daisuke Yoshida[2], Koichi Yasuda[2], Hiromitsu Hatakeyama[1], Jun Furusawa[1], Takatsugu Mizumachi[1], Satoshi Kano[1], Hiroki Shirato[2], Satoshi Fukuda[1]

[1] Department of Otolaryngology-Head & Neck Surgery, Hokkaido University Graduate School of Medicine, Kita 15, Nishi 7, Kita-ku, Sapporo 060-8638, Japan. Phone: +81-11-706-5958

[2] Department of Radiology, Hokkaido University Graduate School of Medicine, Sapporo, Japan

[3] Department of Neurosurgery, Hokkaido University Graduate School of Medicine, Sapporo, Japan

***Corresponding author:** Akihiro Homma

Department of Otolaryngology-Head & Neck Surgery, Hokkaido University Graduate School of Medicine, Kita 15, Nishi 7, Kita-ku, Sapporo 060-8638, Japan. Phone: +81-11-706-5958E-mail: ak-homma@med.hokudai.ac.jp

ABSTRACT

Objective: Here we report our experience of patients with squamous cell carcinoma (SCC) of the nasal cavity and ethmoid sinus (NC&ES) together with an analysis of treatment outcomes.

Methods: A retrospective analysis was performed using data from 25 consecutive patients treated between 2000 and 2012. Four patients were diagnosed with T1, 3 with T2, 4 with T3, 7 with T4a, and 7 with T4b disease. No patient had lymph node metastasis.

Results: Twelve patients were treated with surgery with/without radiotherapy and with/without chemotherapy. Of these, 4 underwent endoscopic surgery without an open approach and 3 required an anterior skull base approach. Thirteen were treated with radiotherapy; 1 with radiotherapy alone, and 4 and 8 with intravenous and intra-arterial chemotherapy, respectively. The 5-yr overall survival for T1-3, T4a, and T4b disease was 53.9%, 71.4%, and 29.0%, respectively. The 5-yr disease-specific survival for T1-3, T4a, and T4b disease was 74.1%, 71.4%, and 29.0%, respectively.

Conclusion: Our treatment policy for patients with SCC of NC&ES, which is basically follows the NCCN guideline, was considered to be appropriate. However, several points in terms of surgery and non-surgical approach remain to be solved through further research.

Key words: nasal cavity; ethmoid sinus; squamous cell carcinoma; surgery; endoscopic; radiation therapy; chemotherapy

Malignant tumors of the nasal cavity and ethmoid sinus (NC&ES) are rare neoplasms that constitute approximately 35% of all malignancies of the paranasal sinuses and nasal cavity in Japan [1], although lower rates are reported in Western countries. NC&ES fall into the same category of anatomic site and their stages are determined using the same criteria in the UICC classification.

The number of patients with malignant tumors of NC&ES treated at a single center is small. Therefore, some reports have included patients from several decades ago, and the time factor must have influence on pretreatment diagnosis and treatment outcome. Indeed, the application of endonasal endoscopic resection of NC&ES tumors has been increasing, and induction chemotherapy and concomitant chemoradiotherapy have been developed for head and neck cancers in recent times. In addition, there are many histological types of malignant tumors that develop in the paranasal sinuses and nasal cavity, such as squamous cell carcinoma (SCC), adenocarcinoma, adenoid cystic carcinoma, mucoepidermoid carcinoma, olfactory neuroblastoma, malignant melanoma, undifferentiated carcinoma, and so on. Therefore, there is a scarcity of prospectively collected data on the management options and outcomes because of the rarity of this disease [2]. The retrospective data collected to date also include data for different sites, such as the maxillary sinus, which accounts for over 50% of sinonasal malignancies, as well as data for many histological types. Therefore, it is difficult to know how to treat patients with tumors in a specific site and with a specific histology. In this study, we focused on SCC of the NC&ES, which is one of the major histological types of NC&ES.

The purpose of the present study was to report our experience with 25 consecutive

patients with SCC of the NC&ES after 2000, with an analysis of treatment outcomes.

MATERIALS AND METHODS

A retrospective analysis was performed on data from 25 consecutive patients with previously untreated SCC of NC&ES treated between January 2000 and December 2012 in Hokkaido University Hospital. One patient was excluded because he was treated with palliative intent due to his poor medical condition.

All patients were initially evaluated by a multidisciplinary team consisting of head and neck surgeons and radiation oncologists, and tumors were classified according to the 7th Edition of the Union for International Cancer Control (UICC) staging system published in 2009. Patients visiting our hospital before 2009 were restaged according to the UICC 7th edition. The stage of the tumor was determined on the basis of patient history, physical examination, chest x-rays, as well as computed tomography (CT) and/or magnetic resonance imaging (MRI). Approval for this study was obtained from the Institutional Review Board at Hokkaido University.

Treatment strategies

All cases were discussed by a multidisciplinary tumor board. All 25 patients were treated with curative intent. In accord with our institutional policy, limited disease (T1-2 N0) was treated by surgery or radiotherapy alone. Radiotherapy was recommended if adverse features, such as positive or close margins, were confirmed pathologically. Locally advanced and resectable disease was treated by a combination of surgery followed by

adjuvant radiotherapy or radiotherapy with intravenous (IV) or intra-arterial (IA) chemotherapy, and unresectable tumors were treated by radiotherapy with chemotherapy (IV or IA).

Statistical analysis

All patients were closely observed during the follow-up period, with the median follow-up period for surviving patients ranging from 1.5 to 14 years (median, 8.3 years).

In this study, the detailed anatomical sites in which the primary tumor developed were evaluated using CT and MR imaging. The primary tumor extension sites were classified according to the 7th UICC staging system and included the medial wall or floor of the orbit, maxillary sinus, palate, cribriform plate, anterior orbital contents, skin of the nose or cheek, minimal extension to the anterior cranial fossa, pterygoid plates, sphenoid or frontal sinuses, orbital apex, dura, brain, middle cranial fossa, cranial nerves other than V2, nasopharynx, and clivus.

The probability of overall survival was computed from the beginning of treatment to the time of death from any cause or the date of the last follow-up contact for surviving patients, and the probability of disease-specific survival was computed to death from disease or the date of last follow-up contact for surviving patients. They were calculated by the Kaplan-Meier method and compared using the log-rank test. Two-sided *P* values <0.05 were considered statistically significant. A prognostic analysis was performed to study the following variables: age, sex, and extension to the primary tumor extension sites. Statistical analysis was performed using JMP Pro 11.0.0 statistical software (SAS Institute, Cary, NC).

RESULTS

Patient Characteristics

Twenty-five patients were enrolled in this study. Patients consisted of 17 males and 8 females, with a median age of 65 years (range 25-81 years). Thirteen patients (52%) had tumors arising in the ethmoid sinus, and 12 (48%) in the nasal cavity. Four patients (16%) was diagnosed with T1, 3 (12%) with T2, 4 (16%) with T3, 7 (28%) with T4a, and 7 (28%) with T4b disease. No lymph node involvement was noted in any patients (Table 1). Inverted papillomas were found in surgical or biopsy specimens from 4 patients.

Treatment modalities

Treatment according to T stage is shown in Table 2. Twelve patients (48%) were treated with surgery. Of these, 4 (16%) were treated with surgery alone, 6 (24%) with surgery and postoperative radiotherapy, and 2 (8%) with induction chemotherapy, surgery, and postoperative radiotherapy. Thirteen patients (52%) underwent radiotherapy without surgery. Of these, one patient (4%) was treated with radiotherapy alone. Radiotherapy and concomitant intravenous chemotherapy (IV-CRT) were undertaken for 4 (16%), and 2 (8%) patients also received induction chemotherapy. Eight patients (32%) were treated with radiotherapy and concomitant intra-arterial chemotherapy (RADPLAT). The treatment protocol for IV-CRT and RADPLAT has been described elsewhere [3-6]. To summarize, RADPLAT consisted of superselective intra-arterial infusions of cisplatin (100–120 mg/m^2/week, 4 times) with simultaneous intravenous infusions of thiosulfate to neutralize

cisplatin toxicity and conventional radiotherapy (65-70 Gy). IV-CRT consisted of weekly cisplatin (40 mg/m^2) or carboplatin (AUC 1.5) together with radiotherapy (70Gy) over 7 weeks. Induction chemotherapy consisted of a combination of cisplatin, docetaxel, and 5-fluorouracil or of nedaplatin, docetaxel, and 5-fluorouracil.

Surgical approach according to T stage is shown in Table 3. Of the 12 patients who underwent surgery, 4 patients received endonasal endoscopic surgery without an open approach. A further two patients underwent tumor resection via a nasal-alar sulcus incision and endoscopic endoscopy to achieve a good view of the tumor and allow resection with an adequate margin as the tumors were located tangential to the external nares. One patient underwent tumor resection by a gingivobuccal approach with endoscopy. Two patients also underwent resection via lateral rhinotomy. All 9 of these patients presented with limited disease (T1–3) of the NC&ES. The remaining 3 patients with T4 disease were treated via an anterior skull base approach with an endonasal endoscopic approach and with/without a lateral rhinotomy approach. Reconstruction of the surgical defect of the anterior skull base using a pericranial flap was required in all 3 patients. The remaining 9 patients did not need reconstruction, and the postoperative course was uneventful in all 9 patients.

Overall Survival and Disease-specific Survival Rates

The 5-year overall survival and disease-specific survival rate calculated by the Kaplan-Meier method, was 52.3% and 59.9%, respectively (Figure 1). Seven patients died of primary site recurrence and 2 patients of distant metastasis without primary site recurrence. Two patients with T2 tumor died of other causes. The 5-yr overall survival for

T1-3, T4a, and T4b disease was 53.9%, 71.4%, and 29.0%, respectively. The 5-yr disease-specific survival for T1-3, T4a, and T4b disease was 74.1%, 71.4%, and 29.0%, respectively (Figure 2). Patients with T4b had a worse disease-specific survival rate than did those with T1-3 (p=0.0413).

Univariate Cox proportional hazards analysis revealed that the medial wall or floor of the orbit extension, pterygoid plate extension, and orbital apex extension were factors for OS (Table 4). However, they were not found to be independent factors for OS in the multivariate analysis. Age, sex, and extension to other anatomical sites were not factors for OS in the univariate analysis.

DISCUSSION

SCC is aggressive cancer, so surgery, by means of en bloc resection, was traditionally regarded as the ideal form of intervention. However, transoral resection has been becoming more popular for head and neck cancer, especially for oropharyngeal and laryngeal caner. Hinni et al. concluded that piecemeal removal of tumors with three-dimensional margin mapping using an operating microscope or rod telescope is safe from an oncologic standpoint, and reduces morbidity and length of hospital stay [7,8].

As for cancer of the NC&ES, en bloc resection is not often achieved even by lateral rhinotomy and/or an anterior skull base approach, and usually requires debulking or segmental resection. In addition, in large tumors such as T4 NC&ES, optimum visualization cannot necessarily be achieved without endoscopic assistance when trying to en bloc resection, even by an open approach. Further, recent advances in endoscopic

instruments have allowed multi-angled and magnified views of the tumor limits, facilitating tumor resection [9].Therefore, several patients who underwent surgery through an open approach early in this study might have undergone an endonasal endoscopic approach if treated more recently. Under these circumstances, we should no longer stick with en bloc resection, but should seek to achieve negative margins with a good view regardless of whether an open or endonasal endoscopic approach is used.

Reconstruction of skull base defects has become controversial since an endonasal endoscopic approach was introduced for the treatment of skull base tumors, as patients with locally advanced SCC of NC&ES usually require postoperative radiotherapy and secure cranionasal separation is necessary to prevent postoperative complications such as cerebrospinal fluid leakage and meningitis. Postoperative complications often result in delays in the commencement of postoperative radiation therapy. In addition, the flap which separates the cranial cavity from the sinonasal tract has to be strong enough to tolerate postoperative radiotherapy. For this reason, a vascularized pericranial flap is more reliable than free grafting. Pedicled flaps using the mucosa of the nasal cavity, such as a Hadad-Bassagasteguy flap and pedicled inferior turbinate flap, are available for use with modestly sized tumors and are a suitable option for cases with minimal skull base defects. However, in locally advanced SCCs of NC&ES, the mucosa used in the formation of such flaps is often removed with the cancer. And in large defects of the skull base, larger flaps are needed. In such situations, a pericranial flap is suitable. Indeed, 3 patients who underwent anterior skull base resection, received reconstruction using pericranial flaps as the defects were large and pedicled flaps using the mucosa of the nasal cavity were

unavailable.

CRT has received little attention with regard to the treatment of sininasal cancer [10]. In this study, CRT without NAC was applied in 2 patients, but failed. NAC followed by CRT was also performed for 2 patients, one of whom remains alive without disease to date. Hanna et al. reported that NAC is a promising technique that may improve treatment outcomes for patients with SCC of the paranasal sinuses [11], and NAC followed by CRT is also considered to be an option for locally advanced NC&ES.

We previously reported the efficacy of RADPLAT for the treatment of tumors in the nasal cavity and the paranasal sinus [3]. However, we did not focus on SCC of the NC&ES in that study. As we previously reported, RADPLAT is considered to be effective for the treatment of patients with locally advanced SCC of the nasal vestibule, with excellent cosmetic results reported [5]. As for NC&ES, tumors are expected to be mainly supplied by the external carotid system, but also partially supplied by the internal carotid system, such as the anterior and posterior ethmoid arteries, particularly when the tumors arise from ethmoid sinus. However, the external carotid system provided the main supply to the tumor in most cases. We have infused cisplatin into the external carotid system, but not into the internal carotid system to avoid CNS and optic complications (Figure 3). As a result, cisplatin was infused from the internal maxillary artery in all 8 patients, the facial artery in 3 patients, and the transverse facial artery in 2 patients. In the remaining patient with T4a ethmoid cancer, angiography revealed that the tumor was not supplied by the external carotid system at all. Therefore, RADPLAT was not indicated in this case, and the patient received IV-CRT. Acute toxicity (≥grade III) was observed in only 2 of 8 patients (25%),

both of whom experienced nausea/vomiting (grade III). With regard to late adverse reactions, brain necrosis (grade II) was observed in one patient. Three patients experienced ocular/visual problems (grade III to IV), but all of them were required orbital exenteration if surgery were indicated. Although ocular/visual problems were observed in patients with tumors invading the orbit, the primary disease was successfully controlled by RADPLAT in 7 of 8 patients. Therefore, RADPLAT is a sound option for T4 NC&ES.

Generally, in sinonasal malignancies, the prognosis is worse for SCCs than for adenocarcinomas. Further, primary tumors of the maxillary sinus have a better prognosis than those of the ethmoid sinus [12,13]. Although there have been no reports focusing on SCCs of NC&ES, Dulguerov et al. reported that the 5-year actuarial specific survival rate of patients with SCC of the nasal and paranasal sinus treated between 1975 and 1994 was 60% [13]. Cantu et al. reported that in 33 cases of SCC of the ethmoid sinus treated between 1968 and 2003, the 5-yr overall survival was 18.7% [12]. In this study, despite 14 out of 25 patients having T4 disease, the 5-yr overall survival was 52.3%, although it might be inappropriate to compare our results with those of the previous studies.

Limited disease (T1-2) should be treated by surgery, if the surgical margin is close or positive and postoperative radiotherapy is indicated. Locally advanced and resectable disease (T3-T4a) should be treated by a combination of surgery followed by adjuvant radiotherapy or radiotherapy with chemotherapy. Unresectable tumors (T4b) or patients who refuse surgery should be treated by radiotherapy with chemotherapy. RADPLAT is another option for the treatment of these patients. Although RADPLAT is not mentioned in the NCCN guidelines, we consider it to be one of the chemoradiotherapy regimens. As to

surgical approach, the most important thing is the achievement of negative margins with a good view regardless of whether an open or endonasal endoscopic approach is used. However, to improve the survival and quality of life after therapy, the indication of endoscopic endonasal surgery without an open approach and the means by which skull base defects are reconstructed need to to be resolved. In addition, further is needed to develop non-surgical approaches for advanced disease, such as induction chemotherapy, RADPLAT.

ACKNOWLEDGMENTS

This study was supported in part by a Health and Labour Sciences Research Grant for Clinical Cancer Research (H26-141) from the Ministry of Health, Labour and Welfare of Japan, the National Cancer Center Research and Development Fund (26-A-4) of Japan, and a Grant-in-Aid for Scientific Research (C) (KAKENHI 24592587) from the Ministry of Education, Culture, Sports, Science, and Technology of Japan.

CONFLICT OF INTEREST

All the authors hereby declare that they have no conflict of interest.

REFERENCES

[1] Japan society for head and neck cancer, Cancer registry committee. Report of head and neck cancer registry of Japan clinical statistics of registered patients, 2011. Jpn J Head Neck Cancer 2013;39: supplement. http://www.jshnc.umin.ne.jp/pdf/2011syourei_houkoku.pdf

[2] Waldron J, Witterick I. Paranasal sinus cancer: caveats and controversies. World J Surg 2003;27:849-855.

[3] Homma A, Oridate N, Suzuki F, Taki S, Asano T, Yoshida D, et al. Superselective high-dose cisplatin infusion with concomitant radiotherapy in patients with advanced cancer of the nasal cavity and paranasal sinuses: a single institution experience. Cancer 2009;115:4705-14.

[4] Homma A, Inamura N, Oridate N, Suzuki S, Hatakeyama H, Mizumachi T, et al. Concomitant weekly Cisplatin and radiotherapy for head and neck cancer. Jpn J Clin Oncol 2011;41: 980-6.

[5] Homma A, Suzuki F, Hatakeyama H, Sakashita T, Yoshida D, Tsuchiya K, et al. Rapid superselective high-dose cisplatin infusion with concomitant radiotherapy for squamous cell carcinoma of the nasal vestibule: a report of two cases. Int Canc Conf J 2012;1:215-9.

[6] Homma A, Sakashita T, Yoshida D, Onimaru R, Tsuchiya K, Suzuki F, et al. Superselective intra-arterial cisplatin infusion and concomitant radiotherapy for maxillary sinus cancer. Br J Cancer 2013;109:2980-6.

[7] Hinni ML, Salassa JR, Grant DG, Pearson BW, Hayden RE, Martin A, et al. Transoral laser microsurgery for advanced laryngeal cancer. Arch Otolaryngol Head Neck Surg 2007;133:1198-204.

[8] Hinni ML, Zarka MA, Hoxworth JM. Margin mapping in transoral surgery for head and neck cancer. Laryngoscope 2013;123:1190-98.

[9] Robinson S, Patel N, Wormald PJ. Endoscopic management of benign tumors extending into the infratemporal fossa: a two-surgeon transnasal approach. Laryngoscope 2005;115:1818-22.

[10] Robbins KT, Ferlito A, Silver CE, Takes RP, Strojan P, Snyderman CH, et al. Contemporary management of sinonasal cancer. Head Neck 2011;33:1352-65.

[11] Hanna EY, Cardenas AD, DeMonte F, Roberts D, Kupferman M, Weber R, et al. Induction chemotherapy for advanced squamous cell carcinoma of the paranasal sinuses. Arch Otolaryngol Head Neck Surg 2011;137:78-81.

[12] Cantu G, Bimbi G, Miceli R, Mariani L, Colombo S, Riccio S, et al. Lymph node metastases in malignant tumors of the paranasal sinuses: prognostic value and treatment. Arch Otolaryngol Head Neck Surg 2008;134:170-7.

[13] Dulguerov P, Jacobsen MS, Allal AS, Lehmann W, Calcaterra T. Nasal and paranasal sinus carcinoma: are we making progress? A series of 220 palients and a systemic review. Cancer 2001;92:3012-29.

Table 1. Patient characteristics (n=25)

		Number of patients
Age		
	Range	25-81
	Median	65
	Average	61.8
Gender		
	Male	17
	Female	8
Primary tumr site		
	nasal cavity	12
	ethmoid sinus	13
T stage		
	1	4
	2	3
	3	4
	4a	7
	4b	7
N stage		
	0	25

Table 2. Treatment according to T stage (n=25)

T (n)	treatment	n	outcome
T1 (4)	Surg	2	2:NED
	Surg, RT	1	2:NED
	RT	1	1:DOD(P)
T2 (3)	Surg, RT	2	2:DOC
	Surg	1	1:NED
T3 (4)	Surg, RT	1	1:NED
	CT, Surg, RT	1	1:NED
	Surg	1	1:DOD(P)
	RADPLAT	1	1:NED
T4a (7)	Surg, RT	1	1:NED
	CT, Surg, RT	1	1:DOD(D)
	CRT	1	1:DOD(P)
	RADPLAT	4	4:NED
T4b (7)	Surg, RT	1	1:DOD(P)
	CRT	1	1:DOD(P)
	CT, CRT	2	1:NED, 1:DOD(P)
	RADPLAT	3	1:NED, 1:DOD(P), 1:DOD(D)

Abbreviations: Surg=surgery; RT=radiotherapy; CT=chemotherapy; RADPLAT=radiotherapy with intra-arterial chemotherapy; IV-CRT=radiotherapy with intravenous chemotherapy, NED=no evidence of disease, DOD=dead of disease, DOC=dead of other cause, DOC=dead of other cause, P=primary disease, D=distant disease

Table 3. Surgical approach according to T stage (n=12)

	T1-2	T3	T4	Total
EE	3	1		4
EE+GB		1		1
EE+NAS	2			2
EE+SB			2	2
EE+SB+LR			1	1
LR	1	1		2
Total	6	3	3	12

Abbreviations: EE=endoscopic endonasal approach, GB=gingivobuccal approach, NAS=nasal-alar sulcus incision, SB=skull base approach, LR=lateral rhinotomy

Table 4. Univariate Cox proportional hazards analysis of 25 SCC-NC&ES patients.

Variable		Score	No. of patients	HR	95%CI	P-value
Medial wall or floor of the orbit extension						
	No	0	15	0.28	0.07-0.93	0.038
	Yes	1	10			
Pterygoid plates extension						
	No	0	23	0.03	<0.01-0.29	0.001
	Yes	1	2			
Orbital apex extension						
	No	0	21	0.1	0.03-0.41	0.003
	Yes	1	4			

Abbreviations: HR=hazard ratio; CI=confidence interval

Figure captions

Figure 1. Overall surivival and disease-free survival rate for all patients (n=25).

Figure 2. Disease-specific survival rate according to T classification.

Figure 3. MRI findings from a 57-year-old man with a right ethmoid sinus cancer that was classified as T4aN0M0 are shown (a). Lateral subtraction angiograms of the right internal maxillary artery (b), right facial artery (c), and right internal carotid artery (d) are shown. These indicated that the tumor was covered by not only the external carotid system (the internal maxillary and facial arteries) but also the internal carotid system. Cisplatin was infused from the external carotid system alone. However, the patient is currently alive without disease after 11 years of follow up.

Figure 1

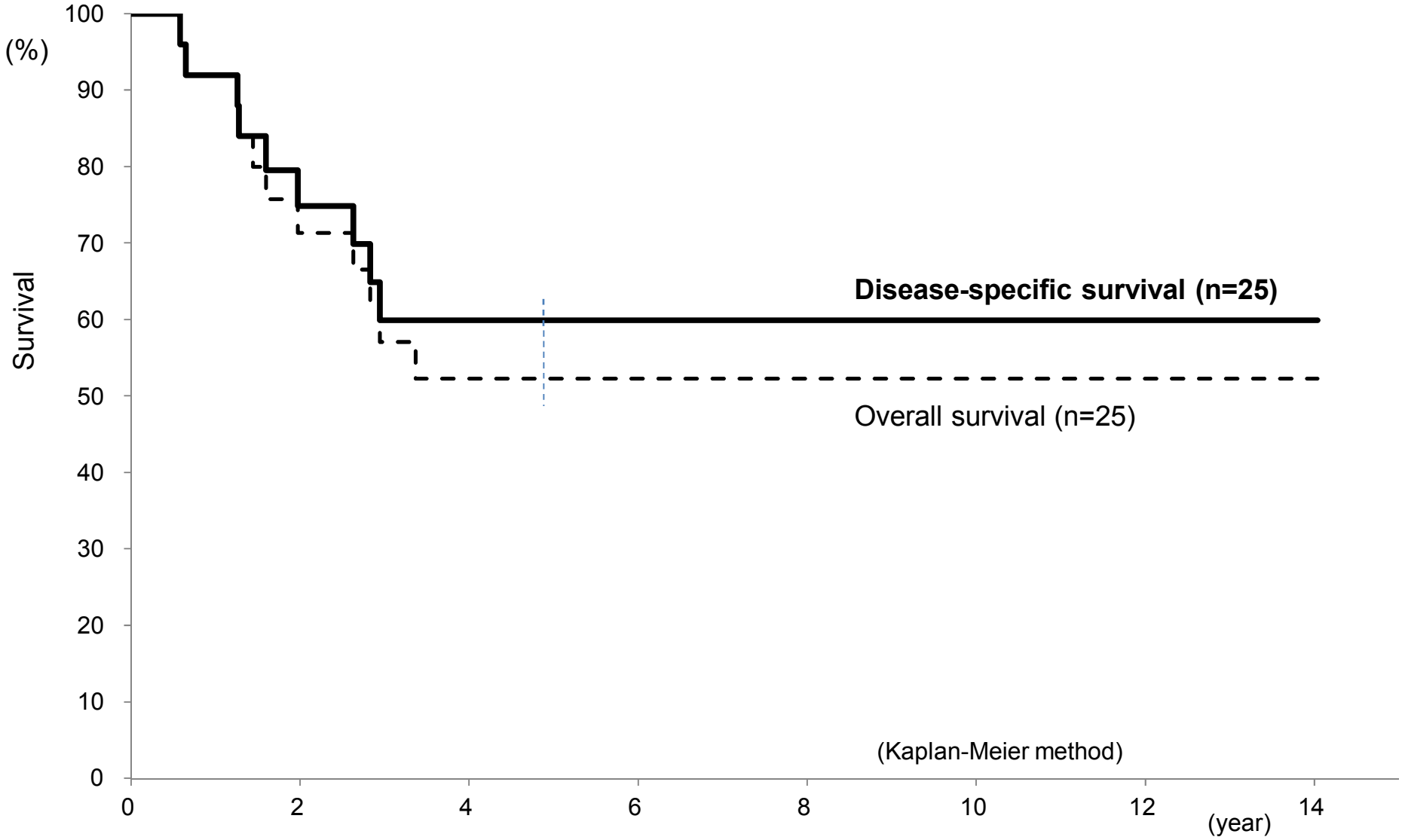

Patients at risk

OS	25	16	9	4
DSS	25	16	9	4

Figure 2

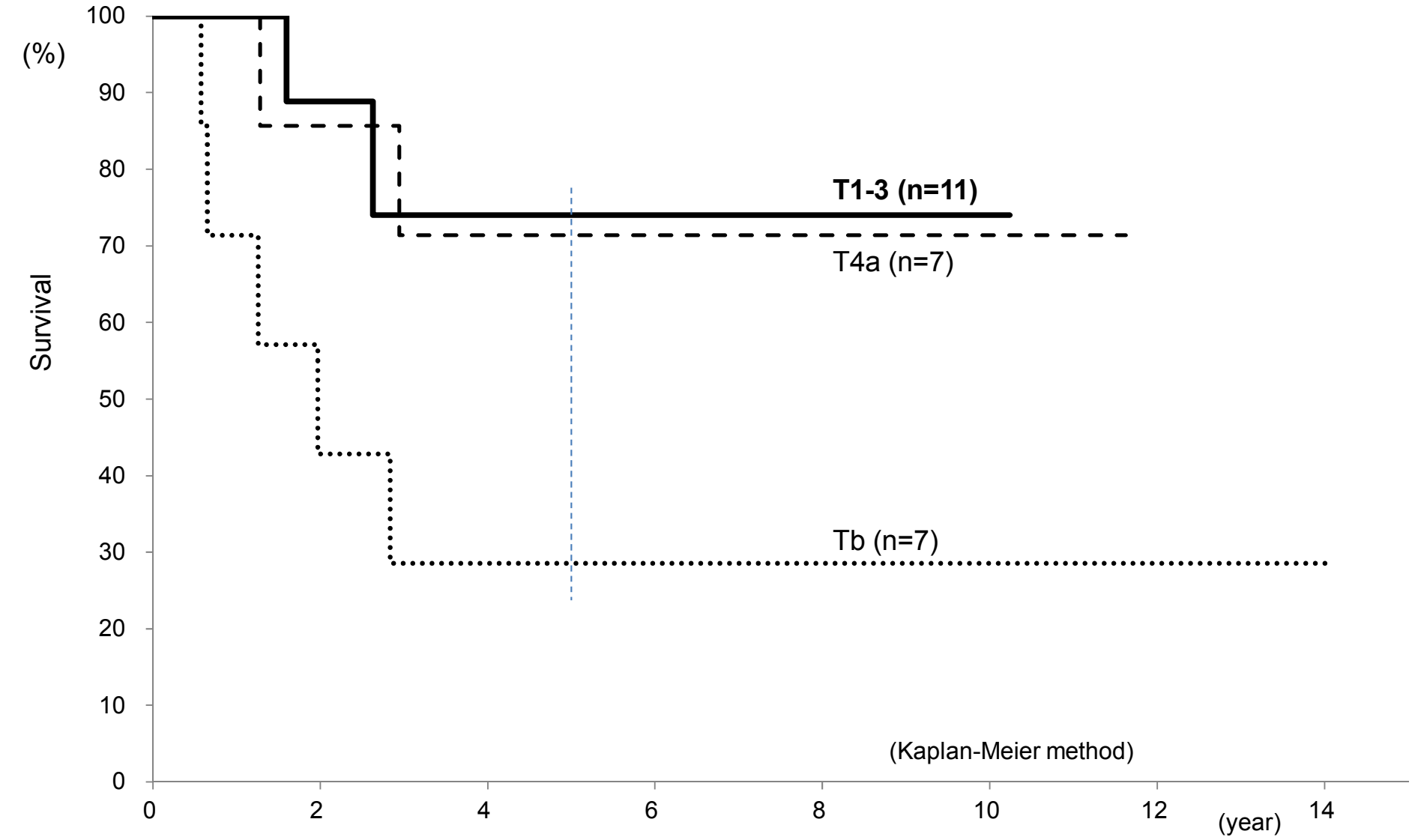

Patients at risk

T1-3	11	7	3	1
T4a	7	6	5	2
T4b	7	3	1	1
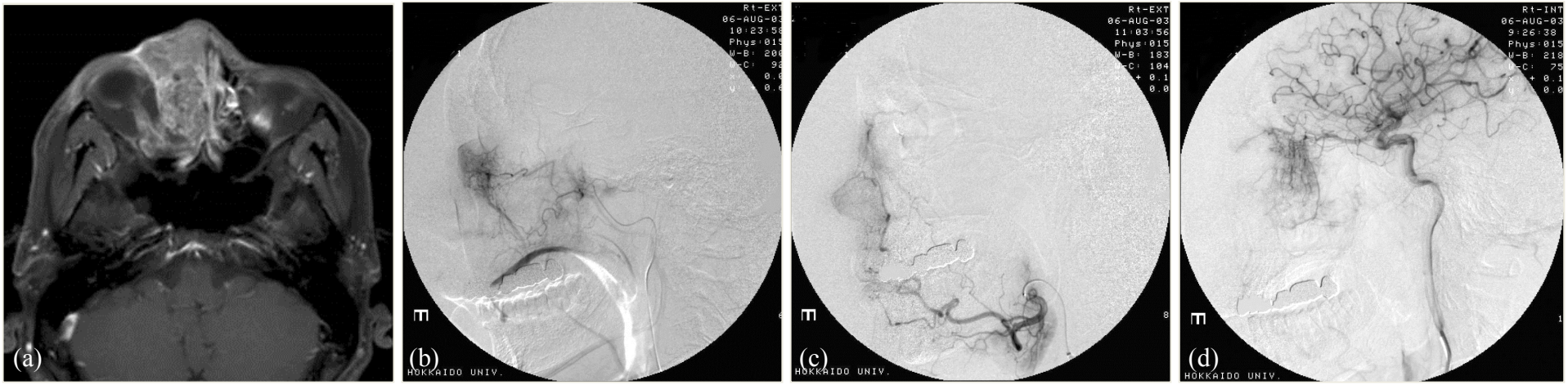
Figure 3