



Title	Secondary medulla oblongata involvement following middle cervical spinal cord injury associated with latent traumatic instability in a patient with ossification of the posterior longitudinal ligament
Author(s)	Sudo, Hideki; Taneichi, H.; Kaneda, K.
Citation	Spinal Cord, 44(2), 126-129 https://doi.org/10.1038/sj.sc.3101803
Issue Date	2006-02
Doc URL	http://hdl.handle.net/2115/14578
Rights	Nature Publishing Group, Spinal Cord, vol. 44-2, 2006, 126-129
Type	article
File Information	SC.pdf



[Instructions for use](#)

Secondary Medulla Oblongata Involvement Following Middle Cervical Spinal Cord Injury Associated with Latent Traumatic Instability in a Patient with Ossification of the Posterior Longitudinal Ligament

Hideki Sudo, MD*[†]

Hiroshi Taneichi, MD*

Kiyoshi Kaneda, MD*

*Center for Spinal Disorders and Injuries, Bibai Rosai Hospital, Bibai, Japan; and

†Department of Orthopaedic Surgery, Hokkaido University Graduate School of Medicine, Sapporo, Japan

Correspondence;

Hideki Sudo, MD

Department of Orthopaedic Surgery

Hokkaido University Graduate School of Medicine

North-15, West-7, Kita-ku, Sapporo, Hokkaido 060-8638, Japan

Phone: +81-11-706-5934 FAX: +81-11-706-6054

E-mail: hidekisudo@yahoo.co.jp

Keywords; cervical spinal cord injury; deteriorative change; medulla oblongata; ossification of the posterior longitudinal ligament

Running Title; Latent Spinal Instability

Abstract

Study Design: Case report describing a rare case with secondary deteriorated medulla oblongata lesion following middle cervical spinal cord injury.

Objectives: It is debatable whether tetraplegic patients with no radiological evidence of structural spinal injury should be treated surgically or conservatively. However, some of patients may actually have latent structural instability, which may cause secondary neurological deterioration. Therefore, it is important that such latent instability should be promptly detected with a high index of suspicion in the acute phase of injury.

Setting: Center for Spinal Disorders and Injuries, Bibai Rosai Hospital, Japan

Methods: A 68-year-old man with ossification of the posterior longitudinal ligament (OPLL) had sustained tetraplegia after a fall. Initially, the patient was diagnosed with an acute spinal cord injury at C4-5 without radiological abnormalities and treated conservatively. Seven hours after the injury, the patient had an ascending neurological deficit, which required respiratory assistance. Magnetic resonance imaging revealed a marked swelling of the spinal cord above C4-5 to the medulla oblongata.

Results: Retrospective radiological assessment revealed that the spine had been unstable at the injured level because of discontinuity of both anterior and

posterior longitudinal ligament and signal intensity change in the retropharyngeal space into the C4-5 intervertebral disc. The injured segment was highly vulnerable to post-injury dynamic stenosis and easily sustained secondary neural damage.

Conclusion: This case report suggests that careful radiological assessment of latent structural instability is required in patients with OPLL in order to prevent deteriorative change of the spinal cord.

Keywords: cervical spinal cord injury; deteriorative change; medulla oblongata; ossification of the posterior longitudinal ligament

Introduction

It has been documented that secondary neurologic deterioration after cervical spinal cord injury (CSCI) is one of the most severe problems that may affect a patient's management and prognosis.^{1,2} Such adverse consequences following spinal cord injury are described as a progressive cephalad ascent of sensory loss and worsening of motor function above the level of the initial injury.

Although the mechanism of the deterioration is still unclear, it has been pointed out that the structural instability of the injured segment is one of the most important factors affecting the detrimental changes.³ The surgical decompression and fixation of the cervical spine is the recommended treatment in a patient with structural damage, such as a fracture-dislocation.³ On the other hand, it is debatable whether tetraplegic patients with no radiological evidence of structural spinal injury should be treated surgically or conservatively. However, some of patients may actually have latent structural instability, which may cause secondary neurological deterioration. Therefore, it is important that such latent instability should be promptly detected with a high index of suspicion in the acute management phase of CSCI.⁴

Here, the authors have documented an unusual case, where secondary detrimental changes in the medulla oblongata following middle CSCI occurred

in a patient with ossification of the posterior longitudinal ligament (OPLL)
because of latent instability was not initially detected.

Case Report

A 68-year-old man fell to the ground and sustained complete tetraplegia. Two hours later, the patient was found and admitted to a tertiary-care facility. The clinical parameters presented the normal range of the heart rate, blood pressure, and respiratory rate. Although the patient escaped from brain, thoracic and abdominal injuries, his neurological status was complete tetraplegia of C4. Plain x-ray, CT and sagittal reformatted CT showed spinal canal stenosis due to OPLL (Figure 1). Although T1-weighted magnetic resonance imaging (MRI) did not demonstrate any signal changes in the spinal cord, the T2-weighted image showed a low signal intensity area at the C4-5 level, which indicated intramedullary hemorrhage⁵ (Figure 2A and B). T2-weighted MRI also showed a high signal intensity area in the retropharyngeal space into the C4-5 intervertebral disc. This indicated that structural damage of the cervical spine associated with hyperextension injury existed at the gap of the OPLL. However, no structural spinal injury was radiographically detected in the tertiary-care facility. Therefore, the patient was diagnosed as acute spinal cord injury without radiological abnormalities at that time. The patient was treated conservatively without any clinical awareness of the hidden instability. A Philadelphia collar was used but skull traction was not performed. Intravenous methylprednisolone

was administered according to the recommended NASCIS-2 (National Acute Spinal Cord Injury Study) protocol.⁶

Seven hours after the initial injury, the patient experienced increased dyspnea and transient loss of consciousness. Arterial blood gas analysis revealed hypoxemia and hypercapnea. Then, the patient was intubated and put on a ventilator due to neurogenic respiratory arrest. When the patient regained consciousness, neurological status changed into complete respiratory tetraplegia with neurological dysfunction at the level of C2. The patient presented with a normal sensory condition of the face, a sense of taste, and swallowing function. Neurological examination revealed normal function of the cranial nerves.

Despite normal cervical alignment, MRI at the onset of acute respiratory arrest showed a marked swelling of the spinal cord above C2-3 to the medulla oblongata. T1-weighted MRI showed high signal intensity in the spinal cord from C4 to C2. T2-weighted MRI demonstrated diffuse heterogeneous high signal intensity within the spinal cord from C4 to the medulla oblongata. These findings indicated that spinal cord edema and intramedullary hemorrhage extend cranially from the C4-5 level⁵ (Figure 3A and B).

The patient was referred to our institute 4 weeks after injury. He was managed conservatively because surgical intervention at such a late stage, after neural damage had already been established, would provide little chance of

neurological improvement. Furthermore, the patient and his family did not elect for surgery to be performed.

MRI obtained 3 month after injury showed that gliosis extended from the medulla oblongata to middle part of the cervical spinal cord, which exhibited an uniform signal intensity on the T1-weighted image but a high signal intensity on the T2-weighted image (Figure 4A and B). Moreover, hypertrophy of the ligamentum flavum was observed at C4-5 segment. This finding proved that there was an undetected instability at C4-5 segment, which led to secondary deterioration of the injured spinal cord.

Discussion

The incidence of neurological deterioration from spinal injury was reported to be from 1.84 to 5.8%.^{1,2} Many basic reports have documented that hemorrhage, microvascular infarction, spasm, spinal cord edema, and free radical production are all relevant factors in this serious condition.^{7,8}

Clinically, Lu et al⁹ reported the predictable risk factors for delayed apnea following middle to lower CSCI as the presence of diffuse and extensive cord lesions, respiratory distress, and bradycardia. In this case, however, a spinal cord lesion was initially localized at C4-5 segment and cardiopulmonary functions were normal.

The most important point regarding initial management of this case was that the patient was managed as one with a stable injury that did not require surgical decompression and stabilization. In this case, mechanical instability existed in the interrupted portion of OPLL (C4/5 segment) was not correctly diagnosed. When mechanical instability exists at the gap of the OPLL, mechanical stress to the spinal cord following initial trauma may be focused on the same site. Consequently, secondary spinal cord injury often aggravates this neurological condition. If the patient had been identified earlier as having any cervical instability and managed by surgical decompression and stabilization, the

neurological deterioration might have been prevented.^{3,4} Because CSCI without osteoligamentous damage is quite common in the elderly population with degenerative spinal stenosis including OPLL, CSCI with spinal stenosis tends to be managed as stable injury without detailed radiological evaluation. Therefore, it is important to find any latent mechanical instability on MRI and to perform adequate management by surgical decompression with or without fusion in the acute phase of injury.⁴

Both ankylosing spondylitis (AS) and diffuse idiopathic skeletal hyperostosis are well-known predictive risk factors for neurological deterioration.^{10,11} Bohlman¹² reported that 50 % of identified AS patients had a delay in the diagnosis of cervical spine structural injury and all of them subsequently develop secondary neurological deterioration. Reid et al¹³ documented a high incidence of neurological deterioration due to this delayed diagnosis. In this case, all cervical spinal segments except C4-5 were fused by ossification of both anterior and posterior longitudinal ligaments. Therefore, applied force to the cervical spine would be concentrated on C4-5 segment in a similar situation of a fractured ankylosing spine. Therefore, C4-5 segment of the spinal cord was highly vulnerable to post-injury dynamic stenosis and easily sustained secondary neural damage.

The clinical manifestations of patients with the medulla oblongata injuries are unclear because such patients rarely survive. This is the first clinical case report describing the deterioration of the ascending medulla oblongata following middle CSCI. In a neuropathological examination at autopsy, Ito et al¹⁴ revealed longitudinal spreading of cord lesions upward to the medulla oblongata in one of eight patients who died after traumatic CSCI. They also documented that there was a completely necrotic lesion without cell reaction in several cord segments as well as the initially damaged lesion. They suggested that the spreading of the lesion might be induced by increased intramedullary pressure that resulted from an intra- and extramedullary circulatory disturbance. In the authors' case, critical instability of C4-5 segment associated with severe spinal stenosis caused by OPLL could lead to acute increased intramedullary pressure, which allowed the extension of the spinal cord lesion.

The patient escaped from cranial nerve damage in spite of medulla oblongata involvement. This may be explained because the involved lesion was located only in the relatively inferior portion of the medulla oblongata that does not contain the cranial nerve nuclei but only the spinal trigeminal nuclei. In addition, there were discrepancies between the neurological status and the MRI findings. Therefore, the apnea was not necessarily the result of the secondary involvement of the medulla oblongata, it might simply be the result of the

involvement of C4 segment in which the center of phrenic nerves are located.

Two years after injury, this patient is still alive with ventilator support.

References

1. Famer J, Vaccaro A, Albert TJ, et al. Neurologic deterioration after cervical spinal cord injury. *J Spinal Disord.* 1998;**11**:192-196.
2. Marshall LF, Knowlton S, Garfin SR. Deterioration following spinal cord injury: A multicenter study. *J Neurosurg.* 1987;**66**:400-404.
3. Mahale YJ, Silver JR. Progressive paralysis after bilateral facet dislocation of the cervical spine. *J Bone Joint Surg [Br].* 1992;**74**:219-23.
4. Benzel EC, Hart BL, Ball PA, et al. Magnetic resonance imaging for the evaluation of patients with occult cervical spine injury. *J Neurosurg.* 1996;**85**:824–829.
5. Flanders AE, Schaefer DM, Doan HT, et al. Acute Cervical Spine Trauma: Correlation of MR Imaging Findings with Degree of Neurologic Deficit. *Neuroradiology.* 1990;**177**:25-33.
6. Bracken MB, Shepard MJ, Collins WF, et al. A randomized controlled trial of methylprednisolone or naloxone in the treatment of acute spinal-cord injury. Results of the Second National Acute Spinal Cord Injury Study. *N Engl J Med.* 1990;**322**:1405-1411.
7. Banick N, Hogan E, Hsu C. The multimolecular cascade of spinal cord injury. *Neurochem Pathol.* 1987;**7**:57–77.

8. Tator CH, Fehlings MG. Review of the secondary injury theory of acute spinal cord trauma with emphasis on vascular mechanisms. *J Neurosurg.* 1991;**75**:15–26.
9. Lu k, Lee TC, Liang CL, et al. Delayed apnea in patients with mid-to lower cervical spinal cord injury. *Spine.* 2000;**25**:1332-1338.
10. Fox MW, Onofrio BM, Kilgore JE. Neurological complications of ankylosing spondylitis. *J Neurosurg.* 1993;**78**:871-878.
11. Paley D, Schwartz M, Cooper P, et al. Fractures of the spine in diffuse idiopathic skeletal hyperostosis. *Clin Orthop.* 1991;**267**:22-32.
12. Bohlman HH. Acute fractures and dislocations of the cervical spine. *J Bone Joint Surg [Am].* 1979;**61**:1119-1142.
13. Reid DC, Henderson R, Saboe L, et al. Etiology and clinical course of missed spine fractures. *J Trauma.* 1987; **27**:980-986.
14. Ito T, Oyanagi K, Wakabayashi K, et al. Traumatic spinal cord injury: a neuropathological study on the longitudinal spreading of the lesions. *Acta Neuropathol (Berl).* 1997; **93**:13-18.

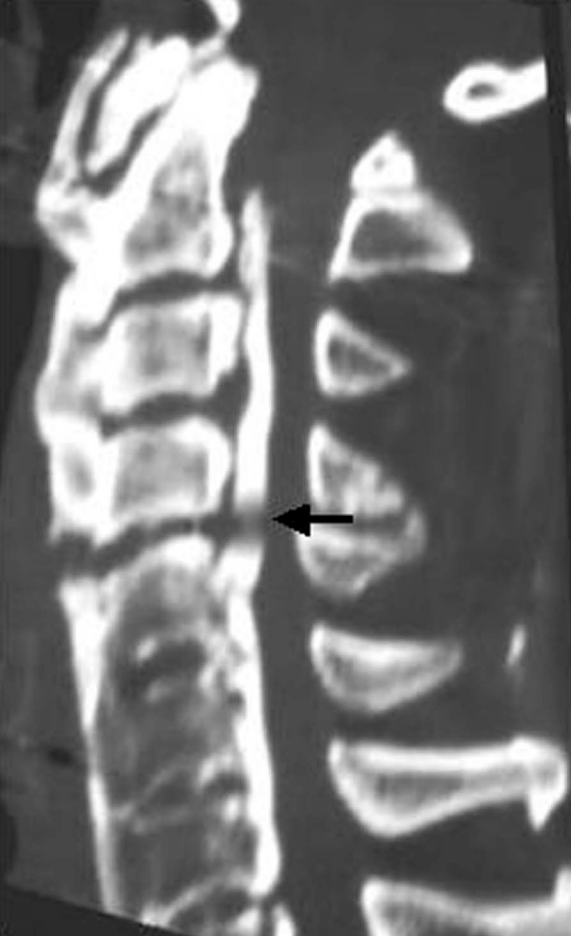Legends

Figure 1. Reformatted CT revealing spinal canal stenosis accompanied with OPLL at the initial injury.

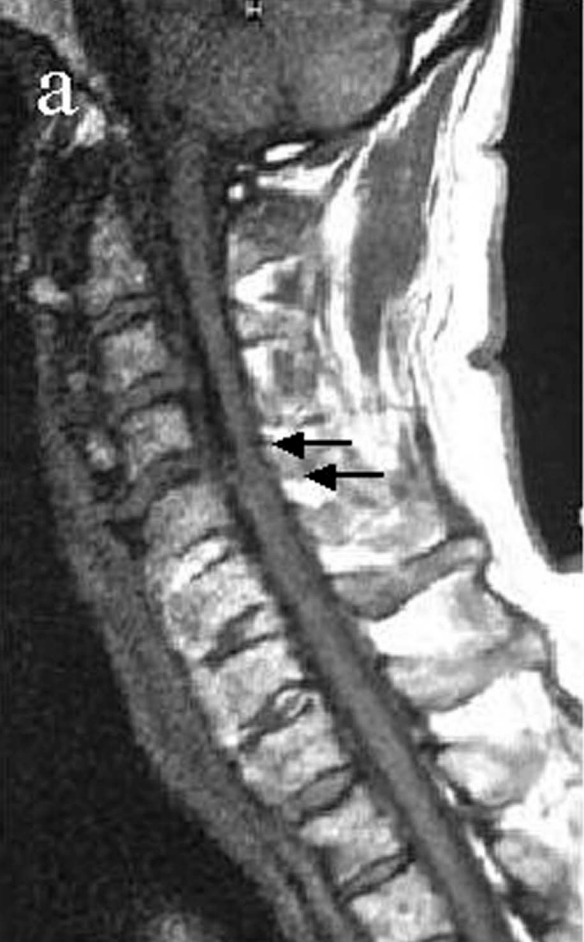Figure 2 A and B. MRI of the initial injury demonstrated the iso signal intensity in the cord on the T1-weighted image (2A) and the low signal characteristics on the T2-weighted image at the C4-5 (2B, black arrows). No structural injuries were initially identified, however, retrospective MRI assessment revealed the high signal intensity area in the anterior aspect of the C4-5 on T2-weighted image (2B,white arrows), which indicated structural instability at the site.

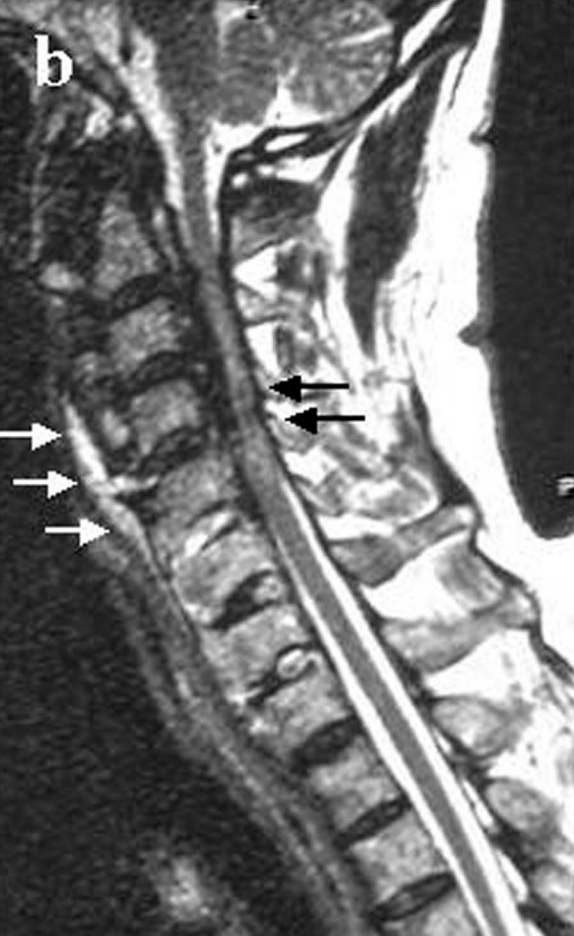Figure 3A and B. MRI at the onset of acute respiratory arrest showed a marked swelling of the spinal cord above C2-3 to the medulla oblongata (arrows). T1-weighted image showed high signal intensity in the cord from C4 to C2 (3A). T2-weighted image revealed diffuse heterogeneous high signal intensity in the cord from C4 to the medulla oblongata (3B).

Figure 4A and B. MRI performed 3 months after the injury showed extensive gliosis from the inferior medulla oblongata to all section of cervical spinal cord. Moreover, it revealed hypertrophic change of the ligamentum flavum at C4-5 indicating structural instability at this site (arrow).



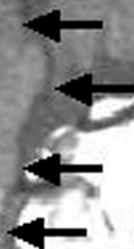
a





b

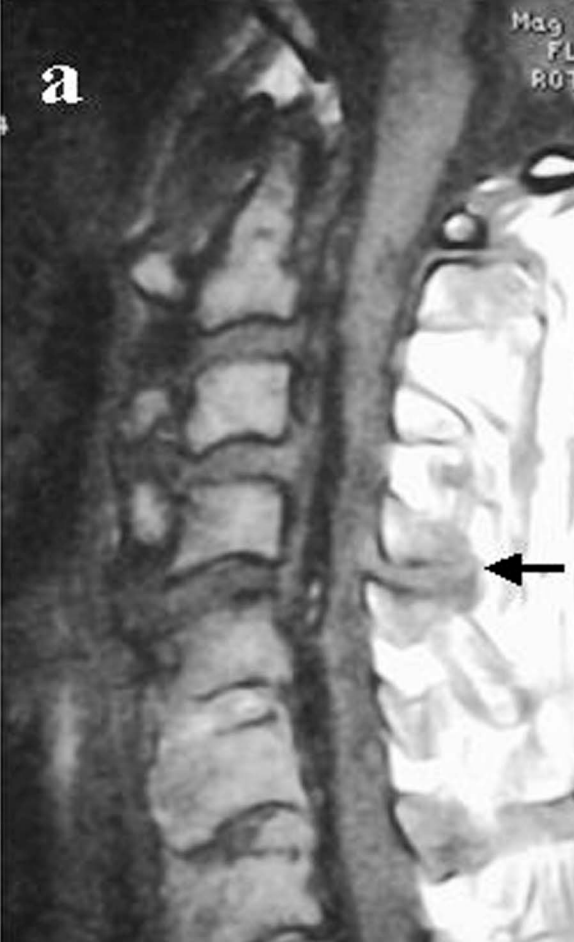a



b

Mag
FL
ROT

a



b

May
F
RO

