Long-term follow up of surgical outcomes in patients with cervical disorders undergoing hemodialysis

Hideki Sudo, MD, Manabu Ito, MD, Kuniyoshi Abumi, MD,Yoshihisa Kotani, MD,

Tatsuto Takeuchi, MD, Keigo Yasui, MD, Akio Minami, MD

Department of Orthopaedic Surgery, Hokkaido University Graduate School of Medicine, Sapporo, Japan

Correspondence: Hideki Sudo, MD, PhD

Department of Orthopaedic Surgery Hokkaido University Graduate School of Medicine

North-15, West-7, Kita-ku ,Sapporo, Hokkaido 060-8638, Japan

Tel: 81-11-706-5934 Fax: 81-11-706-605 Email: nanamisudo@yahoo.co.jp

Key Words: hemodialysis, cervical spine, surgical treatment, adjacent level disease

Acknowledgment: The authors thank Takehiro Takebayashi, MD and Naoki Takeda, MD for their work in the coordination of the study.

Abstract

Objective. With increasing numbers of patients receiving long-term hemodialysis, the number of reports regarding hemodialysis-related cervical spine disorders has also increased. However,

there have been few reports summarizing the surgical results in patients with these disorders. The objectives of this study were to evaluate the long-term follow-up and clinical results after surgical treatment of cervical disorders in hemodialysis patients

Methods. Fifteen patients underwent surgical treatment (delete this sentence). 17 patients were enrolled in this study who underwent surgical treatment for cervical spine disorders while undergoing long-term hemodialysis. Of these patients, 15 patients were followed for more than 3 years after surgery represent, and they present study population. The remaining 2 patients died due to sepsis postoperatively. The average follow-up period was 120 months. Five patients without spinal instability underwent spinal cord decompression using bilateral open door laminoplasty. Ten patients with destructive spondyloarthropathy (DSA) underwent reconstructive surgery using pedicle screw fixation. In eight patients who underwent posterior instrumentation, anterior strut bone grafting with autogenous iliac bone was performed due to the remarkable levels of destruction in the anterior column.

Marked neurological recovery was obtained in all patients after the initial surgery. Progressive destructive changes with significant instability in the mobile segments adjacent to previous spinal fusion were observed in 4 patients who underwent circumferential spinal fusion (40%). There were no patients who required a second surgery after laminoplasty for spinal canal stenosis without DSA changes.

Conclusions. Spinal reconstruction using the cervical pedicle screw system provided an excellent fusion rate and good spinal alignment. However, during the long-term follow-up period, some cases required extension of the spinal fusion due to the destructive changes in the adjacent vertebral levels. Guidelines or recommendations to overcome these problems should be produced in the future to further increase the survival rates of hemodialysis patients.

Key Words: hemodialysis, cervical spine, surgical treatment, adjacent level disease

Introduction

The survival of patients with end-stage chronic renal failure has been significantly prolonged by renal dialysis and transplantation regimes. The cervical spine is a tissue that is severely affected in long-term hemodialysis patients, and can lead to destructive spondyloarthropathy

(DSA) or spinal canal stenosis due to hypertrophy of the ligamentum flavum, the formation of a calcified mass, or spinal amyloid deposition.[5,7,16] The number of reports describing these disorders in the cervical spine has been steadily increasing as the number of surviving patients receiving long-term hemodialysis has being growing.[1,2,9,12,19]

DSA was first described by its radiological features by Kunz et al[8]. In that study, the characteristics of DSA were defined as a narrowing of the intervertebral disc space and the presence of erosions and cysts in the adjacent vertebral plates that were associated with minimal osteophyte formation. The subaxial cervical spine was the most frequently involved region.[1,3,11,15] β2-microglobulin amyloidosis is one major cause of DSA and the middle cervical discs are the most susceptible to this β2-microglobulin amyloid deposition.[15] Risk factors for the development of DSA include the duration of renal failure, duration of hemodialysis, and various clinical variable factors.[9,11]

Thus several reports have described the pathologic features and the pathogenesis of spinal disorders in patients undergoing long-term hemodialysis, although there are relatively few clinical reports following the surgical results in these patients. The main purpose of this study was to report in detail the precise long-term follow-up results of the surgical treatment for cervical disorders in hemodialysis patients.

Materials and Methods

From April 1990 to September 2000, 17 patients were enrolled in this study (13 men, 4 women) who underwent surgical treatment for cervical spine disorders while undergoing long-term hemodialysis (Table 1). Of these patients, 15 patients were followed for more than 3 years after surgery represent, and they present study population {(Table 1) deleted this word}.

The remaining 2 patients died due to sepsis postoperatively. One patient who underwent open door C3 to C7 laminoplasty, died of sepsis 6 months after surgery. The remaining patient who underwent circumferential spinal reconstruction died of sepsis 2 months after surgery (Table 2).

The age range at surgery ranged from 44 to 72 (average 56.1 years). The duration of hemodialysis at the time of the initial operation ranged from 10 to 27 years (average, 18.6 years). The average follow-up period was 120 months (range 36-185 months). The causes of renal failure were glomerulonephritis in 13 patients, polycystic kidney disease in 1 case, and nephrosis in 1 patient. The pathologic features seen in the cervical spines were spinal canal stenosis (5 patients) due to hypertrophy of the ligamentum flavum or presence of calcified mass or amyloid deposition and DSA (10 patients). The compromised spinal vertebral levels were in the middle and lower cervical spine below C3-C4 in 11 patients and C2 in 3 patients. The remaining patient had two noncontiguous lesions in C1-C2 and in the lower cervical spine. Neurological symptoms were radiculomyelopathy (1 patient) or myelopathy (14 patients). The patient who showed radiculopathy had intolerable radiating pain in the right C5 area. Ten out of 14 patients with cervical myelopathy were unable to walk. Seven of 14 patients with myelopathy showed a disturbance in their precise finger motion.

Five patients without spinal instability underwent spinal cord decompression using bilateral open door laminoplasty with or without the removal of the amyloid or calcified mass that had

adhered well to the dural sac. In this group, all of them had lordotic or neutral alignment. Ten patients with radiographic evidence of destructive changes with significant instability underwent reconstructive surgery using pedicle screw fixation with or without bilateral open door laminoplasty. Autogenous iliac bone grafting was used together in all of the cases. Due to a severe destruction of the anterior column or kyphotic deformity compressing the spinal cord, 8 patients who underwent posterior instrumentation procedures were treated with combined anterior bone strut grafting using autogenous iliac bone, and/or anterior decompression. One patient who showed radiculopathy underwent unilateral foraminotomy and fusion using pedicle screw system. The number of the fixed spinal segments ranged from 1 to 5 (average, 2.8). Patients who underwent reconstructive surgery were managed in a rigid cervical collar after surgery for 3 to 4 weeks.

Anterior-posterior and lateral radiographs with flexion and extension views were obtained to determine the fusion status, the presence of any late implant or graft complications, and adjacent level destructive changes. Pre- and postoperative neurological status was assessed using the cervical myelopathy scoring system of the Japanese Orthopedic Association (JOA; the highest possible score for normal, well-being, 17 points).[14] Due to the difficulty of evaluating patient bladder function in this study, 3 points were universally deducted for bladder function, so that 14 points represented the highest possible score in this case.

Results

Neurological recovery was obtained in all patients after surgery. Early postoperative complications occurred in two patients, they included postoperative bleeding in one patient and pneumonia in another (Table 2). There were no patients with neurovascular complications related to the placement of pedicle screws. The mean preoperative JOA score was 6.9 points (2-11 points) and improved to 12.3 points (6-14 points) after the initial surgery. The mean JOA

score at the final follow-up was 10.4 points (2-14 points). During the postoperative follow-up period, 4 patients died (Table 2). One patient who underwent circumferential spinal fusion died after coronary bypass surgery, some 95 months after the initial spinal surgery. One patient who underwent circumferential spinal reconstruction died of intestinal necrosis due to abdominal angina, 129 months after the initial surgery. The third patient who underwent combined anterior-posterior spinal fusion died of acute heart failure 81 months after the first operation. The final patient who underwent circumferential spinal fusion died from an unknown cause of death at 36 months after the initial surgery. There was no association between the duration of hemodialysis and postoperative complications.

Late complications included pseudarthrosis in 1 patient who underwent circumferential spinal fusion (10%) (Case 13). The patient underwent extension of the circumferential spinal fusion, 12 months after the initial surgery. The bony fusion in this patient was completed by the final follow-up (36 months after the initial surgery). Progressive destructive changes with significant instability in the mobile segments adjacent to previous spinal fusion were observed in 4 patients who underwent circumferential spinal fusion (40%). Two patients underwent extension of circumferential spinal fusion using pedicle screw fixation and anterior iliac bone grafting at 26 and 31 months after the initial surgery, respectively. These 2 patients had solid bone fusion at the final follow-up after the second surgery. One patient underwent extension of posterior fusion

alone at 75 months after the initial surgery. However, the patient showed destructive change below the previous surgical sites at 28 months after the second surgery, which was followed up conservatively. The remaining patient was followed up and treated conservatively because of a high risk under general anesthesia. There were no patients who required a second surgery after laminoplasty for spinal canal stenosis without DSA changes (Table 2).

Case Presentations

Case 5. A 47-old-man on maintenance hemodialysis for 20 years for end-stage renal failure caused by chronic glomerulonephritis had severe cervical myelopathy due to DSA. Plain lateral radiographs showed vertebral slippage at C5-6 (Figure 1). T2 weighted sagittal magnetic resonance image (MRI) demonstrated pseudotumor compressing the spinal cord at the level C5-6. The patient underwent posterior decompression and instrumentation surgery at C5-6 level using the pedicle screw fixation system followed by anterior decompression and fusion using an autogenous iliac bone graft. In DSA cases, osteoporosis or bone fragility of vertebral bodies is especially accelerated. On the contrary, the pedicle is the last place for destruction. So, the pedicle screw system was more reliable than anterior instrumentation. Therefore, posterior route was chosen prior to anterior approach for DSA patients. In addition to the stability, resection of amyloid deposits around the intervertebral discs and autogenous bone grafting was essential to achieve biological fusion. When we use the pedicle screw system to restore the spinal alignment

and to provide the stability, anterior implants are not necessary and only autogenous bone grafting will be enough.[1] Due to the aforementioned reasons, the spine was realigned and stabilized through a posterior route and then, resection of intervertebral discs and bone grafting was performed.

After the surgery the patient was able to walk and his numbness in both hands almost completely disappeared. The patient experienced severe pain in his lower extremities at 75 months after the initial surgery (delete this sentence). At 75 months postoperatively, the patient experienced a gait disturbance characterized by spasticity in the lower extremities and numbness in the upper and lower extremities. Plain lateral radiograph showed subluxation at C4-5 adjacent to the first surgical lesion. Extension of posterior fusion was carried out using pedicle screw system at the C4-5 level. The severe pain in his lower extremities was alleviated after the second surgery (delete this sentence). The myelopathy resolved after the second surgery. However, at 28 months after the second surgery, the patient gradually found difficulty walking and experienced complete paraplegia. MRI demonstrated destructive changes compressing spinal cord at the C6-7 level. The patient was followed conservatively because his general condition was very poor and he died of intestinal necrosis due to abdominal angina at 54 months after the second surgery.

The sagittal view of the initial MR image showed already hypertrophy of the ligamentum flavum at the C4-5 level. However, this level did not associate his clinical symptoms. Therefore,

we did not involve any decompression at this level. The principle of the surgery for DSA patients is minimally invasiveness to prevent perioperative complications related to poor general conditions. We do not find the best answers regarding inclusive surgical criteria for treatment levels. We have experienced some patients who progressed slippage at the decompression level several years after the surgery and also other patients who had progression of DSA changes at the adjacent levels to prior fusion segments. Therefore, we cannot conclude whether all affected segments should be included for surgery or not. Farther studies regarding natural history of DSA and long-term clinical studies with a large scale will be needed to answer this question.

Case 6. A 44-year-old man had been on maintenance hemodialysis for 21 years for chronic renal failure caused by chronic glomerulonephritis and was unable to walk due to cervical myelopathy. Preoperative plain radiograph demonstrated no destructive changes (Figure 2). T2 weighted MRI revealed cervical canal stenosis compressing the spinal cord. Bilateral open door laminoplasty was performed from C4 to C7. After the treatment, the cervical myelopathy disappeared. The patient apparently made a complete neurological recovery from being unable to walk preoperatively.

Plain follow-up radiograph revealed DSA changes at C5-6 level at 163 months after the initial surgery. However, the patient was being followed conservatively because only limited neurological deterioration was experienced by the patient.

Discussion

The incidence of spinal DSA is approximately 20% in long-term hemodialysis patients.[9,18] In a five-year radiological prospective study, Leone et al[9] reported cervical spine DSA was found in 19 % of patients. Although the pathogenesis of DSA is still unknown, accumulation of β2-microglobulin is one possible cause of DSA.[3,17] β2-microglobulin is a normal blood protein whose levels in renal failure patient are elevated by 30-50 times the normal values.[4]

β2-microglobulin has a predilection for deposition in cartilage, connective tissue, and synovial membranes, especially the collagen bundles of the annulus fibrosus.[9,15] The suggested mechanism of amyloid fibril formation involves inflammatory processes causing the partial proteolysis of β2-microglobulin into smaller fragments.[10] The amyloid converted from β2-microglobulin has a particular affinity for collagen in intervertebral discs, specifically the peridiscal, periarticular, and perineural tissues.[15] Such amyloid deposits in the vertebral body and disk lead to damage and loss of structural integrity and to further erosive destruction of the spinal segment.[3]

Ito et al[5] (delete this word) We previously reported a distribution pattern of amyloid deposition in the facet joints, intervertebral discs, and vertebral bodies.[5] Amyloid was densely deposited at the enthesis of collagen fibers to the bone at the facet joints and in the peripheral tears of the annulus fibrosis (Figure 3). The capsular and annular fibers were disrupted by amyloid deposition, which eventually may lead to laxity of posterior ligaments and spinal instability. In addition to ligament laxity, the vertebral end plates also were destroyed by amyloid granulation penetration into the adjacent vertebral bodies. These destructive changes of the spinal three-joint complex eventually led to subluxation at multiple levels and severe spinal instability. Besides these destructive changes, calcified masses or amyloid deposits have been detected in the spinal canal and hypertrophied ligamentum flavum.

When patients have neurologic symptoms from either destructive changes or intracanalicular deposition of amyloid, surgical treatment should be considered. The specific treatment plan must be determined on an individual basis according to the state of neural compression, spinal instability, osteoporosis, and the general condition of the patient.

There have been few reports describing the long-term surgical follow-up results in hemodialysis patients with cervical disorders. Especially, there has been no follow-up surgical treatment outcome of more than five years. There are several spinal surgical difficulties in patients who undergo long-term hemodialysis, because of their poor general condition, severe bone fragility, and a low bone fusion rates. Consequently, a high postoperative mortality rate has been reported in these patients.[7,13] Although the numbers of patients in this study overall are small because of the high mortality rate, there are some important clinical topics to discuss. In this current study, patients with spinal canal stenosis due to the presence of a calcified mass or amyloid deposition in the ligamentum flavum or epidural space without marked segmental spinal instability were successfully treated by posterior decompression alone. However, reconstructive surgery with instrumentation was necessary in DSA cases. Due to the severe destructive changes involved, the three-joint complex of the spinal column, circumferential spinal reconstruction comprising posterior fusion and replacement of the destructed vertebral bodies is considered.

The authors have used the pedicle screw system for reconstructive surgery because the pedicle is maintained intact even after severe destruction of many other spinal components, such as the facet or lateral mass.[1] From the surgical results of the current study, the cervical pedicle screw system provides a excellent fusion rate and maintenance of good spinal alignment during the long-term follow-up period. Moreover, circumferential or posterior fusion with pedicle screws do not require rigid external fixation such as Halo best after the operation, which are advantageous in the treatment of hemodialysis patients with a poor general condition. To improve the pedicle screw system further, the authors recently use a computer-assisted surgical insertion navigation system to avoid difficulties with screw insertion, which enable a safer and more accurate pedicle screw placement in the cervical spine.[6]

Conversely, the current study demonstrated that 40 % of patients who underwent circumferential spinal reconstruction required extension of spinal fusion due to destructive changes in the adjacent levels during the long-term follow-up. As most DSA cases involving the cervical spine require circumferential fusion, the construct stiffness of the reconstructed segment is increased, which commonly leads to hyper mobility and extra stresses in the adjacent segment(s). Ohashi et al[15] reported that collagen degenerated after mechanical stress has a high affinity for β2-microglobulin. This phenomenon may accelerate the destructive changes in the adjacent mobile segment. Therefore, the surgeon must decide the most appropriate fusion level.

Guidelines or recommendations to overcome these problems should be produced in the future to further increase the survival rates of hemodialysis patients. As a possible strategy to manage cervical disorders in hemodialysis patients, spinal canal stenosis without marked segmental spinal instability can be successfully treated by posterior decompression alone. Some patients who have undergone posterior decompression alone may show DSA change in the previous surgical lesion in the future as part of the natural course of long-term hemodialysis patients. In this study, one patient developed DSA changes in the follow-up period, however, the patient remains asymptomatic. Hence, hemodialysis patients have to be properly treated according to the pathologic conditions at the time they present with their symptoms because the general condition of these patients is usually not ideal for invasive surgery.

References

1. Abumi K, Ito M, Kaneda K. Surgical treatment of cervical destructive spondyloarthropathy (DSA). **Spine 25**: 2899-2905,2000

2. Danesh FR, Klinkmann J, Yokoo H, Ivanovich P. Fatal cervical spondyloarthropathy in a

hemodialysis patient with systemic deposition of β2-microglobulin amyloid. **Am J Kidney Dis 33**: 563-566,1999

3. Davidson GS, Montanera WJ, Fleming JF, Gentili F. Amyloid destructive spondyloarthropathy causing cord compression: related to chronic renal failure and dialysis. **Neurosurgery 33**: 519-522,1993

4. Gejyo F, Homma N, Suzuki Y, Arakawa M. Serum levels of β2-microglobulin as a new form of amyloid protein in patients undergoing long-term hemodialysis. **N Engl J Med 314**: 585-586,1986

5. Ito M, Abumi K, Takeda N, Satoh S, Hasegawa K, Kaneda K. Pathologic features of spinal disorders in patients treated with long-term hemodialysis. **Spine 23**: 2127-2133,1998

6. Kotani Y, Abumi K, Ito M, et al. Improved accuracy of computer-assisted cervical pedicle screw insertion. **J Neurosurg（Spine3）99**: 257-263,2003

7. Kumar A, Leventhal MR, Freedman EL, Coburn J, Delamarter R. Destructive spondyloarthropathy of the cervical spine in patients with chronic renal failure. **Spine 22**: 573-578,1997

8. Kuntz D, Naveau B, Bardin T, Drueke T, Treves R, Dryll A. Destructive spondyloarthropathy in hemodialyzed patients: a new syndrome. **Arthritis Rheum 27**:369-375,1984

9. Leone A, Sundaram M, Cerase A, Magnavita N, Tazza L, Marano P. Destructive spondyloarthropathy of the cervical spine in long-term hemodialyzed patients: a five-year clinical radiological prospective study. **Skeletal Radiol 30**: 431-441,2001

10. Linke RP, Hampl H, Bartel-Schwarze S, Eulitz M. β2-microglobulin,different fragments and polymers there of in synovial amyloid in long-term haemodialysis. **Biol Chem Hoppe-Seyler 368**:137-144,1987

11. Maruyama H, Gejyo F, Arakawa M. Clinical studies of destructive spondyloarthropathy in long-term hemodialysis patients. **Nephron 61**: 37-44,1992

12. Nair S, Vender J, McCormack TM, Black P. Renal osteodystrophy of the cervical spine: neurosurgical implications. **Neurosurgery 33**: 349-355,1993

13. Naito M, Ogata K, Nakamoto M, Goya T, Sugioka Y. Destructive spondyloarthropathy during long-term haemodialysis. **J Bone and Joint Surg [Br] 74**: 686-690,1992

14. Ogawa Y, Chiba K, Matsumoto M, Nakamura M, Takaishi H, Hirabayashi H, et al. Long-term results after expansive open-door laminoplasty for the segmental-type of ossification of the posterior longitudinal ligament of the cervical spine: a comparison with nonsegmental-type lesions. **J Neurosurg Spine 3**: 198-204,2005

15. Ohashi K, Hara M, Kawai R, Ogura Y, Honda K, Nihei H, et al. Cervical discs are most susceptible toβ2-microglobulin amyloid deposition in the vertebral column. **Kidney Int 41**:

1646-1652,1992

16. Rafto SE, Dalinka MK, Schiebler ML, Burk DL Jr, Kricun ME. Spondyloarthropathy of the cervical spine in the long-term haemodialysis. **Radiology 166**: 201-204,1988

17. Sebert JL, Fardellone P, Marie A, Deramond H, Lambrey G, Legars D, et al. Destructive spondyloarthropathy in hemodialysed patients: possible role of amyloidosis. **Arthritis Rheum 29**: 301-302,1986

18. Yamamoto T, Matsuyama Y, Tsuji T, Nakamura H, Yanase M, Ishiguro N. Destructive Spondyloarthropathy in Hemodialysis Patients: Comparison Between Patients With and Those Without Destructive Spondyloarthropathy. **J Spinal Disord Tech 18**: 283-285,2005

19. Yuzawa Y, Kamimura M, Nakagawa H, Kinoshita T, Itoh H, Takahashi J, et al. Surgical Treatment with Instrumentation for Severely Destructive Spondyloarthropathy of Cervical Spine. **J Spinal Disord Tech 18**: 23-28,2005

Figure Legends

Table 1

Summary of 15 patients who underwent surgery for cervical spine disorders.

Figure1

Case 5. Plain radiography showed destructive spondyloarthropathy changes at the C5-6 level (A). Magnetic resonance image demonstrated pseudotumor compressing the spinal cord (B). The patient underwent circumferential spinal fusion (C). Subluxation at the C4-5 segment adjacent to the fused site was revealed at 75 months after the initial surgery (D). At 28 months after the second surgery, destructive changes were demonstrated at the C6-7 level, below the previous surgical sites (E).

Figure 2

Case 6. Magnetic resonance image demonstrated cervical canal stenosis compressing the spinal cord (A). Bilateral open door laminoplasty was performed from C4 to C7 (B). Plain follow-up radiograph revealed DSA changes at C5-6 level at 163 months after the initial surgery (C). However, the patient was followed up conservatively because little neurological deterioration was apparent.

Figure 3

Pathology of the tissues resected at the time of surgery in Case 7. Destruction of the intervertebral disc and the vertebral endplate by penetration of amyloid deposits (hematoxylin eosin stain, magnification x 100). ALL= anterior longitudinal ligament

Table 1. Summary of 17 Patients Who Underwent Surgery for Cervical Spine Disorders

Case No.	Age(yrs)/Sex	Duration of Dialysis(yrs)	Diagnosis	Vertebral Level	Neurologic Symptoms	Surgery	JOA Preop	JOA Postop	JOA Final	Length of FU (mo)	Associated Comorbidities
1	64/F	11	DSA	C2/3-6/7	myelopathy	Laminectomy(C2-4),PF & AF (C5-7)	4	12	12	95	Lumbar spine-DSA treated conservatively
2	47M	10	DSA	C5/6	radiculomyelopathy	Foraminotomy&PF(C5/6)	10	13	13	185	
3	57/M	17	CS/hypertrophy of LF	C4/5,5/6	myelopathy	Laminoplasty（C3-7）	2	8	8	164	
4	52/F	21	DSA	C3/4-6/7	myelopathy	Laminoplasty（C3-7）,PF & AF (C4-7)	7	12	12	161	Lumbar spine-DSA treated surgically
5	47/M	20	DSA	C5/6	myelopathy	PF & AF (C5-6)	11	14	2	129	
6	44/M	21	CS/amyloid deposition	C3/4-5/6	myelopathy	Laminoplasty（C4-7）	8	12	11	176	
7	63/M	20	DSA	C1, C3/4-5/6	myelopathy	Laminectomy(C1-6),PF & AF (C4-7)	3	6	11	158	
8	64/M	18	DSA	C4/5,5/6	myelopathy	PF & AF (C4-6)	11	14	14	81	DM, RA
9	45/M	19	DSA	C4/5,C5/6	myelopathy	Laminectomy,PF & AF (C4-6)	6	12	12	141	Lumbar spine-DSA treated surgically
10	58/F	27	CS/calcified mass&hypertrophy of LF	C4/5,C5/6	myelopathy	Laminoplasty（C2-7）	4	12	12	131	Parathyroidectomy
11	58/F	19	DSA	C3/4-5/6	myelopathy	Laminectomy,PF & AF (C4-7)	9	13	4	135	
12	72/M	12	DSA	C3/4-5/6	myelopathy	Laminoplasty（C3-7）,PF & AF (C3-5)	4	10	11	79	Recurrent respiratory infection
13	61/M	21	DSA	C3/4,4/5	myelopathy	Laminectomy,PF & AF (C3-6)	5	11	11	36	
14	56/M	23	CS/calcified mass &epidual adhesion	C2-C7	myelopathy	Laminoplasty (C2-7)	4	12	12	71	
15	54/M	20	CS/hypertrophy of LF	C2-T1	myelopathy	Laminoplasty (C2-7)	4	12	12	64	
16	53/M	21	CS/hypertrophy of LF	C3-C7	myelopathy	Laminoplasty (C3-7)	4	6	6	6	
17	60/M	25	DSA	C1/2,4/5-5/6	myelopathy	myelopathy	6	8	8	2	

DSA= destructive spondyloarthropathy; CS= cervical spinal canal stenosis; LF= ligamentum flavum; PF= posterior fusion; AF=anterior fusion; FU= follow-up; DM= diabetes mellitus; RA= rheumatoid arthritis

Table 2. Complications and Life-threatening Outcomes in 17 patients

Case No.	Early Complications	Late Complications	Life-threatening Outcomes
1		2nd Surg; PF(C2-T3) & AF(C4-5) /adjacent segment lesions	Died after coronary bypass surgery 95 months after initial surgery
2			
3			
4		2nd Surg;PF(C2-T2)&AF(C2-4) /adjacent segment lesions	
5		2nd Surg; PF(C4/5) /adjacent segment lesions	Died of intestinal necrosis due to abdominal angina 129 months after initial surgery
6		DSA changes(C5/6) treated conservatively	
7			
8			Died of acute heart failure 81 months after initial surgery
9	Postoperative bleeding		
10			
11		Adjacent segment lesions treated conservatively	
12			
13	ICU for 3 weeks for pneumonia	2nd Surg; PF & AF (C3-7) / pseudarthrosis	Died from unknown cause 36 months after initial surgery
14			
15			
16	Died of sepsis 6 months after surgery		
17	Died of MRSA sepsis 2 months after surgery		

PF= posterior fusion; AF=anterior fusion; DSA= destructive spondyloarthropathy; ICU= intensive care unit; MRSA= methicillin-resistant staphylococcus aureus

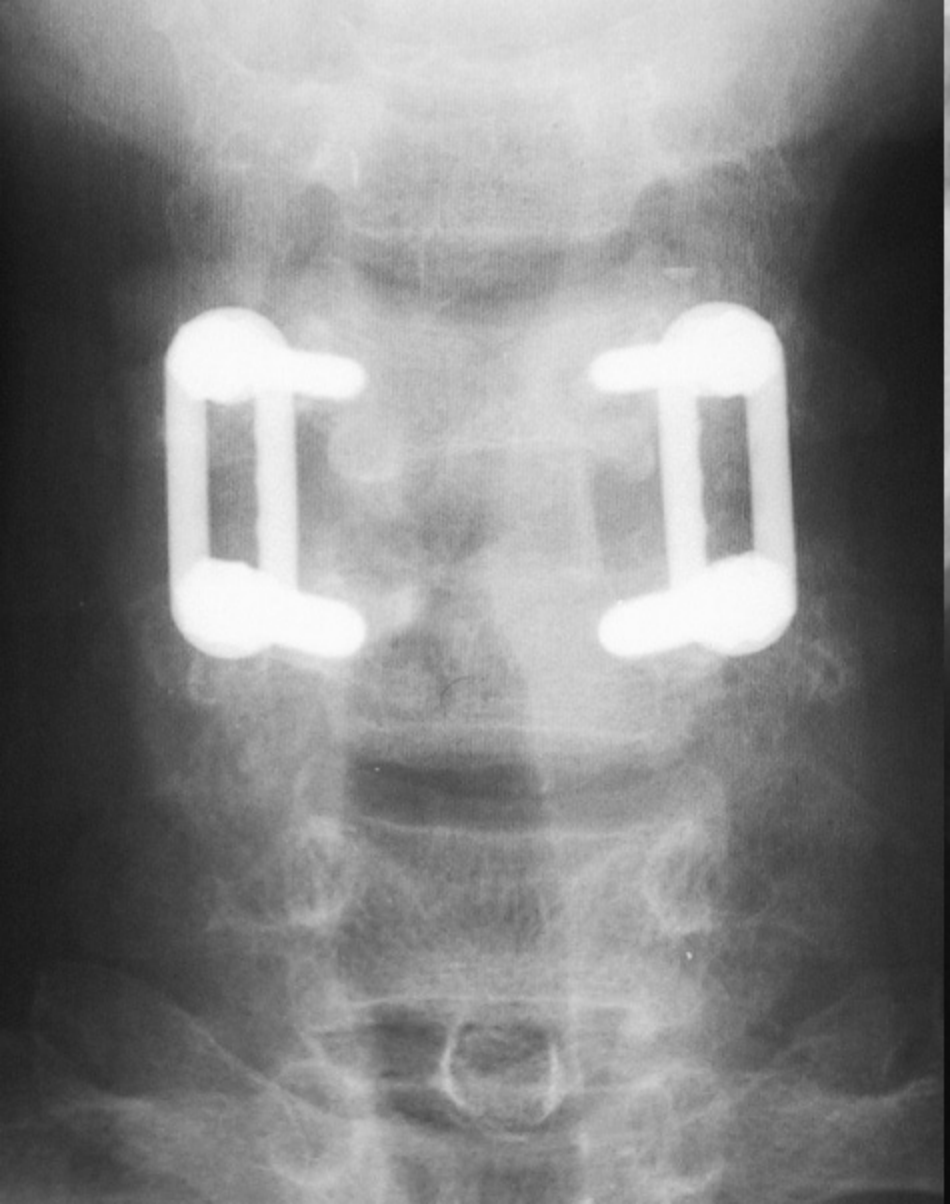


SP

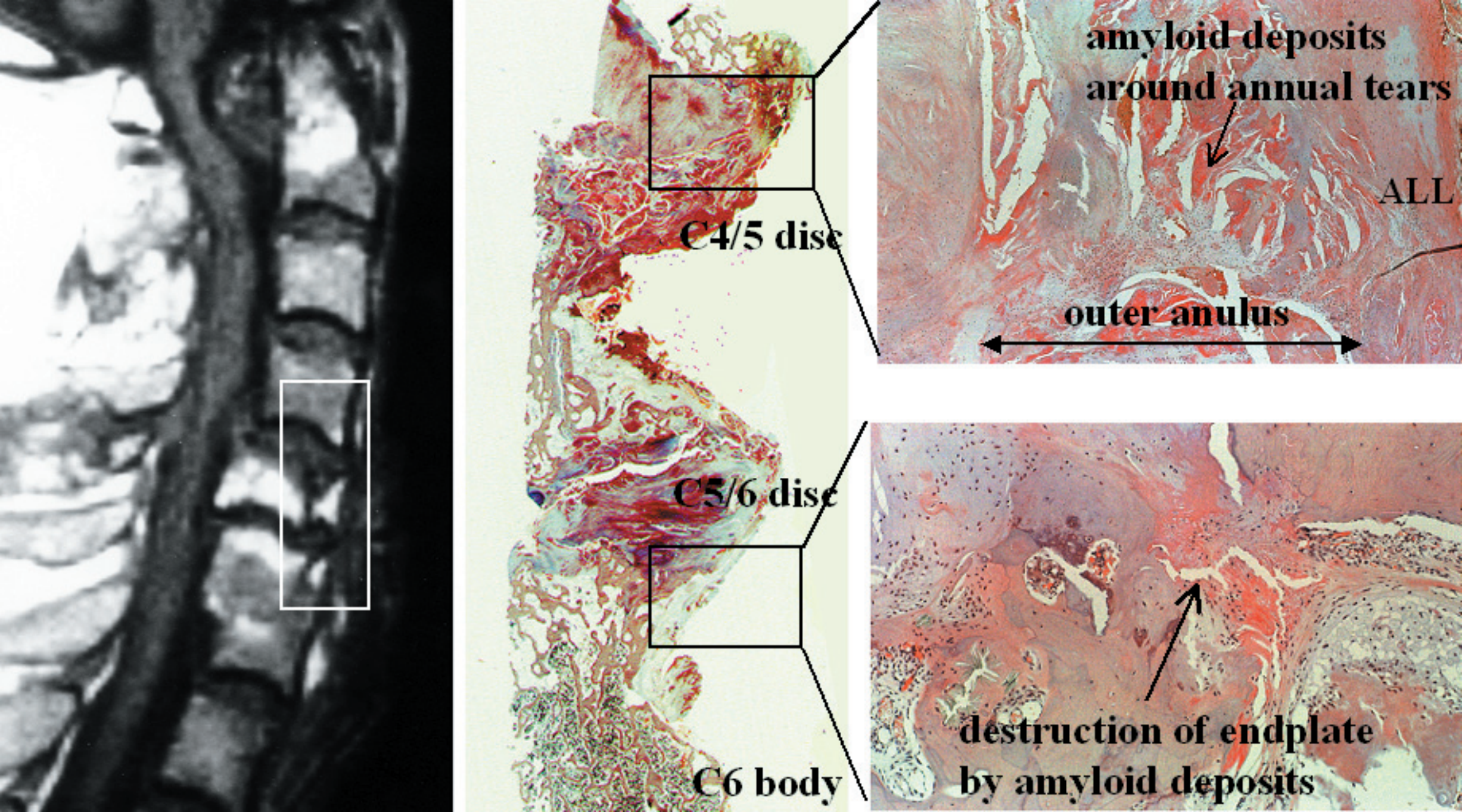
amyloid deposits
around annual tears
ALL
C4/5 disc
outer anulus
C5/6 disc
destruction of endplate
by amyloid deposits
C6 body