HOKKAIDO UNIVERSITY

Title	HISTOLOGICAL AND HISTOCHEMICAL STUDIES ON THE POSTNATAL LYMPH NODES OF THE CAT : ABOUT STRUCTURAL VARIATIONS WITH RELATION TO DIFFERENTIATION, LOCATION AND AGE
Author(s)	SUGIMURA, Makoto
Citation	Japanese Journal of Veterinary Research, 10(4), 155-202
Issue Date	1962-12
DOI	10.14943/jjvr.10.4.155
Doc URL	http://hdl.handle.net/2115/1770
Type	bulletin (article)
File Information	KJ00002373359.pdf

Instructions for use

Hokkaido University Collection of Scholarly and Academic Papers : HUSCAP

HISTOLOGICAL AND HISTOCHEMICAL STUDIES ON THE POSTNATAL LYMPH NODES OF THE CAT: ABOUT STRUCTURAL VARIATIONS WITH RELATION TO DIFFERENTIATION, LOCATION AND AGE

Makoto SUGIMURA

Department of Veterinary Anatomy
Faculty of Veterinary Medicine
Hokkaido University, Sapporo, Japan

(Received for publication, Sept. 7, 1962)

INTRODUCTION

Various structural variations of the lymph node under not only pathological but also under physiological conditions have been pointed out by GILLMAN et al. ('52) and many other investigators; some of the variations have been understood as regional, age- or species-differences by ASCHOFF ('38–'39), DENZ ('47), HELLMAN ('30), HORII ('52), NORDMANN ('28) and RICHTER ('02).

However, there are many points in dispute: In regard to regional difference, JOB ('22) classified the rat lymph nodes into types I and II by the differences of arrangement of the cortex and medulla, and asserted regional difference as regards the occurrence of each type. But DAWSON and MASUR ('29) denied JOB's view in the same animal species. Also, RICHTER ('02) stated that the medulla of the peritoneal lymph nodes is wider than that of the superficial lymph nodes in the horse, cow and dog. Such finding was also reported by some investigators (DUNN, '54 and TRAUTMANN and LIPPMANN, '60) in the mouse and rat. On the contrary, DENZ ('47) maintained that the cortex of the deep lymph nodes is thicker than that of the superficial ones in man.

As to age-difference, it seems to be a definite opinion that the microscopical changes of the lymph node with advance in age are due to the atrophy of lymphatic tissue, increase of collagenous framework and fatty involutions (HELLMAN, '30). But, some investigators, ANDREW and ANDREW ('48), KRUMBAAR ('38) and WEST ('24), harboured suspicion as to such senile changes in their observations of deep cervical nodes of the rat, of clinical materials in man and of lymphatic nodules in the lungs of the rat, cat and rabbit respectively.

Recent reports, by DENZ ('47), GYLLENSTEN ('50) and HORII ('60), have moreover stated that the age-difference of the lymph node correlates intimately with its regional difference.

Actually, perhaps owing to insufficient observations, even the normal pattern of the lymph node is shown as different in form respectively in certain histological

textbooks (COWDRY, '50; HAM, '57; KRÖLLING and GRAU, '60 and MAXIMOW and BLOOM, '57).

The present writer's essential aim is to clarify the exact normal pattern of the lymph node, for the sake of further investigations for pathological and physiological purposes. In this report, relations between various structural variations of the cat lymph nodes and their location, age or differentiation are described from the findings of histological and histochemical observations on the basis of the writer's former detailed macroscopical descriptions of the cat lymphatic system[96)-100)].

MATERIALS AND METHODS

For this research, 49 cats, 1 day to 16 years old, were used as listed in table 1.

TABLE 1. *Materials*

EXP. NO.	SEX	AGE	BODY WEIGHT (g)	NUMBER OF EXAMINED LYMPH NODES	EXP. NO.	SEX	AGE	BODY WEIGHT (g)	NUMBER OF EXAMINED LYMPH NODES
1	♂	1 Day	100	7	26	♀	7 Months	2,200	19
2	♂	1 "	100	36	27	"	8 "	2,000	24
3	"	1 "	100	10	28	♂	8 "	2,800	46
4	"	6 Days	120	32	29	"	10 "	4,500	50
5	♂	7 "	150	4	30	♀	1 Year	1,650	39
6	♀	7 "	220	14	31	"	1 "	1,800	10
7	"	1 Month	250	6	32	"	1 "	1,800	8
8	♂	1.5 Months	360	37	33	"	1 "	2,000	10
9	♀	2 "	400	13	34	"	1 "	2,400	15
10	♂	2 "	450	27	35	♂	2 Years	2,500	44
11	♀	2 "	450	26	36	"	2 "	3,100	22
12	"	2 "	550	40	37	♀	2 "	4,100	34
13	♂	2 "	750	25	38	"	3 "	1,450	3
14	"	3 "	700	2	39	"	3 "	2,050	37
15	♀	3 "	800	15	40	"	3 "	2,500	7
16	♂	3 "	850	23	41	♂	3 "	2,600	7
17	♀	3 "	850	15	42	♀	3 "	2,850	72
18	"	4 "	1,100	23	43	"	3 "	2,900	4
19	♂	4 "	1,150	5	44	♂	3 "	3,900	7
20	"	4 "	1,200	35	45	"	3 "	4,500	10
21	"	5 "	1,100	40	46	♀	5 "	2,900	4
22	"	5 "	1,200	33	47	♂	5 "	5,000	51
23	"	7 "	1,800	47	48	♀	8 "	3,000	32
24	"	7 "	2,000	3	49	"	16 "	3,150	37
25	♀	7 "	2,100	23				Total	1133

For the detection of small lymph nodes, India ink was injected into lymphatic vessels in most cases. Out of the lymph nodes in 48 different regions of the cat's body, the nodes of two groups, *Lnn. epigastrici craniales* and *Ln. prefemoralis* belonging to the writer's so-called group of "inconstant occurrence", were not found in this observation. Accordingly, in this histological investigation, 1133 lymph nodes obtained from 46 different locations were examined.

The cats were killed by ether overdosage. After death, the fresh materials were fixed in 10% formalin, and when necessary, in CARNOY's, ZENKER's and MAXIMOW's fluids. After fixation, as a routine matter, the materials were embedded in paraffin, sectioned serially 4-10 μ in thickness. Some of them were used for the freezing sections.

Paraffin sections were treated with hematoxylin-eosin stain, Giemsa stain, HEIDENHEIN's azan or VAN GIESON's stains for connective tissues and GÖMÖRI's or LILLIE's silver impregnations for reticular fibers. In some section preparations use was made of some histochemical methods: FEULGEN's reaction for DNA. TRAFT's pyronine-methyl green stain with ribonuclease control for RNA, MCMANUS's PAS reaction with saliva control for carbohydrate, OHNO et al.'s toluidin blue stain for acid mucopolysaccharide, DADI's sudan III and LISON's sudan black stains for lipides in frozen section, PERL-STIEDA's Prussian-blue reaction for iron containing pigments and SCHMORL's and MALLORY's reactions for lipofuscin. In addition, some paraffin sections were treated with sudan III and sudan black for lipofuscin-like pigments.

GROUPS OF LYMPH NODES ON THE BASIS OF MACROSCOPICAL OBSERVATIONS

A. Grouping on the Basis of the Ratio of Occurrence of the Lymph Node and Appearances of the Afferent Lymphatic Vessels

For convenience of observation, the lymph nodes were divided into three groups according to the differences of occurrence of the lymph nodes and of appearances of the afferent lymphatic vessels, as follows.

1. Group O. I: constant and nearly constant occurrence. Consists of usually large lymph nodes which receive only peripheral lymph (the writer's type Z node) or which receive both peripheral and efferent lymph fluid (type ZT node).

2. Group O. II: inconstant occurrence. Consists of generally small main nodes which were also classified as the writer's types Z and ZT.

3. Group O. III: inconstant occurrence. Accessory nodes in the lymphcenter. Generally smaller nodes, mostly less than 1 mm in size, which receive only efferent lymph from other nodes (the writer's type T).

The above three groups are called simply "occurrence groups" in this report.

B. Grouping on the Basis of the Location and Peripheral Drainage Area

For the observation of regional difference, the lymph nodes were moreover classified into 15 groups. Each group receives the afferent lymph from a similar drainage area and is located at a similar region, as follows.

1. Submandibular group: including *Lnn. submandibulares laterales* and *mediales.* This group receives afferent lymph from the subcutis of the face and oral cavity.

2. Retropharyngeal group: including *Lnn. retropharyngici* only. The afferent lymph

flows into this node from the deep part of the head, oral and nasal cavities.

3. Parotid group: including *Lnn. parotidici craniales* and *caudales.* The afferent lymph comes from the auricle and parotid gland.

4. Cervical group: including *Lnn. cervicales superficiales dorsales* and *ventrales.* The afferent lymph flows into these nodes from the cranial legs and cervical subcutis.

5. Axillar group: including *Lnn. axillares craniales* and *caudales.* This group receives the afferent lymph from the cranial legs and thoracic subcutis.

6. Inguinal group: including *Lnn. subinguinales superficiales* and *Lnn. epigastrici caudales.* Receives the afferent lymph from the caudal legs and abdominal subcutis.

7. Popliteal group: including *Lnn. ischiadici* and *Ln. popliteus.* Receives the afferent lymph from the caudal legs.

8. Lumbar group: including *Lnn. lumbales craniales* and *caudales*, and draining the wall of abdomen, abdominal and pleural fluids, and genital organs.

9. Iliac group: including *Lnn. ilici interni* and *externi*, draining the caudal wall of abdomen and the urogenital organs.

10. Gastrolienal group: including *Lnn. gastrici sinistri et dextri, Lnn. subpylorici* and *Lnn. gastrolienales* and receiving the afferent lymph from the stomach and spleen.

11. Hepatogastric group: including only *Lnn. hepatogastrici* and draining the liver and stomach.

12. Small intestinal group: including *Lnn. mesenterici communes* only and receiving the afferent lymph from the small intestine.

13. Large intestinal group: including *Lnn. mesocolici dextri, medii et sinistri* and *Lnn. caecales* and receiving the afferent lymph from the large intestine.

14. Mediastinal group: including *Lnn. sternales, Lnn. mediastinales craniales, Lnn. paratracheales* and *Lnn. anguli brachiocephalici* and draining the pleural wall, abdominal and pleural fluids.

15. Tracheobronchial group: including *Lnn. tracheobronchiales craniales* and *caudales* and receiving the lymph from the lungs.

These groups are simply called "regional groups" in this paper.

OBSERVATIONS

A. General Histological Structures of the Cat Lymph Nodes

The microscopical structures of the cat lymph node were described in detail by HEUDORFER ('21). But, his descriptions are also very short like those of many other authors, especially in regard to the cortex. Moreover, the present writer was sometimes troubled to understand exactly some histological structures of the lymph node, because among many investigators, there are many different uses of technical terms concerning the respective structures. For avoiding such sorts of confusion, the general terms used by the present writer are defined as below. A typical pattern of the lymph node is presented in schema 1 in Plate I.

1. Supporting framework { Capsule / Trabeculae { Cortical trabeculae / Medullary trabeculae

2. Lymphatic parenchyma
   - Cortex-Cortical mass (Cortical nodule)
     - Secondary nodule
     - Proper lymphatic parenchyma
     - Varied lymphatic parenchyma
   - Medulla
     - Medullary cords-Varied lymphatic parenchyma
     - Medullary nodule
       - Secondary nodule
       - Proper lymphatic parenchyma
3. Secondary nodule
   - Dark zone
   - Light center
4. Lymphatic sinuses
   - Subcapsular sinus
   - Intermediate sinus
   - Medullary sinus
   - Reticular fiberless sinus
5. Afferent and efferent lymphatic vessels, and blood vessels

1. Supporting framework

a) The thin capsule consists of dense collagenous fibers, in which are scattered fibroblasts, mast cells (Fig. 63), a few lymphocytes and plasma cells, but scarce smooth muscle fibers. The capsule entirely covers the lymph node.

b) The trabeculae consist of the same components as the capsule and are distinguished into two sorts, cortical and medullary. The cortical trabeculae are projected into intermediate sinuses at a right angle from the capsule and the end of the trabeculae continues gradually with the sinus reticular fibers in the sinuses. The medullary trabeculae start from the hilus tissues to be scattered in the medullary sinuses (Fig. 42). The cortical trabeculae are rarely found to connect with the medullary ones in the cat lymph nodes.

2. Lymphatic parenchyma

The lymphatic parenchyma is defined as a dense lymphatic tissue including some nodular tissues (secondary nodules). This is separated by the sinuses from the capsule and trabeculae. As regards the arrangement, the parenchyma is divided into the cortex and medulla.

a) The cortex is a mass of continuous thick or thin dense lymphatic tissues accompanying the secondary nodules; it covers the medulla in general. It sometimes appears as an arrangement of large nodules which are separated from each other by the intermediate sinuses in the section preparations. The large nodules measure sometimes over 1 mm in diameter (Figs. 13, 16 and 29) and correspond to the pseud-secondary nodule of EHRICH. Disorder of the cortex arrangement is frequently found (Fig. 15) as described by DENZ. Therefore, the term, either "cortical mass" or "cortical nodule", is used in this paper. The reticular meshes of the cortex are wide and polygonal in shape, in which there are nearly exclusively small lymphocytes. But, a few large lymphocytes (lymphoblasts) are also found (Plate VIII and Fig. 32).

b) The medulla consists of the medullary cords and medullary nodules: the medullary cords are the network-like cords of the dense lymphatic tissues; they are continuous with the cortex to take an arrangement radial to the hilus. The reticular meshes of the cords are slit-like and denser than those of the cortex (Figs. 28, 30, 42, 51 and 52), in the meshes are found lymphocytes, plasma cells (Figs. 59 and 60), mast cells (Fig. 64) and macrophages, such as dust cells (Fig. 72).

The medullary nodule is a small oval mass of dense lymphatic tissues and usually has a secondary nodule. The medullary nodules sometimes appear in the medullary cords (Figs. 53, 54, 55 and 56). The cell components and reticular meshes of the nodules, except for the secondary nodule, are more similar to those of cortical mass than of the medullary cords.

3. Secondary nodules

The secondary nodules are a restrictive nodular lymphatic parenchyma without veins. They appear generally at the subcapsular sinus side of the cortex, sometimes at the side of the intermediate and medullary sinuses of the cortex, and in the medullary nodule. It was proved in the serial sections that the secondary nodules never appear in the center of a cortical mass or nodule. The secondary nodules consist of a dark zone and light center. The dark zone, consisting nearly exclusively of small lymphocytes, is generally cap-shaped and situated at the sinus side of the secondary nodule. The light center is occupied by lymphoblasts, at the entrance area of the arteriole, and cells resembling reticular cells, at the dark zone side. Accordingly, the light center is surrounded not completely but partially with the cap-shaped dark zone as a usual feature. The reticular fibers distinctly line the nodule, but make scanty appearance in the center of the nodule. Sometimes, it is observed that outside of distinctly lining reticular fibers, small lymphocytes aggregate somewhat densely to have the appearance of the dark zone. Such finding is not treated as a true dark zone of the secondary nodule in this paper.

4. Lymphatic sinuses

The lymphatic sinuses are defined as loose lymphatic tissue; they are divided into the subcapsular, intermediate, medullary and reticular fiberless sinuses (Figs. 25, 33 and 36). The former three have a coarser and looser reticular mesh than that of the medullary cords (Figs. 51 and 52).

a) The subcapsular sinuses are situated between the capsule and the cortex and are poorly crossed by reticular cells.

b) The intermediate sinuses form a connection between the subcapsular sinuses and medullary sinuses passing through the cortical mass generally along the cortical trabeculae. The reticular cells are as scanty as those of the subcapsular sinus. In the cases injected with ink, it seems that the reticular cells of the subcapsular and intermediate sinuses have less phagocytic ability than those of the medullary ones.

c) The medullary sinuses are situated between the medullary cords. The medullary trabeculae are usually found in this part. The reticular cells and free cells, such as lymphocytes, macrophages etc., are more numerous than those in the other sinuses. In injected cases, the reticular cells phagocytose numerous ink particles in their cytoplasm (Fig. 73).

d) The reticular fiberless sinuses, corresponding to "die offenen Bahnen" of HEUDORFER and to "intermediate sinus" of ONO[84], were also found in this observation. The reticular fiberless sinuses are generally situated at the cortico-medullary junction. It is sometimes found that the sinuses begin as blind ends near the secondary nodule at the deep portion of the cortex to open into the ordinary medullary sinuses. The walls of the sinuses are lined by a layer of flat endothelial cells without being crossed by the ordinary reticular cells (Fig. 33). In some nodes, small and large lymphocytes fill the reticular fiberless sinus (Figs. 35

and 36). Injected ink enters more easily into the reticular fiberless sinuses than into the cortical parenchyma, but not more easily than into the ordinary sinuses. In injected preparations, the endothelial cells of this particular sinus appear to have no phagocytic ability.

5. Afferent and efferent lymphatic vessels, and blood vessels

The afferent lymphatic vessels pass obliquely through the whole surface of the capsule except for the hilus to enter into the subcapsular sinus (Fig. 25). The one or two efferent lymphatic vessels gather lymph of the medullary sinuses to leave through the hilus. But, in the large long lymph nodes, for example *Lnn. mesenterici communes*, there are many efferent lymphatic vessels. Their walls consist of a layer of flat endothelial cells and poor connective tissues, and show various sizes according to conditions.

The arteries enter into the lymph node at the hilus to branch off in the medullary trabeculae and after a short distance, to run into the medullary cords to nourish the lymphatic parenchyma. The arteries at the hilus are generally 50-150 μ in diameter, and have several layers of smooth muscular cells and thin adventitia. The arterioles in the lymphatic parenchyma have only one layer of the smooth muscular cells.

The venules, gathering the capillaries of the lymphatic parenchyma, pass through the medullary cords to leave the lymph node through the hilus. The veins at the hilus have few layers of muscular cells and thin adventitia, but sometimes the smooth muscular layer is absent. On the other hand, the venules in the lymphatic parenchyma always lack the smooth muscular cells.

In the cortical mass, there are found the so-called "post-capillary veins" which have a peculiar character (SMITH and HENON); the endothelial cells are somewhat cuboidal and at times the small lymphocytes pass through the wall to migrate into or from the post-capillary vein (Figs. 33 and 34). In the sinuses, blood vessels are absent (Fig. 26). In the secondary nodules, there are arterioles and capillaries, but no veins.

The lymphatic parenchyma except for the secondary nodule is distinctly distinguished into 2 parts, proper and varied, on the basis of the difference of various cell distributions. These findings are described in detail in the last chapter.

B. Structural Variations with Relation to the Differentiation

The above-mentioned several structures are by no means to be found quite completely in all lymph nodes; sometimes the trabeculae, secondary nodules, intermediate and medullary sinuses are absent even in the adult cat. Accordingly, the medullary cords are also sbsent, and simultaneously, nondifferentiation of the medulla, vagueness of the cortico-medullary distinction and unusual arrangement of the cortex are observed. Such findings, additional to a usual pattern of the lymph node, should be treated as a nondifferentiation of the lymph nodes as discussed later on.

For the following observation, the writer made use of the cross-sectioned or serial preparations through the hilus of the lymph node in the cat more than 4 months old.

1. Node types classified by the degree of differentiation

According to the order of differentiation, the lymph nodes were divided into 5 types, especially by the arrangement and distinction of the cortex and medulla, as shown in tables 2, 3, 4 and 5, and schema 2 (cf. Plates II, III and IV).

TABLE 2. *Classification of Each Type as Regards Degree of Differentiation*

	EMBRYONIC		IMMATURE	MATURE	
	D. I	D. II	D. III	D. IV	D. V
Capsule	+	+	+	+	+
Trabecula	−	−	−~+	+	+
Subcapsular Sinus	+	+	+	+	+
Intermediate Sinus	−	−	−	+	+
Medullary Sinus	−	±	+	+	+
Distinction of Cortex and Medulla	Impossible	Not distinct	Distinct	Distinct	Distinct
Cortex Arrangement to Medulla	·	·	One side	Partially cover	Completely cover
Secondary Nodule	−~+	−~+	−~+	−~+	+
Medullary Nodule	−	−	−	−~+	−~+

Remarks: −; Absent, +; Present

TABLE 3. *Existence of Trabeculae of Each Type*

	D. I	D. II	D. III	D. IV	D. V
−	29	24	42	0	0
+	0	0	73	160	434

TABLE 4. *Existence of Secondary Nodules of Each Type*

	D. I	D. II	D. III	D. IV	D. V
−	22	6	20	3	0
+	7	18	95	157	434

TABLE 5. *Existence of Medullary Nodules of Each Type*

	D. I	D. II	D. III	D. IV	D. V
−	29	24	115	135	251
+	0	0	0	25	183

D. I type: Consisting of the capsule, subcapsular sinus and a spherical lymphatic parenchyma. There is no distinction between the cortex and medulla. The trabeculae and medullary nodules are absent, and in many cases (75.9%), secondary nodules also are not found.

D. II type: In addition to the structure of D. I type, medullary sinus-like invasions of the subcapsular sinus are found in the spherical lymphatic mass near the hilus, but the formation

of the medullary cords is unclear. The trabeculae and medullary nodules are absent, and in some cases (25%), secondary nodules also are not found.

D. III type: Distinct formation of the medullary cords and clear demarcation between the cortex and medulla are observed. The cortex forms one spherical or oval nodule and does not cover the medulla. So the cortex and medulla are respectively situated at the opposite sides of the node. Medullary nodules are non-existent. The trabeculae are found in 63.5% of this type, but secondary nodules are absent in 17.4%.

D. IV type: The cap-shaped cortex partially covers the medulla. The trabeculae appear in all nodes of this type. Secondary nodules are absent in 1.9%. Medullary nodules appear in 15.6% of this type.

D. V type: This type has been described in the literature as an ordinary structure of the normal lymph node; the cortex nearly completely covers the medulla. Trabeculae and secondary nodules appear in all cases. Medullary nodules also are observed in about a half of the cases of this type.

It is suggested that amongst these types, D. I and D. II are embryonic nodes, D. III is an immature node, and D. IV and D. V are mature nodes as discussed below.

2. Relation between each type and occurrence groups

The appearances of the five types as regards the degree of differentiation were found not to be related with regional groups, but to be related intimately with occurrence groups, as shown in table 6.

TABLE 6. *Relation between Each Type and Occurrence Groups*

OCCURRENCE GROUPS	EMBRYONIC		IMMATURE	MATURE	
	D. I	D. II	D. III	D. IV	D. V
O. I	0	0	10	124	425
O. II	3	3	25	17	7
O. III	26	21	78	19	2

In O. I group, the mature nodes (types D. IV and D. V) appear exclusively, but immature ones (D. III type) are found in insignificant number. On the other hand, the embryonic nodes (types D. I and D. II) are absent.

In O. II group, the immature nodes appear principally, though the mature nodes are found in somewhat less than a half of the cases. Moreover, the embryonic nodes appear rather frequently.

In O. III group, the immature nodes are principally found. Furthermore, the embryonic nodes appear more often than the mature ones.

In short, undifferentiated forms of the lymph node were frequently observed in the O. II group, which occurs inconstantly, and in the O. III group, which is an accessory one of the other main nodes, even in the adult cat.

C. Regional Differences of Lymph Nodes

As mentioned in the above section, the O. II and O. III groups comprise mainly the embryonic and immature lymph nodes which had no ordinary structures of the mature ones;

accordingly the O. I group, which consists exclusively of mature lymph nodes, was selected for observing regional difference, and further the materials from animals over 4 months old were used for escaping the danger that some results may be disturbed by age-difference.

1. Supporting framework

a) The capsule is usually thin in the cat lymph nodes, so that no regional difference can be found.

b) The cortical trabeculae; the degrees of development are relatively divided into three, −: absent, +: fine wedge-shaped, ++: thick septum-shaped, in section preparations. The occurrences in each regional group are presented in table 7.

TABLE 7. *Relation between Occurrences of Cortical Trabecula and Regional Groups*

REGIONAL GROUPS	−	+	++
Submandibular	•	38	7
Retropharyngeal	•	15	11
Parotid	•	30	2
Cervical	•	42	5
Axillar	•	47	13
Inguinal	•	27	4
Popliteal	•	21	6
Lumbar	5	20	1
Iliac	•	22	7
Gastrolienal	•	38	4
Hepatogastric	•	19	1
Small Intestinal	•	5	30
Large Intestinal	•	43	11
Mediastinal	1	19	24
Tracheobronchial	•	29	2

As shown in the table, the occurrence is not marked, but the lymph nodes with thick cortical trabeculae appear more numerously in the retropharyngeal, small intestinal and mediastinal groups than in the other groups (Figs. 41 and 42).

c) The medullary trabeculae: four developmental conditions are relatively categorized: −: absent; +: scarce presence of fine trabeculae; ++: moderate or thick trabeculae found in about a half of the medullary sinuses and +++: moderate or thick trabeculae found in nearly all of the medullary sinuses.

As shown in table 8, regional differences are markedly found and occurrence falls into two classes: 1) well developed medullary trabecular system is more often found in the submandibular, retropharyngeal, cervical, axillar, inguinal, popliteal, small intestinal and mediastinal groups. 2) A poorly developed system of medullary trabeculae is observed in the

TABLE 8. *Relation between Occurrences of Medullary Trabecula and Regional Groups*

REGIONAL GROUPS	−	+	++	+++
Submandibular	•	1	14	30
Retropharyngeal	•	•	6	20
Parotid	•	16	13	3
Cervical	•	2	25	20
Axillar	•	2	29	29
Inguinal	•	•	20	11
Popliteal	•	•	12	15
Lumbar	•	22	4	•
Iliac	•	17	12	•
Gastrolienal	•	24	18	•
Hepatogastric	•	9	11	•
Small Intestinal	•	•	16	19
Large Intestinal	•	20	23	11
Mediastinal	•	3	18	23
Tracheobronchial	•	22	5	4

parotid, lumbar, iliac, gastrolienal, hepatogastric, large intestinal and tracheobronchial groups (Figs. 42 and 51).

It could not be clearly concluded that the trabecular system in superficial lymph nodes is more developed than that in deep ones.

2. Lymphatic parenchyma

a) Cortex

i) Development of cortex layer

The appearances of the cortex layer are distinguished into the following four developmental types: C. I: continued thick layer (Figs. 11 and 27); C. II: large nodular layer (Figs. 16 and 29); C. III: mixed form with C. II and C. IV (Fig. 10) and C. IV: small nodular or continuous thin layer (Figs. 14 and 31).

As presented in table 9, in only the mediastinal group, is the cortex poorly developed, but no markedly regional difference is found in the other groups. Generally, the cortex of the cat lymph nodes is well developed.

ii) Disordered arrangement of the cortex layer

Irregularity of the cortex arrangement is occasionally found in the cat lymph nodes. The occurrences in the regional groups are presented in table 10.

As shown in the table, the disorder of the cortex arrangement is more observed in the retropharyngeal, small intestinal and large intestinal groups than in the other ones (Fig. 15). The tendency may have some relationship with the well developed cortical trabeculae and cortical mass.

TABLE 9. *Relation between Development of Cortex Layer and Regional Groups*

REGIONAL GROUPS	C. I	C. II	C. III	C. IV
Submandibular	9	34	2	•
Retropharyngeal	5	14	6	1
Parotid	9	19	3	1
Cervical	13	23	9	2
Axillar	2	29	23	6
Inguinal	4	20	4	3
Popliteal	4	20	3	•
Lumbar	•	16	5	5
Iliac	7	15	7	•
Gastrolienal	10	24	7	1
Hepatogastric	2	8	9	1
Small Intestinal	6	24	4	1
Large Intestinal	•	29	17	8
Mediastinal	•	2	20	22
Tracheobronchial	17	10	4	•

TABLE 10. *Relation between Disorder of Cortex Arrangement and Regional Groups*

REGIONAL GROUPS	ORDER	DISORDER
Submandibular	39	6
Retropharyngeal	10	16
Parotid	32	•
Cervical	42	5
Axillar	49	11
Inguinal	29	2
Popliteal	23	4
Lumbar	26	•
Iliac	22	7
Gastrolienal	39	3
Hepatogastric	19	1
Small Intestinal	8	27
Large Intestinal	35	19
Mediastinal	36	8
Tracheobronchial	26	5

b) Medulla

i) Width of the medulla

The width of the medulla falls into three classes, +: more narrow than the cortex; ++: about equal to the cortex and +++: wider than the cortex.

As shown in table 11, the regional differences in width of the medullae are conspicuous. Occurrences may be divided into three groups: 1) the narrow medulla is most often found in the parotid, cervical, axillar, inguinal, popliteal, gastrolienal and tracheobronchial groups. 2) The moderate one is most often observed in the submandibular, retropharyngeal, lumbar, iliac and hepatogastric groups. 3) The wide medulla is conspicuously found in the small intestinal, large intestinal and mediastinal groups. Generally, the wide medulla is more found in the lymph nodes of the body cavity than in those of the superficial area, but exception must be made of the

TABLE 11. *Relation between Width of Medulla and Regional Groups*

REGIONAL GROUPS	+	++	+++
Submandibular	18	19	8
Retropharyngeal	5	12	9
Parotid	28	3	1
Cervical	35	9	3
Axillar	25	19	16
Inguinal	19	6	6
Popliteal	16	8	3
Lumbar	9	10	7
Iliac	5	16	8
Gastrolienal	31	8	3
Hepatogastric	5	11	4
Small Intestinal	2	10	23
Large Intestinal	8	20	26
Mediastinal	2	8	34
Tracheobronchial	25	6	0

TABLE 12. *Relation between Occurrence of Medullary Nodule and Regional Groups*

REGIONAL GROUPS	−	+	
Submandibular	7	38	(37)
Retropharyngeal	2	24	(22)
Parotid	29	3	(3)
Cervical	25	22	(19)
Axillar	38	22	(12)
Inguinal	21	10	(8)
Popliteal	11	16	(15)
Lumbar	26	0	(0)
Iliac	28	1	(1)
Gastrolienal	35	7	(5)
Hepatogastric	13	7	(7)
Small Intestinal	13	22	(22)
Large Intestinal	39	15	(15)
Mediastinal	33	11	(5)
Tracheobronchial	29	2	(2)

( ): Number of lymph nodes which have medullary nodules including a secondary nodule

gastrolienal and tracheobronchial groups which are situated in the body cavity (Plates III and IV).

ii) Breadth of the medullary cords

The breadth of the medullary cords is widely variable not only among the regional groups but also in one and the same lymph node, so that the regional difference is not striking. Generally, the medullary cords are more wider and denser near the cortex. In some nodes, the cords are nearly completely occupied with fatty tissues.

iii) Occurrences of the medullary nodules

As already mentioned, the medullary nodules appeared in over one-third of the cases of mature lymph nodes. The local differences are conspicuous and may be distinguished into three groups.

As presented in table 12, 1) the conspicuous occurrences (over 65%) are found in the submandibular, retropharyngeal and small intestinal groups. 2) The moderate ones (about 60–30%) are observed in the cervical, axillar, inguinal, popliteal, hepatogastric and large intestinal groups. 3) The scarce occurrences or non-existence are found in the other groups (Plates III and IV).

3. Secondary nodules

As already stated, the secondary nodules appear accompanying the cortical mass or nodule, principally at the capsular side, but sometimes they appear at the medullary side of the cortex and in the medullary nodule.

a) Occurrences of secondary nodule

The occurrences of secondary nodules in the cortex do not markedly differ among the regional groups. On the other hand, in the medulla, regional differences in the occurrences are marked as shown in parentheses of table 12. Namely, out of 200, there are 173 lymph nodes which have medullary nodules including the secondary nodules. The tendency of the regional differences coincides with that of the medullary nodules.

b) Types of secondary nodules

The secondary nodules show quite various forms under normal conditions as described by EHRICH ('29–'31), KAWAKAMI ('58–'59) and many other investigators. Actually, it was very difficult reasonably to fit these various forms into the descriptions which they had presented. The present writer classified the secondary nodules morphologically into four types, especially after referring to KAWAKAMI's and EHRICH's descriptions, as follows.

S.N. I (Progressive solid secondary nodule): This type corresponds to KAWAKAMI's "solid type" and is similar to EHRICH's "solid secondary nodule". This size ranges from 70 to 150 μ. This nodule has no distinct light center and consists nearly exclusively of small lymphocytes. But, some lymphoblasts lie scattered, or aggregate at the entrance of the arteriole (Fig. 43).

S.N. II (The so-called FLEMMING's secondary nodule): This type has a large light center consisting nearly entirely of lymphoblasts and shows variable sizes, from 200 to 500 μ. Mitoses are frequently observed. Differently to the typical FLEMMING's type as named by EHRICH, the dark zone of this type is generally cap-like in shape and sometimes becomes thin to be similar to CONWAY's "bare secondary nodule" (Figs. 44, 45, 49 and 50).

S.N. III (KAWAKAMI's "mature secondary nodule"): This type ranges from 200 to 400 μ in size and may also correspond to EHRICH's "transition form". But, the light center of this

type consists of a dark part, aggregation of lymphoblasts at the entrance side of the arteriole (KAWAKAMI's "lymphoblastic portion"), and a pale part, occupied by cells resembling reticular cells at the dark zone side (KAWAKAMI's "reticular portion"). It is proved by the observation of serial preparations that the dark zone is cap-ilke in shape and somewhat more developed than that of S.N. II type (Fig. 46). Sometimes, the dark zone becomes loosely unclear.

S.N. IV (Regressive solid secondary nodule): This type is similar to type S.N. I, but larger in size (200 to 300 μ) than the latter. This nodule consists nearly exclusively of small lymphocytes, but nuclear debris, macrophages, and hyaline substances, which show perhaps degeneration of the blood vessels, are also found in the center (Fig. 47).

The nuclear debris and the macrophages, which phagocytosed the debris, are more or less observed in S.N. II and III types but rarely in S.N. I type. The plasma cells and RUSSELL's bodies are also found in the pale part of S.N. III type (Fig. 59), but mast cells are absent.

c) Appearances of each type of secondary nodules in the cortex

The four types of secondary nodules appear in the cortex of the nodes of each regional group, as shown in table 13.

The secondary nodules show generally the same types in one lymph node as revealed by observation of serial preparations, so the most usual type in each lymph node was used for securing data in this table.

TABLE 13. *Relation between Type of Secondary Nodule and Regional Groups* (in the Cortex)

REGIONAL GROUPS	S.N. I	S.N. II	S.N. III	S.N. IV
Submandibular	•	9	36	•
Retropharyngeal	•	4	22	•
Parotid	•	3	29	•
Cervical	•	6	40	1
Axillar	•	5	55	•
Inguinal	•	7	23	1
Popliteal	•	3	24	•
Lumbar	•	1	23	2
Iliac	•	6	21	2
Gastrolienal	•	8	32	2
Hepatogastric	•	4	14	2
Small Intestinal	•	4	29	2
Large Intestinal	•	4	49	1
Mediastinal	•	6	34	4
Tracheobronchial	•	2	28	1

It will be noted that no regional differences are found. In most groups, S.N. III type is the principal one, S.N. II and IV types appear scarcely. On the other hand, S.N. I type is not found in the cases over 4 months old.

d) Appearances of each type of secondary nodules in the medulla

In the medulla, the secondary nodules appeared in 173 out of 549 examined lymph nodes of the cat over than 4 months old. However, a typical feature of S.N. III type is rarely found in the medulla. Accordingly, some secondary nodules, whose light center consists of mixed lymphoblasts, reticular cells and macrophages, were treated as S.N. III type in this table.

TABLE 14. *Relation between Type of Secondary Nodule and Regional Groups* (in the Medulla)

REGIONAL GROUPS	S.N. I	S.N. II	S.N. III	S.N. IV
Submandibular	1	5	29	2
Retropharyngeal	1	2	9	10
Parotid	1	·	1	1
Cervical	1	1	5	12
Axillar	1	·	4	7
Inguinal	·	1	5	2
Popliteal	1	4	7	3
Lumbar	·	·	·	·
Iliac	·	·	1	·
Gastrolienal	1	·	2	2
Hepatogastric	·	2	2	3
Small Intestinal	·	5	11	6
Large Intestinal	2	2	2	9
Mediastinal	·	·	5	·
Tracheobronchial	·	·	1	1

As shown in table 14, regional differences are not detectable as regards the occurrences of each type. S.N. I and IV types appear more numerously in the medulla than in the cortex.

The secondary nodules of the medulla are less than 200 μ in diameter, usually about 100 μ, and distinction between the dark zone and light center is more indefinite than that of the cortex (Figs. 53–58).

e) Sizes of the secondary nodules of the cortex

In size, the secondary nodules of the cortex are variable, but diameter usually measures from 300 to 400 μ. However, large ones, reaching over 500 μ, are sometimes found in the submandibular, retropharyngeal, small and large intestinal groups (Figs. 15 and 44).

4. Lymphatic sinuses

a) Subcapsular sinuses

No conspicuous regional differences are found as to the breadth of the subcapsular sinuses.

They are usually narrow, but somewhat wide sinuses are sometimes observed in the lymph node whose secondary nodules are not well developed.

b) Intermediate sinuses

The breadth is usually narrow and there are no regional differences.

c) Medullary sinuses

The medullary sinuses have variable breadth and variable quantity of free cells. But, in the table, the breadth is relatively divided into three standards, +: generally more narrow than 40 μ: ++: 40-70 μ: +++: generally wider than 70 μ. All nodes, where medulla could be observed, were used for observing regional difference as regards the breadth of the sinuses.

TABLE 15. *Relation between Breadth of Medullary Sinus and Regional Groups*

REGIONAL GROUPS	+	++	+++
Submandibular	•	12	36
Retropharyngeal	4	6	18
Parotid	17	15	9
Cervical	15	18	14
Axillar	22	20	24
Inguinal	12	8	11
Popliteal	21	3	4
Lumbar	22	8	2
Iliac	6	15	9
Gastrolienal	10	19	20
Hepatogastric	•	11	16
Small Intestinal	7	13	19
Large Intestinal	•	8	46
Mediastinal	7	27	16
Tracheobronchial	17	9	5

As shown in table 15, the breadth of the medullary sinuses is very variable. Not conspicuously, but wide sinuses are more often found in the submandibular, retropharyngeal, hepatogastric, small and large intestinal groups. On the other hand, narrow sinuses are more observed in the parotid, popliteal, lumbar and tracheobronchial groups. The other groups showed so markedly variable breadth, therefore no regional difference was detected.

d) Reticular fiberless sinuses

The reticular fiberless sinuses show variable width and variable quantity of free cells. On the other hand, the occurrence of particular sinuses is observed somewhat to vary among the regional groups.

As presented in table 16, the reticular fiberless sinuses appear in 294 nodes out of 549 (53.6%) their occurrence being more conspicuously found in the submandibular, retropharyngeal, gastrolienal, hepatogastric, small intestinal, large intestinal, mediastinal and tracheobronchial

TABLE 16. *Relation between Occurrence of Reticular Fiberless Sinus and Regional Groups*

REGIONAL GROUPS	−	+
Submandibular	20	25
Retropharyngeal	4	22
Parotid	16	16
Cervical	25	22
Axillar	43	17
Inguinal	14	17
Popliteal	16	11
Lumbar	14	12
Iliac	16	13
Gastrolienal	18	24
Hepatogastric	5	15
Small Intestinal	11	24
Large Intestinal	24	30
Mediastinal	20	24
Tracheobronchial	9	22

groups than in the other groups.

In short, conspicuous regional difference was found as to the development of the medullary trabeculae, disorder of the cortex arrangement, width of the medulla, occurrences of the medullary nodules and of the secondary nodules of the medulla. Some regional differences were also detected as to the development of the cortical trabeculae, appearances of the cortex layer, width of the medullary sinuses and occurrences of the reticular fiberless sinuses. But, no regional differences were noted as to the other structures.

Between the lymph node of type Z and that of type ZT, which were macroscopically classified on the basis of the appearances of the afferent lymphatic vessels, no concrete differences were found in these observations.

D. Age-Difference of Lymph Nodes

For observing age-difference, 13 cases, whose lymph nodes were nearly completely got from all locations, were selected and observed in an attempt to avoid formation of conclusions based on data effected by above-mentioned regional differences. Moreover, the lymph nodes of the inconstant main (O. II group) and accessory nodal (O. III group) groups, which so frequently showed embryonic and immature features, were omitted in the observations described in this chapter.

1. Differentiation

Occurrence of five types of lymph nodes as regards the degree of differentiation are arranged according to age of animals in table 17.

It is to be seen, at one day old, that the embryonic nodes are not found, but the immature nodes (D. III) supply more than a half of all nodes. On the other hand, the mature ones (D. IV and D. V) are observed in less than half of the nodes, especially D. V type was found in only one node. With advance in age, the immature nodes are fewer and fewer, whilst the mature ones increase in number. However, at six days old, rather many immature nodes are found (Figs. 21 and 22). At 2 months old, the tendency of occurrence of each type becomes similar to the adult cases and afterwards, no chronological changes are found with increased age.

In the retropharyngeal and small intestinal groups, the immature nodes are never found after birth. That is to say, these groups show more early development than other groups.

TABLE 17. *Relation between Types as regards Degree of Differentiation and Age*

EXP. NO.	AGE	D. I	D. II	D. III	D. IV	D. V
2	1 Day	·	·	16	13	1
4	6 Days	·	·	9	15	6
8	1.5 Months	·	·	1	20	15
13	2 "	·	·	·	6	18
20	4 "	·	·	1	7	25
25	7 "	·	·	1	5	14
26	7 "	·	·	·	3	16
28	8 "	·	·	·	16	19
29	10 "	·	·	·	15	33
37	2 Years	·	·	·	9	24
42	3 "	·	·	·	9	39
48	8 "	·	·	1	7	22
49	16 "	·	·	1	7	27

2. Supporting framework

a) The capsule appears to become thicker with advance in age, but no conspicuous changes are found (compare Figs. 22 and 28).

b) The postnatal development of the cortical trabeculae is shown in table 18.

TABLE 18. *Relation between Development of Cortical Trabeculae and Age*

EXP. NO.	AGE	−	+	++
2	1 Day	25	5	·
4	6 Days	18	12	·
8	1.5 Months	1	33	2
13	2 "	·	18	6
20	4 "	·	22	11
25	7 "	1	15	4
26	7 "	·	10	9
28	8 "	2	25	8
29	10 "	·	32	16
37	2 Years	1	22	10
42	3 "	·	31	17
48	8 "	·	23	7
49	16 "	·	23	12

At one day and six days old, the cortical trabeculae are not to be found about 80% and 60% respectively (Figs. 22 and 24).

At 1.5 months old, most nodes have the cortical trabeculae. But, thick septum-like trabeculae are found only in the small and large intestinal groups.

In cases over than 2 months old, there are the usual developed cortical trabeculae and afterwards no difference with age is found.

c) The development of the medullary trabeculae is chronologically presented in table 19.

TABLE 19. *Relation between Development of Medullary Trabeculae and Age*

EXP. NO.	AGE	−	+	++	+++
2	1 Day	14	16	•	•
4	6 Days	5	23	2	•
8	1.5 Months	•	15	17	4
13	2 »	•	6	10	8
20	4 »	•	13	15	5
25	7 »	•	2	14	4
26	7 »	•	4	8	7
28	8 »	•	15	17	3
29	10 »	•	8	24	16
37	2 Years	•	11	14	8
42	3 »	•	2	13	33
48	8 »	•	11	17	2
49	16 »	•	14	18	3

At one and six days old, the trabeculae are non-existent in many nodes (Figs. 22 and 24).

At 1.5 months old, trabeculae are developed in usual manner. Afterwards, no chronological age differences are found.

The postnatal development of the medullary trabeculae appears to be more rapid in the groups, which have well developed trabecular systems, than in the groups, which have poorly developed trabecular ones.

3. Lymphatic parenchyma

a) Cortex

i) Appearances of the cortex

The shape of the cortex layer is related intimately with the above-mentioned types as regards the degree of differentiation.

Namely, at one day and six days old, the immature nodes (D. III) appear frequently, so that the cortex layer shows the form of one cortical nodule (Figs. 21 and 22). Moreover, a pearl-ring-shaped cortex layer, which consists of one well developed cortical nodule and thin cortical ring, is sometimes observed in D. IV and D. V types showing so-called mature cortex arrangement (Figs. 23 and 24). Such pearl-ring-shaped cortex occurs in 50%, 28.6% and 8.6% at one day, six days and 1.5 months old, respectively. At 2 months old, such form

is not found. At 4 months old, the cortex appears to have developed to adult-like size.

In cases more than 2 months old, the cortex layer shows the usual tendencies of the adult cases and no age difference is found with advance in age.

In brief, the cortex which is composed of one cortical nodule or a pearl-ring-shaped layer signifies an immature form of the lymph node.

ii) Disorder of the cortex arrangement

Irregularity in the cortex arrangement are absent until 1.5 months old. In cases over 2 months old, such disorders are found, but no changes with age are detected as to the degree of the occurrence.

b) Medulla

i) Width of the medulla

As regards width of the medulla in relation to the cortex, no definite tendency is found with increase in age.

ii) Breadth of the medullary cords

TABLE 20. *Relation between Breadth of Medullary Cords and Age*

EXP. NO.	AGE	+	++	+++
2	1 Day	25	5	•
4	6 Days	11	14	5
8	1.5 Months	13	11	12
13	2 „	3	12	9
20	4 „	3	6	24
25	7 „	4	7	9
26	7 „	4	6	9
28	8 „	7	10	18
29	10 „	10	16	22
37	2 Years	13	10	10
42	3 „	10	19	19
48	8 „	7	11	12
49	16 „	3	14	18

As shown in table 20, individual differences are conspicuous, but the breadth is less at one day and six days old than in cases more than 1.5 months old. Generally, free cells in the medullary cords increase with advance in age, but in cases older than 1.5 months they become variable according to unknown conditions without any definite tendency with increase in age becoming evident.

iii) Occurrences of the medullary nodule

As presented in table 21, at one day old, no medullary nodule is to be found (Fig. 23).

At six days old, one appears in only one node of the small intestinal group.

At 1.5 months old, the nodules are found in six nodes of the retropharyngeal, small and large intestinal groups.

TABLE 21. *Relation between Occurrence of Medullary Nodules and Age*

EXP. NO.	AGE	−	+
2	1 Day	30	•
4	6 Days	29	1
8	1.5 Months	30	6
13	2 "	17	7
20	4 "	27	6
25	7 "	10	10
26	7 "	10	9
28	8 "	24	11
29	10 "	28	20
37	2 Years	25	8
42	3 "	18	30
48	8 "	27	3
49	16 "	33	2

In cases older than 2 months, the occurrence shows the usual tendency of adult cases, but no conspicuous changes are observed with increase in age. However, in cases over 8 years old, few medullary nodules appear.

4. Secondary nodules

a) Occurrences of secondary nodules

The secondary nodules of the medulla develope in company with the medullary nodules, so in this paragraph is presented a description of only secondary nodules of the cortex. The categories are three: −: absent; +: only a few present and ++: frequent.

As shown in table 22, at one day old, the secondary nodules are absent in most cases (80.3%) (Figs. 23 and 24), but they are found in 5 nodes of the retropharyngeal, cervical, gastroliental, small intestinal and mediastinal groups.

At six days old, such nodule is also absent in some cases (26.7%) (Fig. 22).

At 1.5 months old, all lymph nodes have nodules, but the number of secondary nodules present is poor in each lymph node.

In cases older than 2 months, numerous secondary nodules occur in most nodes and no chronological changes are found with increase in age.

b) Types and sizes of the secondary nodules in the cortex

As presented in table 23, at one day and six days old, secondary nodules which appeared measure 70–150 μ in size and fall into S.N. I type in all cases.

At 1.5 months old, out of the appeared secondary nodules, S.N. I type is found in less than a half of the nodes (Fig. 43), while S.N. II type, ranged 200–400 μ in size, appears in more than a half of the nodes.

At 2 months old, S.N. II type is principally found (Fig. 45), but in some nodes S.N. I type also appears. It is noteworthy that a secondary nodule of S.N. II type in the retropharyngeal

TABLE 22. *Relation between Age and the Occurrence of Secondary Nodules in the Cortex*

EXP. NO.	AGE	−	+	++
2	1 Day	25	5	·
4	6 Days	8	22	·
8	1.5 Months	·	12	24
13	2 »	·	1	23
20	4 »	·	·	33
25	7 »	·	·	20
26	7 »	·	·	19
28	8 »	·	·	35
29	10 »	·	·	48
37	2 Years	·	·	33
42	3 »	·	·	48
48	8 »	·	1	29
49	16 »	·	·	35

TABLE 23. *Relation between Age and Type of Secondary Nodule*

EXP. NO.	AGE	S.N. I	S.N. II	S.N. III	S.N. IV
2	1 Day	5	·	·	·
4	6 Days	22	·	·	·
8	1.5 Months	16	20	·	·
13	2 »	6	18	·	·
20	4 »	1	9	23	·
25	7 »	1	1	18	·
26	7 »	·	4	15	·
28	8 »	·	5	30	·
29	10 »	·	4	43	1
37	2 Years	·	·	33	·
42	3 »	·	·	48	·
48	8 »	·	2	20	8
49	16 »	·	2	28	5

group reaches to 500 μ in size.

In cases more than 4 months old, the occurrences of each type show the usual tendency of the adult cases, but S.N. IV type appears somewhat more fruquently in cases 8 years old and over (Fig. 47).

c) Types and sizes of the secondary nodules in the medulla

The occurrences of secondary nodules in the medulla coincide with those of the medullary nodules. The types are as follows (Plate X).

At one day old, no secondary nodule appears in the medulla.

At six days old, one secondary nodule is found only in the small intestinal group and shows to be S.N. I type; it measures 100 μ in diameter.

At 1.5 months old, appeared nodules are also S.N. I type, ranging from 70 to 150 μ in size.

At 2 months old, appeared secondary nodules, measuring 100-200 μ in size, belong to S.N. II type.

At 4 months old, S.N. II type becomes predominant, but S.N. III and S.N. IV types also appear.

In cases more than 4 months old, types of appeared secondary nodules are variable and no chronological changes are evident with advance in age.

5. Lymphatic sinuses

a) Subcapsular sinus

In most nodes of one day and six day old cases, the subcapsular sinus has a wide uniform breadth (Figs. 21 and 23). With advanced development of the secondary nodules and cortical mass, the sinus becomes narrow with advance in age. In cases more than 2 months old, no age differences are detected. Usually, the subcapsular sinus is of narrow width, but sometimes it becomes wide under unknown conditions.

b) Intermediate sinuses

As to the breadth, there is a tendency similar that of the subcapsular sinuses.

c) Medullary sinuses

The breadth is variable and no age differences are found. On the other hand, the sinus reticular cells and free cells appear to increase in number with advance in age until 1.5 months old, but no chronological changes are found among cases over 2 months old.

d) Reticular fiberless sinuses

No chronological changes can be pointed out with advance in age.

To summarize the chapter briefly, age-differences were found as to the degree of differentiation of various parts, development of supporting framework and of the cortex layer, disorder of the cortex arrangement, occurrences of the medullary nodules, occurrences and types of the secondary nodules and breadth of the subcapsular sinus.

Moreover, regional differences in degree of maturity were detected as to the cortex layer, trabeculae, medullary nodules and secondary nodules among some regional groups. Such regional differences owing to the degree of maturity continue, under such conditions as lymph nodes show incomplete structure, from birth till 4 months old, but over 4 months old, no chronological changes are found with advance in age, and the ordinary regional differences, as pointed out in the present above chapter, become conspicuous.

E. Fatty Involution in Lymph Nodes

The fatty tissues found in the lymph node have been usually treated in the literature as fatty involutions appearing with advanced age. In this chapter, are briefly described the relations between the fatty tissues appearing in the lymph nodes and age, or location.

1. Relation between fatty involution and regional groups

For this observation, the lymph nodes of the O. I group in cats over 4 months old were used. The degrees of occurrence of the fatty tissues were divided into four categories: −: absent; +: scatteredly present; ++: occupied about a half of the medulla and +++: occupied nearly all of the medulla.

TABLE 24. *Relation between Fatty Involution and Regional Groups*

REGIONAL GROUPS	−	+	++	+++
Submandibular	39	10	•	•
Retropharyngeal	19	9	•	•
Parotid	9	14	10	7
Cervical	31	9	6	1
Axillar	28	20	9	4
Inguinal	21	9	3	1
Popliteal	2	11	8	6
Lumbar	4	5	12	11
Iliac	6	13	5	6
Gastrolienal	30	18	1	•
Hepatogastric	24	2	•	•
Small Intestinal	33	2	•	•
Large Intestinal	55	2	•	•
Mediastinal	27	12	5	4
Tracheobronchial	15	10	6	•

As shown in table 24, two groups of nodes are formed according to the degrees of occurrence of the fatty tissues; conspicuous occurrences of fatty tissues are found in the parotid, cervical, axillar, inguinal, popliteal, lumbar, iliac, mediastinal and tracheobronchial groups. Poor occurrences are observed in the other groups (Plates III and IV).

2. Relation between fatty involution and age

The occurrence of fatty tissues is chronologically ranged in table 25.

At one day old, no fatty tissues are found in any lymph node.

At six days old, a few fatty tissues appear in one node of the inguinal group at first.

At 1.5 months old, fatty tissues appear poorly in 8 nodes of the axillar, popliteal, lumbar, iliac and mediastinal groups and moderately in one node of the mediastinal group.

At 2 months old, such tissue occurs poorly in 4 nodes of the popliteal, mediastinal and tracheobronchial groups and moderately in one node of the lumbar group.

In the groups, exhibiting only poor fatty tissues in the adult cat, the first appearance is at 4 months old in 4 nodes of the retropharyngeal and gastrolienal groups.

In cases older than 4 months, the occurrences are conspicuous, but somewhat variable. Later, no significant chronological fatty involutions are evident with advance in age.

3. Relation between fatty involution and occurrence groups

As already mentioned, even in the lymph nodes of the adult cats, the embryonic and

TABLE 25. *Relation between Fatty Involution and Age*

EXP. NO.	ACE	−	+	++	+++
2	1 Day	30	•	•	•
4	6 Days	29	1	•	•
8	1.5 Months	27	8	1	•
13	2 »	19	4	1	•
20	4 »	15	10	6	2
25	7 »	18	•	2	•
26	7 »	14	2	2	1
28	8 »	16	3	14	2
29	10 »	19	19	6	4
37	2 Years	25	5	2	1
42	3 »	42	5	•	1
48	8 »	19	8	2	1
49	16 »	25	6	2	2

immature forms were found and such nondifferentiated lymph nodes appeared principally in the writer's O. II and O. III group. The fatty tissues are also found in such embryonic and immature nodes.

As shown in tables 26 and 27, in the lymph nodes of the O. II and O. III groups in the adult cat, the fatty involutions appear rather more conspicuously than those of the O. I group (Plates II, III and IV).

To be brief, conspicuous regional differences were pointed out as to the occurrences of the fatty tissues. Differences by age were also found from birth till 4 months old, but over

TABLE 26. *Relation between Fatty Involution and Occurrence Groups*
(Regional Groups of Much Fatty Involution)

OCCURRENCE GROUPS	−	+	++	+++
O. I	143	103	64	40
O. II	11	9	8	12
O. III	13	12	10	27

TABLE 27. *Relation between Fatty Involution and Occurrence Groups*
(Regional Groups of Slight Fatty Involution)

OCCURRENCE GROUPS	−	+	++	+++
O. I	200	43	1	•
O. II	6	5	6	•
O. III	40	14	19	16

4 months old, no chronological changes were proved with advance in age. Moreover, the embryonic and immature lymph nodes, found in the adult cats, showed more conspicuous fatty involutions than the other ordinary mature ones.

F. Two Divisions of the Lymphatic Parenchyma Other than the Secondary Nodules

The lymphatic parenchyma, consisting of cortical mass (or nodule), medullary cords and medullary nodules, has been considered to have a uniform functional character, though there is a difference between the cortex and medulla in the matter of reaction speed. But the writer classified the lymphatic parenchyma except for the secondary nodule into two parts according to the distribution of several kinds of cells, as described in the following.

1. Cytological and cytochemical characters of the several kinds of cells

a) Small lymphocytes, measured 4–6 μ in diameter, have a round, darkly-staining nucleus and a scanty, basophilic cytoplasm. The cytoplasm appears to be negative to used histochemical methods.

b) Lymphoblasts (large lymphocytes) measure from 10 to 15 μ in diameter. They have a coarsely outlined, large nucleus, including one or two nucleoli, and a broad, strongly basophilic cytoplasm. The lymphoblasts are found dividing by mitosis. The basophilic cytoplasm is metachromatically stained in purple-blue with toluidin blue and in pinkish-red with pyronine-methyl green. The nucleoli are also stained by pyroninophilia. But their cytoplasm is negative to other histochemical reactions (Figs. 37, 49 and 50).

c) Reticular cells have a delicately outlined nucleus, ranging 10–18 μ in diameter. The shape of a nucleus is oval, or sometimes irregular; one or two small nucleoli are found in the nucleus. However, the nucleus of sinus lining reticular cells shows flatly spindle-shape. Their cytoplasm is usually elongated, or star-shaped and sometimes it phagocytoses injected ink particles, hemosiderin pigments and vacuoles. The cytoplasm reacts feebly with pinkish color with PAS reaction. Transition forms between reticular cells and lymphoblasts, sudanophilic PAS-positive cells or free macrophages are frequently observed in the lymph node.

d) Sudanophilic PAS-positive cells have a similar nucleus to that of the ordinary reticular cells. Yellow-brownish coarse granular pigments are found in their broad cytoplasm. The cells measure sometimes over 20 μ in size. The pigments react strongly in red to PAS reaction, but they are not digested by saliva and are negative in Prussian blue reaction. In paraffin sections, the pigments show a sudanophilic character with sudan III and sudan black, moreover they are positive to SCHMORL's and MALLORY's reactions for lipofuscin. They are also stained green with toluidin blue and pinkish-purple with pyronine-methyl green (Figs. 66, 67 and 68). The pigments may be regarded as a lipofuscin-like glycolipin.

e) Plasma cells measure 7~15 μ in diameter. The coarse, darkly-staining nucleus is small, round and has an eccentric position. The broad, strongly-basophilic cytoplasm of cells forms a broad layer in the cell body and a pale area is found adjacent to the nucleus. The cytoplasm is strongly pyroninophilic with pyronine-methyl green and stains purple-blue with toluidin blue (Figs. 59 and 60), and sometimes stains feebly pinkish to PAS reaction.

RUSSELL's bodies are scatteredly found in accompany with plasma cells. The body is component of eosinophilic glassy granules or corpuscles, measuring 1~5 μ in size. They are

situated usually in the cytoplasm of cells (perhaps plasma cells), although sometimes outside of the cells. RUSSELL's bodies in the cat are negative to used histochemical methods (Figs. 61 and 62). A transition form between plasma cells and typical RUSSELL's bodies are found occasionally in company with plasma cells. This cell has an eosinophilic glassy homogeneous cytoplasm and small round, darkly-staining, somewhat pycnotic, nucleus. The eosionophilic glassy cytoplasm is much effected by PAS reaction.

f) Mast cells are oval shaped, measuring $10\sim15\,\mu$ in diameter, in the sinuses, and they are irregular spindle-shaped cells, measuring $10\sim30\,\mu$ in longest diameter, in the trabeculae and capsule. Their round, coarse, darkly-staining nucleus has one or two small nucleoli. The broad cytoplasm is filled with granules which are stained metachromatically in purple with toluidin blue, in purple-red with pyronine-methyl green and in pinkish-red with PAS reaction (Figs. 63, 64 and 65).

g) Blood cells and myelocytes

A few blood cells, such as erythrocytes, neutrophil and eosinophil leucocytes, appear scatteredly in the lymphatic sinuses under physiological conditions.

Moreover, an ectopic myelopoiesis is in many cases found in the lymph nodes of infant and juvenile cats, less than 4 months old, under physiological conditions.

Granulocytopoiesis is active, and a few megakaryocytes and small fields of erthrocytopoiesis are also observed in the medullary cords (Figs. 69, 70 and 71). Basophilic granulocytopoiesis is scarcely found.

The primitive cells (myeloblasts or hemocytoblasts), appearing in the field of myelopoiesis, are difficult to distinguish from ordinary lymphoblasts on the basis of their cytological characters.

The neutrophil leucocytes and megakaryocytes have a PAS-positive cytoplasm.

2. Distribution of various cells

Small lymphocytes, lymphoblasts and reticular cells are more or less distributed in the lymphatic parenchyma and sinuses.

Sudanophilic PAS-positive cells appear in groups in the medullary cords and juxta-medullary zone of the cortex, and scatteredly in the medullary sinuses. But, they are not found in the other parts of the cortex and medullary nodules.

Plasma cells are to a certain extent distributed in the medullary cords and juxta-medullary zone of the cortex, but are not found in the sinuses, and cortical mass, with exception of the secondary nodules and juxta-medullary zones. Sometimes, plasma cells appear in the capsule, trabeculae, so-called KAWAKAMI's reticular portion of the secondary nodules and internodular zone of the cortex. The distribution of RUSSEL's bodies coincides with that of plasma cells, but that rarely appears.

Mast cells are distributed scatteredly in the capsule, trabeculae, medullary cords, juxta-medullary zone of the cortex and sinuses, but are not found in the other structures, such as the cortical mass, except for juxta-medullary zone, and medullary nodules including the secondary nodules.

The fields of myelopoiesis appear in the medullary cords and juxta-medullary zone of the cortex, but are never found in the sinuses, medullary nodules and cortical mass except for the juxta-medullary zone.

3. Classification of lymphatic parenchyma

On the basis of differences in the distribution of various cells, the lymphatic parenchyma, except for secondary nodules, is classified into two sorts of parenchyma, proper and varied.

a) Proper lymphatic parenchyma is composed of a sponge-like framework or stroma of fixed cells (reticular cells) supported on reticular fibers and free cells, such as small lymphocytes and a few lymphoblasts, in the mesh of the stroma. On the other hand, other free cells, such as plasma cells, mast cells, etc, are not found in this parenchyma. The reticular meshes of this parenchyma are usually wide, polygonal shaped. Some small lymphocytes show degenerative features, such as karyorrhexis, karyolysis and pycnosis. Their nuclear debris, which is positive to FEULGEN's reaction, is phagocytosed by reticular cells (Figs. 38, 39 and 40). Lymphoblasts are sometimes found dividing by mitosis (Fig. 37). The peculiar so-called post-capillary veins and reticular fiberless sinuses are also found in this parenchyma.

b) Varied lymphatic parenchyma is composed of slit-like meshes, of finer reticular fibers than those of the proper lymphatic parenchyma, with various kinds of free cells. In this parenchyma, in addition to small lymphocytes and lymphoblasts, there are found variable numbers of plasma cells, RUSSELL's bodies, mast cells and sudanophilic PAS-positive cells. In juvenile cats, a conspicuous ectopic myelopoiesis occurs in this parenchyma. Moreover, the fatty involutions appear also in this parenchyma.

The extent of both types of parenchyma is shown in schema 1 (Plate I).

It will be seen that the "proper lymphatic parenchyma" occupies the cortical mass or nodules, except for the secondary nodules and juxta-medullary zones, and medullary nodules except for the secondary nodules. The internodular zones of the cortex are usually occupied by this parenchyma, but not always.

The "varied lymphatic parenchyma" occupies the medullary cords, juxta-medullary and internodular zones of the cortex.

The distinction between the two parenchymas becomes more distinct under some conditions, in which large numbers of plasma cells, mast cells or conspicuous ectopic myelopoiesis appear in the latter parechyma (Fig 59).

DISCUSSION

Various structural variations of the postnatal lymph nodes were noted in these observations. Some variations seem to be related intimately with the degree of differentiation, the locations of the lymph nodes or with age. Moreover, these three factors are also related with one another. For convenience sake, the writer will discuss relations among them under the following three headings.

A. Structural Variations of the Lymph Nodes with Relation to the Degree of Differentiation

The ontogeny, especially histogenesis, of the lymph node is described in detail by ANDO (man, rabbit and cat), KLING (man), MIYAZAKI (mouse) and MURATA (man).

Their descriptions may be summarized, as follows: the anlages of the lymph nodes develope from lymphatic vessels. The anlages are classified into two, cystic and vascular. The former appears more early than the latter (ANDO and MURATA). In consequence of development of the subendothelial mesenchyma of the anlage,

the first structure, which is deemed as a lymph node, is formed at 4～5 fetal months in man and in the cat embryo; it measures about 57 mm in length. The lymph node of this period is composed of the capsule, subcapsular sinus and one lymphoid mass without division into the cortex and medulla (ANDO, KLING, MIYAZAKI and MURATA). Soon afterwards, the medullary sinuses and next the collagenous trabeculae develope. The secondary nodules appear at times in the lymphoid mass between middle and end of fetal periods, but a light center is absent (ANDO, MURATA and EHRICH[17]). At birth, the lymph nodes usually show a completed, mature form.

As to the phylogeny of the lymphatic tissue accompanying the lymphatic vessel, KIHARA and his colleagues have systematically observed it in the amphibia, reptile, aves and mammals. Recently, independently, LINDER, and MORITA and NISHIDA reported on the lymph nodes of the geese and wild geese. Moreover the postnatal histogenesis of the lymph nodes of the lower mammals (rat and mouse), reported by MASSHOFF and GROSS, and TANAHASHI, is an important item for reference.

Their descriptions briefly summarized are as follows: In lower species under than the reptile, there is no true lymph node, but the lymphatic vessels have some subendothelial lymph infiltration or lymphatic nodules without secondary nodules (TAKAWA[103] and KONDO[59]). In the aves except for water fowls, there are also no true lymph nodes (KONDO[56)-58)]), but in some species the secondary nodules appear in the subendothelial lymphatic nodules (TAKAWA[105]). In the water fowls, true lymph nodes with the secondary nodules develope, but the trabeculae and sinus reticular fibers are scarcely developed; however a subendothelial lymphatic apparatus and a transition form between the lymph node and subendothelial lymphatic nodule appear frequently (KIHARA and NAITO, LINDER, MANABE[65),66)], MORITA and NISHIDA, and TAKAWA[104]). In the mammals, the lymph node usually appears as a sort of true lymph node. However, the number of lymphcenter increases with advanced animals, from the rat (JOB), guinea pig (HASHIBA), rabbit (NISHIDA), cat (SUGIMURA, KUDO and TAKAHATA[96)-100)]), dog, horse, cow (BAUM) to the monkeys (TESHIMA[109)-111)]).

Moreover, in the lower mammals (rat and mouse), the lymph nodes even after birth show embryonic structures which correspond with these of 5～6 fetal months in man (MASSHOFF and GROSS, and TANAHASHI).

In short, on the basis of the ontogeny and phylogeny, it may be histologically unquestionable that the most primitive lymph nodes are composed merely of the capsule, subcapsular sinus and one nodular lymphoid mass. With advanced development, the medullary sinuses and simultaneously medullary cords appear, and consequently the division between the cortex and medulla becomes distinct. In this period, the occurrence of the secondary nodules is perhaps possible. Lastly, the collagenous trabeculae develope and the ordinary structural elements of the lymph nodes become complete.

In the cat more than 4 months old, the present writer classified the lymph nodes into five types according to their degrees of differentiation.

The writer's D. I type coincides with the most primitive lymph nodes with exception of occurrence of the secondary nodule which has a light center in some cases. The D. II type corresponds with somewhat advanced embryonic form. On the other hand, the writer's D. IV and D. V types are the ordinary mature lymph nodes. However, the cortex arrangement of D. V type is more complete than that of D. IV type. The D. III type is considered as an intermediate form between the embryonic and mature ones. More pertinently, the D. III type should be treated as an immature node from the two following facts: the nodes corresponding to the writer's D. III type are described by JOB, ROEMER, and JORDAN and LOOPER only in the rodents (rat, hedgehog and rabbit), which rank with the lower animals among the mammals. The other fact is that the D. III type appears at birth and six days old, in many cases of the writer's O. I group, in which in the adult cat are usually found mature nodes.

The present writer found that the occurrence of each differentiation type differs among his occurrence groups, but that occurrence is not related so intimately with their location in this observation; in the O. I group, the mature nodes appear exclusively. In the O. II and O. III groups, the immature and embryonic ones are principally found, especially in the O. III group. That is to say, the small lymph nodes, which are found inconstantly (O. II) or as accessory nodes (O. III), showed an incompleted form in most cases, such as is found in the embryonic or infant periods, even in the adult cat. Moreover, in the such embryonic and immature nodes the fatty involution was more conspicuously found than in the mature nodes.

By GULLAND, HELLMAN, KLING, OTTAVIANI, STILES and SUZUKI, the postnatal occurrence of such embryonic forms has been already pointed out in man and other animals, but without systematic description. The significance of such embryonic nodes is unknown yet.

On the basis of the ontogeny and phylogeny, the occurrence of embryonic nodes might signify a phylogenetic tendency by which the numbers of lymph nodes of the mammals become more numerous in advanced animals. In other words, such embryonic and immature lymph nodes are excess-developed ones and become atrophic, as shown by conspicuous fatty involution, at an early period without forming a complete structure. The name, KLING's "rudimental nodes" may also be suitable.

As to their dispensability and a reason of their undeveloped structure, it may be also macroscopically explained that the such nodes, occurring inconstantly, are usually related with limited peripheral area and most of the same peripheral areas are better drained into other nodes appearing constantly, and that the accessory

nodes receive only fine, unimportant branches of the efferent vessel of main nodes occurring constantly, and are not related directly with peripheral areas (SUGIMURA, KUDO and TAKAHATA[96)~100)]).

But, if the main lymph nodes are attacked by some toxogenous invader, these undifferentiated nodes may be important for performance of some compensatory function.

B. Structural Variations of the Lymph Nodes with Relation to Location and Age

For observation of regional difference, the lymph nodes of the writer's O.I group, which includes principally mature forms in the cases over 4 months old, were used as the materials. For observation of age difference, 13 cases, whose lymph nodes were nearly completely taken from all locations, were mainly examined in order to avoid possible influence of some results by regional difference.

1. Supporting framework

As to development of the supporting framework of the lymph nodes, many investigators (OKI, OMORI and RICHTER) have written about their regional differences in the rabbit, dog, pig, horse, cow and man. It seems generally to be a full accepted view that the trabecular system of the lymph nodes is more well developed in the superficial area than in the deep area.

The present writer confirmed, on the whole, the above usual opinion, but some exceptions should be noted; the parotid group has a poorly developed trabecular system even in the superficial area. On the other hand, the small intestinal group has a well developed one in the abdominal cavity in the cat.

By DENZ and HELLMAN, the trabecular system is stated to be scarcely or poorly developed at birth but afterwards becomes conspicuous with advance in age.

In the cat, the trabecular system was usually absent at birth and continued to develope until the age of 2 months. But, afterwards, no chronological changes were to be found with advance in age, contrary to DENZ's view.

2. Lymphatic parenchyma

Regional difference of the lymphatic parenchyma in the literature has been observed as regards two points of view, development and arrangement of the cortex and medulla.

HAM, KOPSCH, MAXIMOW and BLOOM, and RICHTER stated that the medulla is more developed in the lymph node of the mesentery than in those of the superficial areas. The same opinion was also reported by some other investigators; TRAUTMANN and LIPPMANN classified the rat lymph nodes into three types, 1) a peripheral type having a wide cortex, 2) a mesenteric type having thin cortex and 3) intermediate type. Also, DUNN described a similar tendency in the mouse.

On the other hand, DENZ asserted that the lymph nodes of the deep area have

more developed cortex than those of the superficial area in man, and that the such findings are owing to the functional differences between the two drainage areas, the skin and digestive epithelium.

In this observation of the lymph nodes of the cat body, the present writer ascertained that the cortex is usually very well developed in the cat, except for only the mediastinal group whose members have a poorly developed cortex. As to the medulla, it was not simply divided into two, such as superficial and deep, but classified into three types; 1) most poorly developed one: parotid, cervical, axillar, inguinal, popliteal, gastrolienal and tracheobronchial groups; 2) moderate: submandibular, retropharyngeal, lumbar, iliac and hepatogastric groups and 3) well developed: mediastinal, small and large intestinal groups. That is to say, the views of HAM and many others may be, on the whole, affirmed, but there are many exceptions.

As a cause of dispute among many investigators, it should be considered that the results obtained from the observation of two or several locations were unreasonably applied to the wholly body by above investigators. But, as it was pointed out by RICHTER that such a regional difference is not conspicuous in the cow, it may be considered that there are some differences among animal species.

DENZ, HELLMAN and TANAHASHI pointed out that the lymphatic parenchyma, especially the cortex, becomes most well developed at puberty, and afterwards become atrophied with advance in age.

The present writer found that the lymphatic parenchyma, especially the cortex, increased until 4 months old, but that afterward it showed a conspicuous individual difference and no chronological atrophy was detected with advance in age.

As to the regional difference of the arrangement of the cortex and medulla, there is a dispute in the rodent lymph node; JOB classified the rat lymph nodes into two: type I, whose cortex covers the medulla and type II, whose cortex and medulla are situated at the opposite sides of the node respectively. He maintained that type II is found more conspicuously in the body cavity than in the superficial area. JORDAN and LOOPER agreed with the JOB's view, on the whole, in the rabbit, but DAWSON and MASUR denied such a regional difference in the rat.

JOB's type II corresponds to the present writer's D. III type, which is an immature node. In the cat, this type appeared principally in the writer's O. II and O. III groups, but the occurrence of this type did not show regional difference. As already discussed, more attention should be paid to the degree of differentiation of the lymph node.

As regards the irregularity of the cortex arrangement, DENZ pointed out that it is more conspicuous in the deep nodes than in those of the superficial area in man and that the occurrence is related intimately with the developmental degree

of the cortical trabeculae.

In the cat, the present writer found markedly such a irregularity of the cortex arrangement in the retropharyngeal, small and large intestinal groups. But, he harboured suspicion that the occurrences differ distinctly between deep and superficial areas, because of the appearance of some exceptions; Such disorder was somewhat conspicuous in the submandibular group of superficial area. On the other hand, it was poor in the hepatogastric and gastrolienal groups of the deep area.

In this study, the medullary nodules were newly defined as a structural element of the lymph node. A usual pattern of the medullary nodules is composed of small nodular dense lymphatic parenchyma, which was more similar to the cortical substance than to the medullary cords on the basis of the reticular meshes and distribution of several kinds of cells, and a secondary nodule, which has an eccentric position. The medullary nodules appeared in the medullary cords in 36.4% of the mature lymph nodes.

CONWAY, HEUDORFER, HORII[34),35)], KAWAKAMI[49)], RICHTER and RÖHLICH[89)] said that the secondary nodules appear also in the medullary cord in the dog, cat, rabbit, horse and cow, but they paid no attention to accompanying dense lymphatic tissue, which belongs to the writer's "proper lymphatic parenchyma".

DENZ maintained that all secondary nodules appearing in the medulla should be classed as cortical substance owing to the irregularity of the cortex arrangement. But the present writer by the observation of serial section preparations could prove that the medullary nodules appear independently in the medullary cords.

As to the occurrence of the medullary nodules, there was found a striking regional difference: 1) conspicuous occurrence: submandibular, retropharyngeal and small intestinal groups, 2) moderate one: cervical, axillar, inguinal popliteal, hepatogastric and large intestinal groups and 3) scarce or non-occurrence: parotid, lumbar, iliac, gastrolienal, mediastinal and tracheobronchial groups.

The medullary nodule was non-existent at birth and only a few nodules appeared before the age of 1.5 months. In cases older than 2 months, the occurrence of the medullary nodule became marked, but it was somewhat variable and did not show chronological changes. The present writer has no exact data as to how condition is related to occurrence. But, at least, it seems that the medullary nodules appear under physiological conditions on the basis of their histology and postnatal development.

3. Secondary nodules

Following in the footsteps of FLEMMING, reports by ALBERTINI, CONWAY, DABELOW, EHRICH, FISCHER, GLIMSTEDT, GROLL and KRAMPF, GYLLENSTEN, HELLMAN, JECKELN, KAWAKAMI, LINDNER and SCHALLOCK, MAXIMOW and BLOOM,

NAKAGAWA, OHTANI and ARISHIGE, ONO, ROTTER, WÄTJEN and many other investigators have been made as to the fate and forms of the secondary nodule under various physiological, pathological or experimental conditions. But, the findings differ with one another and there is no fully accepted opinion yet. Actually, it is very difficult to fit these various forms reasonably into the descriptions which have published.

The present writer classified the secondary nodule into four types after referring specially to EHRICH's and KAWAKAMI's descriptions: S.N. I type is a solid secondary nodule, showing comparatively progressive character, in which some lymphoblasts are more dominant than degenerative features, such as nuclear debris, though small lymphocytes pack exclusively in the nodule. The diameters are usually small, ranging from 50 to 150 μ. The S.N. II type corresponds to EHRICH's "FLEMMING type". However, the dark zone of this type does not surround a light center, but it is cap-shaped. The size varies from 200 to 500 μ in diameter. S.N. III type coincides with KAWAKAMI's "mature type", which has a cap-shaped dark zone and light center, composed of reticular and lymphoblastic portions. It ranges 300 to 400 μ in size. The secondary nodule corresponding to this type was described also by RÖHLICH[89] in the cat. Type S.N. IV is also a solid nodule, but shows more regressive character, such as nuclear debris and hyalin substances. The sizes ranging 200 to 300 μ, were usually larger than those of S.N. I type.

As to the occurrence of each type, no regional differences were found, but age-differences were conspicuous. That is, at birth and six days old, no secondary nodule existed in many nodes, but in some nodes the S.N. I type appeared. At 1.5 months old, the secondary nodule appeared in all lymph nodes. Some of them showed the S.N. I type, but in many nodes, the S.N. II type, corresponding to EHRICH's "FLEMMING type" or CONWAY's "bare type", appeared. In cases over 4 months old, type S.N. III, corresponding to KAWAKAMI's "mature type", was principally found, and no conspicuous age-difference was detected afterwards. However, at 8 and 16 years old, the S.N. IV type somewhat much appeared, though it scarcely appeared in the cases more than 4 months to 3 years old.

Although there are some disputes as to the postnatal development of the secondary nodule among investigators, owing probably to vague definition as to EHRICH's "transition form", the above-mentioned tendency, on the whole, may be in agreement with the descriptions of EHRICH, GYLLENSTEN, HORII, KAWAKAMI, and OHTANI and ARISHIGE.

The size of the secondary nodule was so large that it sometimes reached over 500 μ in diameter in the submandibular, retropharyngeal, small intestinal and large intestinal groups.

This finding supports the descriptions by DENZ, EHRICH and HELLMAN.

The occurrence of the light center may be intimately related with some exogenous influences, as pointed out by CONWAY, HELLMAN, MARSHALL and many other investigators. The present writer has also no data on the basis of which to conclude whether the light center is a germinal center (FLEMMING) or a reaction center (HELLMAN). But, it is an indubitable fact that the writer's type S.N. III, corresponding to KAWAKAMI's "mature type", appears principally in the adult cat under physiological condition. Usually, the light center of this type shows more or less of a proliferative feature (lymphoblasts with mitosis), a degenerative one (nuclear debris and hyalin substances) and a reactive one (plasma cells, RUSSELL's bodies and macrophages). In the light center, moreover, the proliferative field is situated at the entrance of the arteriole (corresponding to KAWAKAMI's "lymphoblastic portion"), while the degenerative and reactive fields, on the contrary, are situated at the side of the cap-shaped dark zone (corresponding to KAWAKAMI's "reticular portion"). The present writer supports HORII and KAWAKAMI's opinion that this type of secondary nodule is stable, mature form and moreover a normal organella of the lymph node which may have a physiological function, on the basis of observations during this study.

The secondary nodule of the medulla was frequently found in the adult cat. The size was smaller than that of the cortex and ranged 50–200 μ in diameter; the demarcation of the light center and dark zone was unclear as described by RÖHLICH[89]. As to occurrence of secondary nodules in the medulla, CONWAY, DABELOW, HEUDORFER and KAWAKAMI stated that such a nodule is temporary one due to some exogenous stimuli.

But, the present writer pointed out that the postnatal development shows a similar tendency with that of the cortex, though the development of medullary ones is somewhat later than that of cortical ones. Accordingly, it is suggested that the secondary nodule of the medulla is an undifferentiated one, but developes as a result of physiological stimuli. The correctness of this suggestion should be acertained by phylogenetic studies.

4. Lymphatic sinuses

ASCHOFF, DUNN, NORDMANN, and TRAUTMANN and LIPPMANN treated a mesenterial lymph node as a separate type on the basis of the conspicuous activity of the sinus reticular cells and their wide sinuses.

The present writer found that the medullary sinuses were wider in not only the small and large intestinal groups, but also in the submandibular and retropharyngeal groups. On the other hand, the narrow sinuses were found in the parotid, popliteal, lumbar and tracheobronchial groups, but the other groups showed so markedly variable breadths, that no regional difference could be pointed out.

Recently, HORII, HORII and TAMAKI, and OKI maintained in the quantitive observation of the lymph nodes that the regional differences are intimately related to the ratio between the lymphatic parenchyma and sinuses; the lymphatic parenchyma of the "primary lymph node" was larger in quantity than that of the "secondary lymph node" in the rabbit and man, but such a tendency was not distinct in the guinea pig, rat, hamster, dog, cat, pig and cow.

The present writer's observations as regards the width of the medulla and medullary sinuses may, on the whole, support HORII's opinion, but as to the development of the cortex layer, the present writer can not approve his view in the cat. Actually, in agreement with HORII's view in the cat, the present writer could not find regional difference between his type Z (corresponding to HORII's "primary lymph node") and type ZT (corresponding to HORII's secondary lymph node).

HELLMAN said that the sinuses are usually wider in infant and juvenile animals than in the adult ones.

The present writer found that the sinuses, especially subcapsular sinuses, are wider at birth and six days old than in cases over 1.5 months old. This tendency appears to be related intimately with the development of secondary nodules and the cortex layer. Accordingly, the subcapsular sinuses become narrow with the advanced development of the secondary nodule.

The reticular fiberless sinus has been described by HEUDORFER (dog and cat), RICHTER (horse) and KLING (human embryo). The particular sinus may also correspond to ONO's[84] "intermediate sinuses". Generally, it seems in the literature to be considered that these sinuses are primitive medullary ones without having developed sinus reticular cells.

The present writer found that the reticular fiberless sinus appears in more than a half of the cases of observed nodes. The particular sinus is situated restrictedly in the cortical mass and in the cortico-medullary junction. This sinus begins as a blind end near the secondary nodule to open into the medullary sinuses. Injected ink particles seem to be not phagocytosed in these endothelial cells. Sometimes, small lymphocytes fill the reticular fiberless sinus and form dark cords.

At least, the above findings show that the reticular fiberless sinus is lined with a layer of non-phagocytotic endothelial cells and is of use as a passage for lymphocytes. The presence of lymphatic vessels in the lymph node is denied for the present. But, the writer would suggest that the reticular fiberless sinus is a lymphatic capillary in the cortical mass. Actually, this suggestion is not too unreasonable, because the subepithelial lymphatic nodules in the intestine have very aboundant lymphatic capillaries (KIHARA).

5. Fatty involution and regressive change with advance in age

Concerning a chronological change of the lymph node with advance in age, the fatty involution and a atrophy of lymphatic parenchyma are described by AZUMA, HELLMAN, SUZUKI and TANAHASHI. Generally their view seems to be an acceptable opinion. On the other hand, ANDREW and ANDREW, KRUMBAAR, MILLER and WEST were doubtful regarding such chronological changes in the observations of the deep cervical nodes of the rat, of clinical materials in man, of lymphatic tissues in the lung of man and of the rat, cat and rabbit, respectively.

Only a few investigators, DENZ, RÖSSEL and ZACHAROW, pointed out that the fatty involution is more conspicuous in the superficial lymph nodes than in the deep ones.

The present writer could prove that fatty involutions show conspicuous regional difference; they are divided into two groups. The conspicuous fatty involution was found in parotid, cervical, axillar, inguinal, popliteal, lumbar, iliac, mediastinal and tracheobronchial nodal groups. The other groups showed poor occurrence.

Age difference was proved from birth to 4 months old, but in animals over 4 months old, no chronological changes as to fatty involution and no atrophy of the lymphatic parenchyma were found with advance in age.

Regional difference as regards the degree of maturity was found not only as to the cortex layer and secondary nodule, as described by GYLLENSTEN, but also as to the trabeculae, medullary nodules and fatty involutions. But, such difference becomes unclear, after the mature structure of the lymph node was completed at about 2~4 months old.

In other words, age difference of the lymph node was not found in the cats more than about 4 months old, but afterward the ordinary regional difference became conspicuous.

C. A Pattern of the Lymph Node which Was Concluded after Referring to Two Lymphatic Parenchymas Classified Newly

Some schemata of the normal lymph nodes were drawn by COWDRY, EHRICH[18], HAM, HEUDORFER, and MAXIMOW and BLOOM. Their schemata differ from one another, so that the present writer was quite confused in the present actual observation. Confusion seems to be due to the fact that the lymphatic parenchyma, except for that of the secondary nodule, is insufficiently understood in the histology and distribution of various cells.

GILLMAN et al. classified the lymphatic tissue of the lymph node into a cortical pulp and a medullary pulp. This distinction has become firmly fixed in the literature. But, actually, a common view is represented by MARSHALL's description. He stated, "Apart from the presence of the primary nodules, it is not possible to make any morphological distinction between the cortex and medulla of a lymph node. The author agrees with GILLMAN, however, that the medullary pulp of the

node is the first portion of the pulp to react in many proliferative processes. If the stimulation is prolonged the cortical pulp may become involved at a later stage".

The present writer identified or distinguished several kinds of cells, appearing under normal conditions, with use of the histochemical methods and examined the distribution of each cell.

FUJII, KELLSALL and CRABB, and UNNO and HANAOKA ascertained that the plasma cells are found to a limited extent in the medullary cords. But, generally, it has been considered that plasma cells also appear in the cortical substance, as described by MARSHALL.

The present writer found that the plasma cells are distributed only in the medullary cords and juxta-medullary zone of the cortex, but do not appear in the sinus and cortical mass except for the juxta-medullary zone. Sometimes, plasma cells appeared in the capsule, trabeculae, so-called "KAWAKAMI's reticular portion of the secondary nodule" and internodular zone of the cortex. The occurrences of the RUSSELL's bodies coincided with those of the plasma cells, but the bodies rarely appeared.

KATZBERG (rat), KELLSALL and CRABB (hamster), and SMITH and WOOD (rat) pointed out that mast cells appear normally in the cortex, medullary cord and sinuses, but not in the capsule and secondary nodule.

In the cat, the mast cells are distributed scatteredly in the capsule, trabeculae, medullary cords, juxta-medullary zone of the cortex and sinuses, but are not found in the other portions, such as the cortical mass except for juxta-medullary zone, medullary nodule and secondary nodule.

Sudanophilic PAS-positive cells in the normal lymph node were observed in the mouse only by the present writer in publicated literature (SUGIMURA, FURUHATA, KUDO and TAKAHATA). However, similar cells are described in the cortex of the thymus by ITO and HOSHINO and some other, and in the reticular tissues under lipid storage diseases by MARSHALL.

The present writer found that these cells are distributed in the medullary cords, medullary sinuses and juxta-medullary zone of the cortex, but do not appear in the other portions. The significance of this sudanophilic PAS-positive cell is unknown yet.

It has been usually considered that the extra-medullary myelopoiesis occurs in the lymph node under some pathological conditions (DUNN, and MAXIMOW and BLOOM). On the other hand, MASSHOFF and GROSS, and RÖHLICH[90] found conspicuous ectopic myelopoiesis in the infant mouse, and cat and dog respectively. Moreover, recently, many investigator in Kyoto University (NAKAJIMA, TAKEMURA, and KAWAKAMI, SHIGEMOTO and TOYOTA) have stated that such ectopic myelopoiesis occurs in the lymph node of various infant animals under certain physiological

conditions.

The present writer found that such ectopic myelopoiesis occurs in the lymph nodes of juvenile and infant cats less than 4 months old; the granulocytopoiesis is prominent, but few megakaryocytes and small fields of erythrocytopoiesis are also observed. The location was restricted to the medullary cords and juxta-medullary zone of the cortex. But, this ectopic myelopoiesis was not found in the secondary nodule, though it has been described by above-mentioned investigators.

The present writer and colleagues[101] already have reported as to the distribution and regional difference of various cells in the mouse lymph nodes.

On the basis of the observations, the present writer could classify the lymphatic parenchyma, except for the secondary nodule, into two types, "proper" and "varied".

The "proper parenchyma" is composed of a sponge-like framework of reticular cells and free cells, densely filled small lymphocytes and scattered lymphoblasts in the mesh of the stroma. On the other hand, there are no other free cells in this parenchyma.

The "varied lymphatic parenchyma" is composed of slit-like meshes of finer reticular fibers than those of the "proper" parenchyma and various free cells, such as plasma cells, mast cells, RUSSELL's bodies and sudanophilic PAS-positive cells, in the meshes. In the infant cat, conspicuous ectopic myelopoiesis appeared markedly in the mesh. On the other hand, in the adult cat, fatty tissues appeared in this parenchyma.

The locations of each parenchyma is shown in schema 1.

It will be noted that the "varied lymphatic parenchyma" occupied the medullary cords, juxta-medullary zone and internodular zone of the cortex. On the other hand, the "proper lymphatic parenchyma" occupied the cortical mass, except for the above two zones, and the medullary nodule, except for the secondary nodule. The distinction between the two parenchymas became distinct under some conditions in which large numbers of plasma cells, mast cells or conspicuous ectopic myelopoiesis appear in the varied parenchyma, in disagreement with MARSHALL's view.

The writer's new classification of the lymphatic parenchyma may be related intimately to the pathology and physiology of the lymph node in practical and functional meaning.

After referring to the two divisions of the lymphatic parenchyma, a normal schema of the lymph nodes was newly suggested as drawn in schema 1.

The writer believes that the schema may be of use for functional and pathological discussions of various reactions of the lymph node.

SUMMARY AND CONCLUSION

Detailed histological and histochemical observations on the postnatal lymph

nodes of the cat were made with special reference to the relation between structural variations of the lymph node and the degree of differentiation, location or age, on the basis of the writer's detailed macroscopical study of the cat lymphatic system.

A. Structural Variations as Regards the Degree of Differentiation

The degree of differentiation of the lymph node was determined by the existence of trabeculae, medullary cords, secondary nodules, medullary and intermediate sinuses, and the distinction between and arrangement of the cortex and medulla.

On the basis of the degree of differentiation, the lymph nodes in the adult cat were classified into five types, D. I~D. V.

On the basis of the ontogeny and phylogeny of the lymph node, it was suggested that the writer's D. I type is the most primitive structure and that the D. II type is a somewhat advanced form, though most structural elements are absent. These two types were concluded to be an embryonic node. Type D. III corresponds to the structure of JOB's type II, observed in the rat lymph nodes, and was frequently found in the infant cat. Accordingly this type was treated as an immature node. or intermediate type. The D. IV and D. V types showed the ordinary developed structure of the lymph node. Type D. V was a more advanced form than D. IV type with respect to the cortex arrangement. The two types were treated as a mature node.

In the adult cat, the occurrences of each type differed among the occurrence groups, which were macroscopically classified on the basis of the ratio of occurrence and appearances of the afferent lymphatic vessels, but the occurrences of each type were not related intimately with the regional groups, which were classified as the location and regional lymphatic drainage area.

More particularly, in occurrence group O. I, which occurred constantly and consisted usually of large main lymph nodes, the mature node was almost the only sort found. In group O. II, which occurred inconstantly and consisted usually of small main lymph nodes, and in group O. III, which included accessory nodes of the main lymph nodes in the lymphcenter, immature and embryonic nodes were principally found.

The writer suggested that these embryonic and immature nodes are an excess-developed lymph node and become atrophic at an early period, however, that they may be able to perform a compensatory function of the main node under certain conditions.

B. Structural Variations as Regards the Regional Difference

Conspicuous regional difference was found as to the development of the medullary trabeculae, irregularity of the cortex arrangement, width of the medulla, occurrence of the medullary nodule and of the secondary nodule of the medulla

TABLE 28. *Summarized Table as to Regional Differences*

GROUPS DIVIDED AS TO REGIONAL DIFFERENCE	REGIONAL GROUPS	CONSPICUOUS DIFFERENCE					SLIGHT DIFFERENCE				
		Development of Medullary Trabeculae	Disorder of Cortex Arrangement	Width of Medulla	Occurrence of Medullary Nodule	Occurrence of Fatty Involution	Development of Cortical Trabeculae	Development of Cortex Layer	Size of Secondary Nodule	Breadth of Medullary Sinus	Occurrence of Reticular Fiberless Sinus
Group 1	Large Intestinal	+	++	+++	++	+		++	++	++	++
	Small Intestinal	++	++	+++	+++	+	++	++	++	++	++
	Submandibular	++	+	++	+++	+		++	++	++	++
	Retropharyngeal	++	++	++	+++	+	++	++	++	++	++
Group 2	Hepatogastric	+	+	++	++	+		++		++	++
Group 3	Gastrolienal	+	+	+	+	+		++			++
Group 4	Parotid	+	+	+	+	++		++		+	
	Tracheobronchial	+	+	+	+	++		++		+	++
Group 5	Lumbar	+	+	++	+	++		++			
	Iliac	+	+	++	+	++		++			
Group 6	Cervical	++	+	+	++	++		++			
	Axillar	++	+	+	++	++		++			
	Inguinal	++	+	+	++	++		++			
	Popliteal	++	+	+	++	++		++		+	
Group 7	Mediastinal	++	+	+++	+	++	++	+			++

+: Poor, ++: Moderate, +++: Conspicuous

and fatty involution. Slight regional difference was also detected as to development of the cortical trabeculae, and of the cortex layer, size of secondary nodule, width of the medullary sinus and occurrence of the reticular fiberless sinuses. The relation between these findings and regional groups are summarized, as shown in table 28.

As shown in the table, the relationships fall into 7 categories.

Group 1 (large intestinal, small intestinal, submandibular and retropharyngeal nodal groups): This group is peculiar in having the wide medullary sinus and medulla, and to show usually the conspicuous occurrence of the medullary nodule and irregularity of the cortex arrangement. The development of the trabeculae is also conspicuous, but fatty involution is poor and rarely found.

Group 2 (hepatogastric group): This group has also wide medulla, wide medullary sinuses and poor fatty involution, but development of the trabeculae and disorder of the cortex arrangement are not conspicuously found.

Group 3 (gastrolienal group): In this group, structural peculiarity is poor.

Group 4 (parotid and tracheobronchial groups): This group is similar to Group 3, but conspicuous fatty involution appears. In details, the tracheobronchial group, which has numerous dust cells, can be distinguished from the parotid group.

Group 5 (lumbar and iliac groups): This group is similar to Group 4, but has somewhat wide medulla.

Group 6 (cervical, axillar, inguinal and popliteal groups): The special features of this group are very well developed medullary trabeculae and conspicuous fatty involution.

Group 7 (mediastinal group): This group is somewhat similar to Group 6, but the wide medulla and narrow cortex are peculiar in this group.

On the basis of these findings, it may be considered that the old disputes as regards regional difference are owing to insufficient observation of the lymph node, obtained from only a few locations, usually only two or a few.

C. Structual Variations as Regards the Age-Difference

Age-differences were pointed out with respect to the development of the trabeculae and of the cortex layer, irregularity of the cortex arrangement, occurrence of the medullary nodule, occurrence and type of the secondary nodule, breadth of the subcapsular sinus, and fatty involution.

These age changes were detected from birth till the age of 2 or 4 months, being continued during occurrence of uncomplete structure of the lymph node, but at about 4 months old, the mature structure was completed, after which neither chronological development nor atrophy were usually found, except for the type of the secondary nodule.

Moreover, regional difference as regards the degree of maturity was found as

to the cortex layer, trabeculae, medullary nodule, secondary nodule and fatty involution from birth to 4 months old, but afterwards, such regional change owing to the degree of maturity did not show a chronological tendency with advance in age.

In other words, age differences of the lymph node were not found in cats over 4 months old, but regional differences became conspicuous.

D. Two Divisions of the Lymphatic Parenchyma as Regards the Distribution of Several Kinds of Cells and a Pattern of the Lymph Node

The writer could histochemically identify several kinds of cells, small lymphocytes, lymphoblasts, plasma cells, RUSSELL's bodies, mast cells and sudanophilic PAS-positive cells, whose substance may be regarded as glycolipin and a lipofuscin-like substance.

Moreover, in the infant and juvenile cats, less than 4 months old, conspicuous ectopic myelopoiesis was sometimes found in the lymph nodes.

In this report, the distribution of the above various cells has been described in detail.

On the basis of his observations, the writer could classify the lymphatic parenchyma except for the secondary nodule into two types, proper and varied; the "proper parenchyma" is composed of a sponge-like framework of reticular cells and free cells, densely filled small lymphocytes and scattered lymphoblasts, in the meshes of the stroma, but there were no other free cells in this parenchyma. The "varied parenchyma" is composed of slit-like meshes of finer reticular fibers than those of the "proper" one and of various free cells, such as lymphocytes, plasma cells, RUSSELL's bodies and sudanophilic PAS-positive cells, in the meshes. Moreover, conspicuous ectopic myelopoiesis, in the juvenile cat, and fatty involution, in the cat older than 4 months, appeared in this second type parenchyma.

The "varied lymphatic parenchyma" appeared in the medullary cords, juxta-medullary zone and internodular zone of the cortical mass. On the other hand, the "proper" one occupied the cortical mass, except for the secondary nodules and above two zones, and medullary nodules except for the secondary nodules. The distinction between the two parenchymas became clear under certain conditions in which large numbers of plasma cells or conspicuous ectopic myelopoiesis appeared in the "varied" one, contrary to the old view.

After referring to the above classification of the lymphatic parenchyma, a normal pattern of the cat lymph node was newly drawn, as shown in schema 1.

ACKNOWLEDGEMENT

To Professor K. TAKAHATA, chief of the Department of Veterinary Anatomy, the writer expresses his deepest appreciation for friendly guidance and helpful criticisms during this

work. Further, the writer wishes to offer cordial thanks to Dr. N. KUDO and Mr. K. FURUHATA, members of the staff of the Department, for their encouragement.

REFERENCES

1) ANDO, S. (1916): *Kaibo Z. (Acta anat. nippon.)*, **3**, 761 (in Japanese)
2) ANDO, S. (1916): *Ibid*, **3**, 781 (in Japanese)
3) ANDO, S. (1916): *Ibid*, **3**, 979 (in Japanese)
4) ANDREW, W. & N. V. ANDREW (1948): *Amer. J. Anat.*, **82**, 105
5) ASCHOFF, L. (1938-39): *Anat. Anz. Erg.-H.*, **87**, 152
6) AZUMA, T. (1931): *Tokyo Igk. Z. (Mit. med. Gesel. Tokyo)*, **45**, 554 (in Japanese with German summary)
7) ALBERTINI, A. (1932): *Beitr. path. Anat.*, **89**, 183
8) BAUM, H. (1926): *Anat. Anz.*, **61**, 39
9) CONWAY, E. A. (1937): *Anat. Rec.*, **69**, 487
10) COWDRY, E. V. (1950): A Textbook of Histology, 4th Edit., Lea & Febiger, Philadelphia
11) DABELOW, A. (1930): *Anat. Anz. Erg.-H.*, **81**, 187
12) DABELOW, A. (1938-39): *Anat. Anz. Erg.-H.*, **87**, 179
13) DAWSON, A. B. & J. MASUR (1929): *Anat. Rec.*, **44**, 143
14) DENZ, F. A. (1947): *J. Path. Bact.*, **59**, 575
15) DUNN, T. B. (1954): Reticular Tissue in Mice, *J. nat. Cancer Inst.*, **14**, 1281 (Translated into Japanese by N. IDA)
16) EHRICH, W. (1929): *Amer. J. Anat.*, **43**, 347
17) EHRICH, W. (1929): *Ibid*, **43**, 384
18) EHRICH, W. (1931): *Beitr. path. Anat.*, **86**, 287
19) FISCHER, H. (1937): *Z. mikr.-anat. Forsch.*, **41**, 229 (Cited by HELLMAN)[32]
20) FLEMMING, K. (1885): *Arch. mikr. Anat.*, **24**, 50 (Cited by HELLMAN)[30]
21) FUJII, H. (1960): *Arch. Hist. Jap.*, **18**, 479
22) FUJII, H. (1960): *Ibid*, **19**, 519
23) GILLMAN, J., GILLMAN, T., GILBERT, C. & I. SPENCE (1952): *Cancer*, **5**, 792
24) GLIMSTEDT, G. (1932-39): (Cited by HELLMAN)
25) GROLL, H. & F. KRAMPF (1920-21): *Zbl. allg. Path. path. Anat.*, **31**, 145
26) GULLAND, L. (1894): *J. Path. Bact.*, **2**, 447
27) GYLLENSTEN, L. (1950): *Acta anat.*, **10**, 130
28) HAM, A. W. (1957): Histology, 3rd Edit., Pitman Medical Publishing Co. LTD., London
29) HASHIBA, G. (1917): *Anat. Rec.*, **12**, 331
30) HELLMAN, T. (1930): Lymphgefässe, Lymphknötchen und Lymphknoten, MÖLLENDORF's Handbuch der Mikroskopischen Anatomie, **6**, 1 Teil, 233
31) HELLMAN, T. (1938-39): *Anat. Anz. Erg.-H.*, **87**, 132
32) HELLMAN, T. (1943): Lymphgefässe, Lymphknötchen und Lymphknoten, MÖLLENDORF's Handbuch der Mikroskopischen Anatomie, **6**, 4 Teil, 174
33) HEUDORFER, K. (1921): *Z. Anat. EntwGesch.*, **61**, 365
34) HORII, I. (1952): *Symposium on Hematology*, **6**, 45 (in Japanese)
35) HORII, I. (1960): *Kaibo Z. (Acta anat. nippon.)*, **35**, 391 (in Japanese)

36) HORII, I. & Y. TAMAKI (1951): Rinpakyu-ni-kansuru kenkyu (Studies on the Lymphocytes), Tokyo and Kyoto (in Japanese)
37) ITO, T. & T. HOSHINO (1962): *Z. Zellforsch.*, **56**, 445
38) JECKELN, E. (1932): *Beitr. path. Anat.*. **90**, 224
39) JOB, T. T. (1915): *Anat. Rec.*, **12**, 331
40) JOB, T. T. (1922): *Amer. J. Anat.*, **31**, 125
41) JORDAN, H. E. & J. P. LOOPER (1927): *Amer. J. Anat.*, **39**, 437
42) KATZBERG, A. A. (1954): *Anat. Rec.*, **118**, 393
43) KAWAKAMI, Y. (1958): *Kaibo Z. (Acta anat. nippon.)*, **33**, 348 (in Japanese with English summary)
44) KAWAKAMI, Y. (1958): *Ibid*, **33**, 483 (in Japanese with English summary)
45) KAWAKAMI, Y. (1958): *Ibid.* **33**, 490 (in Japanese with English summary)
46) KAWAKAMI, Y. (1959): *Ibid.* **34**, 123 (in Japanese with English summary)
47) KAWAKAMI, Y. (1959): *Ibid.* **34**, 131 (in Japanese with English summary)
48) KAWAKAMI, Y. (1959): *Ibid*, **34**, 243 (in Japanese with English summary)
49) KAWAKAMI, Y., DOHI, M. & T. IIZUKA (1959): Report II Division of *Anat.* Kyoto Univ., (in Japanese)
50) KAWAKAMI, Y., SHIGEMOTO, K. & M. TOYOTA (1960): *Kaibo Z. (Acta anat. nippon.)*, **35**, Suppl. II. 8 (in Japanese)
51) KELLSALL, M. A. & E. D. CRABB (1959): Lymphocytes and Mast Cells, The Williams & Wilkins Company, Baltimore
52) KIHARA, T. (1950): *Symposium on Hematology*, **3**, 118 (in Japanese)
53) KIHARA, T. (1952): *Ibid*, **6**, 1 (in Japanese)
54) KIHARA, T. & E. NAITO (1933): *Folia anat. jap.*, **11**, 405
55) KLING, C. (1904): *Arch. mikr. Anat.*, **63**, 575
56) KONDO, M. (1937): *Folia anat. jap.*, **15**, 309
57) KONDO, M. (1937): *Ibid*, **15**, 329
58) KONDO, M. (1937): *Ibid*, **15**, 349
59) KONDO M. (1937): *Kyoto Igk. Z. (J. Kyoto Med. Assoc.)*, **34**, 391 (in Japanese)
60) KOPSCH, FR. (1933): RAUBER-KOPSCH Lehrbuch und Atlas der Anatomie des Menschen, Abt. 3, Georg Thieme Verlag, Leipzig
61) KRÖLLING, O. & H. GRAU (1960): Lehrbuch der Histologie und Vergleichenden Mikroskopischen Anatomie der Haustiere, Paul Parey, Berlin und Hamburg
62) KRUMBAAR, E. B. (1938): Lymphatic Tissue, Problems of Ageing (Cited by HELLMAN)[32]
63) LINDER, D. (1961): *Wiss. Z. Humboldt-Univ.*, **10**, 181
64) LINDNER, H. & G. SCHALLOCK (1955-56): *Zbl. allg. Path. path. Anat.*, **94**, 246
65) MANABE, S. (1930-31): *Kaibo Z. (Acta anat. nippon.)*, **3**, 120 (in Japanese)
66) MANABE, S. (1930-31): *Ibid*, **3**, 282 (in Japanese)
67) MANABE, S. (1930-31): *Ibid*, **3**, 349 (in Japanese)
68) MARSHALL, A. H. E. (1956): An Outline of the Cytology and Pathology of the Reticular Tissue, Edinburgh and London, Oliver and Boyd
69) MASSHOFF, W. & U. GROSS (1962): *Virchows Arch.*, **335**, 109
70) MAXIMOW, A. & W. BLOOM (1957): A Textbook of Histology, 7th Edit., W. B.

Saunders Company, Philadelphia and London
71) MILLER, W. S. (1924): *Amer. Rev. Tuberc.*, **9**, 519
72) MIYAZAKI, T. (1940): *Nichi-byo-kai-shi (Tr. Soc. Path. Jap.)*, **30**, 29
73) MORITA, S. & S. NISHIDA (1953): *Nichi-chiku-kai-ho (Jap. J. Zootec. Sci.)*, **24**, 79 (in Japanese with English summary)
74) MORITA, S. & S. NISHIDA (1954): *Ibid*, **25**, 79 (in Japanese with English summary)
75) MURATA, S. (1957): *Kumamoto Igk. Z. (J. Kumamoto med. Soc.)*, **31**, 1401 (in Japanese)
76) NAKAGAWA, T. (1938): *Nichi-byo-kai-shi (Tr. Soc. Path. Jap.)*, **28**, 21 (in Japanese)
77) NAKAJIMA, A. (1961): *Kaibo Z. (Acta Anat. Nippon)*, **36**, Suppl. III, 4 (in Japanese)
78) NISHIDA, K. (1954): *Kumamoto Igk. Z. (J. Kumamoto med. Soc.)*, **28**, 295 (in Japanese)
79) NORDMANN, M. (1928): *Virchows Arch.*, **267**, 158
80) OHTANI, T. & Y. ARISHIGE (1952): *Nisshin Igaku (Jap. J. med. Prog.)*, **39**, 233 (in Japanese)
81) OKI, M. (1956): *Kaibo Z. (Acta Anat. Nippon)*, **31**, 135 (in Japanese)
82) OMORI, A. (1926): *Kumamoto Igk. Z. (J. Kumamoto med. Soc.)*, **16**, 423 (in Japanese)
83) ONO, K. (1940): *Nichi-byo-kai-shi (Tr. Soc. Path. Jap.)*, **30**, 1
84) ONO, K. (1952): *Symposium on Hematology*, **6**, 228 (in Japanese)
85) ONO, K. & T. MIYAZAKI (1936): *Nichi-byo-kai-shi (Tr. Soc. Path. Jap.)*, **26**, 278
86) OTTAVIANI, G. (1931): *Monit. Zool. Ital.*, **41**, Suppl., 260 (Cited by HELLMAN)[32]
87) RICHTER, J. (1902): *Arch. mikr. Anat.*, **60**, 469
88) ROEMER, H. (1932): *Z. Anat. EntwGesch.*, **99**, 492
89) RÖHLICH, K. (1928): *Z. mikr.-anat. Forsch.*, **12**, 254
90) RÖHLICH, K. (1933): *Ibid*, **33**, 467 (Cited by HELLMAN)[32]
91) RÖSSEL, R. (1926): Wachstum und Altern, *Erg. Path.*, **20**, 369 (Cited by HELLMAN)[30]
92) ROTTER, W. (1927): *Virchows Arch.*, **265**, 596
93) SMITH, C. & B. K. HENON (1959): *Anat. Rec.*, **135**, 207
94) SMITH, R. O. & W. B. WOOD (1949): *J. exp. Med.*, **90**, 555
95) STILES (1892): *Edinb. med. J.*, **38**, 26 (Cited by GULLAND)
96) SUGIMURA, M., KUDO, N. & K. TAKAHATA (1955): *Jap. J. vet. Res.*, **3**, 90
97) SUGIMURA, M., KUDO, N. & K. TAKAHATA (1956): *Ibid*, **4**, 101
98) SUGIMURA, M., KUDO, N. & K. TAKAHATA (1958): *Ibid*, **6**, 69
99) SUGIMURA, M., KUDO, N. & K. TAKAHATA (1959): *Ibid*, **7**, 27
100) SUGIMURA, M., KUDO, N. & K. TAKAHATA (1960): *Ibid*, **8**, 35
101) SUGIMURA, M., FURUHATA, K., KUDO, N. & K. TAKAHATA (1962): *Kaibo Z. (Acta anat. nippon.)*, **37**, 37 (in Japanese)
102) SUZUKI, T. (1952): *Acta Sch. med. Univ. Kioto*, **30**, 174
103) TAKAWA, O. (1943): *Kyoto Igk. Z. (J. Kyoto med. Assoc.)*, **40**, 363 (in Japanese)
104) TAKAWA, O. (1943): *Ibid*, **40**, 485 (in Japanese)
105) TAKAWA, O. (1943): *Ibid*, **40**, 789 (in Japanese)
106) TAKEMURA, A. (1962): *Kaibo Z. (Acta anat. nippon.)*, **37**, 40 (in Japanese)
107) TANAHASHI, T. (1949): *Nagoya Igk. Z. (J. Nagoya med. Assoc.)*, **63**, 115 (in Japanese)
108) TRAUTMANN, F. & H. LIPPMANN (1960): *Mat. Med. Norkmark*, **12**, 16 (Cited from World Research Literature in Basic Medical Sciences, **36**, 1961)
109) TESHIMA, G. (1935): *Folia anat. jap.*, **13**, 251

110) TESHIMA, G. (1935): *Ibid*, **13**, 289
111) TESHIMA, G. (1935): *Ibid*, **13**, 303
112) UNNO, G. & M. HANAOKA (1952): *Symposium on Hematology*, **6**, 62 (in Japanese)
113) WÄTJEN, J. (1929): *Virchows Arch.*, **271**, 556
114) WEST, L. S. (1924): *Anat. Rec.*, **28**, 349
115) ZACHAROW, J. (1891): *Inaug.-Diss.*, St. Petersburg (Cited by HHLLMAN)[30]

EXPLANATION OF PLATES

PLATE I.

Schema 1. A normal pattern of the cat lymph node

Abbreviations in Schema

C: Cortex
M: Medulla
Cap: Capsule
CT: Cortical trabecula
MT: Medullary trabecula
MC: Medullary cord
MN: Medullary nodule
SN: Secondary nodule
SS: Subcapsular sinus
IS: Intermediate sinus
MS: Medullary sinus
RS: Reticular fiberless sinus
Aff. V: Afferent lymphatic vessel
Eff. V: Efferent lymphatic vessel
: Proper lymphatic parenchyma
: Varied lymphatic parenchyma

Schema 2. Types as regards the degree of differentiation

Schema 1. A normal pattern of the cat lymph node

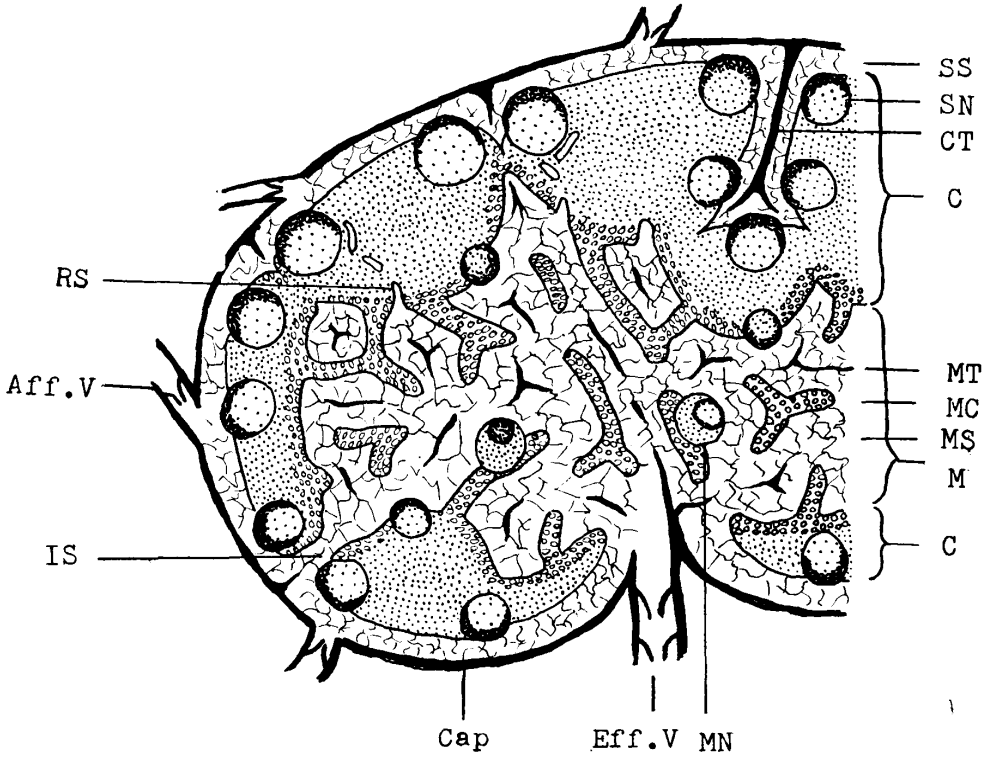

Schema 2. Type as regards the degree of differentiation

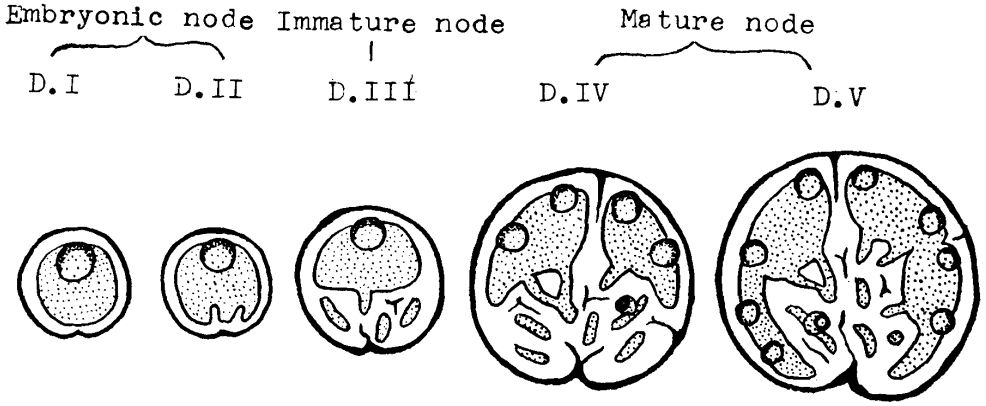

PLATE II. O. II and O. III groups

Fig. 1. Exp. No. 35, *Lnn. submandibulares*, accessory node; Type D. I, there is no differentiation of medulla. H.-E., × 120

Fig. 2. Exp. No. 42, *Lnn. submandibulares*, accessory node; Type D. I, conspicuous fatty involution appears. Secondary nodule is absent. H.-E., × 230

Fig. 3. Exp. No. 42, *Lnn. cervicales profundi*; Type D. II, poor fatty involution appears. Medullary sinus-like indentations are present in an oval lymphoid mass at the hilus side. Azan, × 80

Fig. 4. Exp. No. 30, *Lnn. parotidici caudales*, accessory node; Perhaps type D. II, conspicuous fatty involution appears. Secondary nodule is absent. Injected India ink fills sinuses. Azan. × 80

Fig. 5. Exp. No. 27, *Lnn. mesocolici medii*, accessory node; Type D. III, cortex and medulla are situated at the opposite sides respectively. Ink fills sinuses. H.-E., × 80

Fig. 6. Exp. No. 30, *Lnn. axillares caudales*, accessory node; Type D. III, conspicuous fatty involution appears. Sinuses are black in color due to injected ink. Azan. × 60

Fig. 7. Exp. No. 22, *Lnn. mediastinales dorsales*; Type D. III, two solid secondary nodules (S.N. IV) are present in the cortex. H.-E., × 60

Fig. 8. Exp. No. 23, *Lnn. axillares caudales*, accessory node; Perhaps type D. III, conspicuous fatty involution appears. One solid secondary nodule (S.N. IV) is present in the cortex. H.-E., × 60

PLATE II

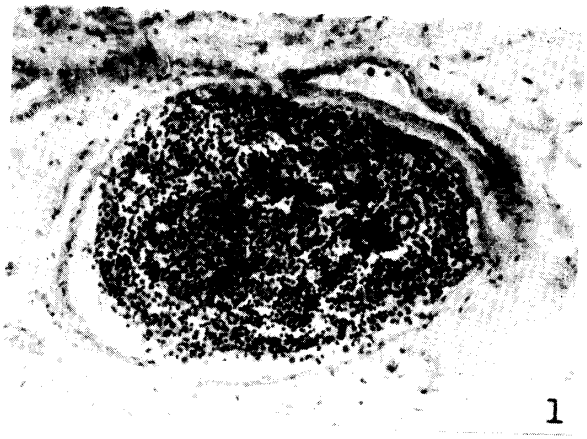

1

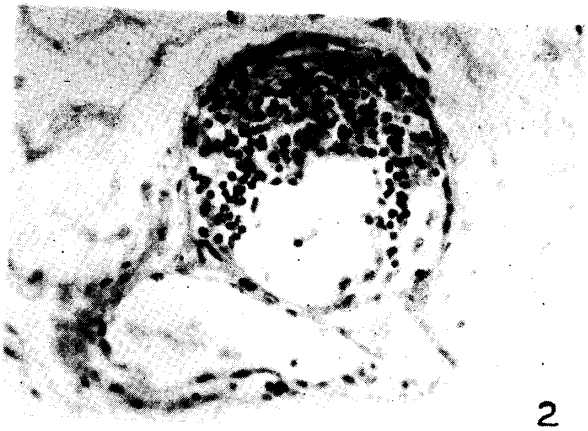

2

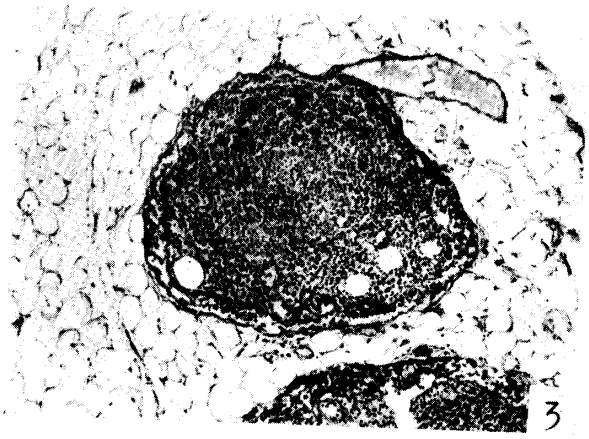

3

4

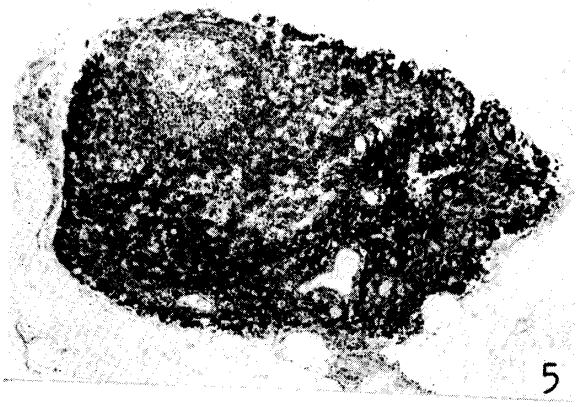

5

6

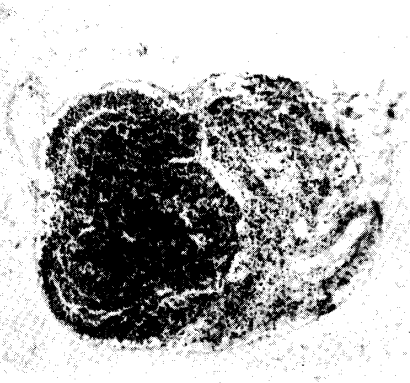

7

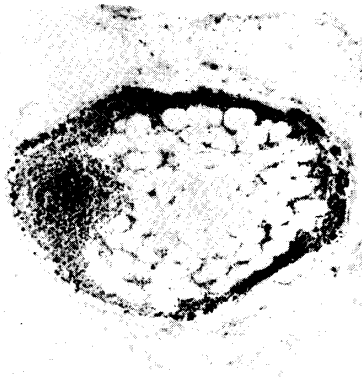

8

PLATE III. O. I group

Fig. 9. Exp. No. 38, *Lnn. mesenterici communes*; Type D. IV (upper) and type D. V (lower). H.-E., × 10

Fig. 10. Exp. No. 42, *Lnn. sternales*; Type D. V, H.-E., × 9

Fig. 11. Exp. No. 39, *Lnn. tracheobronchiales craniales*; Type D. IV (upper) and type D. V (lower). Moderate fatty involution appears. There are numerous dust cells, in groups, in the medulla. H.-E., × 9

Fig. 12. Exp. No. 35, *Lnn. gastrolienales*; Type D. IV (upper) and type D. V (lower). H.-E., × 9

9

10

11

12

PLATE IV. O. I group

Fig. 13. Exp. No. 29, *Lnn. parotidici caudales*; Type D. V. H.-E., × 16

Fig. 14. Exp. No. 47, *Lnn. anguli brachiocephalici*; Type D .V. H.-E., × 13

Fig. 15. Exp. No. 29, *Lnn. mesenterici communes*; Disorder of the cortex arrangement is conspicuous. Secondary nodules are larger than those of other nodes. H.-E., × 13

Fig. 16. Exp. No. 29, *Ln. popliteus*; Type D. V, moderate fatty involution appears. H.-E., × 9

Fig. 17. Exp. No. 47, *Lnn. ischiadici*; Type D. IV, conspicuous fatty involution appears. H.-E., × 16

Fig. 18. Exp. No. 20, *Lnn. epigastrici caudales*; Type D. V, moderate fatty involution is found. H.-E., × 13

Fig. 19. Exp. No. 28, *Lnn. sternales*; Perhaps type D. V, conspicuous fatty involution is observed. H.-E., × 13

Fig. 20. One of the serial preparations of the same node. LILLIE's silver impregnation, × 13

13

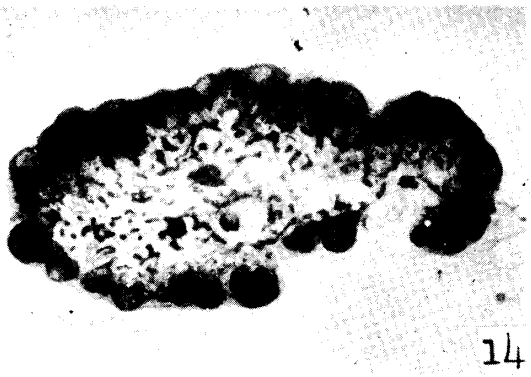

14

15

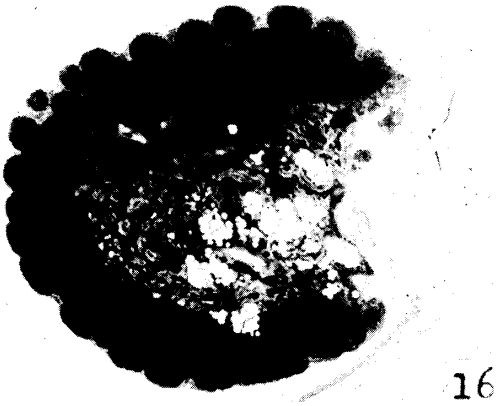

16

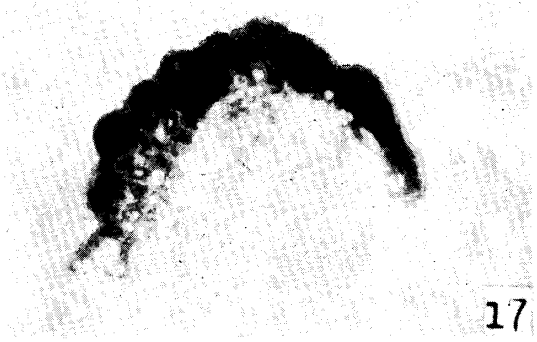

17

18

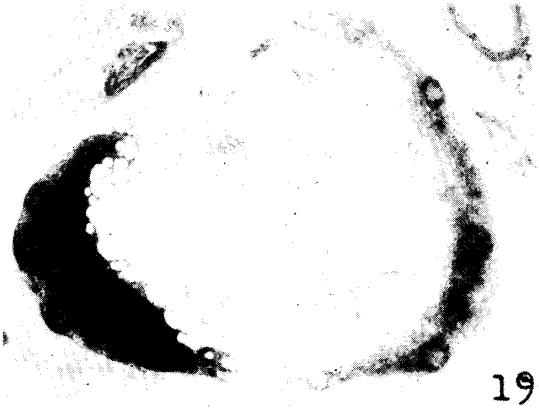

19

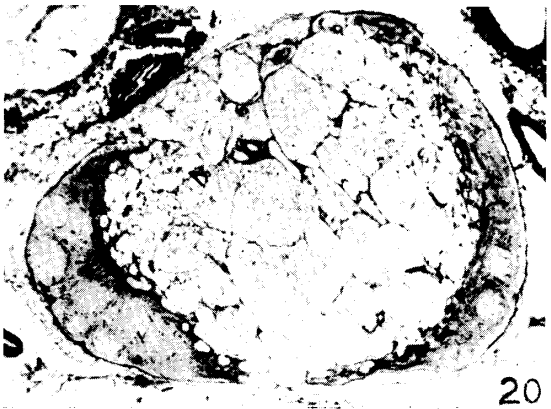

20

PLATE V. O. I group

Fig. 21. Exp. No. 4 (6 days old), *Lnn. mediastinales craniales*; Type D. III, secondary nodules and trabeculae are absent. H.-E., × 90

Fig. 22. One of the serial preparations of the same node; LILLIE's silver impregnation, × 90

Fig. 23. Exp. No. 2 (1 day old), *Lnn. submandibulares*; Type D. V, development of cortex is incomplete. Secondary nodules are absent. Subcapsular sinus is broad. H.-E., × 60

Fig. 24. One of the serial preparations of the same node; Trabeculae are also absent. LILLIE's silver impregnation, × 60

Fig. 25. Exp. No. 20, *Lnn. sternales*; Injected ink fills sinuses and afferent vessel. Subcapsular, intermediate and medullary sinuses are clearly distinguished. H.-E., × 80

Fig. 26. Exp. No. 13, *Ln. popliteus*; Ink is injected into the blood vessels. Unstained preparation, × 80

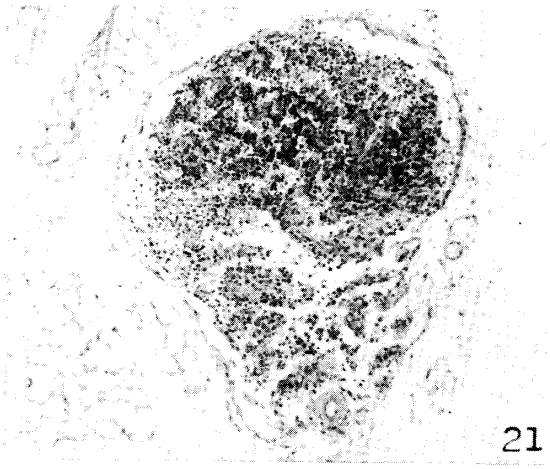
21

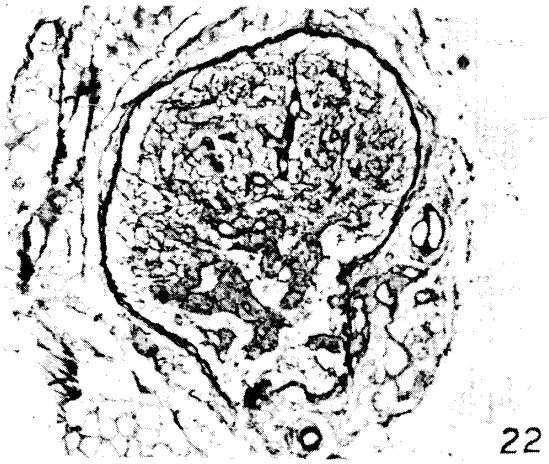
22

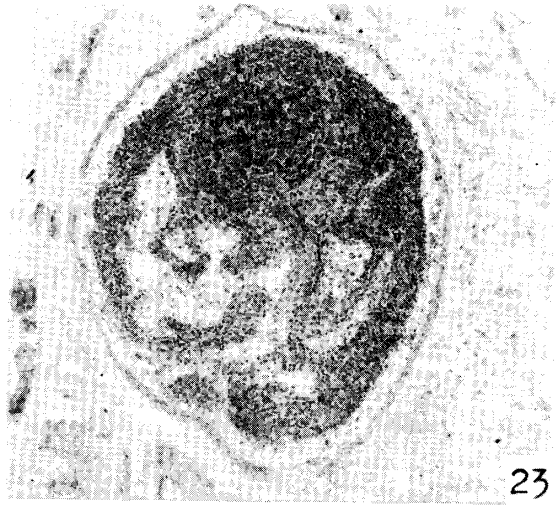
23

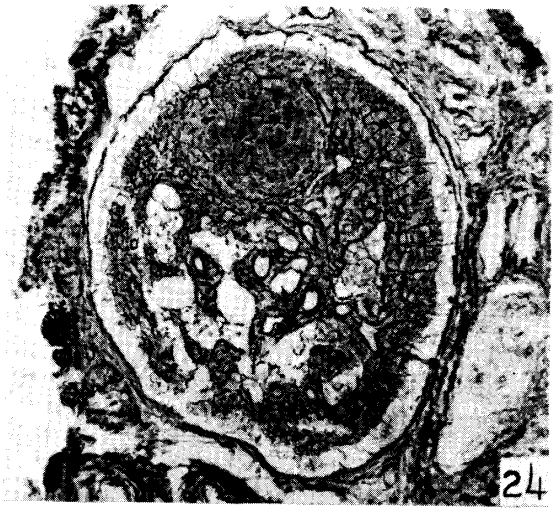
24

25

26

PLATE VI. Cortex

Fig. 27. Exp. No. 37, *Lnn. mesenterici communes*; Thick dense cortical substances are diffusely continued without taking nodular form. H.-E., × 80

Fig. 28. One of the serial preparations of the same node; Appearances of reticular meshes differ distinctly among cortex, medulla and secondary nodule. LILLIE's silver impregnation, × 80

Fig. 29. Exp. No. 29, *Lnn. parotidici caudales*; Cortical substances form a large nodule, which corresponds to EHRICH's pseud-secondary nodule. H.-E., × 80

Fig. 30. One of the serial preparations of the same node; LILLIE's silver impregnation, × 80

27

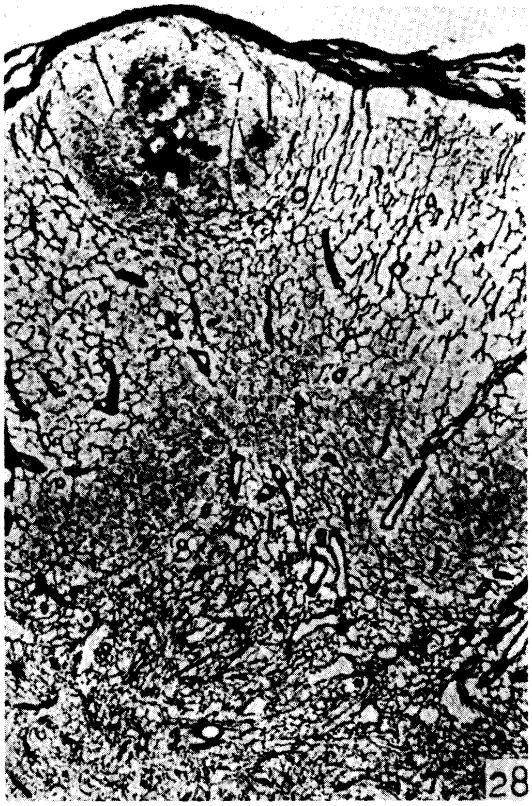
28

29

30

PLATE VII. Cortex

Fig. 31. Exp. No. 47, *Lnn. sternales*; Cortex is constituted from a thin layer of cortical substance, which has secondary nodules. It seems, at a glance, to be constituted from only secondary nodules. H.-E., × 80

Fig. 32. Exp. No. 47, *Lnn. parotidici craniales*; Wide polygonal reticular meshes in the cortex. LILLIE's silver impregnation, × 150

Fig. 33. Exp. No. 15, *Lnn. hepatogastrici*; reticular fiberless sinus, lined by a layer of endothelial cells, reaches near the secondary nodule (upper right). A post-capillary vein (left) has cuboidal endothelial cells. PAS reaction, × 360

Fig. 34. Exp. No. 42, *Lnn. retropharyngici*; A lymphoid cell, elongated in dumb-bell shape, migrates into or from a post-capillary vein through the wall. H.-E., × 760

Fig. 35. Exp. No. 47, *Lnn. mesocolici medii*; Small lymphocytes fill the reticular fiberless sinuses. They appear as dark cords. H.-E., × 180

Fig. 36. One of the serial preparations of the same node; Reticular fiberless sinuses are distinctly lined by reticulum, they open into the medullary sinus. LILLIEs' silver impregnation, × 180

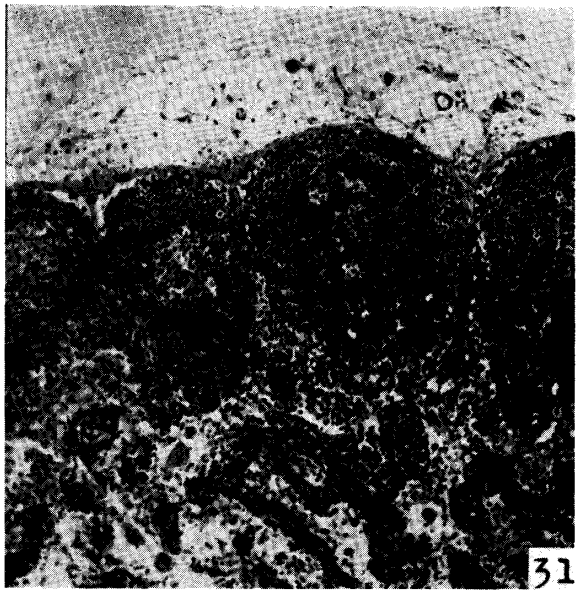
31

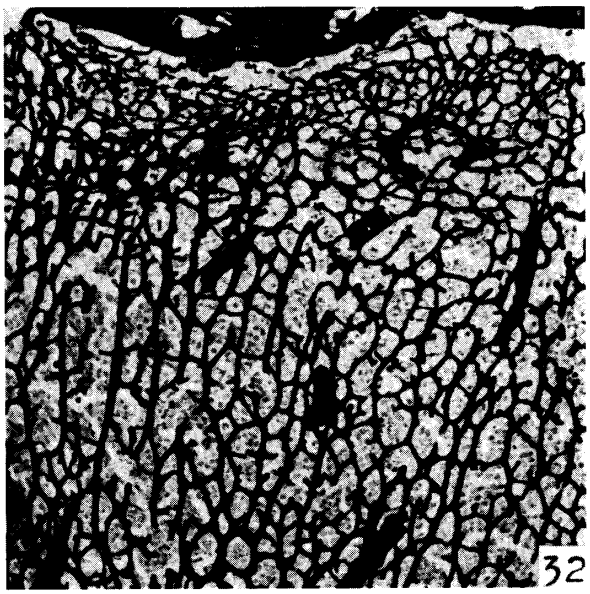
32

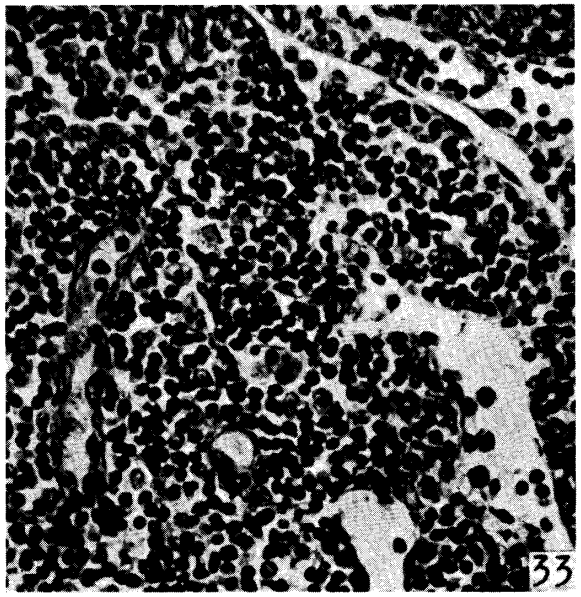
33

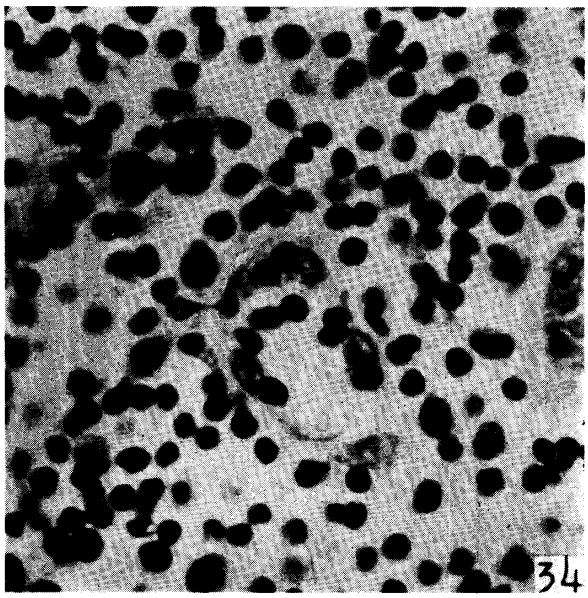
34


35

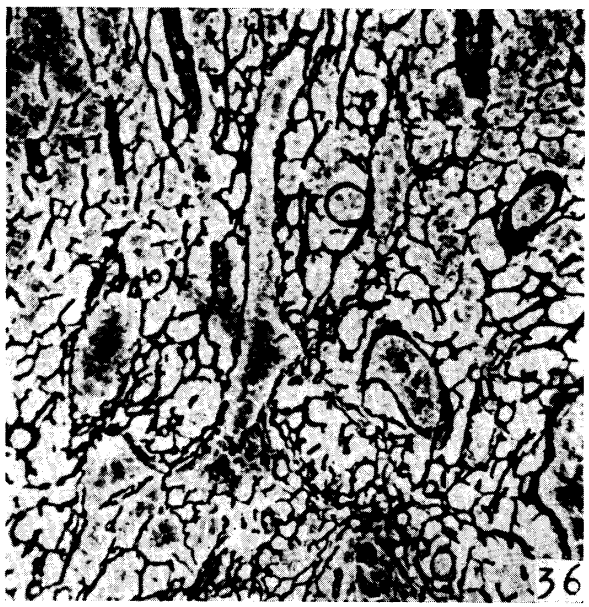
36

PLATE VIII. Cortex and Cortical trabecula

Fig. 37. Exp. No. 48, *Lnn. gastrolienales*; Small lymphocytes, lymphoblasts and their mitosis in the cortex. H.-E., × 760

Fig. 38. Exp. No. 26, *Lnn. gastrolienales*; Nuclear debris phagocytosed by reticular cells (arrow) in the cortex. H.-E., × 760

Fig. 39. Exp. No. 26, *Lnn. mesenterici communes*; Same finding (arrow). H.-E., × 760

Fig. 40. Exp. No. 15, *Lnn. mesenterici communes*; Debris (arrows) is positive to FEULGEN's reaction. FEULGEN's reaction, × 760

Fig. 41. Exp. No. 29, *Lnn. mesenterici communes*; Very well developed cortical trabecula. LILLIE's silver impregnation, × 80

Fig. 42. Exp. No. 49, *Lnn. hepatogastrici*; Moderately developed cortical trabecula. LILLIE's silver impregnation, × 80

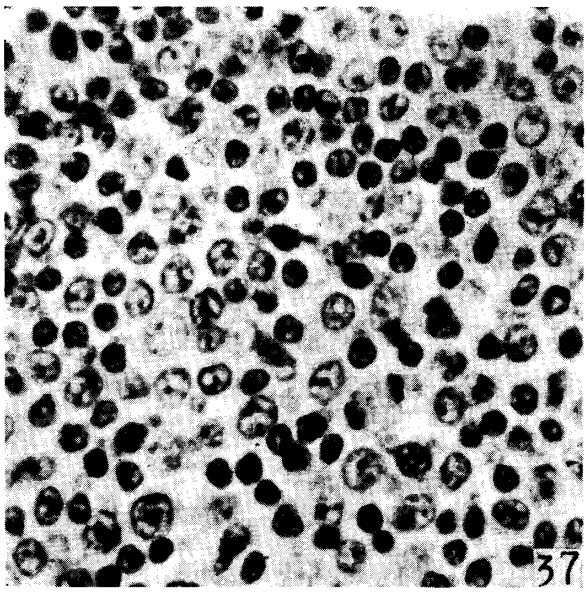
37

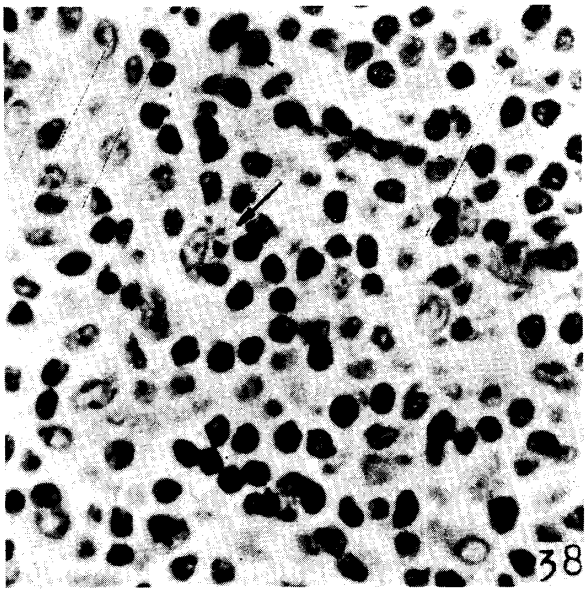
38

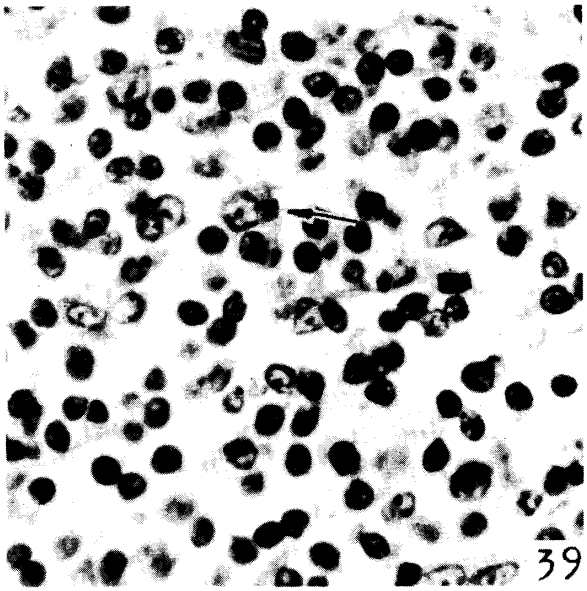
39

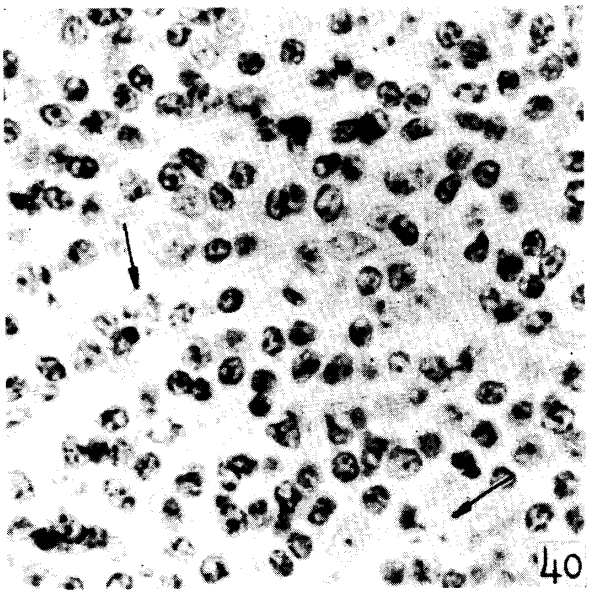
40

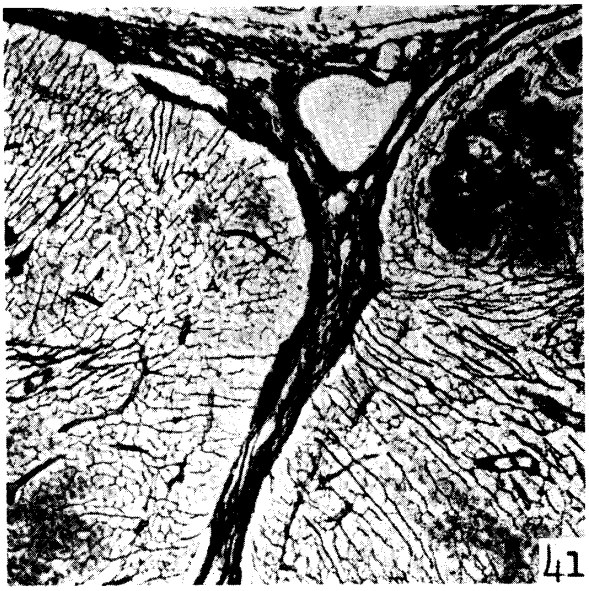
41

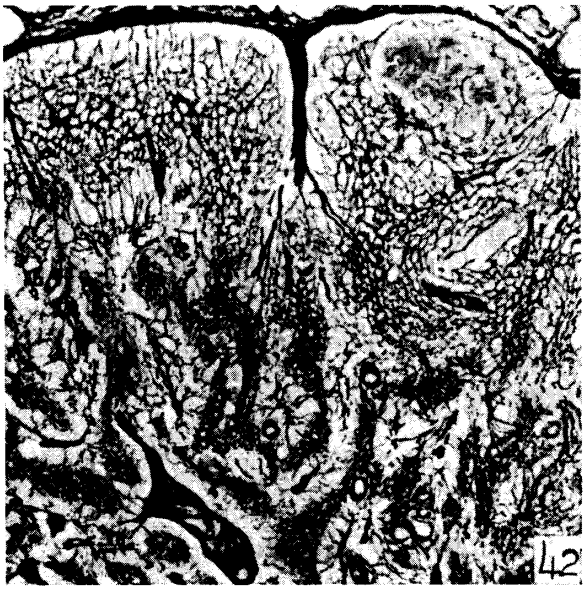
42

PLATE IX. Secondary nodules of cortex

Fig. 43. Exp. No. 7, *Lnn. hepatogastrici*; Two progressive solid secondary nodules (S.N. I). Each nodule consists nearly exclusively of small lymphocytes and a few lymphoblasts. H.-E., × 180

Fig. 44. Exp. No. 25, *Lnn. mesenterici communes*; So-called FLEMMING's secondary nodule (S.N. II). Light center consists exclusively of lymphoblasts, but dark zone situated at the sinus side is cap-like shaped. H.-E., × 100

Fig. 45. Exp. No. 13, *Lnn. retropharyngici*; Type S.N. II corresponding to CONWAY's bare type. H.-E., × 180

Fig. 46. Exp. No. 26, *Lnn. gastrolienales*; Type S.N. III corresponding to KAWAKAMI's mature secondary nodule. H.-E., × 180

Fig. 47. Exp. No. 48, *Lnn. hepatogastrici*; A regressive solid secondary nodule (S.N. IV.) H.-E., × 180

Fig. 48. Exp. No. 28, *Lnn. sternales*; Poor reticular fibers in the secondary nodules (S.N. III). LILLIE's silver impregnation, × 65

Fig. 49. Exp. No. 15, *Lnn. submandibulares*; Lymphoblasts and their mitosis in the light center of type S.N. II. Toluidin blue, × 760

Fig. 50. Exp. No. 26, *Lnn. submandibulares*; Pyroninophilic nucleolus and cytoplasm of lymphoblasts in the light center. There is also a macrophage phagocytosing nuclear debris (arrow). Pyronine-methyl green, × 760

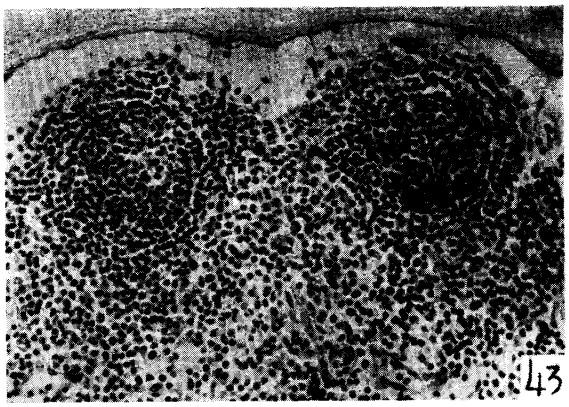
43

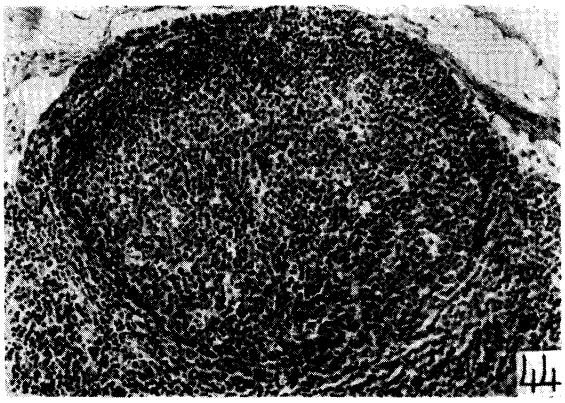
44


45

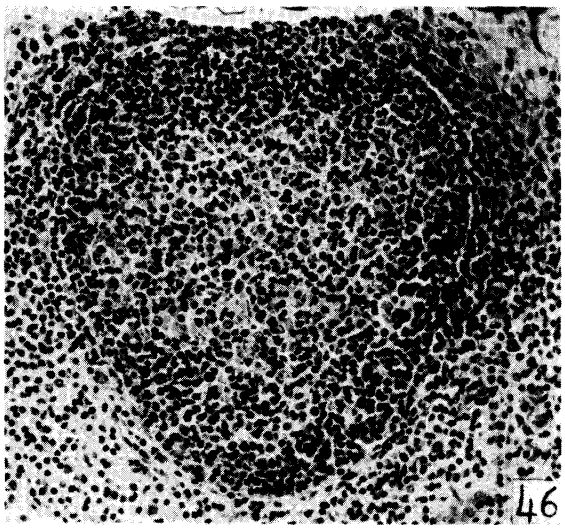
46

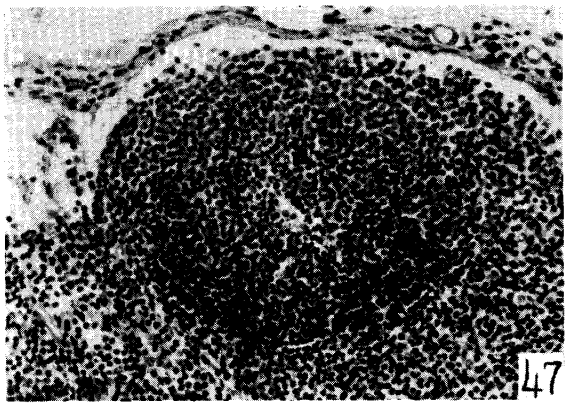
47

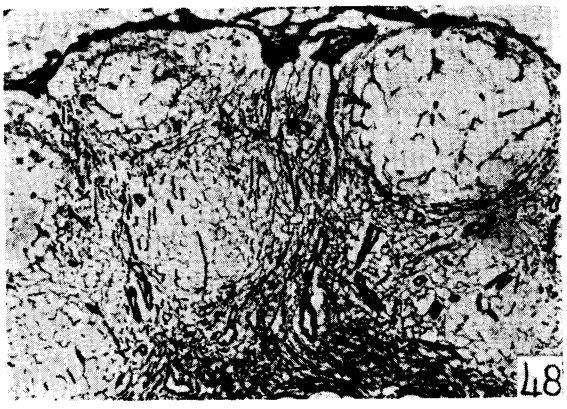
48

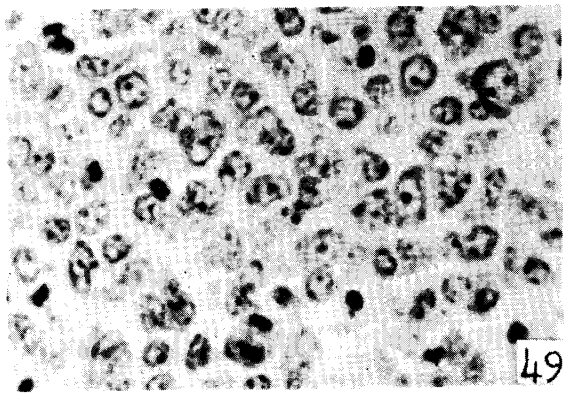
49

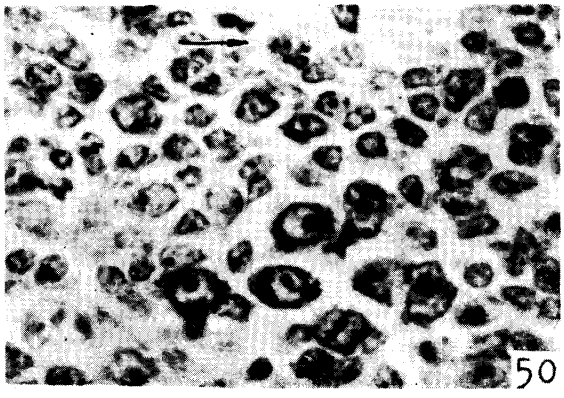
50

PLATE X. Medullary trabeculae and Medullary nodules

Fig. 51. Exp. No. 29, *Ln. popliteus*; Very well developed medullary trabeculae. GÖMÖRI's silver impregnation, × 80

Fig. 52. Exp. No. 49, *Lnn. hepatogastrici*; Poor developed medullary trabeculae. LILLIE's silver impregnation, × 80

Fig. 53. Exp. No. 28, *Lnn. hepatogastrici*; Two medullary nodules including a secondary nodule each. H.-E., × 80

Fig. 54. Exp. No. 47, *Lnn. anguli brachiocephalici*; Same finding. H.-E., × 80

Fig. 55. Exp. No. 16, *Lnn. retropharyngici*; A medullary nodule is composed of a secondary nodule and a dense ovoid mass, consisting of small lymphocytes. H.-E., × 150

Fig. 56. Exp. No. 16, Another medullary nodule of the same node; Reticular meshes of the nodular parenchyma except for a secondary nodule are similar to these of the cortex. GÖMÖRI's silver impregnation, × 150

Fig. 57. Exp. No. 28, *Lnn. hepatogastrici*; A regressive solid secondary nodule (S.N. IV) of the medullary nodule. H.-E., × 330

Fig. 58. Exp. No. 25, *Lnn. mesenterici communes*; So-called FLEMMING's secondary nodule (S.N. II) of the medullary nodule. Distinction between light center and dark zone is obscure. H.-E., × 330


51

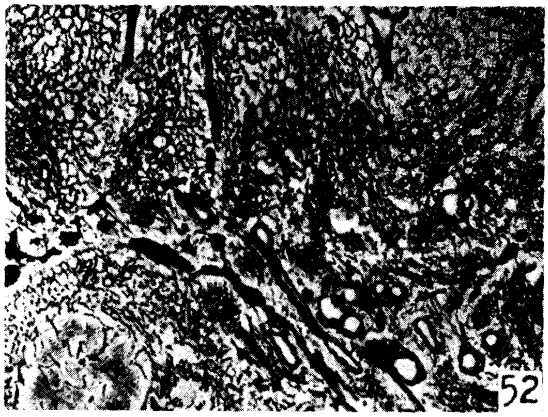
52

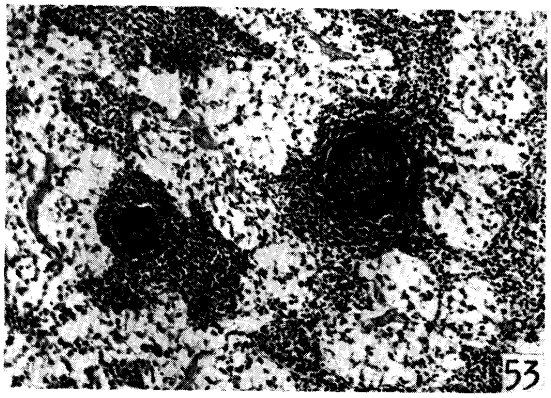
53

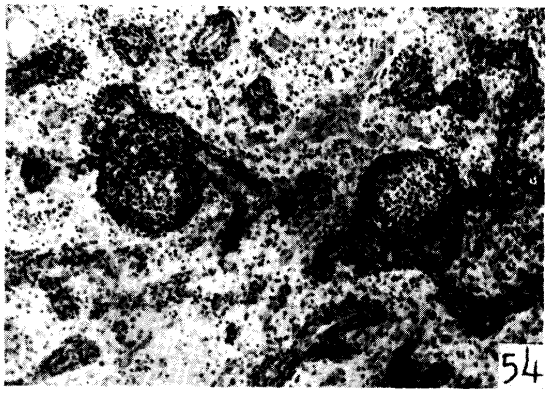
54

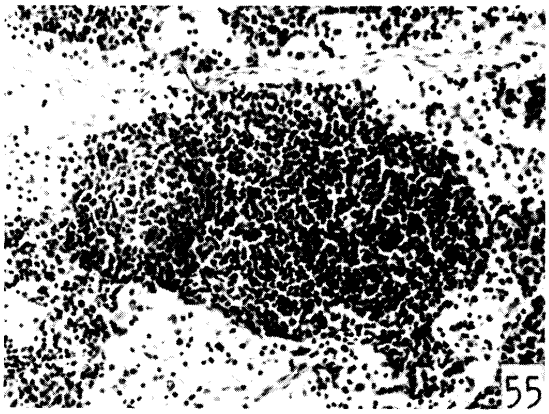
55

56

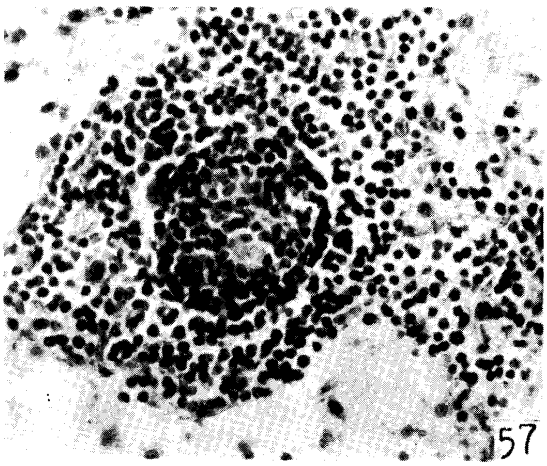
57

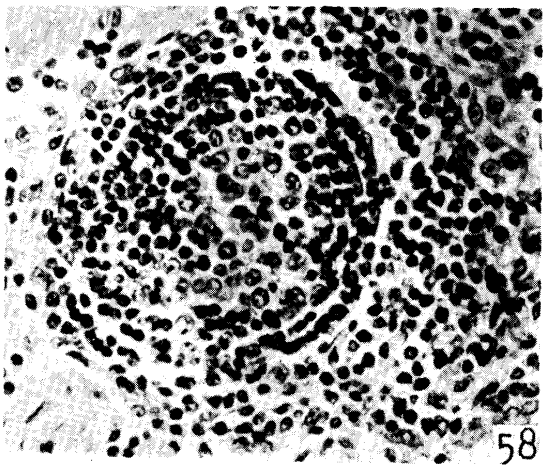
58

PLATE XI. Various cells of medulla

Fig. 59. Exp. No. 20, *Lnn. sternales*; Distribution of the plasma cells is restricted to the medullary cords, juxt-medullary zone of the cortex and upper part of the light center of the secondary nodule, but they are absent in the other cortical parenchyma. Injected ink fills sinuses. Toluidin blue, × 180

Fig. 60. Exp. No. 26, *Lnn. submandibulares*; Plasma cells have a pyroninophilic cytoplasm. Pyronine-methyl green, × 760

Fig. 61. Exp. No. 48, *Lnn. axillares craniales*; Eosionophilic granular RUSSELL's body in the medullary cord. H.-E., × 760

Fig. 62. Exp. No. 48, Another portion of the same preparation; Eosinophilic corpuscular RUSSELL's bodies. H.-E., × 760

Fig. 63. Exp. No. 15, *Lnn. submandibulares*; Mast cells in the capsule and subcapsular sinus. Toluidin blue, × 760

Fig. 64. Exp. No. 15, The medulla of the same preparation; Mast cells in the medullary cord and sinus. Toluidin blue, × 760

Fig. 65. Exp. No. 42, *Lnn. cervicales superficiales*; Mast cells have a PAS-positive cytoplasm. PAS reaction, × 760

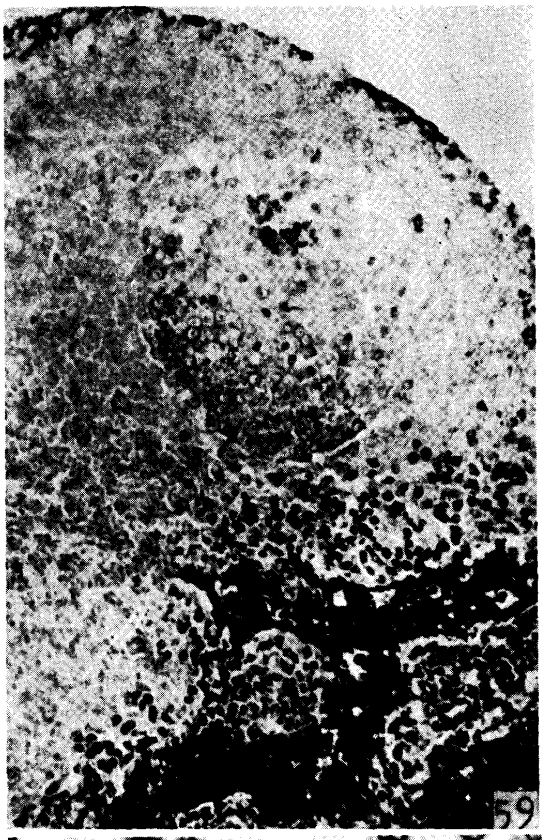
59

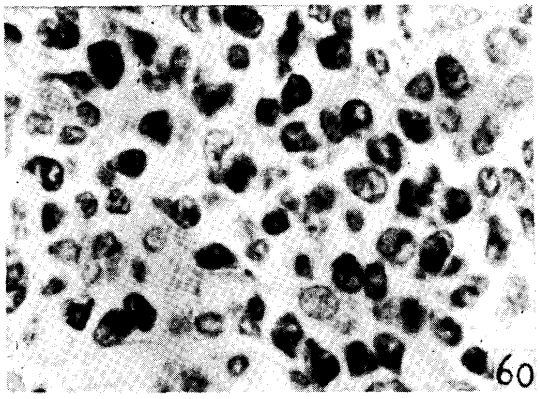
60

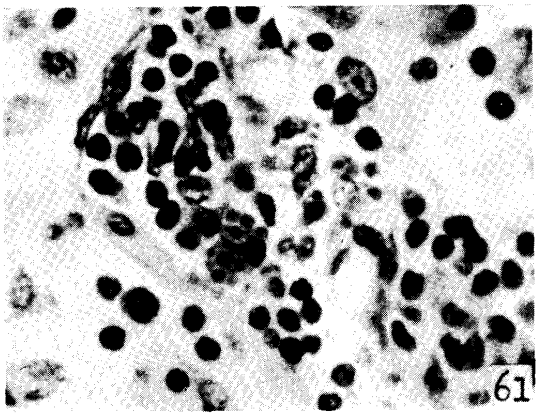
61

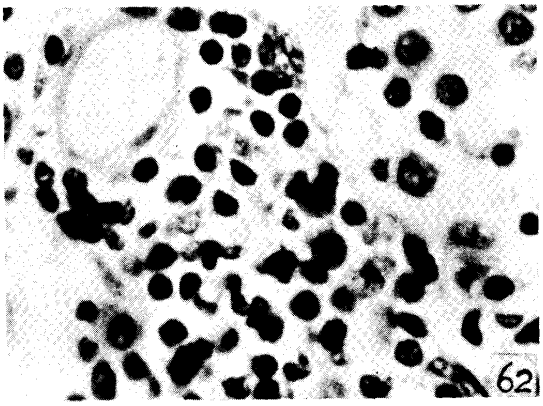
62

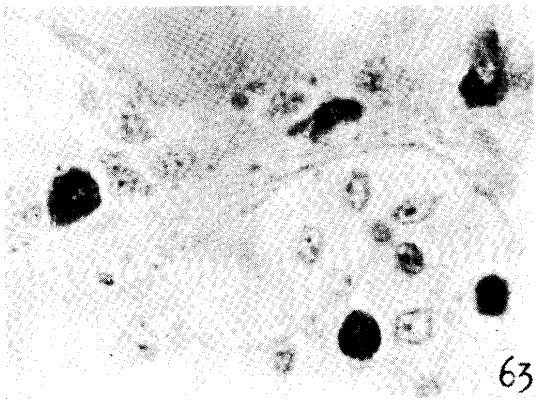
63

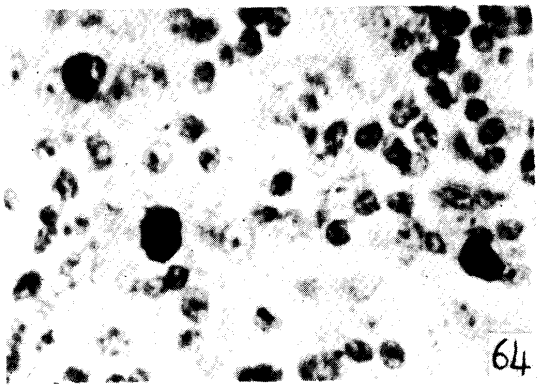
64

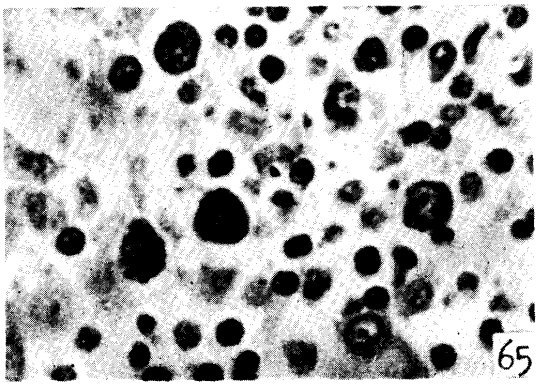
65

PLATE XII. Various cells of the medulla

Fig. 66. Exp. No. 25, *Lnn. mesenterici communes*; Sudanophilic PAS positive cells in the medullary cord. PAS reaction, × 760

Fig. 67. Exp. No. 48, *Lnn. subpylorici*; PAS-positive substance is sudanophilic in paraffin preparation. Sudan black, × 760

Fig. 68. Exp. No. 48, *Lnn. mesenterici communes*; This substance is also positive with SCHMORL's reaction for lipofuscin. SCHMORL's reaction. × 760.

Fig. 69. Exp. No. 6, *Lnn. retropharyngici*; Conspicuous erythrocytopoiesis in the medullary cord. H.-E., × 760

Fig. 70. Another portion of the same preparation; Conspicuous ectopic myelopoiesis. The field exhibits mainly granulocytopoiesis. H.-E., × 760.

Fig. 71. Exp. No. 13, *Lnn. hepatogastrici*; Two megakaryocytes and granulocytopoiesis. An eosinophilic myelocyte (arrow) and mitosis are visible. H.-E., × 760

Fig. 72. Exp. No. 37, *Lnn. tracheobronchiales craniales*; Dust cells, phagocytosing numerous coal dust particles, in the medullary cord. H.-E., × 760

Fig. 73. Exp. No. 4, *Lnn. sternales*; Sinus reticular cells are phagocytosing injected ink particles. H.-E., × 760

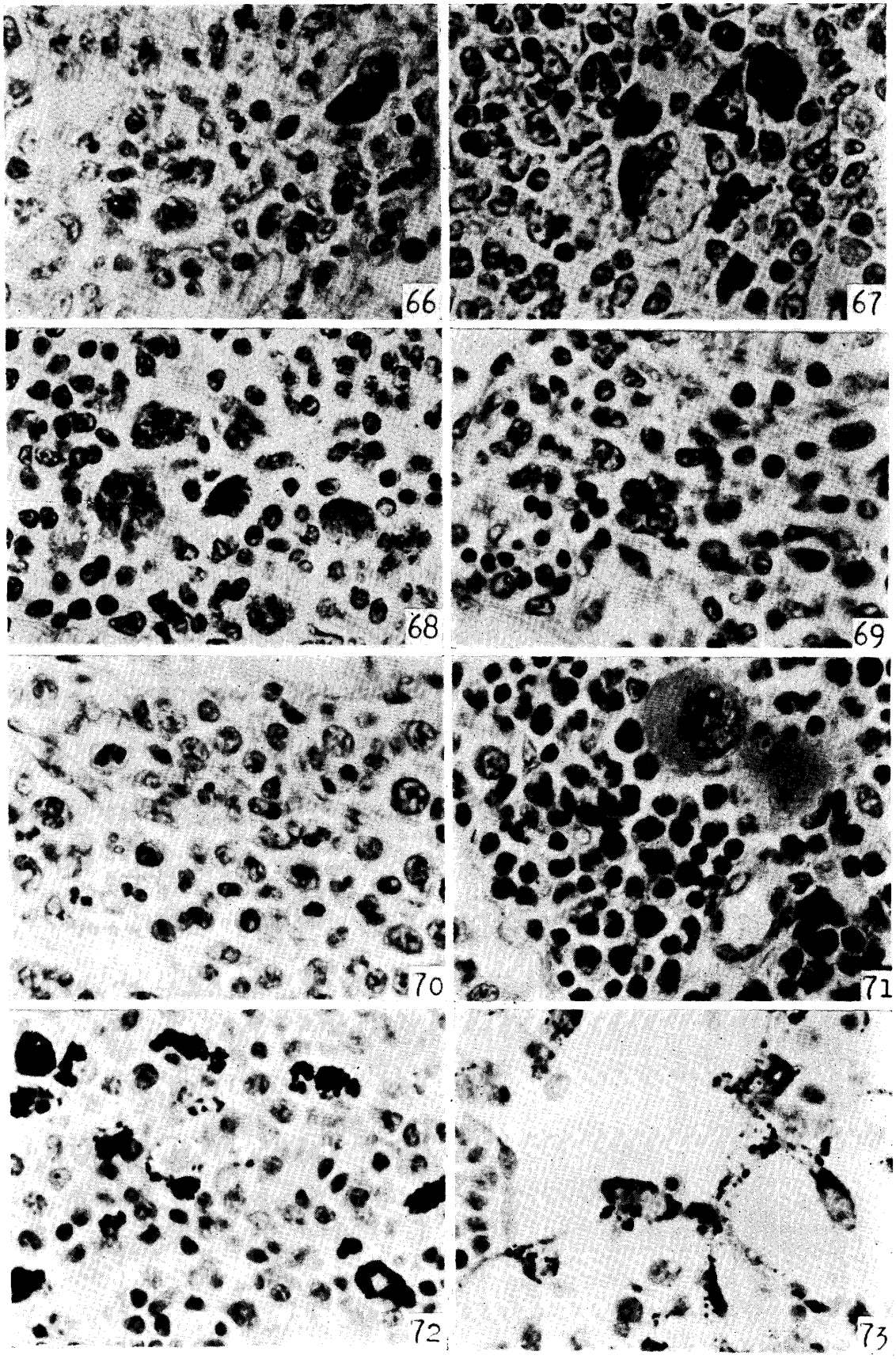
66
67
68
69
70
71
72
73