REGIONAL DIFFERENCES IN THE APPEARANCE OF VARIOUS CELLS IN THE MOUSE LYMPH NODES

Makoto SUGIMURA, Kurahiko TAKAHATA, Norio KUDO
and Kitao FURUHATA

Department of Veterinary Anatomy, Faculty of Veterinary Medicine, Hokkaido University, Sapporo, Japan

(Received for publication, Aug. 24, 1963)

INTRODUCTION

It has generally been considered that reticular cells and lymphocytes are the only normal cells appearing in the lymph nodes, though some investigators (ANDREW and ANDREW, '48; FUJII, '60; GYLLENSTEN, '50; JORDAN and MORTON, '37; KELSALL and CRABB, '59 and SUGIMURA, '62) report plasma, mast and other cells appearing in the lymph nodes under different physiological conditions. There are two opinions about the regional differences in the appearance of these cell components: FUJII[12] ('60) denied regional differences in plasma cells in the medullary cords of the rat lymph nodes, while JORDAN and MORTON ('37) and KELSALL and CRABB ('59) stated that plasma cells appear more abundantly in the mandibular and retrothymic nodes than in the other nodes in the rats and hamsters.

The clarification of types, distribution and regional difference of various cells, appearing in the lymph nodes under different physiological conditions, should offer fundamental data in experimental studies of the organ.

In this paper the writers will attempt to clarify the types and appearance of various cells in mouse lymph nodes, with special reference to regional differences.

MATERIAL AND METHODS

As material, 263 lymph nodes obtained from 13 different locations of 20 mature mice (inbred dd strain) were used (see Table 1).

All mice were given a stock diet (NMF type; Oriental Yeast Co.) and water ad libitum in their usual environment.

Fresh materials were fixed in CARNOY's fluid, 10% neutral buffered formalin, cooled acetone and acetone-alcohol. Following fixation, the specimens were embedded in paraffin, sectioned serially $4\sim6\,\mu$ thick and treated with hematoxylin-eosin, azan and LILLIE's silver impregnation. All sections were subjected to the following histochemical procedures; FEULGEN's reaction for DNA, TRAFT's pyronine-methyl green stain with ribonuclease control for RNA, MCMANUS's PAS reaction with saliva control for carbohydrate, OHNO et al.'s toluidin blue stain for acid mucopolysaccharide, SCHMORL's and MALLORY's reactions for lipofuscin, and DEMPSY's method for alkaline and acid phosphatase after incubation in sodium

TABLE 1. *Cases from which Lymph Nodes Were Obtained*

MALE MICE			FEMALE MICE		
Exp. No.	Age (Months)	Weight (g)	Exp. No.	Age (Months)	Weight (g)
1	3.5	26.5	11	5	23.5
2	"	25.0	12	"	25.0
3	"	26.5	13	7	23.5
4	"	25.5	14	"	28.0
5	"	24.0	15	10.5	24.0
6	4	32.5	16	"	26.0
7	"	37.0	17	"	22.5
8	7	26.0	18	"	29.0
9	"	25.0	19	12.5	30.0
10	7.5	28.5	20	"	27.5

β-glycerophosphate solution. When necessary, some sections were treated with PERLS-STIEDA's Prussian blue reaction for iron containing pigments and with DADDI's sudan III and LISON's sudan black for lipid containing pigments in paraffin section.

OBSERVATIONS

A. Cell Types Distinguished in the Mouse Lymph Nodes

The following cell types were distinguished in the mouse lymph nodes:

1) Small lymphocytes measure from 4 to 6 μ in diameter. Their scanty cytoplasm appears to be negative to the histochemical methods used.

2) Large lymphocytes (including the so-called medium lymphocytes) measure from 8 to 15 μ in diameter. Their broad cytoplasm and one or two large nucleoli are stained pinkish-red with pyronine-methyl green (Figs. 1 and 3), and metachromatically in purple-blue with toluidin blue (Fig. 10). The staining property, which is lost with treatment of ribonuclease, is regarded as rich in RNA. However, their cytoplasm is negative with other procedures. Possibly the so-called plasmablasts are contained in the large lymphocytes defined above.

3) Plasma cells measure from 10 to 20 μ. The staining property of their cytoplasm is the same as that of large lymphocytes, but no pyroninophilic nucleoli are found in mature plasma cells (Figs. 2 and 4). Sometimes, the cytoplasm is active with alkaline phosphatase (Fig. 11). Actually, it is not difficult to differentiate between the mature plasma cells, which form a broad layer in the cell body and have a pale area adjacent to the round darkly-stained nucleus, and the large lymphocytes.

The RUSSELL's body may be derived from plasma cells. The body is composed of eosinophilic glassy granules. They appear to be positive with PAS and SCHMORL's reactions, but to be negative with other histochemical methods (Figs. 5 and 6).

4) Mast cells, in the sinus usually 10~20 μ and in the capsula sometimes over 20 μ in longest diameter, are distinguished by a special feature—their broad cytoplasm is filled

with granules which are stained metachromatically in purple with toluidin blue (Figs. 8 and 9). The granules are also stained in purple-red with pyronine-methyl green (Figs. 2 and 7), but appear to be negative with PAS reaction. Moreover, the granules react deeply in red with MALLORY's reaction and deeply in blue with SCHMORL's reaction.

5) Four types of PAS positive cells may be distinguished:

a) PAS positive cells type I are ordinary reticular cells, measuring 10 to 20 μ, which are star-shaped or irregular. Their cytoplasm is stained faintly in pinkish-red with PAS reaction and sometimes with pyronine-methyl green, but is negative with other procedures except for showing the activity of acid phosphatase.

b) PAS positive cell type II is the above-mentioned RUSSELL's body.

c) PAS positive cell type III, from 10 to 20 μ and sometimes over 35 μ in size, is round or irregular in shape. Its broad cytoplasm includes fine granules which are strongly stained in red with PAS reaction and in orange or black with sudan III or sudan black in paraffin sections (Figs. 13, 14 and 15), but appear to be negative with Prussian blue reaction. The granules are also stained in purple-red with pyronine-methyl green, but do not disappear with incubation of ribonuclease. The cells of this type sometimes contain nuclear debris and hemosiderin pigments in their cytoplasm (Figs. 13 and 14).

d) PAS positive cell type IV has characteristics similar to type III cells, but the granules appear to be strongly positive with SCHMORL's reaction and feebly positive with MALLORY's reaction (Fig. 16).

6) Adipose tissues are observed as round vacuoles, about 35 μ in diameter, in paraffin sections (Figs. 17 and 18).

7) Blood cells and extra-medullary myelopoiesis, primarily granulocytopoiesis and occasionally megakaryocytes, are frequently found in the medullary cords.

The PAS positive cells of types III and IV appear to be active with acid phosphatase. Therefore, both of those types of cells may be derived from ordinary reticular cells.

The activity of acid phosphatase appears in the nuclei of all types of cells (Fig. 12).

Alkaline phosphatase is also active in the endothelial cells of arterioles and occasionally feebly in the cortical parenchyma and secondary nodules (Fig. 11).

Most of the above-mentioned cells are found throughout the medullary cords and sinuses, but plasma cells, adipose tissues and extra-medullary myelopoiesis do not appear in the sinuses. In the cortex, on the other hand, there are no plasma cells (except for the secondary nodule and juxta-medullary area of the cortex) and no PAS positive cells of type IV.

The distributions of various cells in the mouse nodes will be reported in detail a future paper.

Since there was no conspicuous regional difference in the appearance of the different cell types in the cortex, this paper will describe the regional difference in appearance of the cells in the medulla.

B. Differential Cell Counts in the Medulla

Different cells were counted in the nodes of separate locations, as presented in table 2.

Over 200 cells were counted in the medullary cord of every node and the mean numbers of large lymphocytes and plasma cells were represented as percentages.

TABLE 2. *Differential Cell Counts from Lymph Nodes in Different Location*

LYMPH NODES	N.N.	LARGE LYMPHOCYTES	PLASMA CELLS	MAST CELLS	PAS POSITIVE CELLS OF TYPE IV		ADIPOSE TISSUES
		$\bar{x} \pm s$	$\bar{x} \pm s$	$\bar{x} \pm s$	$\bar{x} \pm s$	%	%
Submandibular	29	2.1±0.7	43.0±7.5	53.5±21.7	0 ± 0	0	0
Cervical	22	3.3±1.5	31.7±8.6	9.9± 5.8	0 ± 0	0	10.5
Deep Axillary	21	2.1±1.0	15.5±4.6	27.2±14.4	0.2± 0.5	10.5	0
Inguinal	20	2.1±0.8	15.9±6.7	38.6±21.3	0 ± 0	0	0
Superficial Axillary	21	2.1±0.9	17.9±4.5	60.7±23.3	0 ± 0	0	20.0
Popliteal	20	2.0±1.6	15.1±5.6	121.5±34.4	0.1± 0.2	5.9	5.3
Iliac	21	2.6±1.0	22.4±4.7	13.3± 9.4	0.5± 1.5	12.5	10.5
Caudal	14	3.0±1.6	24.4±9.0	16.0±17.5	1.1± 3.6	9.1	7.9
Renal	20	2.7±1.1	22.4±5.9	9.7±11.4	5.0±10.6	35.3	31.6
Coeliac	24	2.5±1.0	16.4±7.3	0.8± 0.7	10.7±17.0	52.9	5.3
Mesenteric	21	4.7±1.3	8.4±4.6	1.4± 1.4	14.1±22.3	50.0	0
Mediastinal	21	3.6±1.8	22.2±5.7	12.3±11.3	6.0± 8.5	40.0	50.0
Tracheobronchial	9	4.5±0.9	23.6±9.4	4.1±4.8	7.6±16.1	28.6	0

Remaks: N.N.; Numbers of nodes examined
$\bar{x} \pm s$; Mean ± Standard deviation
%; Occurrence ratio

To determine the mean number of mast cells and PAS positive cells of type IV, cells were counted in 20 fields (one field: 10,000 square μ) in the medulla of every node.

The numbers of cells in some nodes, which seemed to be extraordinary, were rejected from counts in this table (SIMIRNOFF's test of rejection; $P<0.01$).

Occurrence ratios of PAS positive cells and adipose tissues were represented as percentage counted from the numbers of cases in whose nodes those cells or tissues appear.

From this table, it is suggested that there are more large lymphocytes in the medullary cords of the mesenteric, mediastinal and tracheobronchial nodes than in those of the other nodes (cf. Figs. 2, 3, 4, 8, 9 and 10).

There are a few plasma cells scattered in the medullary cords of the deep and superficial axillary, inguinal, popliteal, and coeliac nodes and very few in the mesenteric nodes. Many plasma cells are found in the renal, iliac, caudal, mediastinal and tracheobronchial nodes. The largest number of cells appear in the submandibular and cervical nodes (cf. Figs. 2, 3, 4, 8, 9 and 10).

Many mast cells are found in the nodes in the superficial regions of the body, though the appearance of the cells is somewhat variable. A small number of mast cells appear in the nodes of the deeper regions, and a very small number in the body cavity (Figs. 8, 9 and 10).

More PAS positive cells of type IV seem to be found in the nodes situated in the body cavity, especially in the abdominal cavity, than in those nodes in the superficial areas (Fig. 16). The occurrence of this type of cells, however, is various considerably.

Adipose tissues appear more frequently in the superficial axillary, renal and mediastinal nodes (Figs. 17 and 18).

C. Regional Differences in Number and Types of Cells

Five groups are classified by regional differences in the number and types of cells appearing in the nodes of each region (Table 3).

In this table, the differences between the marks (−, ±, +, ++, +++ and ++++) denoting the numbers of large lymphocytes, plasma and mast cells are statistically significant ($P<0.05$). But, the difference in numbers of PAS positive cells is not statistically significant ($P: 0.2\sim0.1$). Therefore, the marks of PAS positive cells and adipose tissues were subjectively decided by the differences between their occurrence degrees.

First group (submandibular and cervical nodes): Noteworthy in this group is the number of plasma cells appearing in the medullary cords. On the other hand, large lymphocytes, PAS positive cells of type IV and adipose tissues are rarely found. Mast cells are observed in small numbers in the cervical nodes, and in considerable numbers in the submandibular nodes.

Second group (superficial axillary, deep axillary, inguinal and popliteal nodes): A small number of plasma cells and a large number of mast cells are conspicuous in this group.

Third group (iliac, renal, caudal and mediastinal nodes): In this group, a considerable number of plasma cells are found, but fewer than the first group. There are a few mast cells and PAS positive cells. Adipose tissue and PAS positive cells are more frequently found in the renal and mediastinal nodes than in the iliac and caudal nodes.

TABLE 3. *Grouping as to Regional Difference*

GROUPS DIVIDED AS TO REGIONAL DIFFERENCE	LYMPH NODES	LARGE LYMPHOCYTES	PLASMA CELLS	MAST CELLS	PAS POSITIVE CELLS OF TYPE IV	ADIPOSE TISSUES
I	Submandibular	+	++++	++	−	−
	Cervical	+	+++	+	−	+
II	Deep Axillary	+	+	++	±	−
	Inguinal	+	+	++	−	−
	Superficial Axillary	+	+	++	−	+
	Popliteal	+	+	+++	±	±
III	Iliac	+	++	+	±	+
	Caudal	+	++	+	±	±
	Renal	+	++	+	+	++
	Mediastial	+	++	+	+	++
IV	Tracheobronchial	++	++	±	+	−
V	Coeliac	+	+	±	++	±
	Mesenteric	++	±	±	++	−

Remarks: − ; Absent, ± ; Scarce, + ; Slight, ++; Moderate, +++; Numerous, ++++; More Numerous

Fourth group (tracheobronchial node): Large lymphocytes and plasma cells are fairly numerous, but there are few other cells.

Fifth group (mesenteric and coeliac nodes): Rare plasma and mast cells are a special feature of this group. Moreover, PAS positive cells are frequently found in this group. The mesenteric nodes in which there are many large lymphocytes may be distinguished from the coeliac nodes.

DISCUSSIONS

In this study, the writers clarified the regional difference as to appearance degrees of large lymphocytes, plasma cells, mast cells, PAS positive cells of the writers' type IV and adipose tissues in the medulla of the mature mouse lymph nodes.

A few pyroninophilic large lymphocytes were distributed in the all parts of the nodes, but there were more in the light center of the secondary nodules (Fig. 1). It has been already reported by UNNO and HANAOKA that the cells increase with administration of egg albumin. As to the regional difference, they stated briefly that there are many pyroninophilic large lymphocytes (UNNO et al.'s lymphogonia) in the sinuses of the mesenteric nodes.

The present writers found many pyroninophilic large lymphocytes in the medullary cords of the mesenteric, mediastinal and tracheobronchial nodes. But the possibility remains that immature plasma cells (plasmablasts) may be found in the large lymphocytes definited by the present writers. The writers could not be sure that these large lymphocytes appear in the presence of large numbers of plasma cells. That is to say, most of the large lymphocytes may differ from the so-called plasmablasts. The frequent mitosis observed in the lymph nodes may prove that they actively produce small lymphocytes.

The fact that the plasma cells produce antibodies has drawn the attention of many investigators (AMANO, '61; COONS et al., '55; EHRICH et al., '49; FAGRAEUS, '48). Some investigators suspect that plasma cells appear under normal physiological conditions (STERNBERG, '26), but many investigators believe that the cells are found in the medullary cords and juxta-medullary zone of the cortex of the lymph nodes under normal physiological condition (ANDREW and ANDREW, '48; FUJII,[12] '60; GYLLENSTEN, '50 and SUGIMURA, '62) and increase under some pathological or experimental conditions, such as X-ray irradiation (DUNN, '54; AWAYA, et al., '59 and '61) and with ageing (ANDREW and ANDREW, '48 and DUNN, '54). As to the regional differences, it is generally considered that many plasma cells are found in the mesenteric nodes located on the course of absorption of nutriments. PARSONS ('43) stated that many plasma cells are found in the submandibular nodes as they are in the mesenteric nodes. On the other hand, JORDAN and MORTON ('37) and KELSALL and CRABB ('59) maintained that there are more plasma cells in the

submandibular and retrothymic nodes than there are in the other nodes. Contrarily, FUJII[12] ('60) denied such a regional difference in rats.

The present writers proved that there were many plasma cells in the submandibular and cervical nodes, but that few plasma cells are usually found in the mesenteric and coeliac nodes. These findings may support JORDAN et al.'s opinion. From the present result, it is suggested that the nodes draining the mucous membrane of the oral cavity are initially affected by external stimuli, but surely this is a normal physiological change found in usual environments.

Distributions of mast cells have been described by ANDREW and ANDREW (rat), GYLLENSTEN (guinea pig), JORDAN and MORTON (rat), KELSALL and CRABB (hamster), SMITH and WOOD (rat) and SUGIMURA (cat). The cells increase in the lymph node and thymus with X-ray irradiation (BLOOM, and KELSALL and CRABB) and in the lymph nodes of the rat with advanced age (ANDREW and ANDREW). By ONO, SHIBUZAWA and RI ('52), the mast cells release granules from their cytoplasm under stress and macrophages are activated their phagocytic ability. On the other hand, regional differences in the appearance of mast cells in mice seems only to have been observed by the present writers.

In the present observation, more mast cells are found in nodes located in superficial areas than in those in the deeper ones. The cells are rarely found in the mesenteric and coeliac nodes. Certainly, there are many mast cells in the nodes draining the subcutis, but the present writers have no data to explain this.

Sudanophilic PAS positive cells are reported in cat lymph nodes (SUGIMURA). Similar cells are found in mouse lymph nodes (lipochrome-like substance; DUNN) and in those of man (lipofuscin; HAMAZAKI).

The present writers separate PAS positive cells into four types: Type I is ordinary reticular cells. Type II is RUSSELL's bodies. Types III and IV are sudanophilic. The latter moreover appears to have a positive SCHMORL's reaction. The substance found in the cells of type IV may be regarded as glycolipin with a lipofuscin-like nature. But, SCHMORL's and MALLORY's reactions are seemed not to have a staining property for lipofuscin, because RUSSELL's bodies, elastic lamellae of arteries, and the horny layer of the epidermis were also positive with the former and the granules of mast cells strongly so with the latter. Therefore, the present writers cannot state positively that the substance of PAS positive cells of type IV is lipofuscin.

In this observation, only the PAS positive cells of type IV were observed for regional differences. These cells are frequently found in the nodes draining the digestive organs in the abdominal cavity. It is a interesting fact that PAS positive cells of type IV were frequently found in the nodes in which only a few mast cells appear, and both cell types show similar staining properties with pyronine-

methyl green, SCHMORL's and MALLORY's reactions, though the intensity of their reaction differs somewhat. If the mast cells frequently release granules from their cytoplasm in the mesenteric and coeliac nodes, and consequently there are few occasions in which mast cells are found in these nodes, it may be suggested that PAS positive cell of type IV and mast cells are closely related in function.

It is an accepted opinion that adipose tissues are usually found in the lymph nodes as a senile change. But, SUGIMURA stated that no tendency for adipose tissues to increase with age could be ascertained. He maintained that it is more likely that adipose tissues are related to regional difference in the cat. The same opinion was also reported by ZACHAROW.

In mature mice, the present writers observed that adipose tissues appear more frequently in the superficial axillary, renal and mediastinal nodes than in the other nodes, but not in such numbers as may be found in cat lymph nodes.

Based on the appearance of the above-mentioned five types of cells, the present writers classified mouse lymph nodes into five groups. From these findings, it should be asserted that the selection of the location of nodes is an essential factor in various experimental studies with a view to clarifying the function of some cells in the lymph nodes.

SUMMARY

An attempt was made to clarify the cell types and regional differences in the appearance of various cells found in 263 lymph nodes, obtained from 13 different locations in 20 mature mice.

By histological and histochemical procedures, small lymphocytes, large lymphocytes, plasma cells, mast cells, PAS positive cells of four types, extra-medullary myelopoiesis and adipose tissues were distinguished in the mouse lymph nodes.

Regional differences were clarified as to appearance of large lymphocytes, plasma cells, mast cells, PAS positive cells of type IV, having glycolipin which shows lipofuscin-like nature, and adipose tissues in the medulla.

Based on these findings, the mouse lymph nodes were classified in five groups. First group (submandibular and cervical nodes): Many plasma cells. Second group (superficial axillary, deep axillary, inguinal and popliteal nodes): Many mast cells. Third group (iliac, caudal, renal and mediastinal nodes): Intermediate type. Adipose tissue is often found in renal and mediastinal nodes. Fourth group (tracheobronchial node): Also intermediate type. However, large lymphocytes are fairly frequently observed. Fifth group (mesenteric and coeliac nodes): Very few plasma and mast cells. But, many PAS positive cells of type IV.

REFERENCES

1) AMANO, S. (1961): *Nichi-ketsu-kai-shi* (*Acta haem. jap.*), **24**, 1 (in Japanese with English summary)
2) ANDREW, W. & N. V. ANDREW (1948): *Amer. J. Anat.*, **82**, 105
3) AWAYA, K., H. FUJII & A. INADA (1959): *Kaibo Z.* (*Acta anat. nippon.*), **34**, 111 (in Japanese)
4) AWAYA, K., H. FUJII & H. HORI (1961): *Ibid.*, **36**, 359 (in Japanese)
5) BLOOM, W. (1954): Radiation Biology, Edited by A. HOLLAENDER, Vol. **1**, New York (Cited by KELSALL & CRABB)
6) COONS, A. H., E. H. LEDUC & J. M. CONNOLLY (1955): *J. exp. Med.*, **102**, 49
7) DUNN, T. B. (1954): Reticular Tissue in Mice, J. nat. Cancer Inst., **14**, 1281 (Translated into Japanese by N. IDA)
8) EHRICH, W. E. & T. N. HARRIS (1942): *J. exp. Med.*, **76**, 355
9) EHRICH, W. E. & D. L. DRABKIN & C. F. FORMAN (1949): *Ibid.*, **90**, 157
10) FAGRAEUS, A. (1948): *J. Immunol.*, **58**, 1
11) FUJII, H. (1960): *Arch. Hist. Jap.*, **18**, 479
12) FUJII, H. (1960): *Ibid.*, **19**, 519
13) GYLLENSTEN, L. (1950): *Acta anat.*, **10**, 130
14) HAMAZAKI, Y. (1938): *Virchows Arch.*, **301**, 490
15) HANAOKA, M. (1963): Ketsuekigaku Zensho (The Complete Works of Hematology), Vol. **1**, Morphology, Maruzen (in Japanese)
16) HELLMAN, T. (1930): Lymphgefässe, Lymphknötchen und Lymphknoten, MÖLLENDORF's Handbuch der Mikroskopischen Anatomie, **6**, 1 Teil, Berlin
17) JORDAN, H. E. & C. B. MORTON (1937): *Amer. J. Anat.*, **61**, 407
18) KELSALL, M. A. & E. D. CRABB (1959): Lymphocytes and Mast Cells, The Williams & Wilkins Company, Baltimore
19) PARSONS, L. D. (1943): *J. Path. Bact.*, **55**, 397
20) SMITH, R. O. & W. B. WOOD (1949): *J. exp. Med.*, **90**, 555
21) STERNBERG, C. (1926): Die Lymphknoten, Handbuch der Spezillen Pathologischen Anatomie und Histologie von HENKE-LUBARSCH, Bd. **1**, 1 Teil, Berlin (Cited by HELLMAN)
22) SUGIMURA, M. (1962): *Jap. J. vet. Res.*, **10**, 155
23) UNNO, G. & M. HANAOKA (1952): *Symposium on Hematology*, **6**, 62 (in Japanese)
24) ZACHAROW, J. (1891): *Inaug.-Diss.*, St. Petersburg (Cited by HELLMAN)

EXPLANATION OF PLATES

PLATE I.

Fig. 1. Exp. No. 14, Coeliac node; Many large lymphocytes in the light center of the secondary nodule and scattered in the other cortical parenchyma. Pyronine-methyl green, ×210

Fig. 2. Exp. No. 7, Submandibular node; Many plasma cells in the medullary cords (left). No plasma cells in the medullary cords adjacent to the cortex in this specimen (right). Three mast cells are visible in the sinuses. Pyronine-methyl green, ×350

Fig. 3. Exp. No. 6, Mesenteric node; Many large lymphocytes in the medullary cords of this node, but few plasma cells. Pyroninophilic cytoplasm and nucleoli of large lymphocytes are clearly illustrated. Pyronine-methyl green, ×840

Fig. 4. Exp. No. 16, Caudal node; Plasma cells are fairly numerous. Pyronine-methyl green, ×840

Fig. 5. Exp. No. 17, Popliteal node; Three RUSSELL's bodies appear to have positive PAS reaction. ×840

Fig. 6. Exp. No. 17, Inguinal node; The RUSSELL's bodies also have positive SCHMORL's reaction. ×840

PLATE II.

Fig. 7. Exp. No. 7, Submandibular node; Two mast cells found in the sinus are metachromatically stained in purple-red (black in figure) with Pyronine-methyl green. ×840

Fig. 8. Exp. No. 20, Inguinal node; Many mast cells in the medulla. Toluidin blue, ×420

Fig. 9. Exp. No. 12, Iliac node; A few mast cells are observed in this node. Toluidin blue, ×420

Fig. 10. Exp. No. 6, Mesenteric nodes; No mast cells in this node. Fairly numerous large lymphocytes in the medullary cord. Toluidin blue, ×420

Fig. 11. Exp. No. 19, Superficial axillary node; Alkaline phosphatase active in the endothelium of the arterioles and in the fields of the plasma cells. DEMPSY's method, ×210

Fig. 12. Another preparation of the same node; Acid phosphatase active in the nuclei of all cells and in the cytoplasm of the sinus reticular cells. DEMPSY's method, ×210

PLATE III.

Fig. 13. Exp. No. 16, Coeliac node; PAS positive cells of type III are in groups in the cortex. Some cells have phagocytosed nuclear debris in their cytoplasm. PAS reaction, ×840

Fig. 14. Exp. No. 16, Mediastinal node; PAS positive cells of type III in the medulla. Some cells contain hemosiderin pigments (PAS negative transparent granules in figure) in their cytoplasm. PAS reaction, ×840

Fig. 15. Exp. No. 12, Coeliac node; Cells of type III are stained in black with sudan black in a paraffin section. A postcapillary vein with high endothelial cells are found (upper left). Sudan black, ×840

Fig. 16. Exp. No. 17, Coeliac node; PAS positive cells of type IV appear to have positive SCHMORL's reaction. ×840

Fig. 17. Exp. No. 14, Mediastinal node; Conspicuous adipose tissue. H.-E., ×54

Fig. 18. Exp. No. 15, Renal node; Some adipose tissue. H.-E., ×54

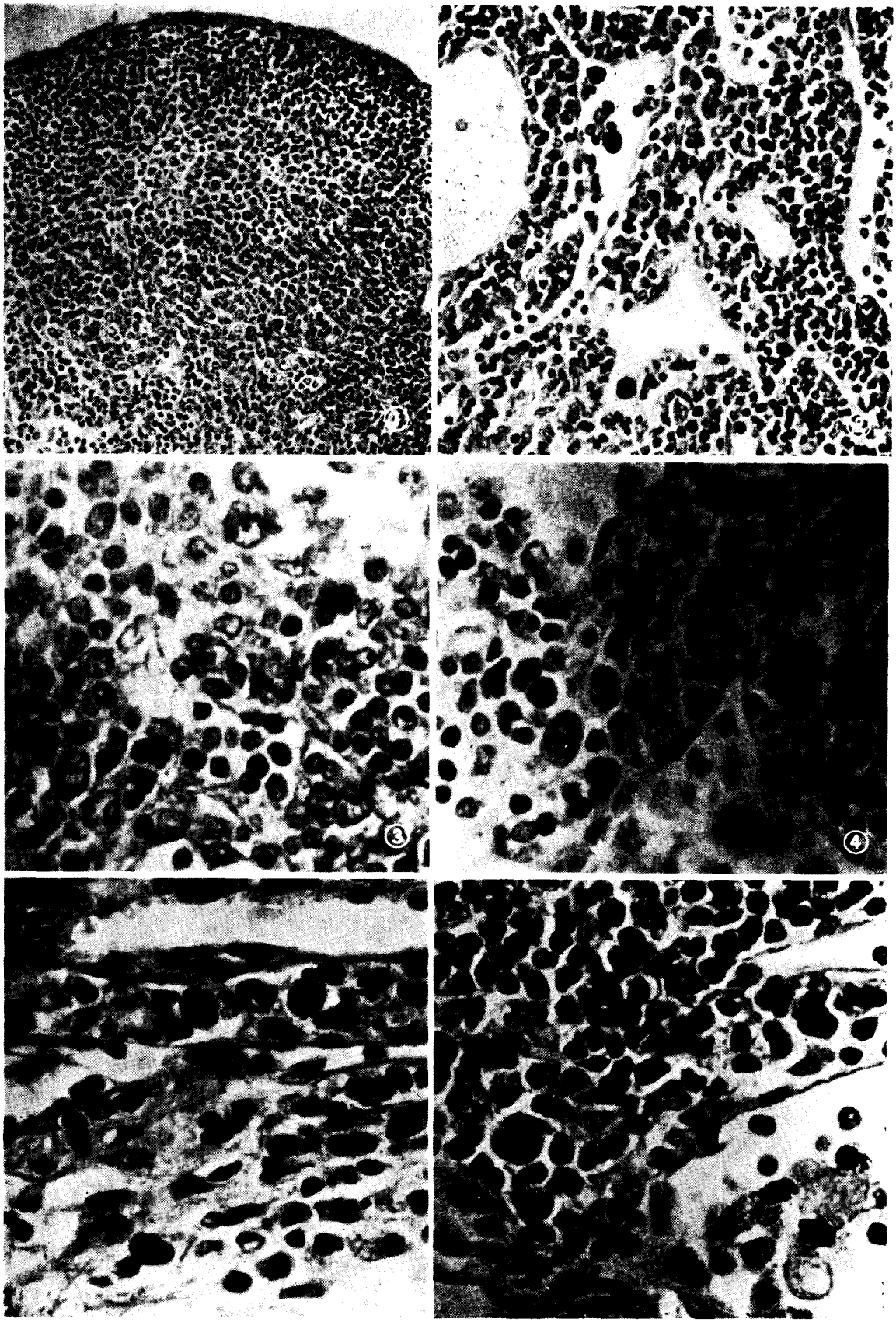
3
4