NUCLEAR BODIES IN CELLS OF VARIOUS LYMPHATIC ORGANS

Makoto SUGIMURA, Noriyuki OHTAISHI,
Norio KUDO & Yoshikatsu MIFUNE*

Department of Veterinary Anatomy
Faculty of Veterinary Medicine
Hokkaido University, Sapporo, Japan

(Received for publication, May 8, 1969)

INTRODUCTION

Peculiar nuclear inclusions, "nucleoloid bodies" named by the present writers, appear in small lymphocytes of lymph nodes of mice, cats and sheep and of hemal nodes of sheep. Some bodies are intimately related with the nucleoli[19,20]. The bodies were defined under the name "nuclear bodies" and described in detail by WEBER & FROMMES ('63). After their report, this name is usually used by many investigators. Accordingly, in this paper, the writers also use the "nuclear bodies" as a fitting morphological name.

The nuclear bodies seem to appear more or less in almost all parenchymatous and interstitial cells of animals[23]. With respect to the lymphatic tissues, some authors reported that the large nuclear bodies most often appear in small lymphocytes[19]. A similar discovery was obtained in an observation of agranulocytes of thoracic duct[24]. However, others have concluded that the bodies more frequently appear in endothelial and reticuloendothelial cells than in lymphocytes[3,11]. These findings give an impression that a further statistical observation is necessary in cells of different lymphatic organs of various animals.

In this paper, appearance and frequency of the cells with nuclear bodies were examined in the thymuses, lymph nodes, spleens and patches of Peyer in mice, especially with an aid to clarify functions of the nuclear bodies in lymphocytes.

MATERIALS AND METHODS

As materials, the thymuses, lymph nodes, spleens and patches of Peyer obtained from 11 mice of NIH strain, 5 to 8 weeks old, were used. Specimens were fixed in 1% osmium tetroxide (MILLONIG), embedded in Epon 812 (LUFT), cut on Porter-Blum ultramicrotome and stained with uranyl acetate and lead citrate as a routine matter.

Cell count; thymic cortices, thymic medullae, cortices of subiliac lymph

* Laboratory of Electron Microscopy

nodes, diffuse lymphatic tissues of patches of Peyer and white pulps of spleens were photographed at initial magnification 2,000 to 2,500 times at JEM-7 electron microscopy and printed on photographic papers 2~2.5 times. Three cases of each organ were used for cell counts. Cells, which were cut through planes near the middle of cell bodies, were observed to distinguish their cell types and existence of the nuclear bodies. They were counted over 500 cells per case, but cells of the germinal centers were omitted in this experiment, since it necessitates of a further study.

RESULTS

1 Types of cells and their populations

The present observation is limited only to the diffuse lymphatic tissues of the cortices and medullae of thymuses, cortices of lymph nodes, white pulps of spleens and patches of Peyer except for germinal centers. In these organs, several types of cells were distinguished.

Cells of lymphocytic series are divided to three types, small, medium and large, according to their sizes.

In small lymphocytes, a nucleus is approximately 6 μ and less in size and large chromatin masses are found around the periphery and center of the nucleus. A small nucleolus is sometimes observed in the nucleus. The narrow cytoplasm contains mitochondria, scarce ribosomes and a small Golgi complex with centrioles. Rough-surfaced endoplasmic reticulum, multivesicular bodies, small dense bodies and lipid droplets are sometimes found in the cytoplasm (plates I~III). Small thymic lymphocytes (thymocytes) in the cortex seem to have a narrower cytoplasm, in which free ribosomes are somewhat numerous, than that of small lymphocytes of other lymphatic organs (figs. 4 & 5). But thymocytes are treated as small lymphocytes for convenience of description in this report.

In medium lymphocytes, the nucleus is larger (6~8 μ) than that of small lymphocytes. The chromatin is recognized as a dense area of irregular outline disposed around the periphery and around the small nucleolus. The cytoplasm is more abundant than that of small lymphocytes. The types of cytoplasmic organelles and inclusions are similar to those of small lymphocytes, but free polysomes are more numerous (fig. 5).

In large lymphocytes, the nucleus is larger (over 8 μ in size) and has one or two large nucleoli. Numerous shallow indentions of the nuclear envelope are observed on the periphery of the nucleus. The broad cytoplasm is packed with abundant polysomes. Mitochondria are larger in size and their intercristal spaces are more light, broader than these of small and medium lymphocytes. Other organelles and inclusions are similar to those of medium lymphocytes (fig. 4).

In reticular cells, the nucleus is oval with irregular indentions in shape. The chromatin forms an irregular rim around the periphery of the nucleus and around nucleoli. One or two nucleoli are often observed, but their sizes varied from cell to cell. They have several long cytoplasmic protrusions. Their cytoplasmic organelles and inclusions are variable in quality and quantity, but reticular cells are in general divided into three types according to

behavior of junctions on the opposing membranes.

Mesenchymal reticular cells are found in all of the observed lymphatic organs. They loosely surround the reticulum fibers and include somewhat numerous lysosome-like dense bodies. Macrophages are probably included in this type of reticular cells. On the opposing membranes of this type of cell, a junctional apparatus was not observed, though the interdigitation is usually observed (figs 8 & 10).

Sinus endothelial cells (littoral cells) are a separate type of the mesenchymal reticular cells. The cells have a tight junction, zonula adherens, on the opposing cell membranes and usually include a few inclusions. The cells are only found in the lymph nodes and show an endothelial property.

Epithelial reticular cells are found only in the thymus. The cells have some epithelial characteristics; desmosomes, tonofilaments and basement membrane (figs. 7 & 18).

Plasma cells can be distinguished from other types of cells by presence of abundant rough-surfaced endoplasmic reticulum and a well-developed Golgi complex.

Mast cells and granular leukocytes with the specific granules are easy to distinguish from the other types of cells.

Blood vessels are also observed in all of lymphatic organs.

The populations of the above-mentioned types of cells are shown in table 1.

TABLE 1 *Population of various types of cells*

TYPES OF CELLS	CORTEX OF THYMUS $\bar{x} \pm s$	MEDULLA OF THYMUS $\bar{x} \pm s$	CORTEX OF LYMPH NODE $\bar{x} \pm s$	WHITE PULP OF SPLEEN $\bar{x} \pm s$	PATCH OF PEYER $\bar{x} \pm s$
Small lymphocytes	83.3 ± 2.2	81.7 ± 3.2	87.4 ± 3.3	92.3 ± 0.7	92.3 ± 2.9
Medium lymphocytes	9.7 ± 1.4	2.9 ± 0.5	1.1 ± 1.3	1.7 ± 0.7	1.7 ± 0.6
Large lymphocytes	2.8 ± 0.9	0.4 ± 0.1	0.4 ± 0.5	0.6 ± 0.2	0.5 ± 0.3
Mitotic cells	1.6 ± 0.4	0.3 ± 0.3	0	0.1 ± 0	0.2 ± 0.2
Mesenchymal reticular cells	0.5 ± 0.2	4.8 ± 0.8	8.1 ± 1.0	4.9 ± 0.4	4.5 ± 1.7
Sinus-endothelial cells	0	0	2.5 ± 1.3	0	0
Epithelial reticular cells	1.6 ± 1.0	8.0 ± 4.3	0	0	0
Other cells*	0.5 ± 0.8	1.7 ± 1.2	0.5 ± 0.4	0.4 ± 0.6	0.8 ± 0.3

* Including endothelial cells of blood vessels, plasma cells, mast cells, eosinophilic and neutrophilic leukocytes

In the four organs observed, the cells of lymphocytic series comprise an average of 85.3% to 97.4% making them the most numerous of the population. Especially small lymphocytes are quite numerous comprising an average of 81.7% to 92.3% of the total. In the thymic cortex, however, large, medium lymphocytes and their mitosis are more abundant

than in the thymic medulla and other lymphatic organs.

The populations of reticular series vary somewhat among different lymphatic organs. Mesenchymal reticular cells are observed to be more numerous in lymph nodes and to be scarce in the thymic cortex. Sinus endothelial cells are specific in the lymph nodes. Epithelial reticular cells are found in the thymus only, more numerously in the thymic medulla. The other types of cells are scarce to comprise an average of less than 1.7% in the observed four lymphatic organs.

2 Occurrences of cells with nuclear bodies

The occurrences of cells with nuclear bodies are shown in table 2.

TABLE 2 *Frequency of cells with nuclear body*

TYPES OF CELLS	CORTEX OF THYMUS $\bar{x} \pm s$	MEDULLA OF THYMUS $\bar{x} \pm s$	CORTEX OF LYMPH NODE $\bar{x} \pm s$	WHITE PULP OF SPLEEN $\bar{x} \pm s$	PATCH OF PEYER $\bar{x} \pm s$
Small lymphocytes	4.4 ± 1.3	14.5 ± 1.7	33.2 ± 6.9	32.3 ± 6.1	37.1 ± 7.5
Medium lymphocytes	8.1 ± 6.4	0.3 ± 0.4	9.2 ± 10.2	22.4 ± 7.1	26.8 ± 15.1
Large lymphocytes	0	0	•	0	0
Mitotic cells	0	0	0	0	0
Mesenchymal reticular cells	26.7 ± 30.5	46.6 ± 18.8	18.0 ± 2.4	24.3 ± 8.9	22.7 ± 9.1
Sinus-endothelial cells	•	•	28.8 ± 6.8	•	•
Epithelial reticular cells	25.5 ± 14.6	56.7 ± 16.2	•	•	•
Other cells	0	15.0 ± 14.8*1	0	10.0 ± 17.3*2	14.3 ± 14.3*1

*1 Only endothelial cells of blood vessels
*2 Only plasma cells

The nuclear bodies occur in small and medium lymphocytes, cells of reticular series, plasma cells and endothelial cells of blood vessels, but their frequencies differ among different types of cells. No nuclear body was found in large lymphocytes, mitotic cells, mast cells and granular leukocytes.

Small lymphocytes of not less than 30% of total have one or more nuclear bodies in the lymph nodes (fig. 8), spleens (fig. 9) and patches of Peyer (fig. 10). On the other hand, small thymic lymphocytes with nuclear bodies comprise an average of 4.4% in the cortex (figs. 4 & 5) and 14.5% in the medulla (fig. 6).

Mesenchymal reticular cells with nuclear bodies comprise a variable range of 18.0% (lymph node) to 46.6% (thymic medulla) of the cells counted. Epithelial reticular (fig. 7) and sinus endothelial cells with nuclear bodies have similar ranges like the mesenchymal reticular cells. In the thymic medulla, however, epithelial reticular cells with nuclear bodies are more

numerous than those of the cortex.

In the other types of cells, a considerable number of plasma cells and endothelial cells have nuclear bodies, but their occurrences are variable among cases because these types of cells counted were very few in number in this observation.

3 Sizes of nuclear bodies and their occurrences

In thin sections, nuclear bodies seem to be divided into three forms according to their sizes.

A form: The bodies are less 0.4 μ in diameter and seem to occur solitarily in a thin section. None or few dense granules were observed in the central core of the body (fig. 11).

B form: The bodies are over 0.4 μ in diameter and also occur solitarily in sections. The central core of the bodies has numerous dense granules (fig. 12).

C form: The bodies group with two or more A and/or B forms. The largest group measures over 2 μ in size (figs. 13 & 14).

In about a half of the cells with nuclear bodies, two or more bodies, seven bodies in the most numerous case, appear in a nucleus (fig. 17). In some sections, one nucleus includes not only a form but also all of three forms of the bodies. Accordingly, cells with nuclear body are grouped in three types. That is, type I cells contain only A form of the nuclear body, but not B and C forms (fig. 11). Type II cells have B, but not always A form. C form is never found in type II cells (fig. 12). Type III cells include C form, but not always A and B forms (figs. 13, 14 & 17).

Occurrences of each type are examined in lymphocytic series, because other types of cells were counted only a few number.

As shown in table 3 and figure 1, in the lymph nodes, spleens and patches of Peyer, a large number of lymphocytes with nuclear bodies belonged to types II or III, which have large or grouped nuclear bodies. On the other hand, in the thymus, most of lymphocytes

TABLE 3 *Frequency of cell types classified with sizes of nuclear bodies (Cells of lymphocytic series*)*

TYPES OF CELLS	CORTEX OF THYMUS $\bar{x} \pm s$	MEDULLA OF THYMUS $\bar{x} \pm s$	CORTEX OF LYMPH NODE $\bar{x} \pm s$	WHITE PULP OF SPLEEN $\bar{x} \pm s$	PATCH OF PEYER $\bar{x} \pm s$
I	4.4 ± 1.4	7.9 ± 1.5	6.9 ± 1.0	6.0 ± 2.7	5.5 ± 1.4
II	0.1 ± 0.2	5.5 ± 1.1	11.7 ± 2.0	13.5 ± 2.1	15.9 ± 5.0
III	0.2 ± 0.3	0.8 ± 0.7	14.1 ± 4.1	12.7 ± 3.6	15.4 ± 2.0
Ns	4.6 ± 1.4	2.7 ± 1.0	0	0	0
Nl	0	1.1 ± 0.2	0.7 ± 0.7	1.1 ± 0.6	0.4 ± 0.2

* Including small, medium and large lymphocytes
Ns: Nuclear body related with small nucleous
Nl: Nuclear body related with large nucleolus

FIGURE 1 *Frequency of cell types classified with sizes of nuclear bodies*

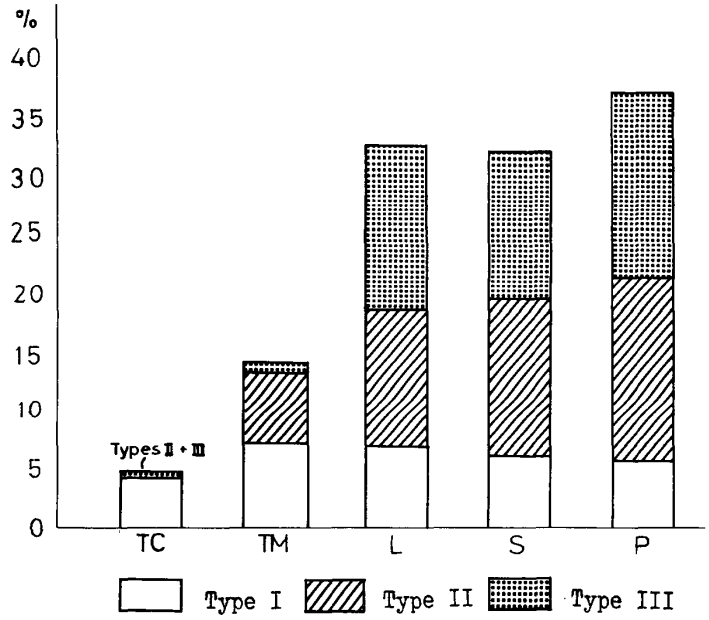

FIGURE 2 *Frequency of nuclear bodies related nucleolus*

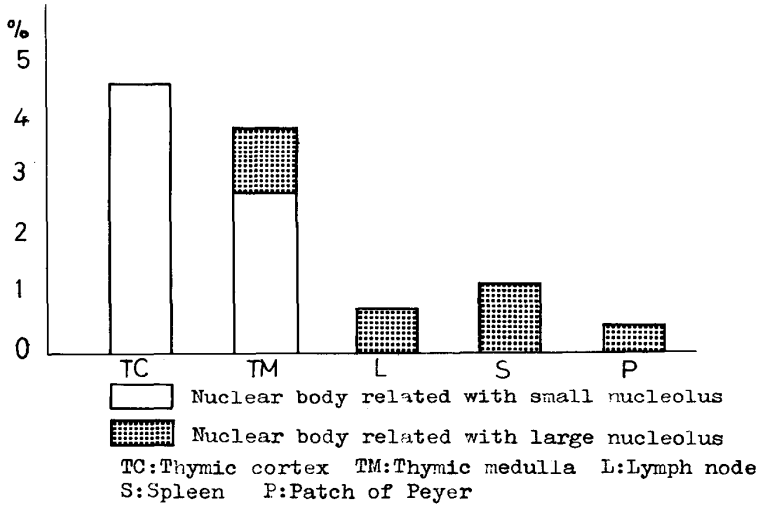

with nuclear body belong to type I which has a small nuclear body. That is to say, nuclear bodies are small in size and very few in number in the thymic cortex, but they are larger and somewhat numerous in the medulla. In the other lymphatic organs, the bodies are more larger and grouped, and become more numerous.

In cells of reticular series, though the tabular study has not been tested at this time, most of cells with nuclear body belonged to type I, but many epithelial reticular cells contained nuclear bodies of types II and III, especially in the thymic medulla.

4 Nuclear body with relation to nucleolus

The nuclear body is occasionally related with nucleolus; filaments, which are just similar to these of the outer coat of the nuclear body, are often found in contact with nucleolus. The nucleolus is covered by the filamentous structure like a cap, outside of which it appears a light halo. Occurrences of this case are shown in table 3 and figure 2.

In the thymic small lymphocytes, nucleoli related with nuclear body are usually smaller (figs. 5 & 15) than these of the other lymphatic organs (fig. 16). These findings are observed not only in lymphocytes but also in epithelial reticular cells (fig. 18) and endothelial cells of venules (figs. 19~21).

A tabular study was completed in cells of lymphocytic series only. As shown in table 3 and figure 2, the nucleoli related with nuclear bodies are most frequently observed in small lymphocytes of the thymus and are found only in about one-fifth of those of the thymus in other lymphatic organs.

Discussions

Nuclear bodies have been observed in nuclei of several types of cells in mice lymph nodes by the writers[19]. The bodies were also reported in cells of some plants and animals under a variety of physiological and pathological conditions by many investigators[2,3,9~12,16,23~25]. The nuclear bodies seem to appear more or less in almost all parenchymatous and interstitial cells of animals as reported by the previously mentioned investigators, but the bodies appear to be larger in size and more frequent in some types of cells; such as, in adrenal parenchymatous cells of calves[25], epididymal epithelial cells of dogs[9] and humans[10], lymphocytes in lymph nodes of mice[19] and in thoracic duct effluent of calves[24], and reticulo-endothelial cells of humans and hamsters[3,11].

Concerning lymphatic tissues, Sugimura et al. ('65) reported that the large nuclear bodies seem to appear most frequently in small lymphocytes of mouse lymph nodes and sheep hemal nodes. Weber & Joel ('66) observed that the nuclear bodies are present only in lymphocytes, but not in other agranulocytes of the thoracic duct effluent of calves. On the other hand, Brooks & Siegel ('67) have reported that the bodies appear most often in endothelial and reticulo-endothelial cells and rarely in lymphocytes, macrophages, and plasma cells of human lymph nodes. The same findings were reported in cells of hamster lymphatic tissues and human tumors by Krishan et al. ('67).

In the present observation, the nuclear bodies were found most frequently in small lymphocytes in the cortex of lymph nodes, white pulps of spleens and patches of Peyer with ranges of an average number of 32.3% to 37.1% in thin sections. However, it is worthy of note that the nuclear bodies appear very rarely in small lymphocytes of the thymic cortex (4.4%) and medulla (14.5%).

The cells of reticular series, mesenchymal and epithelial, often have also nuclear bodies with the ranges of an average number of 18.0% to 56.7% in four different organs. No nuclear bodies appeared in large lymphocytes and mitotic cells in this observation. In the previous paper[19], the writers reported a mitotic cell with nuclear body, but this case might be a very rare finding.

The writers paid attention to an actual frequency of the nuclear bodies of small lymphocytes. The nuclear size of small lymphocytes is about 6 μ in diameter and the nuclear bodies are located within the inner two-thirds of the nuclei.

TABLE 4 *Sizes and theoretical values of frequency of nuclear bodies in small lymphocytes*

		THYMIC CORTEX	THYMIC MEDULLA	OTHER LYMPHATIC TISSUES
Mean sizes of nuclear bodies		280 mμ	460 mμ	730 mμ
Theoretical values of frequency	1*	7.0 %	11.5 %	18.2 %
	2	14.0 %	23.0 %	36.4 %
Counted values of frequency		4.4 %	14.5 %	32.3~37.1 %

* 1: Supposed to be a nuclear body per nucleus
2: Supposed to be two nuclear bodies per nucleus

As calculated in lymphocytes of the thoracic duct effluent of calves by WEBER & JOEL, the nuclear body should theoretically be found in thin section of a 4 μ sphere in mice too. For example, in the thymic medulla, the mean size of nuclear bodies is 460 mμ in diameter. If they occur singly, the bodies should be observed in 11.5% of small lymphocytes as shown in table 4. The counted value of 14.5% appears to be reasonably close to the theoretical one. From the theoretical frequency as shown in table 4, it suggests as follows; in the thymus cortex, about a half of small lymphocytes have a small nuclear body (A form). In the thymic medulla, all small lymphocytes contain a small nuclear body (A form) or somewhat large one (B form). In the lymph nodes, spleens and patches of Peyer, all small lymphocytes contains two or more large nuclear bodies (B & C forms).

SAINTE-MARIE & LEBLOND reported that the thymic lymphocytes multiply in the cortex and finally migrate into medulla, where they enter, through diapedesis, into the lumen of blood vessels and possibly, but to a lesser degree, into the lymphatic circulations. The corresponding photographs were obtained in this observation (fig. 20). The recent reviews indicate that the thymocytes reaching the blood are disseminated to other lymphatic tissues, where they constitute the

immediate progenitors of the immunocompetent cells[6,8,14]. Figure 3 schematically shows a suggestion according to the development of the nuclear bodies in lymphocytes.

FIGURE 3 *Nuclear bodies of lymphocytes*

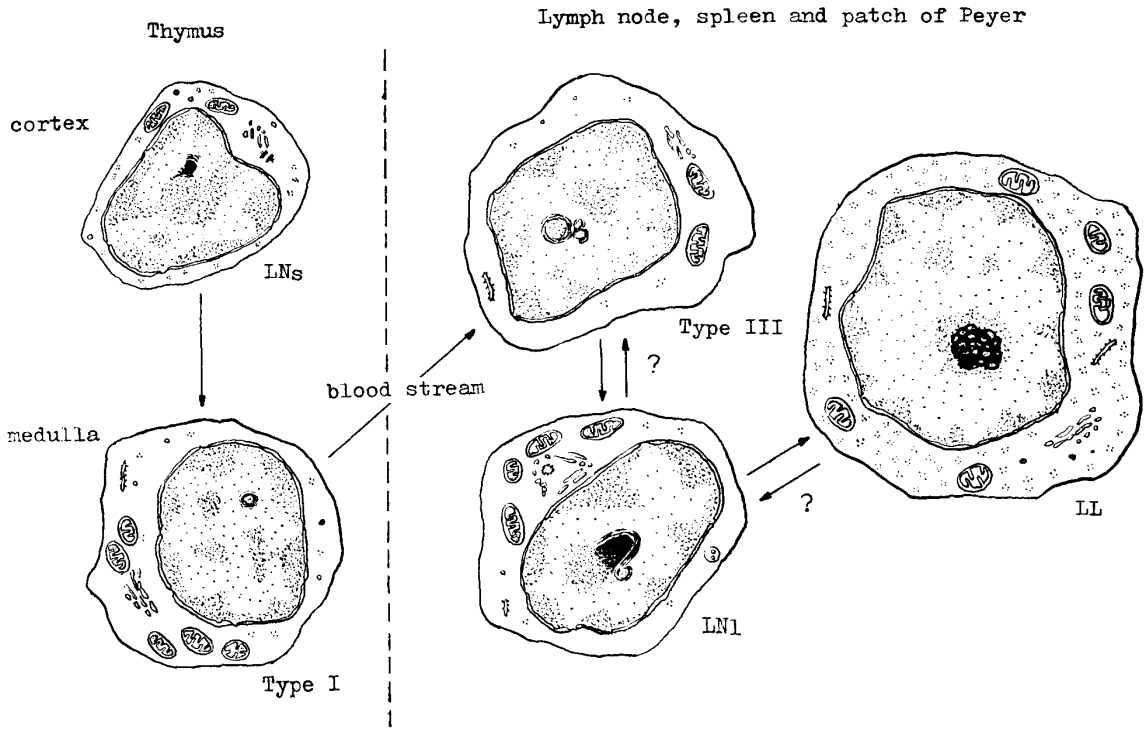

LNs: Small lymphocyte with nuclear body related with small nucleolus
LN1: Small lymphocyte with nuclear body related with large nucleolus
Type I: Small lymphocyte with small nuclear body
Type III: Small lymphocyte with large, grouped nuclear body
LL: Large lymphocyte

That is to say, it may be that in lymphocytes of the thymic cortex, a small nuclear body is formed from a nucleolus at the first time; the present observation clearly shows that the outer filamentous coat of the body is closely related with the nucleolus, but the body appears only in a half of lymphocytes of the cortex. After migrating to the thymic medulla, all small lymphocytes come to contain each a nuclear body. After they enter into blood circulations, the majority of small lymphocytes are disseminated to lymph nodes, spleens and patches of Peyer, and the nuclear bodies appear to increase their size and number.

It is known that a small amount of thymic cell suspensions (5~10 millions) do not restore neonatally thymectomized mice to normal reactivity[13], though a large amount of their suspensions are possible to restore it[26]. Furthermore, in thymic cell suspensions it is more difficult to induce the graft-versus-host reaction than in other lymphatic cell suspensions[1,21]. These findings indicate that the

lymphocytes, whose immunological functions are immature, are more numerous in the thymus than in other lymphatic organs, thus the functional maturation of lymphocytes seems to be closely related with development of the nuclear bodies.

It is suggested that the nuclear body may originate from the nucleolus by some authors[12], but no clear morphological evidence is present here. The present writers obtained many figures showing the close relationship between the outer filamentous coat of the nuclear body and the nucleolus. The findings explain that the nuclear body may originate from the nucleolus, but there is present the possibility that the nucleolus may reversely be formed from the nuclear body ("nucleolar organizer" discussed by WEBER et al.[25]). In either case, it is clear that the nuclear body has a close relationship with the nucleolus.

According to the functional meaning of the nuclear body, there are some proposals; WEBER et al.[25] stated that "the nucleolar organizer" would be the most plausible to consider, as the nuclear body corresponds roughly in number to the nucleoli and is not observed in mitosing form. BOUTEILLE et al. concluded that the nuclear body is related to cellular hyperactivity, such as physiological, hormonal, drug-induced, viral or tumoral. Other possible suggestions are that it is "a receptor center for tropic hormones"[25]. Actually, in the nuclear bodies of cells in adrenal cortex[25] and in epididymis[9,10] controlled by tropic hormones of the adenohypophysis, there occurs a conspicuous morphological changes, in which the inner granular zone of a nuclear body appears to transform itself into vacuolated bodies (multilocular body of WEBER et al.) with or without dense bodies.

In the present observation, the nuclear bodies of lymphocytes of the thymic cortex differ from those of other lymphatic organs, and the bodies of the thymic medulla are intermediate in size and frequency. From kinetics, migrating routes and functions of lymphocytes reported by many investigators, there may be a direct relation of the nuclear body of the lymphocytes with the functional maturation of the cells. The suggestion may be not inconsistent with the conception of the nuclear body as related to "hyperactivity of the cells" by BOUTEILLE et al. On the other hand, it is known that small lymphocytes can turn into blast cells under some immunological conditions[18,22]. If the bodies are able to transform into the nucleoli in the process of the blast cell formation, the conception of "the nucleolar organizer" would be also plausible (fig. 3, from LNl to LL).

KRISHAN et al. reported that the fibrous nuclear bodies do not contain any DNA or RNA but may have proteins in their structure on the basis of enzyme extractions. These results of histochemical and enzyme extraction procedures are contrary to the concept of the nuclear body as "nucleolar organizer".

Looking at the filamentous structures as similar with the outer coat of the

nuclear body appearing on the surface of the glycogen body[4] and of other abnormal nuclear inclusions[5,7] which seem to be useless for usual nuclear metabolism, the filamentous materials of the nuclear body can be considered to work as "a segregator" between karyoplasm and unnecessary substances in nuclei, as membranous structures do so in the cytoplasm. If so, the functional significance of the nuclear body seems to be depend upon what substances there are in the central core of the body. The chemical components of the inner granular materials are not clarified at present. In lymphocytes of mice, the inner granular materials of the bodies can be supposed to be a substance which is related to nucleolus, as the nuclear bodies appear to derive from the nucleolus. Actually, the granular materials are morphologically the same just as the "granular zone"[22] of nucleoli in figures stained with lead only (fig. 3 of SUGIMURA et al.[19]). But, a further study is necessary to clarify the chemical components of the inner granular substances.

SUMMARY

The sizes and frequency of the nuclear bodies were observed in cells of the thymic cortex, thymic medulla, lymph node, spleen and patch of Peyer of mice.

The nuclear bodies are most often found in small lymphocytes (32.3 to 37.1 %) of the lymph node, spleen and patch of Peyer, but very rarely in small lymphocytes of the cortex (4.4 %) and medulla (14.5 %) of the thymus. The bodies are also often found in mesenchymal and epithelial reticular cells, but are variable in occurrence.

From the frequency and size of the nuclear body in cells of lymphocytic series, it is suggested that in thymic cortex, about a half of the small lymphocytes contain a small nuclear body, and in the medulla all small lymphocytes contain a small or a large body, and in the other lymphatic organs all of small lymphocytes include two or more large, grouped, nuclear bodies.

The outer filamentous coat of the nuclear bodies is closely related with nucleolus. No nuclear bodies were found in the large lymphocytes and mitotic cells.

Thus the relationship between morphological changes of the nuclear body and differentiation of lymphocytes has been discussed in this paper.

REFERENCES

1) BILLINGHAM, R. E. & SILVERS, W. K. (1961): *J. exp. Zool.*, **146**, 113
2) BOUTEILLE, M., KALIFAT, S. R. & DELARUE, J. (1967): *J. Ultrastruct. Res.*, **19**, 474
3) BROOKS, R. E. & SIEGEL, B. V. (1967): *Blood*, **29**, 269
4) CARAMIA, F., GHERGO, G. F. & MENGHINI, G. (1967): *J. Ultrastruct. Res.* **19**, 573

5) DAVID, H. (1964): *Z. mikrosk.-anat. Forsch.*, **71**, 412
6) FICHTELIUS, K.-E. & BRYANT, B. J. (1964): "On the fate of thymocytes" The thymus in immunobiology, Ed. GOOD, R. A. & GABRIELSEN, A. E., 274, New York, Evanston & London: Hoeber Medical Division
7) FOSTER, C. L., YOUNG, B. A., ALLANSON, M. & CAMERON, E. (1965): *J. Endocr.*, **33**, 159
8) GOLDSCHNEIDER, I. & MCGREGOR, D. D. (1968): *J. exp. Med.*, **127**, 155
9) HORSTMANN, E. (1965): *Z. Zellforsch. mikrosk. Anat.*, **65**, 770
10) HORSTMANN, E., RICHTER, R. & ROOSEN-RUNGE, E. (1966): *Ibid.*, **69**, 69
11) KRISHAN, A., UZMAN, B. G. & HEDLEY-WHYTE, E. T. (1967): *J. Ultrastruct. Res.*, **19**, 563
12) LAFONTAINE, J. G. (1965): *J. Cell Biol.*, **26**, 1
13) MILLER, J. F. A. P. (1964): "Effect of thymic ablation and replacement" The thymus in immunobiology, Ed. GOOD, R. A. & GABRIELSEN, A. E., 436, New York, Evanston & London: Hoeber Medical Division
14) MURRAY, R. G. & WOODS, P. A. (1964): *Anat. Rec.*, **150**, 113
15) PORTER, K. A. & COOPER, E. H. (1962): *J. exp. Med.*, **115**, 997
16) ROBERTSON, D. M. & MACLEAN, J. D. (1965): *Archs Neurol., Chicago*, **13**, 287
17) SAINTE-MARIE, G. & LEBLOND, C. P. (1964): "Thymus-cell population dynamics" The thymus in immunobiology, Ed. GOOD, R. A. & GABRIELSEN, A. E., 207, New York, Evanston & London: Hoeber Medical Division
18) SENDA, N. & MORI, Y. (1966): *Saishin-Igaku*, **21**, 1215 (in Japanese)
19) SUGIMURA, M., FURUHATA, K., OHTAISHI, N., KUDO, N. & MIFUNE, Y. (1965): *Jap. J. vet. Res.*, **13**, 96
20) SUGIMURA, M., OHTAISHI, N., YAMADA, J., FURUHATA, K. & KUDO, N. (1966): *Kaibo Z.* (*Acta anat. nippon.*), **41** Suppl. No. 1, 9 (in Japanese)
21) TAMAOKI, N. (1966): *Saishin-Igaku*, **21**, 1235 (in Japanese)
22) TOKUYASU, K., MADDEN, S. C. & ZELDIS, L. J. (1968): *J. Cell Biol.*, **39**, 630
23) WEBER, A. F. & FROMMES, S. P. (1963): *Science*, **141**, 912
24) WEBER, A. F. & JOEL, D. (1966): *Blood*, **28**, 266
25) WEBER, A., WHIPP, S., USENIK, E. & FROMMES, S. (1964): *J. Ultrastruct. Res.*, **11**, 564
26) YUNIS, E. J., HILGARD, H. R., MARTINEZ, C. & GOOD, R. A. (1965): *J. exp. Med.*, **121**, 607

Explanation of plates

All photographs were taken from specimens fixed with osmic acid, and stained with uranyl acetate and lead citrate. All scales indicate 1 μ.

Plate I

Fig. 4 Thymic cortex: A large lymphocyte (LL) with numerous polysomes and small lymphocytes are found. Two small lymphocytes contain small nuclear bodies (arrows).

Fig. 5 Thymic cortex: A mitotic cell (M), medium (ML) and small lymphocytes are observed. Two lymphocytes have small nucleolus related with filamentous elements (arrows) which are quite similar to those of the outer coat of the nuclear body.

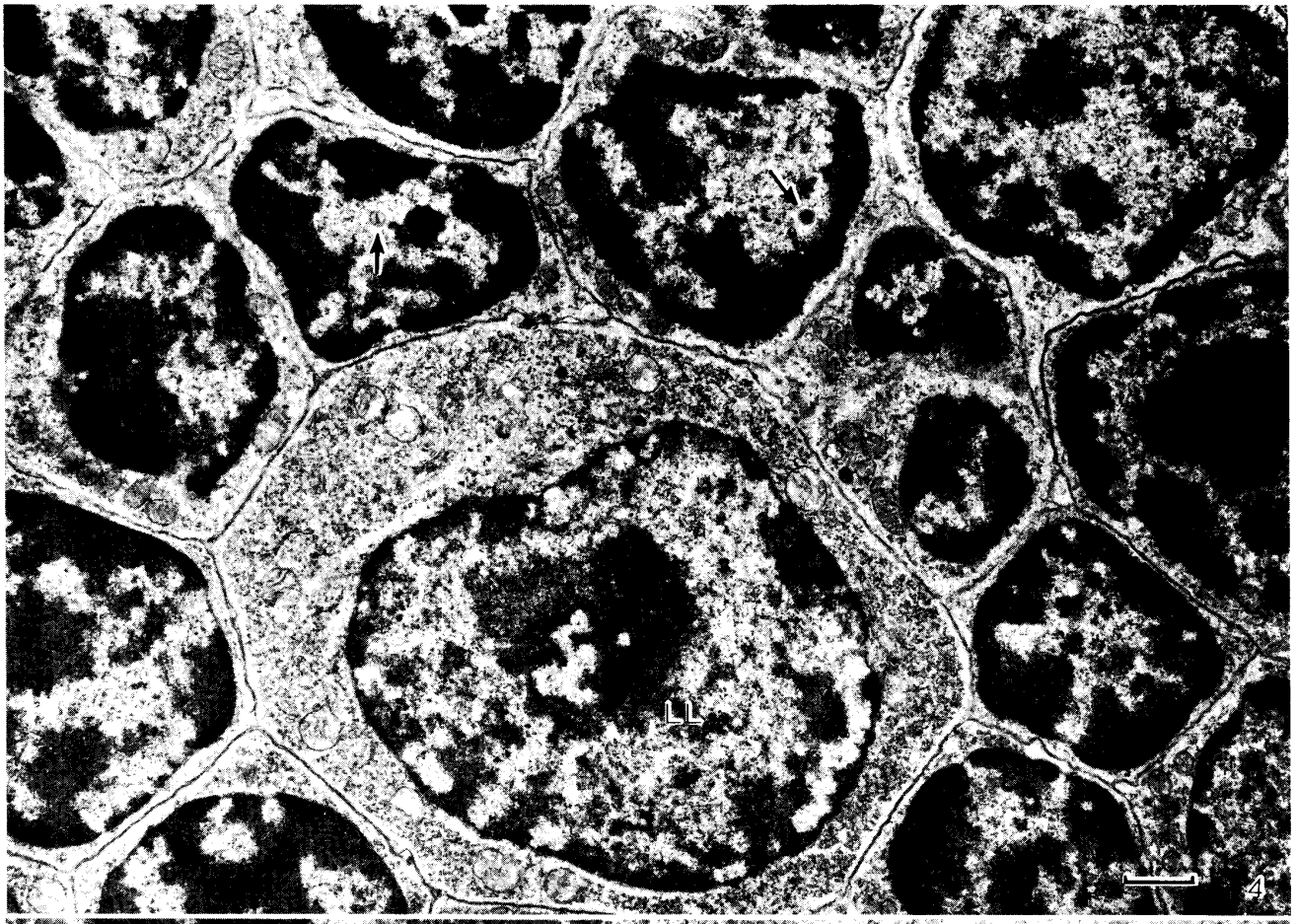
N
LL
4

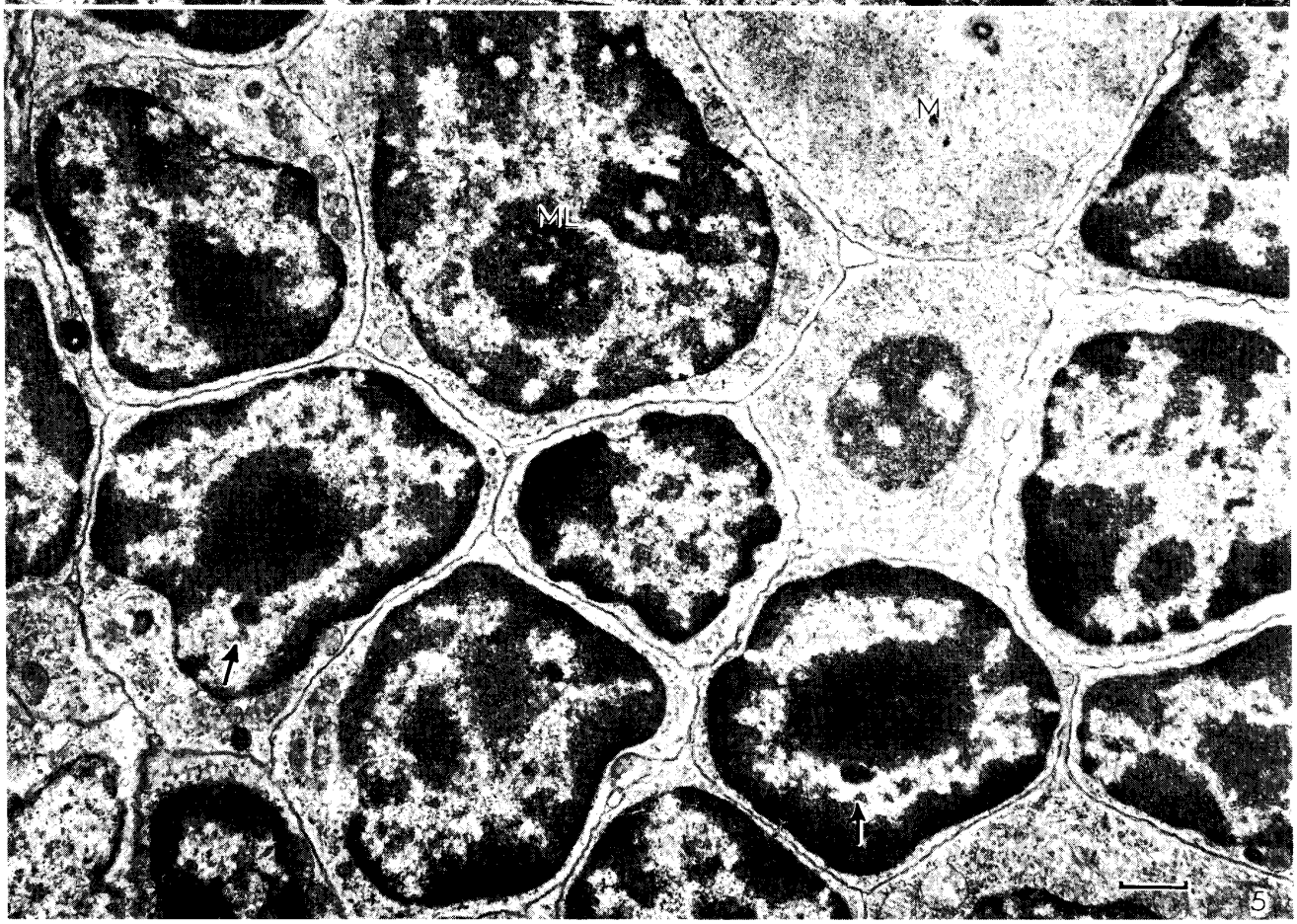
M
ML
5

PLATE II

Fig. 6 Thymic medulla: Two small lymphocytes with nuclear body (arrows) are shown in the upper side of this figure. Another cell (probably mesenchymal reticular cell) contains a nuclear body closely near a nucleolus.

Fig. 7 Thymic medulla: Epithelial (ER) and mesenchymal reticular cells (MR) with large nuclear bodies (arrows) are seen. The central core of the body of mesenchymal reticular cell contains a small vacuole.

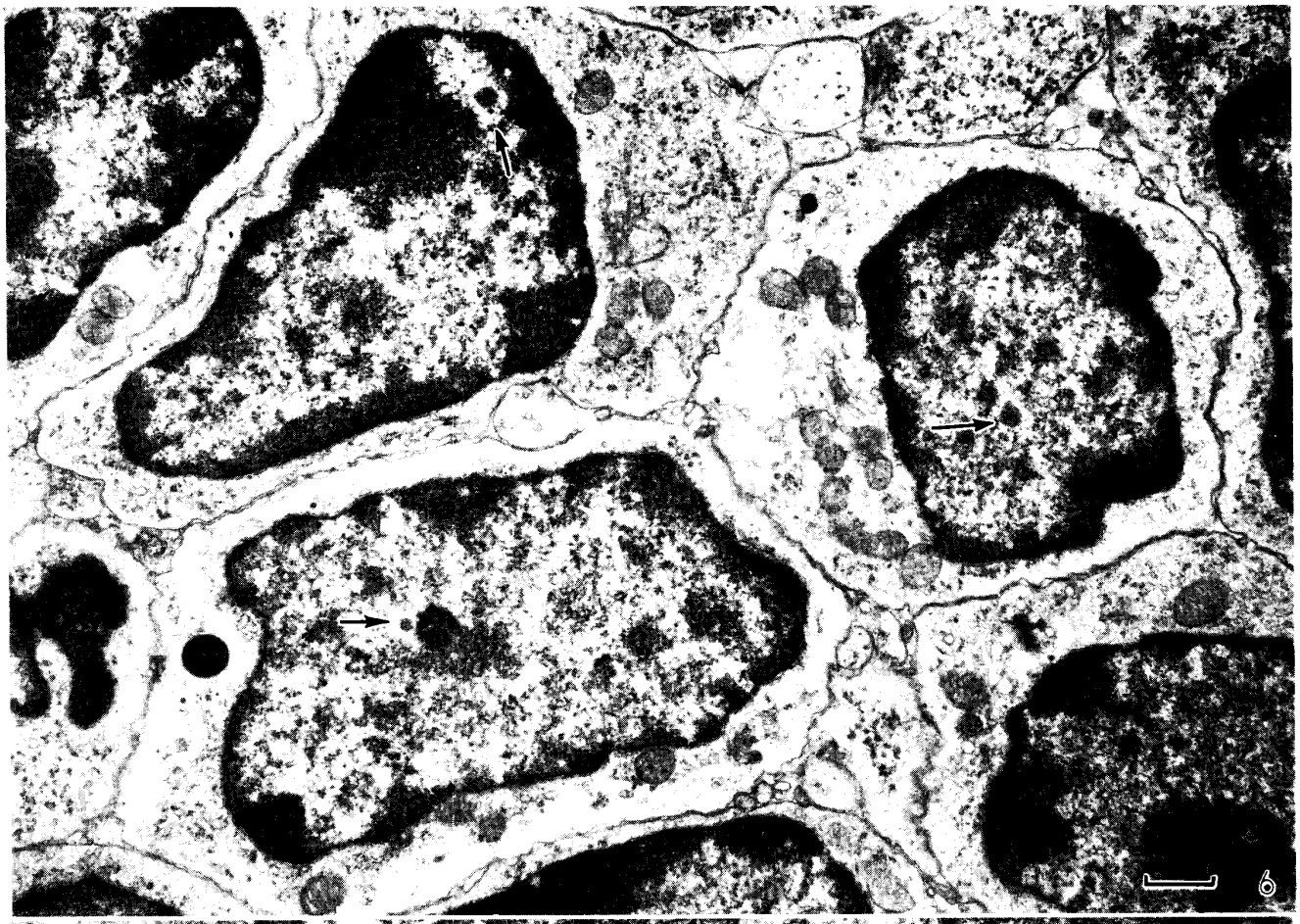
6

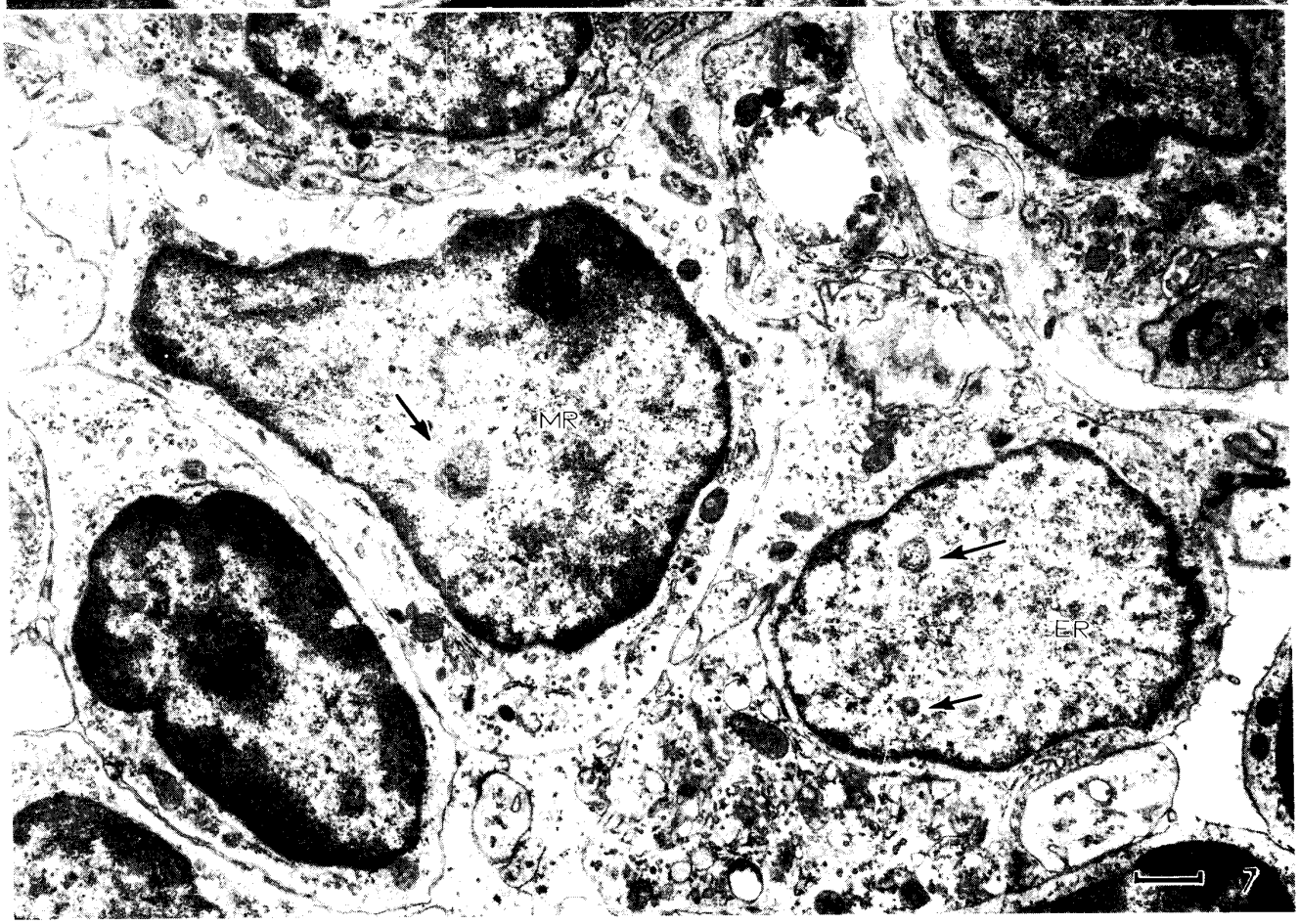
MR
ER
7

PLATE III

Fig. 8 Cortex of lymph node: Large or grouped nuclear bodies (arrows) are seen in nuclei of small lymphocytes.

Fig. 9 White pulp of spleen: Small lymphocytes often contain various shapes of nuclear bodies (arrows).

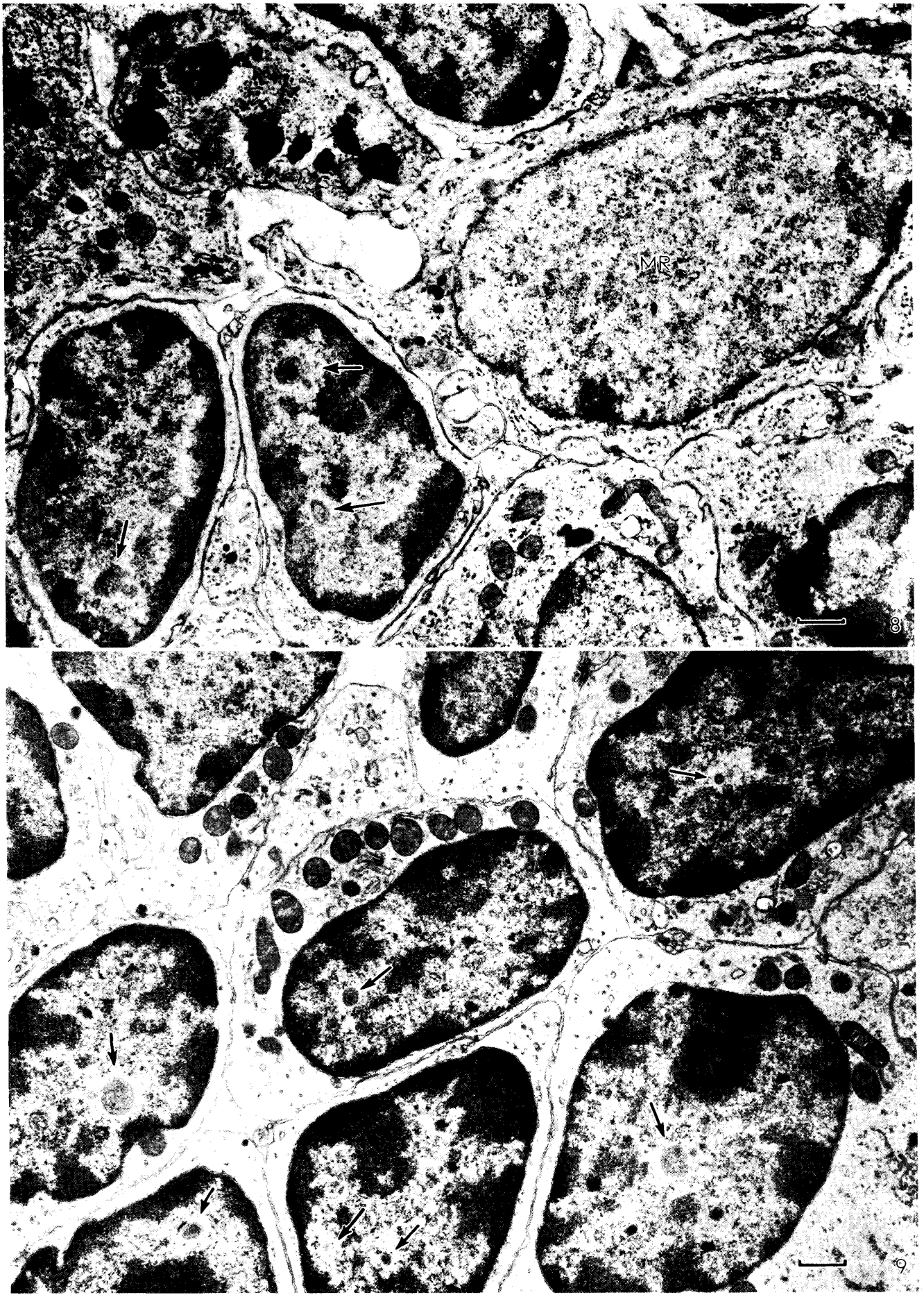
MR
8
9

PLATE IV

Fig. 10 Patch of Peyer: Small lymphocytes with one or more large nuclear bodies (arrows) are found.

Fig. 11 Small lymphocyte with a small nuclear body (arrow)

Fig. 12 Small lymphocyte with a large nuclear body (arrow)

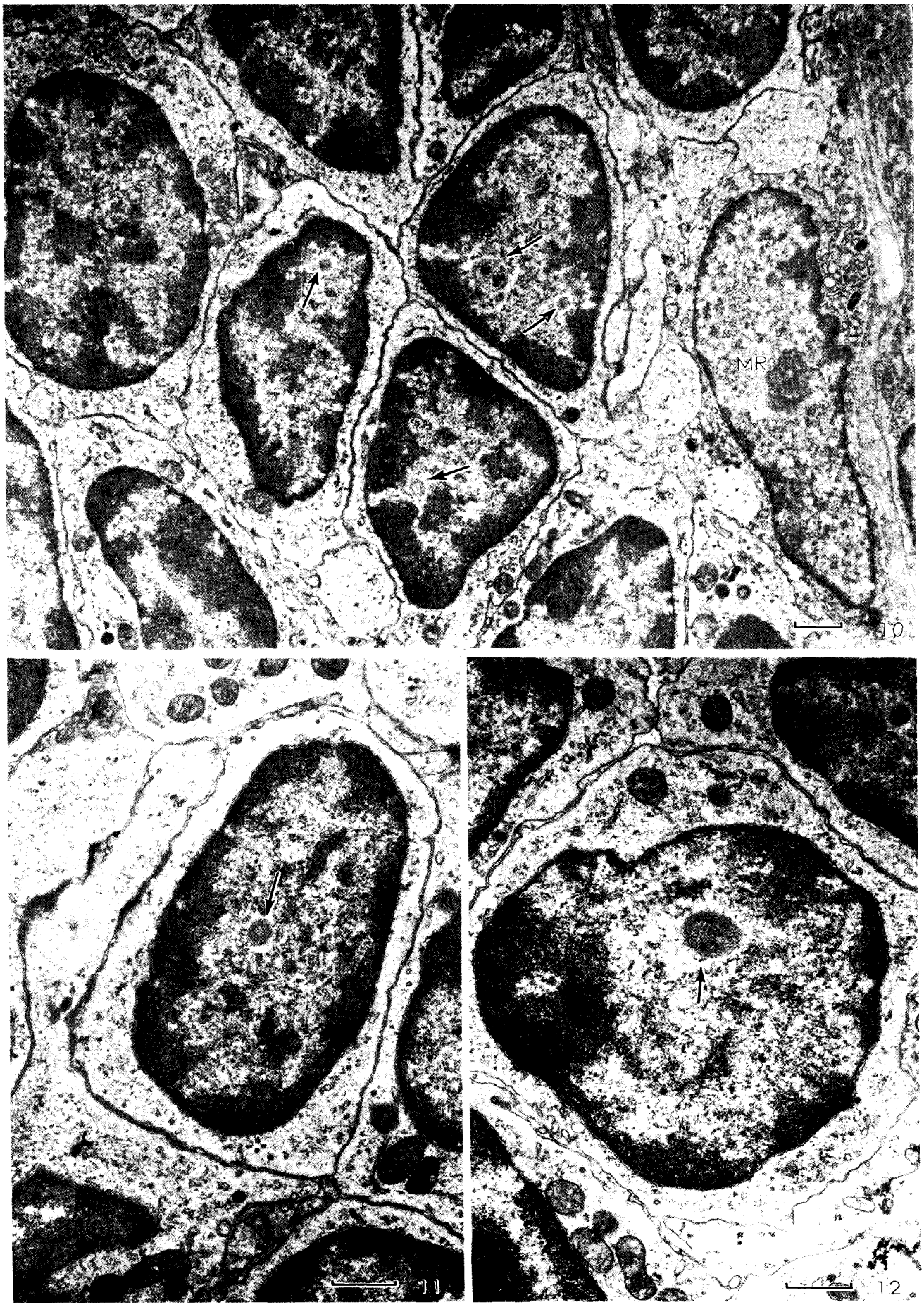
MR
10
11
12

PLATE V

Fig. 13 Small lymphocyte with a small and a large grouped bodies (arrows)

Fig. 14 Small lymphocyte with a large grouped nuclear body (arrow)

Fig. 15 Thymic lymphocyte: Filaments (arrow), which are similar to the outer ones of the nuclear body, are closely contact with a small nucleolus.

Fig. 16 Small lymphocyte of lymph node: Filaments and grouped nuclear bodies (arrows) are closely contact with a large nucleous. This finding shows that large grouped nuclear bodies may relate with nucleoli.

Fig. 17 Epithelial reticular cell of thymic medulla: The nucleus of the cell contains several nuclear bodies (arrows).

Fig. 18 Epithelial reticular cell of thymic medulla: Close-relationship between filaments and nucleoli is ascertained (arrows).

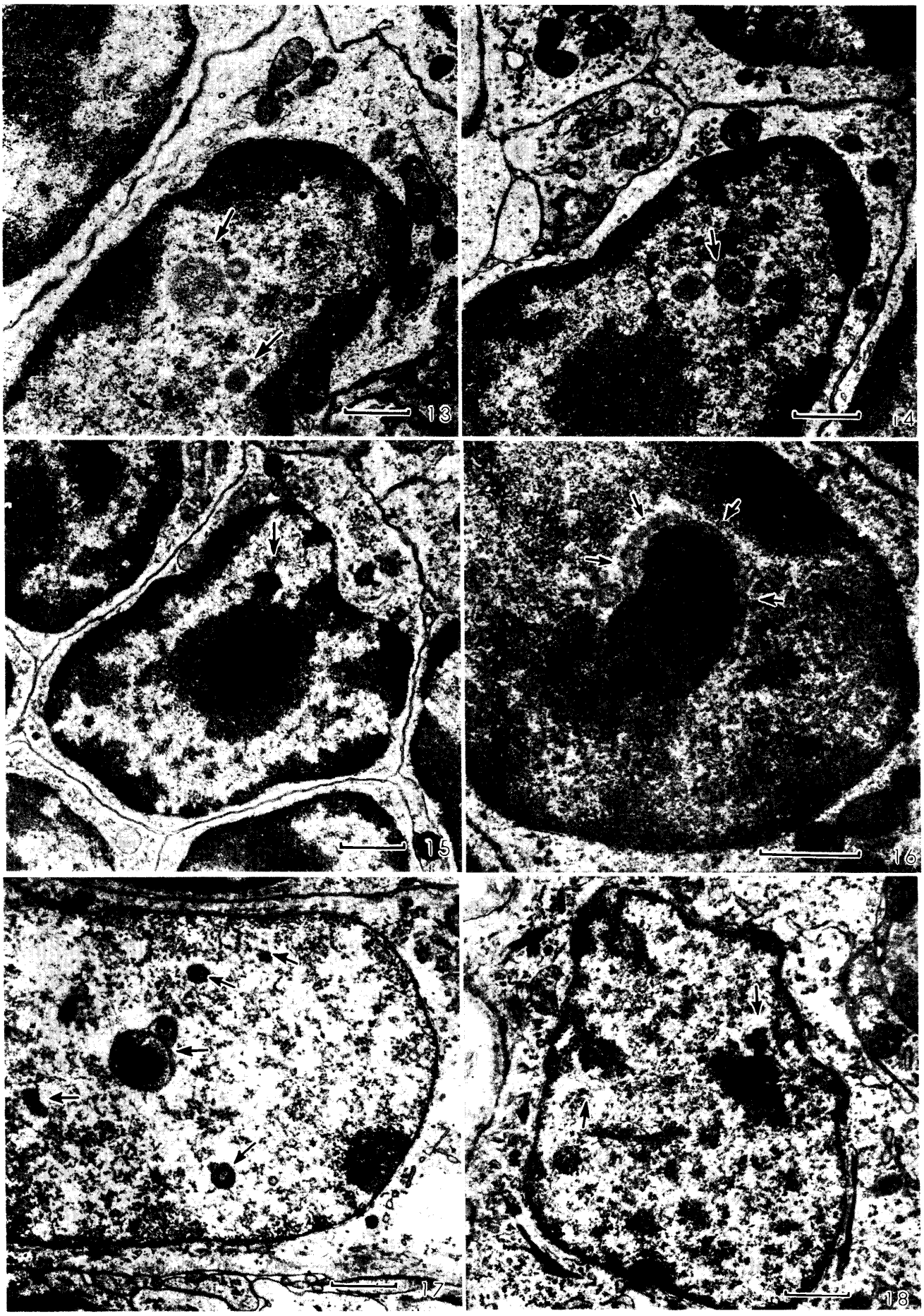
13
14
15
16
17
18

PLATE VI

Fig. 19 Endothelial cells (E) of post-capillary venule i nlymph node: The nucleus of the cell sometimes contains filaments closely related with nucleoli (arrows).

Figs. 20 & 21 Venule of thymic medulla: In thymic medulla, there are venules through which small lymphocytes (L) with nuclear body (arrow) pass to (or from) blood circulation. The nucleus of the endothelial cells (E) also sometimes has nuclear bodies and filaments related with nucleoli (arrows).

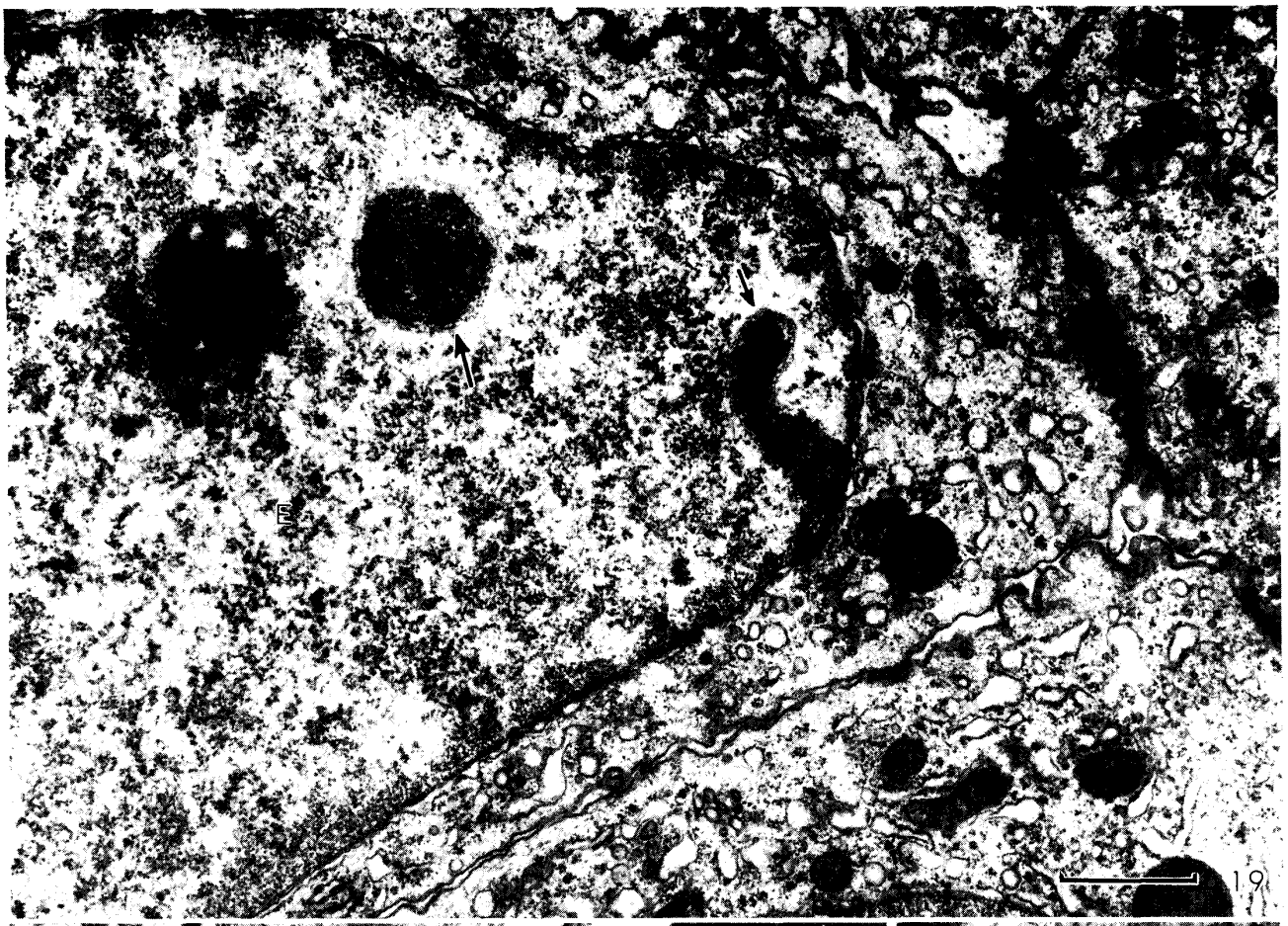
E
19


E
20


E
21