Jap. J. vet. Res., **21**, 1~14 (1973)

HISTOLOGICAL STUDIES IN THE INSERTION OF THE TENDON ON THE DISTAL PHALANX OF THE HORSE

Kanjuro OTOMO

Department of Veterinary Surgery
Faculty of Veterinary Medicine
Hokkaido University, Sapporo, Japan

(Received for publication, September 27, 1972)

Development and age-change occurring in the insertion of the extensor tendon and the deep flexor tendon on the distal phalanx were studied on the histological level in horses varying in age from embryo (18 cases) to adult (53 cases). Moreover, the fine structure of the insertion of the deep flexor tendon was partly observed.

The five following developmental stages were distinguished according to the histological changes in the insertion of the extensor tendon: 1) The stage of cartilage (from 15 to 80 cm embryos); 2) The stage of spongy bone formation (from 85 cm embryos to 2 weeks old infants); 3) The stage of fibrous bone formation (from 3 months to 1.5 years old); 4) The stage of lamellar bone formation (from 1.5 to 3 years old); and 5) The stage of completion of the insertion (4 years old and over).

The five following developmental stages were distinguished according to the histological changes in the insertion of the deep flexor tendon: 1) The stage of cartilage (from 15 to 80 cm embryos); 2) The stage of inner compact layer formation (from 85 cm embryos to 2 weeks old infants); 3) The stage of outer compact layer formation (from 3 months to 1.5 years old); 4) The stage of fibrocartilage formation (from 1.5 to 3 years old); and 5) The stage of completion of the insertion (4 years old and over).

Electron microscopic observation in the insertion of the deep flexor tendon can be described as follows.

Tendons were arranged perpendicular or oblique to the bone surface and entered the bone in an approximately perpendicular or oblique position.

In the tendon, the axial period of collagenous fiber was on the average 640 Å. It was divided into D-region (high dense region) and L-region (comparatively low dense region); the width of D-region was on the average 380 Å, and that of the L-region about 260 Å, respectively determined by measurements on several fibrils. Eleven dark transverse lines per period can usually be observed, 8 in the D-region and 3 in the L-region. The diameter of collagenous fiber measured about 3,000 Å and maximum was about 4,000 Å.

In the bone, the axial period of the collagenous fiber was from 600 to 700 Å. It was divided into D-region and L-region, and several dark transverse lines per period can usually be observed. The diameter of the fibers measured about 1,000 Å.

INTRODUCTION

The distal phalanx is an important bone to horses, for it is the basis of the horse's movement. Accordingly, the physiological change is expected from the insertion of the tendon, when the tendon's pulling capacity acts upon the bone. Reports of the distal phalanx on horses have been published by several workers, including MÖLLER[25], STOLCH[46], SAARNI[39], MUSZAR[27], NICKEL & WISSDORF[29]. However, no one has systematically investigated the insertion of the tendon of the distal phalanx.

On the other hand, studies in the insertion of the tendon of other parts have been reported by RANVIER[36], DOLGO-SABUROFF[7,8], WEIDENREICH[49], PETERSEN[33], SCHUBERT[42], WOLLYNSKI[51], MOLLIER[26], LUBOSH[21], SCHNEIDER[41], KNESS & BIERMANN[16], and KNESE & HARNACK[17].

In recent years electron microscopy has been employed in the examination of the bone and the tendon, but electron microscopic studies of the insertion of the tendon have not been reported in available literature.

In this paper, the writer will try to clarify a specific structure in the insertion of the tendon of the distal phalanx in horses varying in age from embryo to adult, with parallel studies of electron microscopic observations of the insertion of the deep flexor tendon of the distal phalanx in horses. Most of the findings in this report were presented at the 50, 52, 54, 59, 62nd Meeting of the Japanese Society of Veterinary Science in 1960, 1961, 1962, 1965, 1966, and published as abstracts.

MATERIALS AND METHODS

Materials subjected to investigation were obtained from embryo (18 cases) to adult (53 cases) horses (tab. 1).

Light microscopy: The specimens were taken as soon as possible after the animals were slaughtered; all materials were fixed in 10% formalin solution. For histological examination on all the cases, the materials were prepared by sagittal sectioning at the center of the hoof bone containing the tendon. All of these materials were decartified electrolytically in 5% HCl solution and were celloidin-embedded. Specimens were stained with hematoxylin-eosin. The length of the embryo was the crown-rump length.

Electron microscopy: The specimens were fixed for two hours in ice cold 1% osmium tetroxide (MILLONIG, '60). The tissue was washed in distilled water and then decalcified from 7 to 17 days in 5% formalin and 0.25 molar EDTA (ethylenediaminetetraacetic acid) at pH 8.0 (STERN, '61). The tissue was washed again and then dehydrated in increasing concentrations of ethanol and embedded

TABLE 1 *Investigated materials*

EMBRYO		ADULT												
No.	Length	No.	age	Ext. No.	Flex. No.	El. No.	No.	age	Ext. No.	Flex. No.	No.	age	Ext. No.	Flex. No.
1	15	1	2w	1	1		19	1.5	14	14	37	8	—	31
2	24	2	3m	2	2		20	3	15	15	38	8	—	32
3	25	3	3	3	3		21	4	16	16	39	8	—	33
4	27	4	3	4	4		22	4	17	17	40	8	29	34
5	32	5	3	5	5		23	5	18	18	41	9	30	35
6	33	6	4	6	6		24	5	19	19	42	9	31	36
7	33	7	4	7	7		25	5	20	—	43	10	—	37
8	35	8	4	8	8		26	5	21	20	44	10	—	38
9	39	9	4	9	9		27	6	22	21	45	10	—	39
10	42	10	5	—	—	1	28	6	23	22	46	10	32	—
11	42	11	5	—	—	2	29	6	24	23	47	12	—	40
12	51	12	5	—	—	3	30	6	25	24	48	13	—	41
13	56	13	5	—	—	4	31	6	26	25	49	13	33	42
14	65	14	5	—	—	5	32	6	27	26	50	13	—	43
15	80	15	8	10	10		33	7	28	27	51	13	—	44
16	85	16	9	11	11		34	7	—	28	52	13	—	45
17	95	17	1y	12	12		35	7	—	29	53	15	—	46
18	110cm	18	1	13	13		36	8	—	30				

N.B. w week
m month
y year
Ext. Extensor
Flex. Flexor
El. Electron microscopy

in Epon 812 (LUFT, '61). Sectioning was done with JUM-5 ultramicrotome using glass knives. Sections 1 to 2 μ in thickness were mounted on glass slides and stained with aqueous toluidine blue. These sections were then examined with the light microscope to judge whether the specimens were properly oriented and to assure that the cementum would be included in the trimmed block face. The acceptable specimens were stained with uranyle acetate (WATSON, '58) or lead citrate (MILLONIG, '61). Microscopy was performed with JEM-7.

RESULTS

I Insertion of the extensor tendon of the distal phalanx

1) General description

The insertion of the extensor tendon is divided into three parts: distal, middle and proximal. Compact bone is observed at the bone side of the distal part and spongy bone is observed in the middle and proximal parts (fig. 5).

Embryo

The distal phalanx at the insertion of the tendon is composed of cartilage in the all cases (fig. 1) except No. 18.

Nos. 1~15 (15~80 cm embryos): The tendon consists of the fibroblasts with intercellular collagenous fibers (fig. 6).

Nos. 16~18 (85~105 cm embryos): The tendon becomes fibrous, but the peritendineum externum is imperfectly separated from tendon.

In the cases of No. 16, the bone side of the distal part of the insertion of the extensor tendon is fibrous and a portion of the tendon fibers is buried deeply in the bone surface (fig. 7).

Adult

The peritendineum externum continues distally with the periosteum of the distal phalanx in the all cases.

Nos. 1~11 (2 weeks~9 months): Tendon fibers are inserted into the bone at the distal part of the insertion of the tendon (fig. 9). Bone side of the distal part of the insertion consists of the fibrous bone, and the middle to proximal part consists of the spongy bone. In the case of No. 1, the peritendineum externum is imperfectly separated from the tendon. In the cases of Nos. 9~11, many small vessels are observed at the distal part of the insertion.

Nos. 12~15 (1~3 years): The tendon fibers are inserted into the bone at the distal part, and its fibers reach the bone surface at the middle to the proximal part. Many small vessels and lamellar formation are observed at the fibrous bone of the distal part of the insertion (fig. 11). It is consisted of the

spongy bone at the bone side of the middle to the proximal part. The trabeculae based on the distal part of the insertion, are observed.

Nos. 16~21 (4~5 years): The tendon fibers are inserted into the bone at the distal part of the insertion, and its fibers reach the bone surface at the middle to the proximal part. The thin layer of fibrous bone is observed on the surface of the bone (fig. 13), and the inner layer consists of compact bone and it becomes increasingly thick. The bone side of the middle to the proximal part consists of spongy bone (fig. 3). The boundary line between tendon and bone side is clear (fig. 13). It is clear that trabeculae, based on distal part of the insertion, radiate to the Facies solearis. In the case of No. 10, the cartilage is partly observed at the tendon side of the middle part of the insertion. In the cases of Nos. 19, and 20, the cartilage is partly observed at the tendon side of the proximal part of the insertion.

Nos. 22~33 (6~13 years): The tendon fibers are inserted into the bone at the distal part of the insertion. In tendon side, the cartilage is observed between the tendon fibers in the middle and proximal parts. The bone side of the distal part of the insertion is compact bone, and the proximal part is spongy bone. It is clear that the trabeculae, based on the distal part of the insertion, radiate to the Facies solearis.

2) Separation into groups

The results of the histological findings of the insertion of the extensor tendon are given in table 2.

The following five developmental stages are distinguished according to the histological changes in the insertion of the extensor tendon.

1) The stage of cartilage (from 15 to 80 cm embryos): The distal phalanx at the insertion of the extensor tendon is composed almost completely of cartilage, and the tendon consists of rich cellular elements with fine intercellular collagenous fibers (fig. 1).

2) The stage of spongy bone formation (from 85 cm embryos to 2 weeks old infants): In the distal phalanx at the insertion of the extensor tendon, the ossification of the spongy bone is observed. The tendon becomes fibrous, and a portion of the tendon fibers begin to bury deeply in bone at the distal end of the insertion of the extensor tendon (figs. 2, 6~8).

3) The stage of fibrous bone formation (from 3 months to 1.5 years old): The connection between tendon and bone is complete, it consists almost completely of spongy bone in the distal phalanx at the insertion, but the fibrous bone formation is observed at a part of the distal end of the insertion (figs. 9 & 10).

TABLE 2 *Insertion of extensor tendon*

BONE SIDE	STAGE						
	Ia	Ib	Ic	II	III	IV	V
Cartilage	+	+	+				
Fibrous bone							
appearance				+	++	++	+
lamellar bone formation					+	+	++
Sponge bone							
appearance			+	+	+	++	++
ossification			+	+	+	+	++
appearance of trabecula						+	

TENDON SIDE	STAGE						
	Ia	Ib	Ic	II	III	IV	V
Fibrocartilage							±
Tendon							
cellular	+	±					
fibrous		+	+	+	+	+	+
separation of peritendineum ext.				+	+	+	+
connection of bone			+	+	+	+	+

N.B. Ia 15~35 cm length embryo
Ib 39~80 cm length embryo
Ic 85~95 cm length embryo
II 110 cm length embryo~2 weeks old infant
III 3 months~1.5 years
IV 1.5~3 years
V 4 years and over

4) The stage of lamellar bone formation (from 1.5 to 3 years old): In this stage, blood vessels begin to grow in the fibrous bone, are observed in the prior stage, and then the bone changes to lamellar bone. This compacta becomes thicker at its distal end, the clear bone trabecula, base on this compacta, radiates to the Facies solearis (figs. 11 & 12).

5) The stage of the completion of the insertion (4 years old and over): Ossification has disappeared. The fibrous bone at the distal end of the insertion changes completely to lamellar bone, but thin layer of the fibrous bone remains on the surface of the bone (figs. 3 & 13).

II Insertion of the deep flexor tendon of the distal phalanx

1) General description

The peritendineum externum continues distally with the periosteum of the

distal phalanx. Tendon fibers are attached directly to the bone. The tendon insertion is divided into four zones: tendon, fibrocartilage, mineralized fibrocartilage and bone (fig. 21).

The outer and the inner layers are observed at the compact bone of the insertion, and the sow teeth form is observed at the surface of the outer layer (figs. 4 & 21).

Embryo

The distal phalanx at the insertion of the tendon is composed of cartilage in the all cases (fig. 1) except in Nos. 16~18. In the cases of Nos. 16~18, the bone side consists of the spongy bone. The inner compact layer formation is observed at the insertion of the deep flexor tendon, and the periosteal layer is observed between the tendon and the bone in the case of No. 18 (fig. 14).

Adult

Nos. 1~11 (2 weeks~9 months): In the case of No. 1, the peritendineum externum is imperfectly separated from the tendon, and a portion of the tendon extends to the Margo solearis in parallel with the Facies solearis. The connection between the bone and the tendon is imperfect. The inner layer formation and the grooves of ossification are observed on the surface of the outer layer (figs. 14 & 15). In the cases of Nos. 3, 5~7, 10 and 11, the cartilage is observed for the whole length of the insertion. In the cases of Nos. 8 and 9, the blue line is observed on the layer of the fibrocartilage. In the cases of Nos. 2~11, the outer layer formation of the compact bone and many grooves of the ossification are observed.

Nos. 12~14 (1~2 years): The development of the inner and outer layers of the compact bone is moderate. The teeth form, many grooves of the ossification, and many small vessels are observed at the outer layer of the compact bone.

Nos. 15~17 (3~4 years): The arrangement of the outer circumferential lamellae is the same as the orientation of the tension of the tendon (fig. 2), and the sow teeth form is observed on the surface of the outer layer of the compact bone. The layer of the fibrocartilage is observed entirely at the tendon insertion, and the blue line separates unmineralized and mineralized fibrocartilage. In the case of No. 17, ossification has disappeared at the tendon insertion.

Nos. 18~26 (5~6 years): The development of the compact bone is clear, and the clear bone trabeculae, based on this compact bone, radiate to the upper part. The ossification has disappeared at the tendon insertion. In the cases of Nos. 20, 22, 24~26, the outer layer of the compact bone projects to the out side.

Nos. 27~46 (7~15 years): The compact bone of the insertion and the

trabeculae become increasingly strong. As a whole, the outer layer projects to the out side. In the cases of Nos. 27, 29, 35~37, 42, 45 and 46, calcification is observed in the tendon that attaches to the eminence of the outer layer. In the cases of Nos. 33 and 37, the eminence of the outer layer is especially clear.

2) Separation into groups

Results of the histological findings of the insertion of the deep flexor tendon are given in table 3.

The following five develepmental stages are distinguished according to the histological changes in the insertion of the deep flexor tendon.

TABLE 3 *Insertion of flexor tendon*

BONE SIDE	STAGE						
	Ia	Ib	Ic	II	III	IV	V
Cartilage	+	+	±				
Compact bone							
inner layer							
appearance			±	+	++	++	+++
ossification		±	±	+	+		
outer layer							
appearance					+	+++	+++
ossification					+	+	
Sponge bone							
appearance of trabecula					±	+	+

TENDON SIDE	STAGE						
	Ia	Ib	Ic	II	III	IV	V
Fibrocartilage							
appearance of cartilage					+	+	+
calcification						+	+
Tendon							
cellular	+	±					
fibrous		±	+	+	++	++	++
separation of peritendineum ext.					+	+	+
connection of bone					+	+	+

N.B. Ia 15~35 cm length embryo
Ib 39~80 cm length embryo
Ic 85~95 cm length embryo
II 110 cm length embryo~2 weeks old infant
III 3 months~1.5 years
IV 1.5~3 years
V 4 years and over

1) The stage of cartilage (from 15 to 80 cm embryos): The distal phalanx at the insertion of the deep flexor tendon is composed of cartilage (fig. 1). A portion of the embryonic deep flexor tendon extends almost to the Margo solearis, and the fibers form a portion of the periosteum.

2) The stage of inner compact layer formation (from 85 cm embryos to 2 weeks old infants): Formation of the compact bone is observed in the distal phalanx at the insertion of the deep flexor tendon, and especially in this latter stages, the haversian system is quite clearly formed. The peritendineum externum is imperfectly separated from the tendon, and a portion of the tendon extends to the Margo solearis parallel with the Facies solearis. The intercellular substances of tendon consist of clear collagenous fibers, but the connection between the tendon and the bone is imperfect (figs. 4, 5, 14 & 15).

3) The stage of outer compact layer formation (from 3 months to 1.5 years old): The haversian system of the inner compact layer becomes clearer, and, moreover, the formation of the outer layer can be observed. The outer layer shows many grooves of ossification on the surface of the inner compact. The peritendineum externum separates from the tendon and transfers to the layer of the periosteum. The tendon is attached directly to the surface of the bone (figs. 16 & 17).

4) The stage of fibrocartilage formation (from 1.5 to 3 years old): Cartilage cells appear among the fiber bundles of the tendon near the insertion of the deep flexor tendon. In this latter stage, a layer of fibrocartilage is clearly distinguished as a whole between the tendon and the outer compact layer (fig. 18).

5) The stage of completion of the insertion (4 years old and over): In this stage, the ossification disappears and the insertion of the tendon may be complete. Hereafter, the compacta of the insertion and the trabeculae become stronger (figs. 2, 19~21).

III Electron microscopic finding

1) Bone surface

The bone surface appears as a dense line, and is studded with projections of varying size. These projections are roughly conical in shape. The conical projections are associated with individual collagen fibers. Where a number of fibers enter the bone as a bundle a projection may be found (fig. 22). The fibers which are embedded in the bone may have characteristic collagen banding (figs. 28 & 29). Near the surface they tend to be parallel and to continue in the orientation of their insertion. There are some cases where a dense line may be not observed at the bone surface. We observe an ossification groove on the

bone surface, and the collagen fiber, about 1,000 Å in width, may be observed around an ossification groove (fig. 23).

2) Bone side

The bone minerals are distributed along lines parallel to the long axis of the collagen. Moreover the spots fuse in linear or needle-shaped crystallites which span the band region (fig. 28). The bone collagen fiber are about 1,000 Å in width, and they show a cross or strangely oblique orientation. The axial period of the collagen fiber is from 600 to 700 Å. It is divided into D-region and L-region, and several transverse dark lines per period may usually be observed (fig. 29).

Osteocytes embedded in mineralized bone. The cell surface does not rest on the mineralized collagen but is separated from it by a layer of structureless material of a moderate density (fig. 27). The osteocytes have cytoplasmic processes which extend into bone canaliculi, and these processes are also separated from the mineralized collagen by an amorphous matrix.

3) Tendon side

The tendon consists almost entirely of bundles of fibres lying approximately parallel to its long axis, and it is composed mainly of collagen. The axial period of collagenous fiber is on the average 640 Å. It is divided into D-region (high dense region) and L-region (comparatively low dense region); the width of the former is on the average 380 Å and that of the latter about 260 Å respectively, as determined by measurements on several fibrils. Figures 25 and 26 show 11 transverse dark lines per period. The diameter of collagenous fiber is about 3,000 Å, and the maximum is about 4,000 Å. In a few instances, the collagen fibers seem to splay out into multiple branches. It can be observed that there are numerous fine fibrils between the collagenous fibers (fig. 24).

In the transitional region between the tendon and the bone, the chondrocyte with short processes lies in a lacuna containing small filament and collagen fibrils (fig. 26).

DISCUSSION

The literature dealing with the insertion of the tendon is extensive[7,15~18,21,26,33,36]. According to the above literature, this can be classified into the following four types: type I, the periost is observed at the tendon insertion; type II, the tendon fibers insert into the bone; type III, the fibrocartilage zone is observed at the tendon insertion; and type IV, "Einstrahlungsknochen"[33] is observed at the tendon insertion.

Previous work in this series has shown a regional difference of a tendon

insertion, but has not shown an age-change.

Described above in the section, RESULTS, the five following developmental stages in the insertion of the extensor tendon were distinguished: 1) the stage of cartilage, 2) the stage of sponge bone formation, 3) the stage of fibrous bone formation, 4) the stage of lamellar bone formation, 5) the stage of completion of the insertion; and in the insertion of the deep flexor tendon: 1) the stage of cartilage, 2) the stage of inner compact layer formation, 3) the stage of outer compact layer formation, 4) the stage of fibrocartilage formation, 5) the stage of completion of the insertion.

As mentioned above, age seems to be a decisive influence on the morphology of the insertion of the tendon.

In the extensor tendon, the stage of sponge bone formation, fibrous bone formation, and lamellar bone formation are like types II and IV. RANVIER (1880) observed that whenever a tendon or ligament was inserted into bone, the fibers continued into the bone as perforation fibers. MOLLIER (1937) observed that superficial tendon fibers continued with the periosteum at the insertion of the tendon. PETERSEN (1930) described "Einstrahlungsknochen" and stated that it consisted of the secondary periosteal bone.

It is supposed that the function of the fibrous bone layer of the insertion of the extensor tendon have elasticity and expansibility. MOLLIER (1937) pointed out that the tendon fibers inserted into the bone, and the fiber-bundle orientation was the same as tension direction. We also obtained the same findings.

In the deep flexor tendon, the stage of inner compact layer formation is like type I. In this stage, the connection between the tendon and the bone is imperfect, and the periosteal layer, consisting of fibroblasts, is observed at the tendon insertion. DOLGO-SABUROFF (1929/1930), using the cat patellar-tendon inserted into the tibia, described four zones; tendon, fibrocartilage, mineralized fibrocartilage, and bone. He also described the cartilage cells as beginning to appear and gradually increase in number. The tendon gradually takes on the appearance of fibrocartilage. The stage of outer compact layer formation is like type II, III. The stage of fibrocartilage formation is like type III.

We point out that the stage of outer compact layer formation coincides with the beginning of the active movement of the pony. The surface of the outer layer likes the teeth of a saw, and projects to outside as a whole. In generally, the arrangement of the lamellae is the same as the orientation of the tension of the tendon. As stated above, the tension of the animal's movement has a part in the formation of the tendon insertion. According to KROMPECHER (1937/1938), the condition of the production of the fibrocartilage was the tension and the pressure. In fact, we think that tension has a part in the production

of the fibrocartilage in the insertion of the deep flexor tendon.

The morphological difference between the insertion of the extensor tendon and the deep flexor tendon is observed. It is thought that its difference depends upon the functional difference between the extensor tendon and the flexor tendon. It is generally known that the flexor tendon's tension is greater than that of the extensor tendon.

It has been found that the tendon fibers are inserted into the bone at the distal end of the insertion of the extensor tendon by microscopical observation. But, as for the deep flexor tendon, the tendon fibers reach only the bone surface, and consequently the point of insertion between the bone and the tendon is not clear, and the electron microscopy is used for observation in detail.

As the tendon is inserted into the bone, the collagenous fibers of the tendon are arranged perpendicularly or obliquely to the bone surface and enter the bone in an approximately perpendicular or oblique position. In recent years, studies on the fine structure of collagen fiber have been reported by many investigators. In the tendon, we observe that the axial period of collagen fiber is on the average 640 Å. It is divided into D-region (high dense region) and L-region (comparatively low dense region); the width of the D-region is on the average 380 Å, and that of the L-region about 260 Å respectively as determined by measurements of several fibrils. Eleven transverse dark lines per period may usually be observed, 8 in the D-region and 3 in the L-region. The diameter of collagenous fiber is about 3,000 Å, and the maximum is about 4,000 Å. According to NEMETSCHEK (1964), the band pattern of collagen fiber has been investigated by means of the negative staining method with phosphotungustic acid on isolated or extracted collagen fiber, and 10 bands in an axially repeating unit was revealed. With ultra-thin sectioning methods, however, many fewer (6 to 7) intraperiodic bands were seen than reported hitherto. But recently SHINAGAWA et al. (1966) showed 16 bands in each period of the fibril in the newt corum.

It remains to be proved that the difference of the periodicity of the band of a collagen fibril is due to the difference in tissue or to the resolution of the electron microscopy.

ACKNOWLEDGEMENTS

The author is grateful to Dr. T. SAKAI, Professor of the Department of Surgery, Dr. S. OYA, Ex-professor of the Department of Internal Medicine, Dr. Y. FUJIMOTO, Professor of the Department of Comparative Pathology, and Dr. N. KUDO, Professor of the Department of Anatomy, for their kind guidance in this study.

References

1) ALBERT, K. (1909): Untersuchungen über den Flach und Vollhuf des Pferdes (*Inaug. Diss., Dresden*) [MUSZAR, A. (1930): *Münch. tierärztl. Wschr.*, **81**, 311]
2) BASSETT, C. A. L. & HERMANN, I. (1961): *Nature Lond.*, **190**, 460
3) BROSKE, M. (1925): Untersuchungen über Faserknorpel bein Pferde (*Inaug. Diss., Berlin*) [SCHAFFER, J. (1930): Handbuch der mikroskopischen Anatomie des Menschen, Die Gewebe II, Hrsg. MÖLLENDORFF, W., Berlin: Verlag von Julius Springer]
4) CHAPMAN, J. A. (1961): *J. biophys. biochem. Cytol.*, **9**, 639
5) CLIZ, S. (1929): *Berl. tierärztl. Wschr.*, **45**, 869
6) CUTHBERTSON, D. M., SIRIS, E. & GILFILLAN, R. S. (1964): *J. bone Jt Surg.*, **46** A, 781
7) DOLGO-SABUROFF, B. (1929/1930): *Anat. Anz.*, **58**, 80
8) DOLGO-SABUROFF, B. (1935): *Morph. Jb.*, **75**, 395
9) GOLDBERG, B. & GREEN, H. (1964): *J. Cell Biol.*, **22**, 227
10) GRANT, R. A., HORNE, R. W. & COX, R. W. (1965): *Nature Lond.*, **207**, 822
11) GROSS, J., HIGHBERGER, J. G. & SCHMITT, F. O. (1952): *Proc. Soc. exp. Biol.*, **80**, 462
12) GROSS, J., HIGHBERGER, J. H. & SCHMITT, F. O. (1954): *Proc. Natn. Acad. Sci. U.S.A.*, **40**, 679
13) FLECK, O. (1925): Vergleichende Untersuchungen über die Knochenstruktur zwischen dem flachen und dem normalen Hufbein (*Inaug. Diss., Leipzig*) [*Deut. tierarztl. Wschr.*, **35**, 679]
14) KAJIKAWA, K. (1969): *J. Electron Microsc.*, **10**, 1
15) KNESS, K. H. (1965): *Z. Zellforsch. mikrosk. Anat.*, **44**, 585
16) KNESS, K. H. & BIERMANN, H. (1958): Ibid., **49**, 142
17) KNESS, K. H. & HARNACK, M. V. (1962): Ibid., **57**, 520
18) KÖLLIKER, A. (1849): *Z. Zool.* **I** [HÄGGQVIST, G. (1931): Handbuch der mikroskopischen Anatomie des Menschen, Die Gewebe III, Hrsg. MÖLLENDORFF, W., Berlin: Verlag von Julius Springer]
19) KROMPECHER, S. (1937/1938): *Verhandlungen der anatomischen Gesellschaft, Anat. Anz.*, **85**, Erg. 229
20) LANG, J. (1960): *Anat. Anz.*, **108**, 225
21) LUBOSH, W. (1937): *Morph. Jb.*, **80**, 89
22) MÖLLENDORFF, W. (1930): Handbuch der mikroskopischen Anatomie des Menschen, Die Gewebe II, Berlin: Verlag von Julius Springer
23) MÖLLENDORFF, W. (1939): Ibid., Die Gewebe III
24) MÖLLENDORFF, W. (1956): Ibid., Die Gewebe IV
25) MÖLLER, H. (1872): *Magazin fur die gesamte Tierheilk.*, **38**, 321 [MUSZAR, A. (1930): *Münch. tierärztl. Wschr.*, **81**, 311]
26) MOLLIER, G. (1937): *Morph, Jb.*, **79**, 161
27) MUSZAR, A. (1930): *Münch. tierärztl. Wschr.*, **81**, 311

28) NEMETSCHEK, T. (1964): *Verhandlungen der anatomischen Gesellschaft, Anat. Anz.*, **115**, Erg. 109
29) NICKEL, R. & WISSDORF, H. (1964): *Zentbl. VetMed.*, **11**, 265
30) OLSEN, B. R. (1963): *Z. Zellforsch. mikrosk. Anat.*, **59**, 184
31) OLSEN, B. R. (1963): Ibid., **59**, 199
32) PALADE, G. E. (1952): *J. exp Med.*, **95**, 285
33) PETERSEN, H. (1930): Handbuch der miroskopischen Anatomie des Menschen, Die Gewebe II, Hrsg. MÖLLENDORFF, W., Berlin: Verlag von Julius Springer
34) POMMER, G. (1917): *Wien. klin. Wschr.*, **20**, 328
35) PORTER, K. R. & VANAMEE, P. (1949): *Proc. Soc. exp. Biol. Med.*, **71**, 513
36) RANVIER, L. (1880): *Lecons d' Anatomic géneral surle Systéme musculaire* (Paris) [HÄGGQVIST, G. (1931): Handbuch der mikroskopischen Anatomie des Menschen, Die Gewebe III, Hrsg. MÖLLENDORFF, W., Berlin: Verlag von Julius Springer]
37) ROBINSON, R. A. & CAMERON, D. A. (1956): *J. biophys. biochem. Cytol.*, **2**, 253
38) ROBINSON, R. A. & WATSON, M. L. (1952): *Anat.* Rec., **114**, 383
39) SAARNI, I. (1921): *Die intrauterine Entwicklung der Extremitätenknochen des Pferdes (Inaug. Diss., Giessen)* [MUSZAR, A. (1930): *Münch tierärztl. Wschr.*, **81**, 311]
40) SCHMITT, F. O., HALL, C. E. & JACUS, M. A. (1942): *J. Cell. Comp. Physiol.*, **20**, 11
41) SCHNEIDER, H. (1955): *Münch. med. Wschr.*, **44** 1479
42) SCHUBERT, M. (1931): *Anat. Anz.*, **73**, 119
43) SHINAGAWA, Y., UYEDA, M., KAMINO, K. & INOUYE, A. (1966): Electron Microscopy 1966 volume II biology 407, Ed. UYEDA, R., Tokyo: Maruzen Co., Ltd.
44) SIEMER, E. (1931): *Tire ärztl. Rdsch.*, **37**, 793
45) STERN, I. B. (1962): *Am. J. Anat.*, **115**, 377
46) STOLCH. H. (1920): *Ein Pferdefetus von 202 Tagen (Inaug. Diss., München)* [MUSZAR, A. (1930): *Münch. tierärztl. Wschr.*, **81**, 311]
47) WASSERMANN, F. & ROTH, L. E. (1952): *Anat. Rec.*, **115**, 443
48) WATSON, M. L. & ROBINSON, R. A. (1953): *Am. J. Anat.*, **93**, 25
49) WEIDENREICH, F. (1930): Handbuch der mikroskopischen Anatomie des Menschen, Die Gewebe II, Hrsg. MÖLLENDORFF, W. Berlin: Verlag von Julius Springer
50) WOLFF, J. (1870): *Virchows Arch. path. Anat. Physiol.*, **50**, 389
51) WOLLYNSKI, F. A. (1936): *Anat. Anz.*, **82**, 260
52) WOLPERS, C. (1944): *Klin. Wschr.*, **23**, 169

EXPLANATION OF PLATES

PLATE I

Fig. 1 The insertion of the extensor tendon (E) and the flexor tendon (F) (56 cm embryo) H. & E. ×10

Fig. 2 The insertion of the flexor tendon
The inner (I) and outer layers (O) of the compact bone (4 years old) H. & E. ×10

Fig. 3 The insertion of the extensor tendon
The compact bone at the distal part (D) of the insertion of the tendon and the spongy bone at the middle (M) to the proximal part (P) of the insertion of the tendon (5 years old) H. & E. ×10


E
F
1


D
M
P
3


D
O
P
2

PLATE II

Figs. 4 & 5 The insertion of the flexor tendon
The inner compact layer formation (105 cm embryo and 2 weeks old infant) H. & E. ×20


5
4

PLATE III

The insertion of the extensor tendon is shown in figures 6~13. H. & E.

Fig. 6	56 cm embryo	× 150
Fig. 7	105 cm embryo	× 150
Fig. 8	2 weeks old infant	× 40
Fig. 9	3 months old infant	× 150
Fig. 10	1 year old	× 150
Fig. 11	2 years old	× 150
Fig. 12	3 years old	× 150
Fig. 13	4 years old	× 150


6

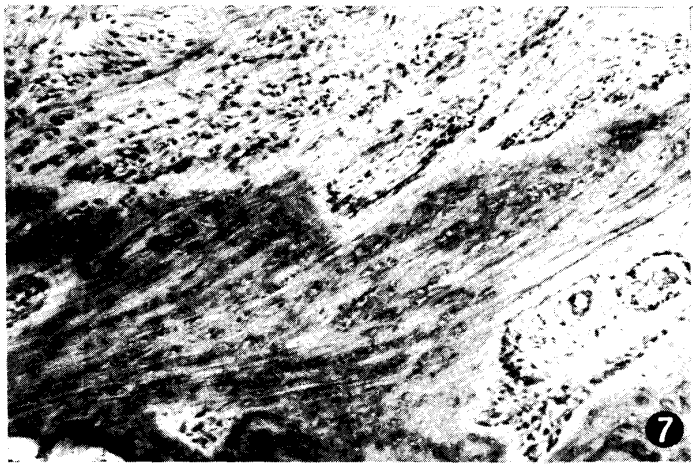
7


8


9


10

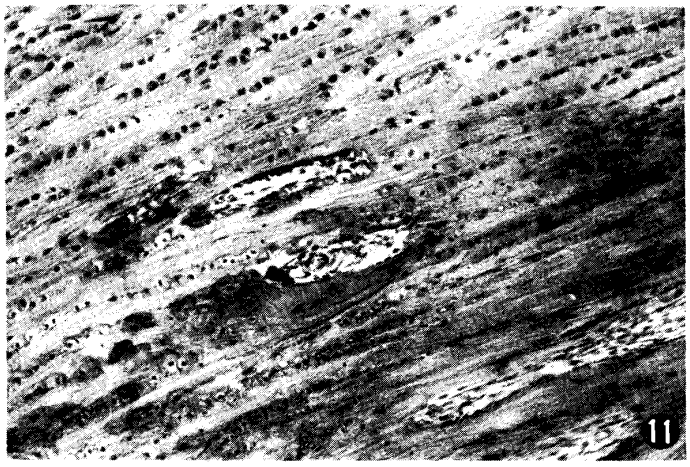
11


12


13

PLATE IV

The insertion of the flexor tendon in figures 14~21 H. & E.

Fig. 14	105 cm embryo	× 40
Fig. 15	2 weeks old infant	× 40
Fig. 16	3 months old infant	× 150
Fig. 17	1 years old	× 150
Fig. 18	2 years old	× 150
Fig. 19	4 years old	× 150
Fig. 20	6 years old	× 150
Fig. 21	8 years old	× 150

Bone (B), mineralized fibrocartilage (M), fibrocartilage (F), and tendon (T)

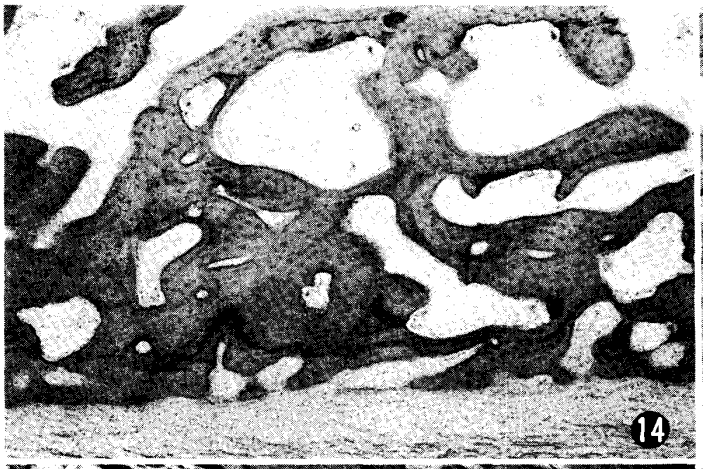
14

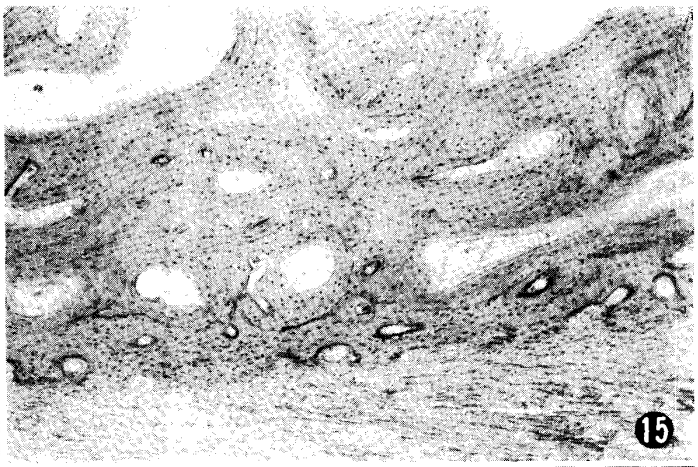
15

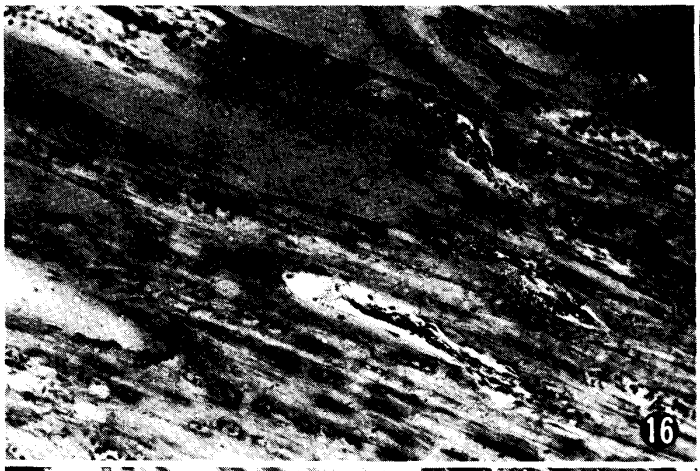
16


17


18


19


20


B
M
21

PLATE V

Fig. 22 An electron micrograph of the insertion of the flexor tendon ×20,000

Fig. 23 The surface of the ossification grooves ×10,000


22

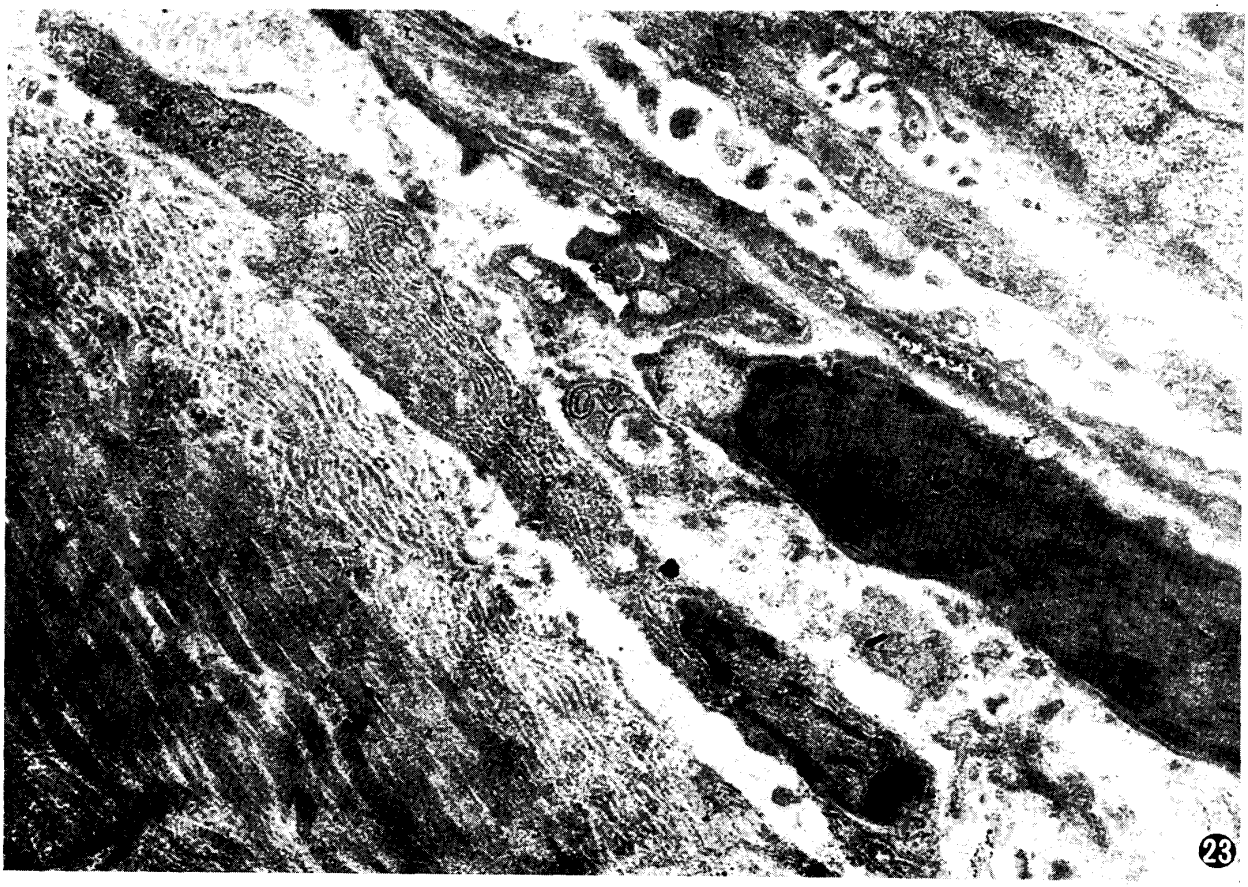
23

PLATE VI

Fig. 24 Numerous fine fibrils between the collagenous fibers ×120,000

Fig. 25 The 11 bands in each period of fibril ×160,000



24

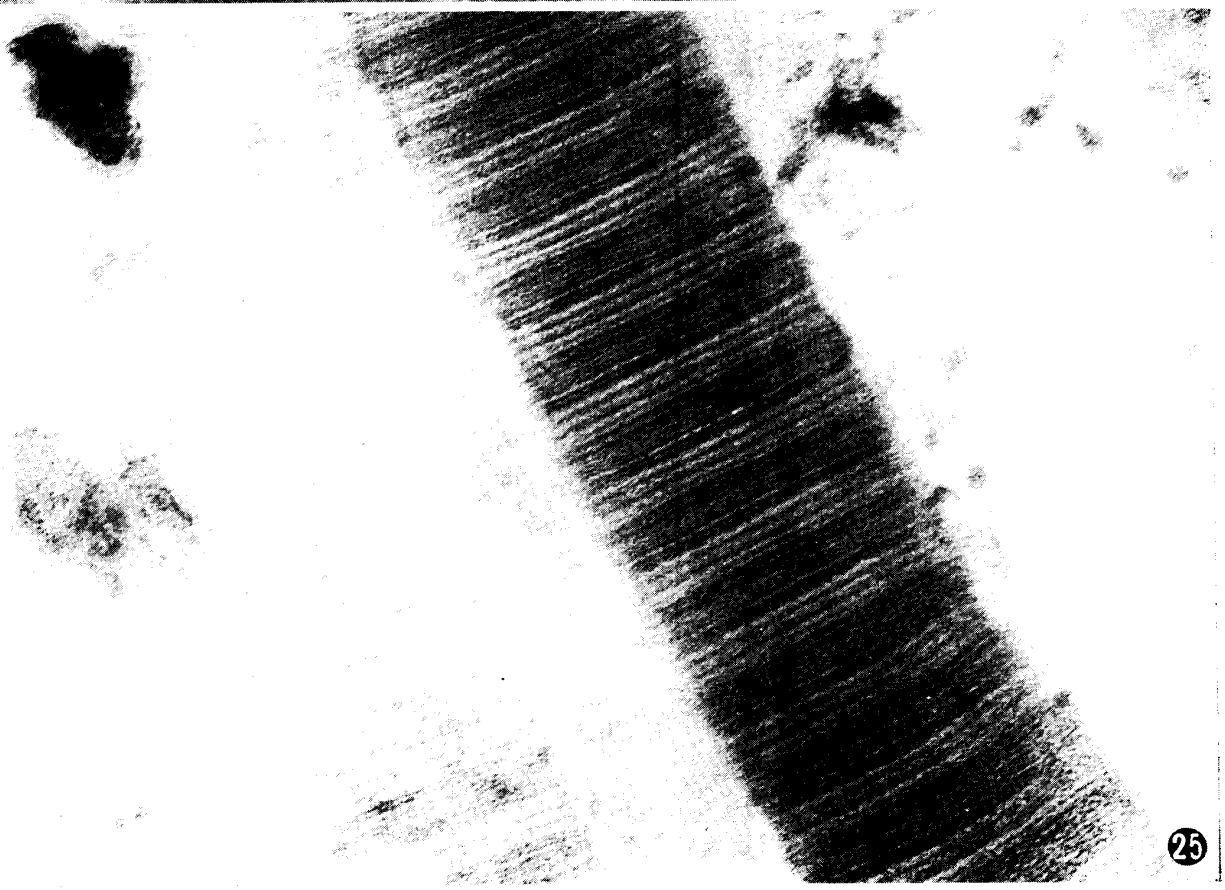

25

PLATE VII

Fig. 26 The chondrocyte ×10,000

Fig. 27 The osteocyte ×10,000

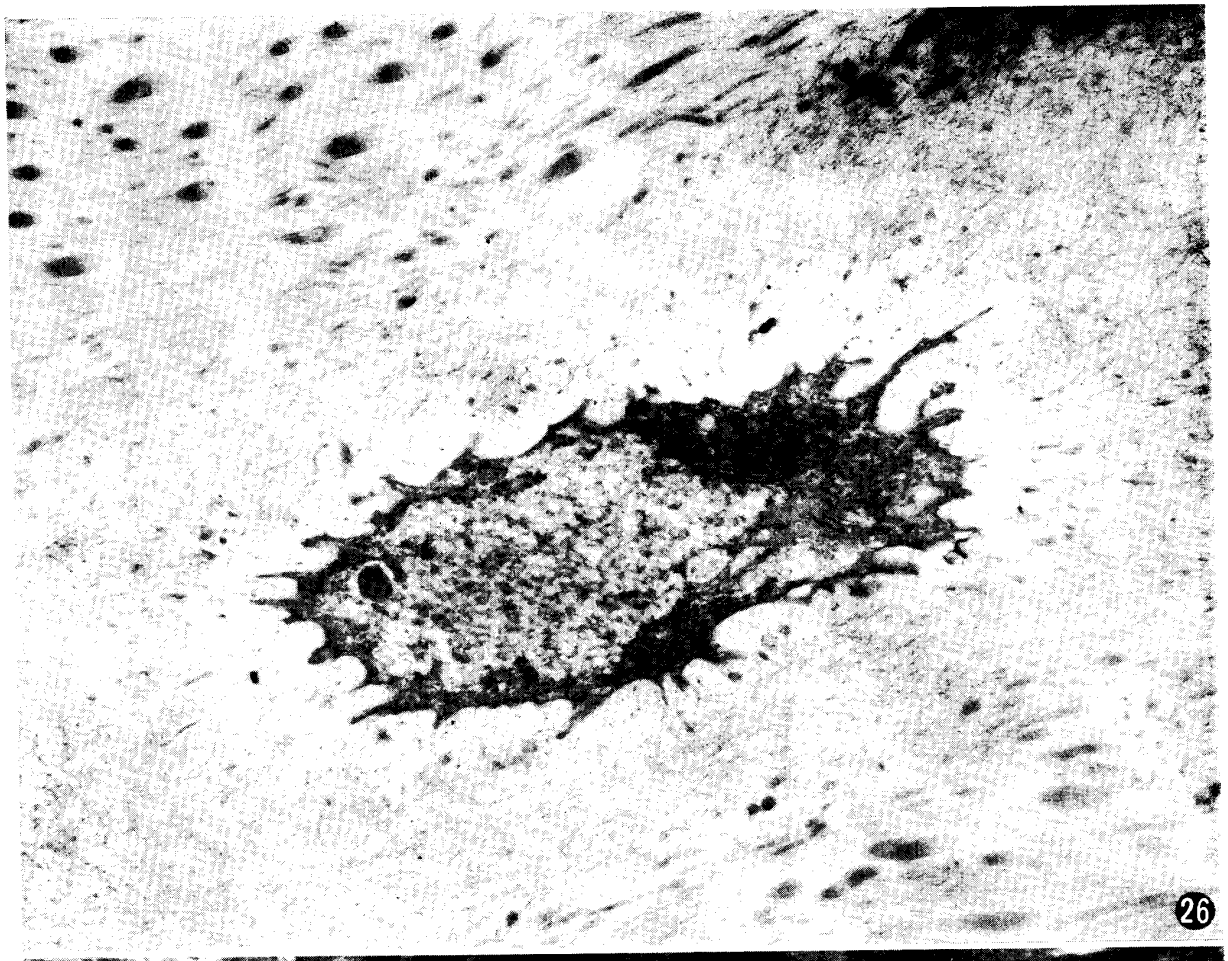
26

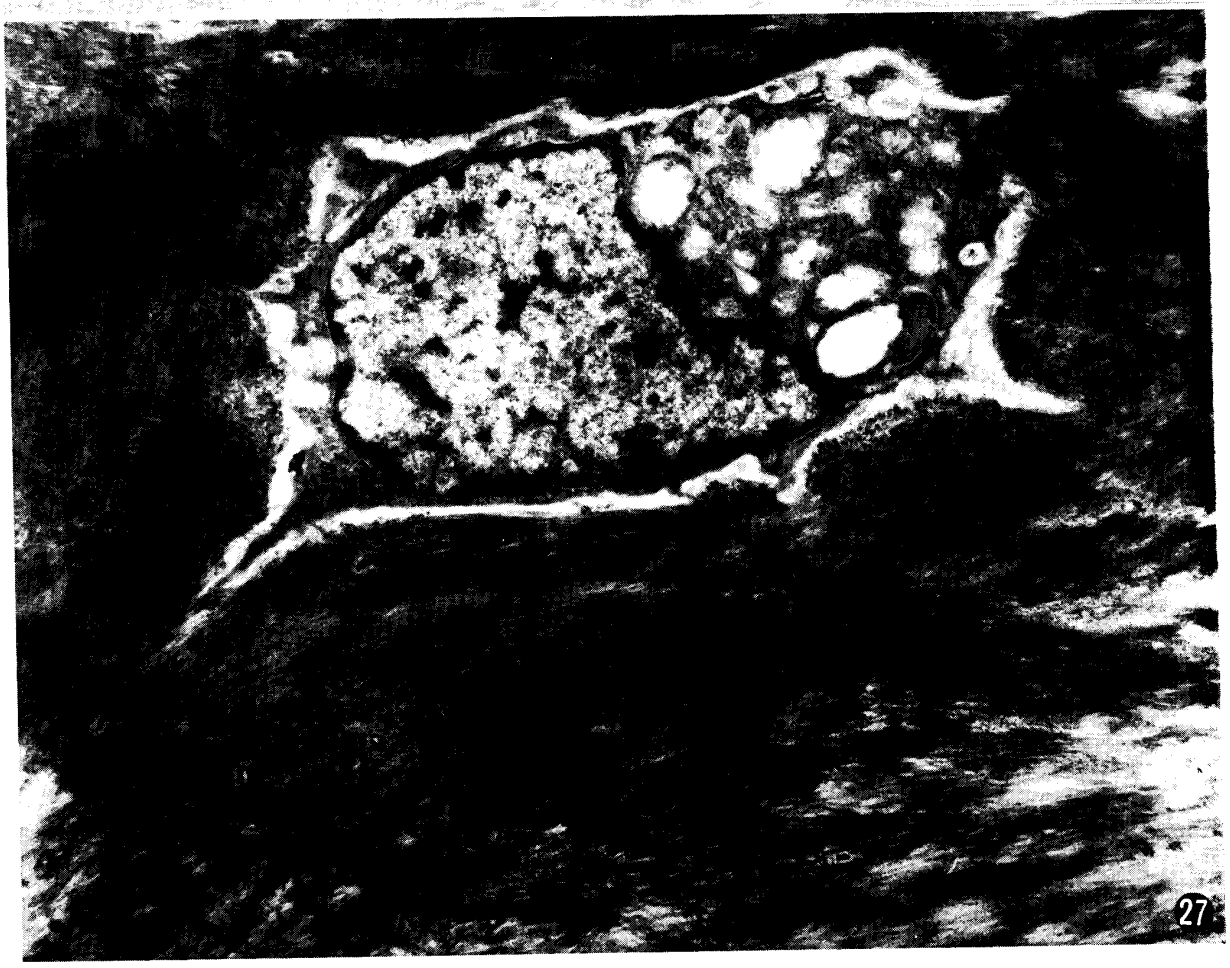
27

PLATE VIII

Fig. 28 Undecalcified section of the bone
The needle-shaped crystallites × 10,000

Fig. 29 Decalcified section of the bone
The collagen fibers of the bone × 10,000


28


29