Jap. J. vet. Res., **21**, 41~49 (1973)

CYTOGENETICAL STUDIES ON SWINE INTERSEXES*

Yoh-Ichi MIYAKE

Department of Veterinary Obstetrics
Faculty of Veterinary Medicine
Hokkaido University, Sapporo, Japan

(Received for publication, February 10, 1973)

Eight cases of swine intersexes, about 6 months old, were investigated cytogenetically and morphologically. Three normal females and 3 males of similar ages were used as controls. The intersexes examined were classified into 5 types by gonadal morphology. Chromosome karyotype of cultured leucocytes from the intersexes revealed a 38,XX constitution, the same as the normal female pattern in the swine, regardless of the degree of gonadal deviation. No sex-chromosome chimerism was observed. A higher incidence of drumsticks in neutrophilic nuclei was indicated in the intersexes as well as normal females. These suggest that the present intersexes are genetically female.

Studies on embryological mechanisms of the development of mammalian intersexes are very attractive to investigators working in the field of animal reproduction as well as to cytogenetists, because such studies may probably give us some clue to resolve complex relations between morphological features of the fetus and sex determination or differentiation. Recently, the development of investigations in this field has promptly been accelerated by introduction of new cytogenetical methods, especially advanced techniques for chromosome analysis. In the bovine species, many studies have been carried out on the chromosome karyotype of intersexual individuals including freemartins[1,6~8]. Intersexes in the goat have also been investigated cytogenetically[11]. In swine, however, little information is available on the chromosome karyotype of intersexual animals, especially with interrelations between the gonadal morphology and chromosome karyotypes. In this paper, the present author intends to add further knowledge in this area through cytogenetical investigations of 8 swine intersexual cases with various morphological types of the gonad.

MATERIALS AND METHODS

Eight cases of swine intersexes with various malformed gonads at necropsy were used in this study, while 3 normal pigs each of male and female sex were provided as controls. All of the pigs, about 6 months old, hybrids of Landrase,

* This paper is based on part of a thesis submitted by the author in partial fulfillment of the requirements for the degree of Master of Veterinary Medicine.

were obtained from a slaughterhouse in Sapporo, Hokkaido. After slaughter the whole reproductive organs were separated, macroscopically inspected and measured. Some pieces of each gonad were fixed with 10 percent formalin phosphate buffer, embedded in paraffin and sectioned at 5 μ. After being stained with hematoxylin and eosin, the sections were examined histologically. Samples of chromosome analysis were displayed by the following techniques; leucocytes derived from the sternum bone marrow of each case were incubated in 10 ml of medium, consisting of 81 percent Eagle's minimum essential medium, 10 percent heparin and 9 percent calf serum. After 1/2 hour of incubation at 37°C, mitotic activity was arrested for 1 hour by adding colchicine at a final concentration of 3 μg per 1 ml of culture medium at 37°C. After a hypotonic treatment with 0.075 M KCl and a fixation with Carnoy solution (1 part glacial acetic acid plus 3 parts methyl alcohol), the cells were stained with Giemsa's solution. Analysis for the chromosome karyotype was made with 30 metaphase figures per animal. For this purpose, a microscopic photograph of a well-spread metaphase plate per case was prepared with a final magnification of 1,000, and chromosomes on the photographic paper were cut out. Thus, a karyotype was made by serial arrangement of chromosomes according to the method by MURAMOTO et al. For a sex chromatin test, kidney cells were squashed on the slide and stained with lacto-aceto-orcein. Five hundreds of kidney cells were examined microscopically and positive percentages of sex chromatin were calculated both in intersexes and control cases. Drumsticks were analyzed on the incidence per thousand neutrophilic leucocytes on smear preparations from spleen blood. Gonadal smears from testes of normal males and from testes-like tissues of the intersexes were fixed with alcohol, stained with Giemsa's solution and checked microscopically for the presence of sperms.

RESULTS

The intersexual cases examined were grouped into the following 5 types according to Omura and Kagiyama's classification of gonadal morphological characteristics:

Type A: both sides testis-like: 2 cases;
Type B: both sides ovo-testis: 2 cases;
Type C: one side testis-like, the other side ovo-testis: 1 case;
Type D: one side testis-like, the other side ovary-like: 1 case;
Type E: one side ovary-like, the other side ovo-testis: 2 cases.

Logically, there should be another one group with ovary-like gonads on both sides, but such a case was not observed in the present author's materials. In the ovo-testis gonad, both testis-like and ovary-like components were clearly

separated by a well-developed connective tissue. The testis-like component in all cases was small in size as compared with the testis of control males and the mediastinum testis was entirely absent. The ovary-like component in the cases of Type B to E contained several small ovarian follicle-like vesicles with follicular fluid-like transparent liquid. Histologically, the testis-like component had seminiferous tubules and interstitial cells, but none of male germ cells was shown (fig. 3), whereas the testes from control males showed typical spermatogenesis (fig. 2). The follicular vesicles of the ovary-like tissue had the granulosa layer.

As for accessory sexual organs, in all cases of intersex, a pair of oviduct-like small tubes, an almost normally developed uterus, cervix and vagina were observed. A pair of vas deferens-like small tubes and epididymis were seen in all intersexes excepting the side of ovary-like gonad in cases of Type E, ending blindly near the vagina. The seminal vesicle, prostate and bulbo urethral gland could not be found macroscopically. An enlarged clitoris protruded upwards between the vulval labia as compared with normal female, although in some cases it could not be confirmed because of missing of the vulva at slaughter.

The macroscopical findings on sexual organs of the intersexes and controls are summarized in table 1. The whole appearance of the sexual organs of an intersex having bilateral ovo-testes (case B_1) is shown in figure 1 according to the mentioned items by SOMLEV et al.[18]

The results of the chromosome karyotype analysis and the incidences of sex chromatin and of a drumstick for all cases examined are indicated in table 2. Intersex cases (fig. 6), as well as control females, exhibited principally the normal female karyotype in the swine, 38, XX (fig. 8), whereas normal males exhibited 38,XY (fig. 7). There were few exceptional karyotypes in some cases. In case A_1, 37,XX was detected, where one acrocentric chromosome belonging to group 6 was lacking, and in case E_1 a karyotype with 36,XX was shown, where 2 submetacentric chromosomes were lacking. Likewise, a chromosome karyotype with 76,XXXX, polyploidy, was seen in few cells from 4 cases.

The sex chromatin was displayed as a small mass of chromatin adjacent to the inner aspect of the nuclear membrane (fig. 4). Positive percentages of sex chromatin in intersexes, normal females and males were 1.0~3.2 percent, 1.8~2.2 and 1.4~2.0, respectively. The drumstick was displayed as a pedunculated mass of dense chromatin which was attached to one of the nuclear lobes by a fine thread-like stalk (fig. 5). The incidence was 0.6~1.3 percent in intersexes, 0.7~0.8 in normal females and 0~0.3 in normal males, respectively. Furthermore, on gonadal smears none of intersexes showed spermatozoa, while control males did normally.

TABLE 1 *Macroscopical views of intersexes, normal females and males*

	INTERSEXES								NORMAL					
									Female			Male		
	A_1	A_2	B_1	B_2	C	D	E_1	E_2	1	2	3	1	2	3
External sex	F	F	F	F	F	F	F	F	F	F	F	M	M	M
External genitalia														
Vulva	?	?	+	+	?	+	+	+	+	+	+	−	−	−
Clitoris	?	?	+	+	?	+	+	+	+	+	+	−	−	−
Internal genitalia														
Vagina	+	+	+	+	+	+	+	+	+	+	+	−	−	−
Uterus	+*1	+	+*1	+	+*2	+	+	+	+	+	+	−	−	−
Fallopian tubes	+	+	+	+	+	(+)	+	+	+	+	+	−	−	−
Epididymis	+	+	+	+	+	+	(+)	(+)	−	−	−	+	+	+
Vas deferens	+	+	+	+	+	+	(+)	(+)	−	−	−	+	+	+
Accessory reproductive glands														
femal type	−	−	−	−	−	−	−	−	+	+	+	−	−	−
male type	−	−	−	−	−	−	−	−	−	−	−	+	+	+
Gonads*3														
Ovary	−	−	−	−	−	(+)	(+)	(+)	+	+	+	−	−	−
Testis	+	+	−	−	(+)	(+)	−	−	−	−	−	+	+	+
Ovo-testis	−	−	+	+	(+)	−	(+)	(+)	−	−	−	−	−	−

N. B. F: Female, M: Male, ?: Could not be confirmed because of missing at slaughter,
+: Observed, (+): Observed only on one side, −: Not observed

*1: Uterus containing pus-like fluid

*2: Uterus containing a grey colored fluid

*3: All gonads of intersexes were abdominal.

TABLE 2 *Chromosome karyotype, sex chromatin and drumstick*

CASE		CHROMOSOME ANALYSIS		INCIDENCE OF*2 SEX CHROMATIN	INCIDENCE OF*3 DRUMSTICK
		Karyotype	No. of cells counted*1		
				%	%
Intersexes					
	A_1	37,XX 38,XX 76,XXXX	1 26 3	1.2	0.6
	A_2	38,XX	30	1.2	1.2
	B_1	38,XX 76,XXXX	28 2	1.0	0.9
	B_2	38,XX 76,XXXX	29 1	2.0	1.1
	C	38,XX	30	1.4	1.1
	D	38,XX	30	1.8	0.8
	E_1	36,XX 38,XX	1 29	2.2	0.9
	E_2	38,XX 76,XXXX	27 3	3.2	1.3
Normal controls					
♀	No. 1	38,XX	30	2.2	0.7
	No. 2	38,XX	30	2.0	0.8
	No. 3	38,XX	30	1.8	0.8
♂	No. 1	38,XY	30	2.0	0.3
	No. 2	38,XY	30	1.4	0
	No. 3	38,XY	30	1.4	0.1

N. B. *1: In total 30 metaphase figures cultured from sternum bone marrow
*2: In 500 kidney cell nuclei
*3: In 1,000 neutrophilic leucocytes on spleen blood smear

DISCUSSION

The question whether the intersex is genetically female or male has long been studied and discussed by numerous investigators on many kinds of animals. In the swine species, it is not exceptional. Recently, a majority of authors who cytogenetically investigated swine intersexes reported that their genetic sex seemed to be fundamentally female, in spite of comparatively wide variations in the gonadal deviation. That is, since MAKINO et al. demonstrated that an intersexual pig with testicular gonads had a 38,XX karyotype, the normal female chromosome pattern in the swine, HARD & EISEN (in an intersex with testis), MCFEELY et al. (in 2 male pseudohermaphrodites), MAIK (in 25 intersexes), SOMLEV et al.[17] (in an intersex with ovo-testis), GERNEKE (in 8 intersexes) and VOGT[20] (a male pseudohermaphrodite) succeeded in showing the same chromosomal pattern.

On the contrary, however, McFEE et al. first presented a special case of swine intersex with a 38,XX/XY karyotype in cultured leucocytes, which was very different from the normal female chromosome constitution. VOGT[21], BRUERE et al. and SOMLEV et al.[18] also reported several intersexes with such type of sex-chromosome chimerism. TOYAMA et al. observed other types of chimerism, XX/XXY and XX/XO/XY, in 2 intersexes of this species. Some of these authors considered chimeric intersexes with XX/XY constitution to be swine freemartins, and thought that an XX/XY leucocyte chimerism should be attributed to a chorionic vascular anastomosis between fetuses of opposite sexes during the early intra-uterine life, similarly as in bovine freemartins.

Cytogenetically, the 8 intersexes described in the present paper revealed a fundamentally female chromosome constitution in bone marrow leucocytes, 38,XX, which was quite in accord with those reported by the former authors. But, no sex-chromosome chimerism, as presented by the latter authors, was observed.

It is generally accepted that the Y chromosome in man, and apparently in other mammals, is a sex determinant which is responsible for stimulating the medullary stroma of the genital ridge to produce testicular tissue. Considering such a general acceptance, the question why testicular development can occur in an intersex individual without the Y chromosome will arise. The answer is still obscure. In this connection, however, it is interesting to know an opinion presented by GRIBOFF & LAWRENCE, in which the translocation of a portion of Y chromosome on X chromosome is suggestive in a human intersex case having testicular tissue and apparent XX chromosome constitution. GERNEKE also stated that in some swine intersexes with well-developed testes, 98 percent of the cultured cells examined had a 38,XX karyotype, and remaining 2 percent of the cells showed 39 chromosomes, 38,XX plus extra small one. This extra chromosome was like the normal Y chromosome in the swine, but smaller than the Y.

From the cytogenetical examination of the present author's cases, no evidence was obtained to actively support GERNEKE's statement or the opinion by GRIBOFF & LAWRENCE. In order to clarify the existence of such phenomena, it should be needed, on one hand, that statistical analyses about the arm ratio in each chromosome and the relative length between chromosomes will be carried out. On the other hand, a clearer identification of chromosomes by newly-discovered cytogenetic techniques should also be required for this purpose.

A considerably higher incidence of drumsticks (0.6~1.3 percent) in 1,000 spleen blood neutrophiles was shown in the present author's intersexes and control normal females, whereas the incidence in normal males was less than 0.3 percent. This may support the view that the genetic sex of the present

cases would be female, although, as McFee et al. and Gerneke have already stated, these values do not allow the conclusive determination of genetic sex of the animal by this method.

On the other hand, the incidence of sex chromatin in 500 kidney cell nuclei did not show clear differences among intersexes, control females and males. This method, therefore, seemed to be unsuitable for the genetic sex diterminations in the swine.

Conclusion

Eight cases of swine intersexes, about 6 months old, from a slaughterhouse, were investigated on macroscopical and histological findings of the sexual organs, chromosome karyotype, sex chromatin, drumstick and the presence of spermatozoa on gonadal smears. Six normal animals, three of each sex, of similar ages were used as controls.

1) The intersexes examined were classified into the following 5 types according to the morphological characteristics of the gonads: Type A: both sides testis-like, type B: both sides ovo-testis (fig. 1), type C: one side testis-like, the other side ovo-testis, type D: one side testis-like, the other side ovary-like, type E: one side ovary-like, the other side ovo-testis.

2) Histological findings of the testis-like gonads and testis-like components of ovo-testis showed the seminiferous tubules without any male germ cells (fig. 3). In all cases of intersexes, a pair of oviduct-like tubes, uterus, cervix and vagina were observed. An enlarged clitoris protruded upwards between the vulval labia (fig. 1).

3) Thirty metaphase plates were examined for chromosome karyotype of leucocytes derived from the sternum bone marrow. Intersex cases, as well as control females, exhibited principally the normal female karyotype in the swine, 38,XX (figs. 8 & 6), whereas normal males had 38,XY (fig. 7).

On 500 nuclei of kidney cells, positive percentages of sex chromatin (fig. 4) in the intersexes, normal females and males were 1.0~3.2, 1.8~2.2 and 1.4~2.0 percent, respectively. The results seemed to be unsuitable for the sex diagnosis of the swine.

The drumstick (fig. 3) incidence per 1,000 neutrophilic leucocytes on smear preparations from spleen blood was 0.6~1.3 percent in intersexes, 0.7~0.8 percent in normal females and 0~0.3 percent in normal males, respectively. The fact may support the view that the present intersexes in the swine are genetically female, as is shown clearly in the results of chromosome karyotype analysis.

4) None of intersexes showed spermatozoa on gonadal smears, while control males did normally.

ACKNOWLEDGMENT

I am very grateful to Dr. Tsune ISHIKAWA for his kind suggestions and improvement of the manuscript, and to Dr. Keiichiro KAWATA for his careful reading of the manuscript. Also, I thank Dr. Motomichi SASAKI, Dr. Yuh H NAKANISHI and Miss Michiko MORI who gave profitable advice and assistance and to the veterinarians of the Sapporo Slaughterhouse for their kind cooperation in collecting materials for the present study.

References

1) Basrur, P. K. & Stroitz, D. K. (1966): *Chromosoma*, **19**, 176
2) Bruere, A. N., Fielden, E. D. & Hutchings, H. (1968): *N. Z. vet. J.*, **16**, 31
3) Gerneke, W. H. (1967): *Onderstepoort J. vet. Res.*, **34**, 219
4) Griboff, S. I. & Lawrence, R. (1961): *Am. J. Med.*, **30**, 544
5) Hard, W. L. & Eisen, J. D. (1965): *J. Hered.*, **56**, 254
6) Kanagawa, H., Kawata, K. & Ishikawa, T. (1965): *Jap. J. vet. Res.*, **13**, 43
7) Kanagawa, H., Kawata, K., Ishikawa, T., Muramoto, J. & Ono, H. (1965): *Ibid.*, **13**, 121
8) Kanagawa, H., Muramoto, J., Kawata, K. & Ishikawa, T. (1965): *Ibid.*, **13**, 33
9) Maik, H. (1969): *Genet. pol.*, **10**, 172 (in Polish with English summary)
10) Makino, S., Sasaki, M., Sofuni, T. & Ishikawa, T. (1962): *Proc. Japan Acad.*, **38**, 686
11) Masui, K. (1970): *Chikusan no Kenkyu* (*Anim. Husb., Tokyo*), **24**, 265
12) McFee, A. F., Knight, M. & Banner, M. W. (1966): *Can. J. Genet. Cytol.*, **8**, 502
13) McFeely, R. A., Hare, W. C. D. & Biggers, J. D. (1967): *Cytogenetics*, **6**, 242
14) Muramoto, J., Makino, S., Ishikawa, T. & Kanagawa, H. (1965): *Proc. Japan Acad.*, **141**, 236
15) Ono, S., Trujillo, J. M., Stenius, C., Christian, L. C. & Teplitz, R. L. (1962): *Cytogenetics*, **4**, 258
16) Omura, Y. & Kagiyama, Y. (1968): *Jui-chikusan Shinpo* (*J. vet. Med.*), (476) 850 (in Japanese)
17) Somlev, B., Melander, Y., Hansen-Melander, E., Aamdal, J. & Anderson, K. (1970): *Hereditas*, **64**, 296
18) Somlev, B., Melander, Y., Hansen-Melander, E. & Holm, L. (1970): *Ibid.*, **64**, 203
19) Toyama, Y., Suzuki, T. & Hayashida, S. (1970): *Jap. J. Zootech. Sci.*, **41**, Suppl. 41 (summary in Japanese)
20) Vogt, D. W. (1966): *J. Anim. Sci.*, **25**, 252
21) Vogt, D. W. (1968): *J. Hered.*, **59**, 166

EXPLANATION OF PLATES

PLATE I

Fig. 1 Whole reproductive organs of an intersex case with ovo-testes on both sides (case B_1)
OV: ovo-testis, EP: epididymis, UT: uterus, CR: cervix, VG: vagina, ET: external genitalia, BL: bladder, TS: testis-like component

Fig. 2 Histological findings of a testis from a control male tubules showing typical spermatogenesis × 185

Fig. 3 Histological findings of a testis-like gonad from an intersex (case B_1)
Seminiferous tubules having Sertoli cells but no evidence of spermatogenesis × 185

Fig. 4 Sex chromatin (arrow) in a kidney cell from an intersex (case B_1) × 1,750

Fig. 5 Drumstick (arrow) in a spleen blood leucocyte from an intersex (case B_1) × 1,750

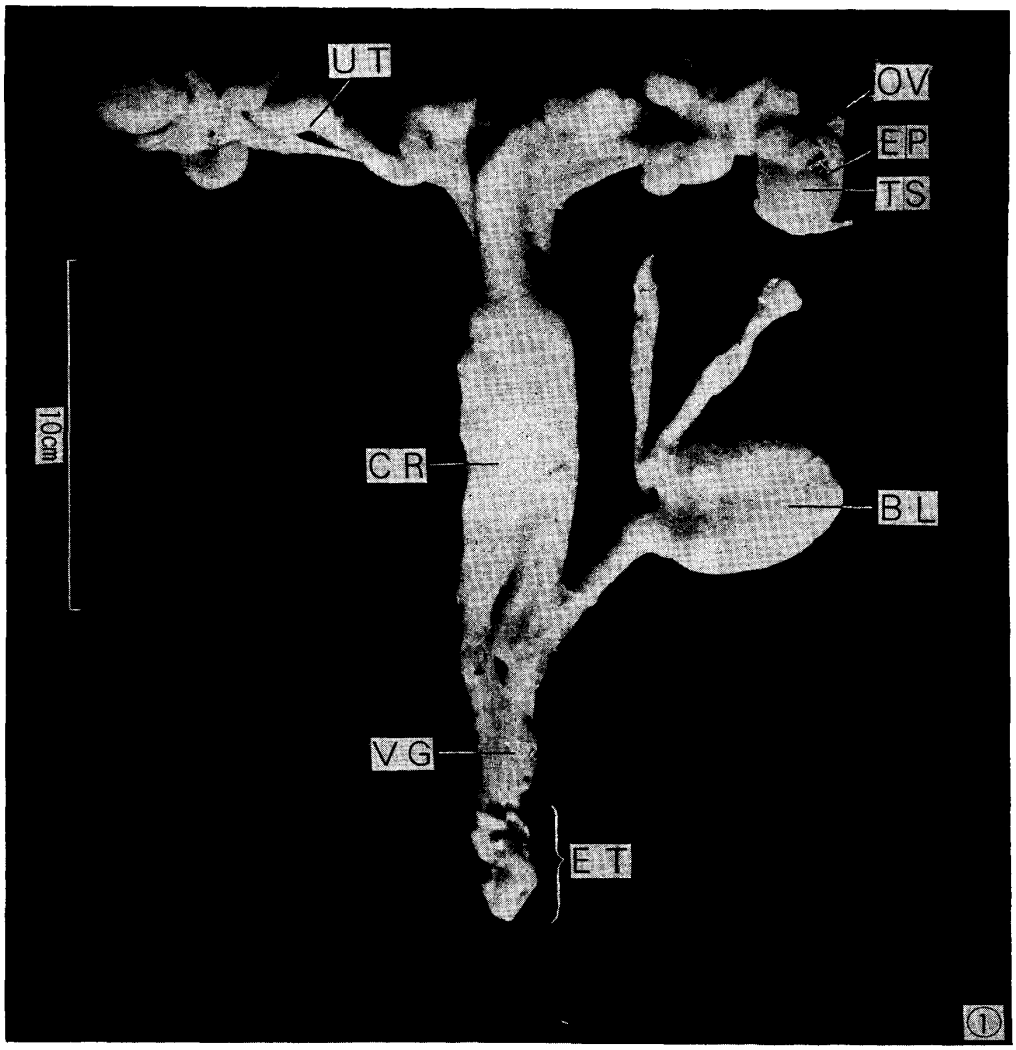
UT
OV
EP
TS
10cm
CR
BL
VG
ET
①

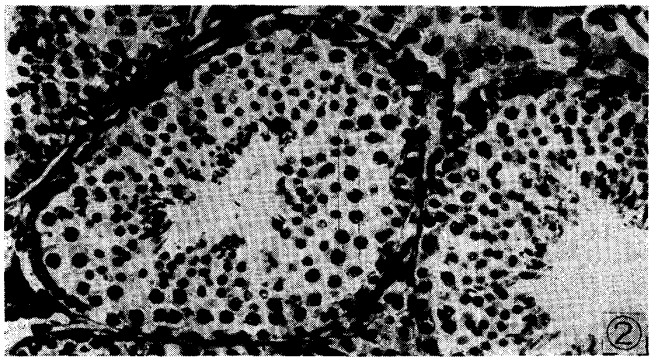
②

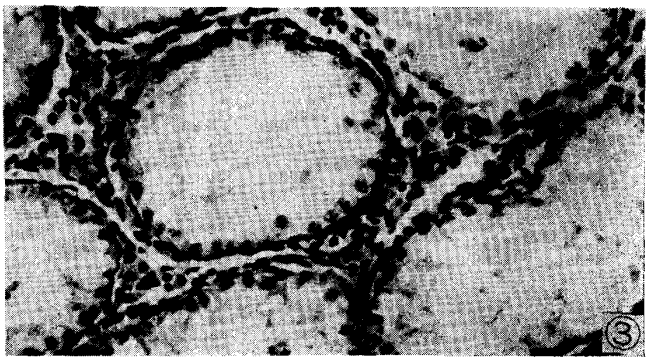
③

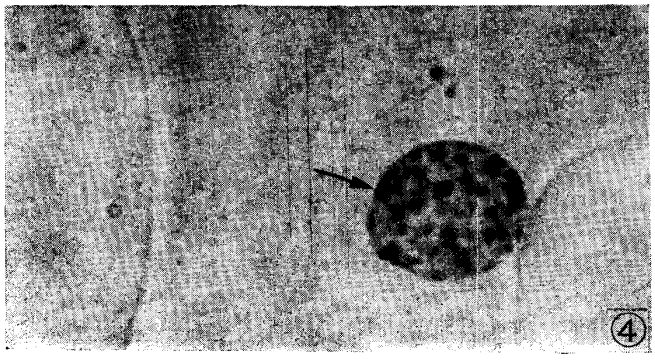
④

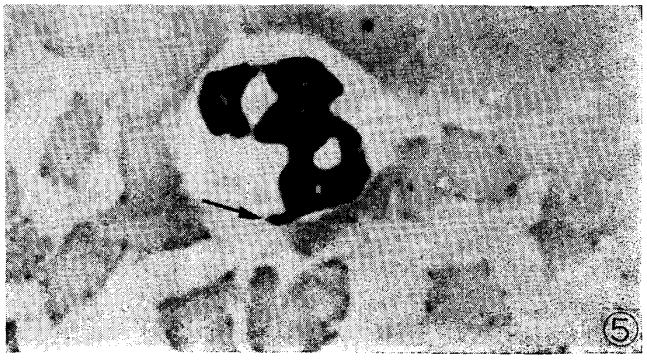
⑤

PLATE II

Fig. 6 Chromosome karyotype in a bone marrow leucocyte from a normal female, 38,XX

Fig. 7 Chromosome karyotype in a bone marrow leucocyte from a normal male, 38,XY

Fig. 8 Chromosome karyotype in a bone marrow leucocyte from an intersex (case B_1), 38,XX

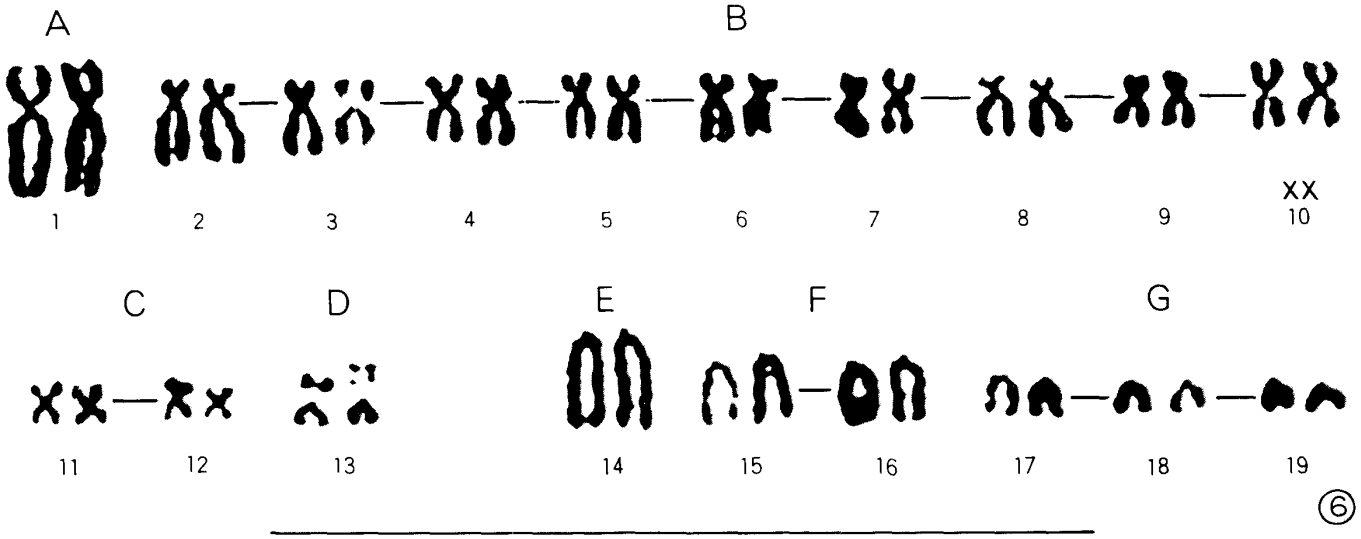
A
B
XX
1 2 3 4 5 6 7 8 9 10
C D E F G
11 12 13 14 15 16 17 18 19
⑥


XY
1 2 3 4 5 6 7 8 9 10
11 12 13 14 15 16 17 18 19
⑦


XX
1 2 3 4 5 6 7 8 9 10
11 12 13 14 15 16 17 18 19
⑧