Jap. J. vet. Res., **24**, 13~18 (1976)

EXPERIMENTAL STUDIES IN INTESTINAL HEALING OF THE DOG

I OBSERVATIONS ON SIDE-TO-SIDE SMALL INTESTINAL ANASTOMOSIS

Toshio KOIKE, Kanjuro OTOMO, Isao ABE
and Tamotsu SAKAI

Department of Veterinary Surgery
Faculty of Veterinary Medicine
Hokkaido University, Sapporo, Japan

(Received for publication, February 4, 1976)

The healing process of side-to-side intestinal anastomotic wounds, was studied in the jejunum and ileum of the dog. Gross, histologic, and angiographic observations were made. Inflammatory reaction, such as hemorrhage, edema, necrosis, and cell infiltration at the site of anastomosis disappeared around the 10th day after the operation. It appears, however, that the anastomotic wounds will heal after 30 to 40 days, in terms of other changes, such as the loss of the protrusion of intestinal wall, fall-off of the inner layer silk suture, completion of mucosal coverage on the defect, and revascularization at the anastomotic site.

INTRODUCTION

Intestinal anastomosis in man is a very common practice. The extensive studies on intestinal anastomosis have been done so far. However, the problems of post surgical complications, such as inadequate peristalsis, peritoneal adhesions, intestinal obstruction, and anastomotic disruption, have still been unsettled.

In domestic animals, the indication for this surgical operation is comparatively high only in the case of intestinal obstruction of the dog. This disease occurs most commonly in the small intestine, and therefore end-to-end intestinal anastomosis, if used the standard two-layer suture method, is likely to cause stenosis at the anastomotic site. For this reason, side-to-side anastomosis has been preferred for clinical use.

There also remains unsolved problems of secondary changes after side-to-side intestinal anastomosis, such as pouch formation at the closed end of the anastomosed intestine[4], anastomotic disruption of the above blind pouch, and the fate of the inner one of the two-layer sutures.

The purpose of this study is to describe the healing process of side-to-side intestinal anastomotic wound in the jejunum and ileum of the dog, with emphasis on the microangiographic changes.

MATERIALS AND METHODS

Forty clinically normal mongrel dogs, aging from 6 months to 3 years, were used in this study. For 12 hours preoperatively and 48 hours postoperatively, all food was withhold. The dogs were fed with a liquid diet on the 3rd day after the operation and then the diet was gradually changed to the normal diet within a week. All dogs received intramuscular injections of penicillin 200,000 I. U. on the day of operation and daily for 3 postoperative days.

The dogs were anesthetized intravenously with sodium pentobarbital, 25 mg per kg body weight. A midline incision was made in the abdomen and the intestine was transected 15 to 30 cm proximal to the ileocecal junction. A conventional two-layer inverting side-to-side anastomosis was used: the first row, posterior seromuscular suture, is a continuous Lembelt suture; the 2nd row, posterior through-and-through suture, is a continuous Albert suture and the 3rd, anterior Schmieden suture, is a continuation of the 2nd; and the 4th is a continuation of the first row around the anterior surface[6].

At intervals from 48 hours to 50 days, the animals were killed and immediately the descending aorta cannulated. After washing out with Ringer's solution, a roentogenological contrast medium (Bariton Sol, Dainihon Pharmaceutical Company, Japan) was injected into the cannulated vessel at physiological pressure of the dog. The segment of the intestine containing the anastomosis was resected and then fixed in 10 per cent formalin. After fixation, microangiograms of the anastomosis were made in both the longitudinal and the cross-sectional axes. For histological examination, 2 mm thick cross sections were embedded in paraffin, sectioned at 8 μ, and stained with haematoxylin-eosin.

RESULTS

Gross findings

The specimens taken from the anastomosis within 12~13 days after the operation, showed a marked intraluminal protrusion at the anastomotic line, and after 16~20 days this protruded tissue decreased in bulk rapidly. The inner silk suture was found sloughing off into the lumen of intestine in the specimens examined 12~13 days after the operation, and at 16~20 days it was no longer detectable in most specimens.

Histological findings (figs. 2~17)

For 3 days following the operation, there have been edema, necrosis, hemorrhage, and infiltration of inflammatory cells in the inverted tissue of the intestine, and after 3~4 days regeneration of the mucosa was seen. At 7 days,

the sections showed a mucosal coverage on the surface of the inverted tissue of anastomosed site, and inflammatory reaction subsided.

After 12~13 days, the inverted tissue, chiefly muscle layers, were separating at the level at which the inner silk suture was buried, so that granulation tissue was exposed to the intestinal lumen, with again a considerable degree of cell infiltration. On the 20th day, regeneration of the mucosa on the exposed granulation tissue reappeared, and at 30~40 days the anastomotic site consisted of a narrow connective tissue with complete mucosal integrity.

Serosal surfaces adhered firmly with granulation tissue by 3~7 days.

Angiographic findings (figs. 18~25)

In the longitudinal sections, an avascular area at the anastomotic line could not be identified in the first 3 days after the operation, as overlapping of tissues at the anastomosed site did occur. By about 8 days, the avascular area was present, and at about 16 days a number of new vessels regenerated from the main arteries along anastomotic line, were seen extending towards the clearly distinguished avascular area. After 30 days, and again after 60 days, vascularity in the avascular area was greatly increased.

In the cross sections, for 3 days after the operation, a zone of diminished vascularity was seen at the site of anastomosis, and there was a dilation of the vessels in the submucosa and a small area of an extravasation of the contrast medium which would seem to be bleeding. At about 8 days, newly formed vessels were generally seen at the anastomotic site, and after 16 days there were good vascular connections crossing the suture line in both the submucosa and the serosa. At this time, vascularity in the mucosa was scanty. Thirty to sixty day wounds showed a complete vascular regeneration in all layers of the intestinal wall.

Discussion

Reconstructing the severed organs or tissues and resuming their function, constitute a large part of surgery. The tissues involved are considered to be an important factor on healing, and this factor affects recovery of their function. The intestine composed of the mucosa, muscle, serosa, blood vessels, and secretory tissue in its thin wall, have complicated functions, such as digestion, absorption, transport of foods; therefore, the mechanism of intestinal healing becomes more complex. Much has been reported on intestinal anastomosis, but many problems still remain.

In man, end-to-end intestinal anastomosis has been routinely used, because of a relatively wide lumen of intestine. Consequently, in basic studies on intes-

tinal anastomosis for application to man, many investigators have generally used end-to-end anastomotic technique in the dog. However, in our veterinary field, side-to-side intestinal anastomosis has been commonly used in the dog, as the two-layer end-to-end anastomosis has a tendency to cause stenosis at the anastomotic site. Few studies on side-to-side intestinal anastomosis have been done, however.

This study dealt further with the wound healing of side-to-side intestinal anastomosis, using adult mongrel dogs, aging from 6 months to 3 years. In side-to-side anastomosis of the dog, the standard two-layer suture method recommended by many authors of textbooks for animal surgery, was adopted here[1~3,6,7,9,11].

ORR (1969) compared the two-layer and single-layer end-to-end intestinal anastomosis in the dog and observed that in the two-layer method, the inverted tissue within the inner suture became necrotic, sloughing away, and the regeneration of mucosa followed, while the single-layer method had less tissue damage on suturing and healed more rapidly than the two-layer method[10]. Similar change was found in our study of side-to-side anastomosis; the loss of the inverted intestinal wall occurred within 13 to 20 days after the operation.

SAKAI et al. (1957) showed that the two-layer suture in the stomach resulted in primary healing at about one week[11]. KITAJIMA (1973) reported that in the single-layer gastrointestinal anastomoses, 2 weeks passed before the wounds

FIGURE 1 *Summarized healing processes of side-to-side anastomotic wound*

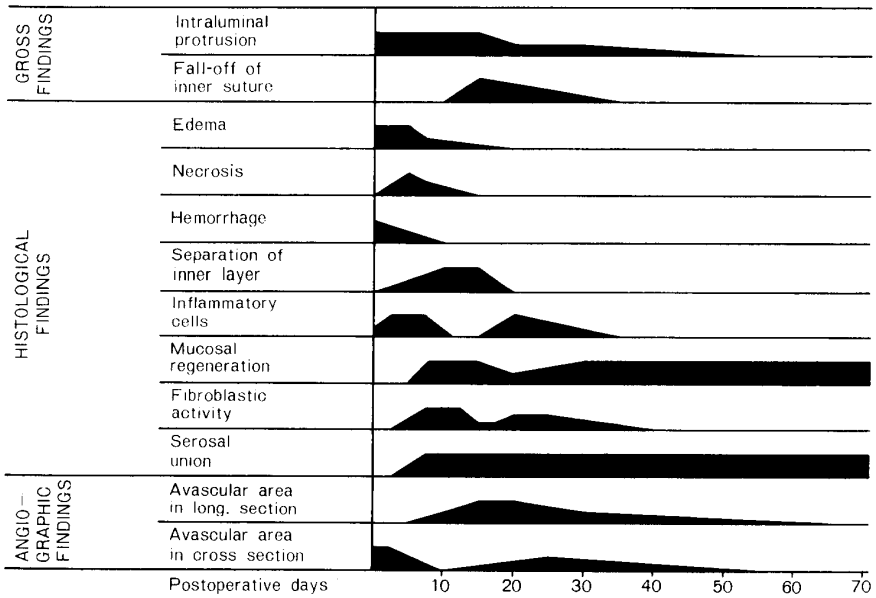

almost healed[5]. On the other hand, ORR could not demonstrate the capillary network across the anostomosis by 4 and 5 weeks postoperatively. MITO (1959) concluded that the anastomotic site showed the normal architecture of blood vessels of the intestine 8~12 weeks after the construction of anastomosis, although he clearly recognized the vascular contact between the submucous blood vessels on both sides by 2 and 3 weeks[8].

The results obtained in this study are summarized in figure 1. Edema, necrosis, hemorrhage, and cell infiltration at the anastomotic site disappeared around the 10th day after the operation. It appears, however, that the anastomotic wounds will heal completely after 30~40 days in terms of other changes, such as the loss of the protrusion of intestinal wall, fall-off of the inner silk suture, completion of mucosal coverage on the defect, and revascularization at the site of anastomosis.

REFERENCES

1) ANNIS, J. R. & ALLEN, A. R. (1967): An atlas of canine surgery, 88, Philadelphia: Lee and Febiger
2) ARCHIBALD, J. (1974): Canine surgery, 2ed, 599, California: American Veterinary Publications Inc.
3) BERGE, E. & WESTHUES, M. (1966): Veterinary operative surgery, 216, Copenhagen: Medical Book Company
4) HAYASHI, S., TAKEMAE, T., KURIBAYASHI, K., AKAU, S. & KOBAYASHI, S. (1971): *Geka Chiryo* (*Surg. Ther.*) **24**, 416 (in Japanese)
5) KITAJIMA, M. (1974): *Jap. J. Surg.*, **60**, 457 (in Japanese)
6) KUROSAWA, R. & SAKAI, T. (1873): Veterinary surgical therapeutic technics, 6ed, 110, Tokyo: Yokendo (in Japanese)
7) LEONARD, E. P. (1968): Fundamentals of small animal surgery, 199, Philadelphia: W. B. Saunders Company
8) MITO, Y. (1959): (translated title) Studies on blood supply of gastrointestinal anastomotic wounds (Diss., Sapporo, in Japanese)
9) ORMROD, A. N. (1966): Surgery of the dog and cat, 44, London: Bailliere, Tindall and Cassell
10) ORR, N. W. M. (1969): *Br. J. Surg.*, **56**, 771
11) SAKAI, T., KOIKE, T., MATSUHASHI, A. & OTOMO, K. (1957): *J. Jap. vet. med. Ass.*, **10**, 137 (in Japanese)
12) TAKIYAMA, I. (1964): *Jui-chikusan Shinpo* (*J. vet. Med.*), (379) 791 (in Japanese)

Explanation of plates

Plate I Histological findings of anastomoses
Hematoxylin and eosin

Figs. 2~7 Cross sections taken from the site of Albert-Lembelt suture ×3

Figs. 8~13 Cross sections taken from the site of Schmieden-Lembelt suture ×3

Figs. 2 & 8, 3 & 9, 4 & 10, 5 & 11, 6 & 12, 7 & 13 taken 2, 8, 16, 22, 50, 127 days after the operation respectively

Fig. 14 Cell infiltration in the muscularis at 2 days ×260

Fig. 15 Onset of separation of inner layer at 9 days ×260

Fig. 16 New granulation tissue exposed to the intestinal lumen at 13 days ×260

Fig. 17 Complete healing at 68 days ×260

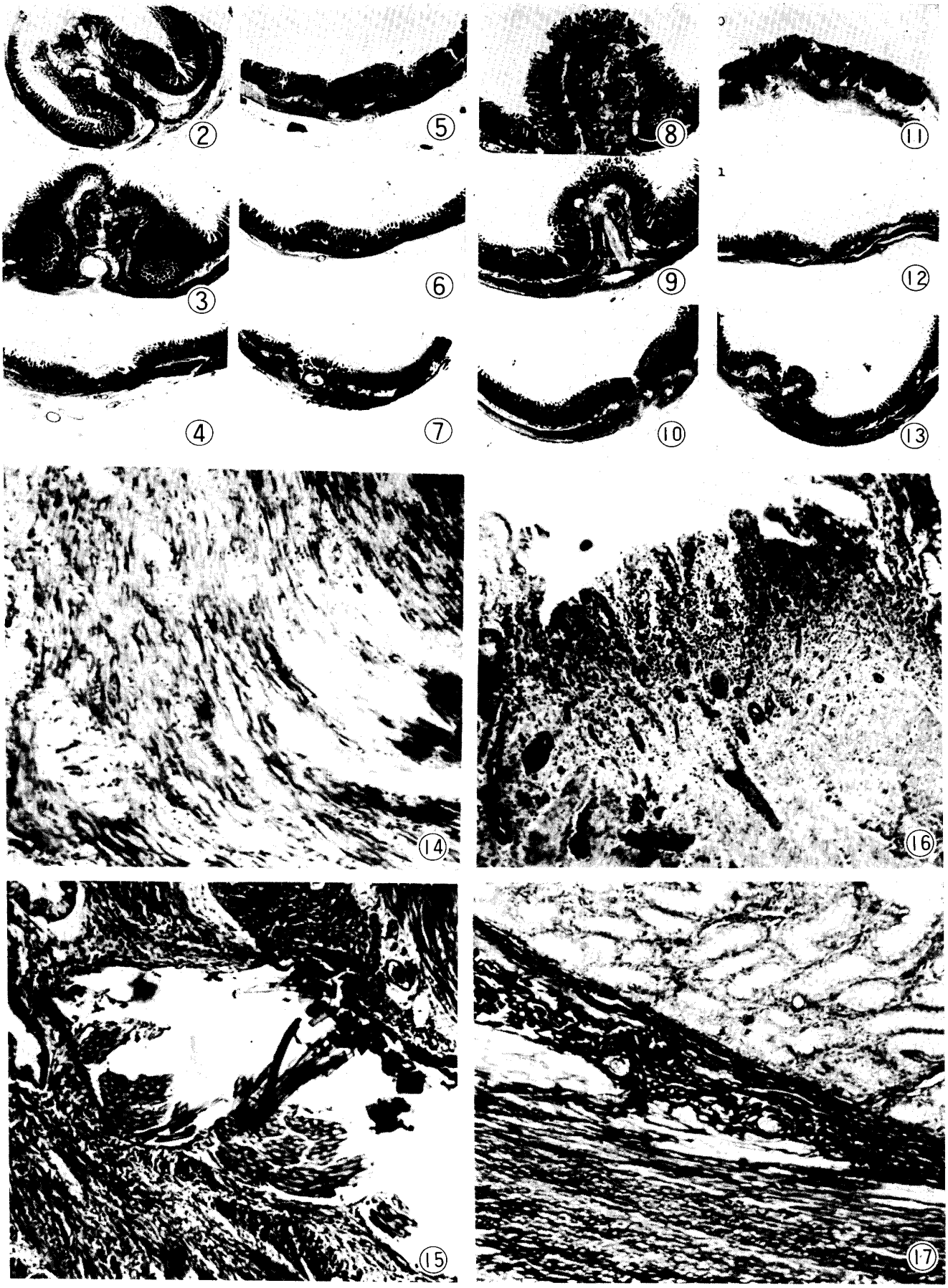
2
5
8
11
3
6
9
12
4
7
10
13
14
16
15
17

PLATE II Angiographic findings of anastomoses

Figs. 18~21 Longitudinal section ×3.0

Figs. 22~25 Cross section ×5.2

Figs. 18 & 22, 19 & 23, 20 & 24, 21, 25 taken 3, 8, 16, 30, 60 days after the operation respectively


18


22


19


23


20


24


21


25