Jap. J. vet. Res., **24**, 19~24 (1976)

EXPERIMENTAL STUDIES IN INTESTINAL HEALING OF THE DOG

II OBSERVATION ON END-TO-END SMALL INTESTINAL ANASTOMOSIS

Toshio KOIKE, Mitsuyoshi HAGIO, Tadaaki KUDO and Tamotsu SAKAI

Department of Veterinary Surgery
Faculty of Veterinary Medicine
Hokkaido University, Sapporo, Japan

(Received for publication, February 4, 1976)

Wound healing of end-to-end small intestinal anastomosis was studied and compared with previously reported data on side-to-side small intestinal anastomotic wound. The healing process of end-to-end anastomosis was basically similar to that of side-to-side anastomosis. However, an increase in vascularity at the anastomotic site is less severe and mucosal regeneration on the defect is more delayed in end-to-end anastomosis than those in side-to-side anastomosis.

INTRODUCTION

Side-to-side anastomosis is most commonly used for intestinal anastomosis in the dog[10]. However, in man, many investigators have pointed out that the risk of creating a blind pouch at the closed end after side-to-side anastomosis which causes so-called blind loop syndrome, is occasionally present[5]. Moreover, it has been commonly believed that the transport of the intestinal contents following end-to-end anastomosis results in more physiological condition than that following side-to-side anastomosis.

Therefore, in the present study, the wound healing of the conventional two-layer end-to-end intestinal anastomosis was examined in the dog, with special reference to microangiographic findings.

MATERIALS AND METHODS

Thirty-five dogs to be used were clinically normal mongrel dogs, aging from 6 months to 3 years. The pre- and postsurgical treatment and surgical technique were described in the previous publication[9].

A standard method of end-to-end intestinal anastomosis was performed in all the dogs, namely, two-layer inversion using a continuous Albert suture for the inner layer and a continuous Cushing suture for the outer layer.

Animals were killed at intervals from 48 hours to 127 days. Details of the

procedures for angiographic and histological assessments have been provided in the previous report[9]. In addition, in order to demonstrate the vascular communication across ths anastomotic line from both sides, the mesenteric vessels were occluded in some cases, so that the intestine on one side of the anastomosis could be separately injected arterially with the contrast medium.

RESULTS

Gross findings

A marked intraluminal protrusion of intestinal wall at the anastomotic site, was seen for 5~7 days after the operation. The protrusion then gradually decreased in bulk, and after 15~20 days of operation the anastomotic site became almost flat with a partial protrusion.

In two cases in which the proximal intestine was found to be distended, a lumen narrowing at the site of anastomosis was great.

The inner silk suture began to slough off into the lumen from about the 5th day following the operation, being not recognizable in approximately half of the specimens taken at 10~15 days and in most specimens at 20~30 days.

Histological findings (figs. 1~5)

Hemorrhage, edema, necrosis, and cellular infiltration in the mucosa, submucosa, and muscularis were noted at the anastomotic site and its vicinity for 3 days after the operation. By the 5th day, regeneration of the mucosa occurred, and by the 7th day there was good coverage on the anastomotic defect with intestinal mucosa in some cases. Most specimen showed complete mucosal union by the 15th day. In the specimens examined on the 50th day, the villi in the area of anastomosis was shorter than those of the adjacent healthy mucosa. Cell infiltration was confined to the neighboring area of

FIGURE 1 *Summary of histological findings*

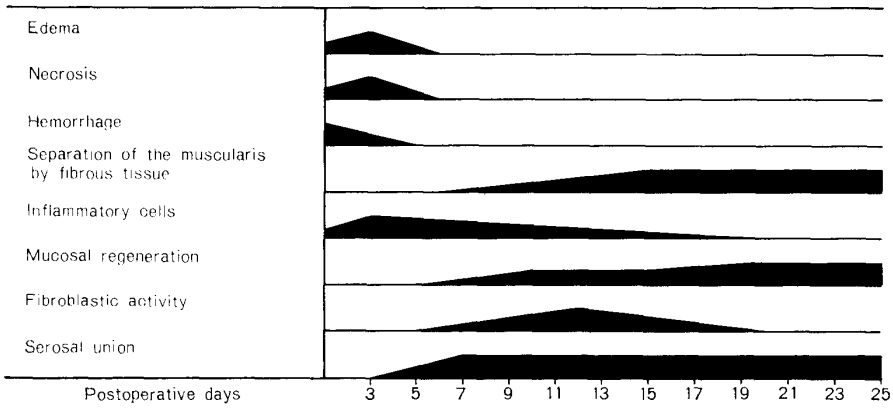

the suture at about 10 days, where the infiltration persisted for about 20 days postoperatively.

The granulation tissue bridging the muscle layers of the both sides of anastomosis, has become wide since about 7th day, and it was replaced by fibrous connective tissue within 15~20 days.

The union of the serosal surfaces with granulation tissue, was nearly completed within 3~7 days.

Angiographic findings (figs. 6~21)

In the longitudinal sections, microangiograms showed an avascular area at the anastomotic line in the first 3 to 5 days. After 7 days, vasodilation on the angiograms along the anastomotic line was seen, and minute blood vessels regenerated from this dilated vessels were extending towards the suture line. There was clear evidence of vascular contacts across the suture line after 15 days.

Cross sections taken for 3 to 5 days showed an avascular area at the anastomotic line as well as the longitudinal sections. Only a few minute blood vessels were seen extending towards this avascular area after 7~10 days, and after 15 days there were good vascular contacts between the submucosal vessels on both sides.

In some cases in which the intestine on one side of the anastomosis was separately injected with contrast medium, crossover of the injected material was no demonstrable until the 5th day. It was barely demonstrable by the 10th day, from which it gradually became clear. By the 20th day, the angiographic findings at the anastomotic site were almost the same as those at the normal site of the intestine which received the same angiographic procedures.

Discussion

End-to-end intestinal anastomosis was very commonly used in man, from the standpoint of the nature of intestinal movement and of prevention of the blind loop syndrome after side-to-side anastomosis; therefore, many experimental studies of end-to-end anastomosis using the dog have been reported[4]. In recent years, the single-layer inverting[1,2,7] and everting[3,6] end-to-end techniques have been investigated for avoiding the great narrowing of the intestinal lumen usually formed by the standard two-layer end-to-end anastomosis, but the weight of opinions has yet remained in favor of the standard two-layer method.[6,10]

For purposes of comparison with the previously described side-to-side intestinal anastomosis, wound healing after the standard two-layer end-to-end anastomosis in the same conditioned dogs was studied in the jejunum and

ileum.

Grossly and histologically, our observations were similar to those reported by SAKAI et al. (1957) and KITAJIMA (1973). Unlike the side-to-side anastomosis[9], however, in this study there was no histologic evidence that the inverted tissue within the inner silk suture sloughed away and then the anastomotic site became flat. It is considered that the disappearance of the inverted tissue created is due, in part, to gradual streching of the anastomosed site by the intestinal movement.

By microangiography, KITAJIMA observed that the vascular communication across the anastomotic line was identified at 7 days after the operation. This does not agree with our results in which vascular contacts crossing the line of anastomosis was nearly established after 10～15 days. The fact that in end-to-end anastomosis, the vessels on the intestinal wall run mainly parallel to the anastomotic line, may be a cause of delay in revascularization at the anastomotic site.

Actually, in the cases in which the marginal vessels and the mesenteric vessels suppling the portion of anastomosis were ligated, the angiographic findings of the anastomosed site were same as those of the healthy intestine receiving the same angiographic procedures by the 20th day.

The differences between the side-to-side anastomosis described previously[9] and the end-to-end anastomosis described herein, were :

1) On the microangiographic findings, unlike the side-to-side intestinal anastomosis, a remarkable increase in vascularity along the anastomotic line was not recognized in the end-to-end anastomosis. The dilation of the vessels running parallel to the anastomotic line and regeneration of the minute blood vessels from this dilated vessels were characteristic of the end-to-end anastomosis.

2) Regeneration of the mucosa was faster in the side-to-side anastomosis than in the end-to-end anastomosis. There was no evidence of fall-off of the inner layer into the lumen in the end-to-end anastomosis.

3) The regenerated villi at the anastomotic site were shorter than those of the adjacent healthy mucosa in the end-to-end anastomosis.

4) With the end-to-end anastomosis, the connective tissue bridging the muscularis of both sides of anastomosis has become wide as time progressed.

Those may be attributed to the difference of the blood supply to the anastomosed area, the direction of intestinal movement against the joined area, and the amount of inverted tissue at the anastomotic site by each method.

REFERENCES

1) ARCHIBALD, J. (1974): Canine surgery, 2ed, 594, California: American Veterinary Publications, Inc.
2) BENNETT, R. R. & ZYDECK, F. A. (1970): *J. Am. vet. Ass.*, **157**, 2075
3) GILL, W., FRASER, S. J., CARTER, D. C. & HILL, R. (1969): *Surgery Gynec. Obstet.*, **128**, 1297
4) JINNAI, D. & MURAI, S. (1973): *Geka, (Surg.)*, **34**, 1200 (in Japanese)
5) HAYASHI, S., TAKEMAE, T., KURIBAYASHI, K., AKAU, S. & KOBAYASHI, S. (1971): *Geka Chiryo (Surg. Ther.)*, **24**, 416 (in Japanese)
6) HOFFER, R. E. & JENSEN, H. E. (1973): Stereoscopic atlas of small animal surgery, 91, Saint Louis: The C. V. Mosby Company
7) IRVIN, T. T., GOIIGHER, J. C. & JOHNSTON, D. (1973): *Br. J. Surg.*, **60**, 457
8) KITAJIMA, M. (1974): *Jap. J. Surg.*, **60**, 457 (in Japanese)
9) KOIKE, T., OTOMO, K., ABE, I. & SAKAI, T. (1976): *Jap. J. vet. Res.*, **24**, 13
10) KUROSAWA, R. & SAKAI, T. (1973): Veterinary surgical therapeutic technics, 6ed, 110, Tokyo: Yokendo (in Japanese)
11) SAKAI, T., KOIKE, T., MATSUHASHI, A. & OTOMO, K. (1957): *J. Jap. vet. med. Ass.*, **10**, 137 (in Japanese)

Explanation of plates

Plate I Histological findings of anastomoses Hematoxylin and eosin

Fig. 2 Mucosal union with a layer of epithelium at 7 days after the operation ×240

Fig. 3 Fibrous union of serosal surface and contact between the omentum and serosa at 10 days ×240

Fig. 4 Newly formed mucosa at 15 days ×96

Fig. 5 Regenerated villi being still shorter than the adjacent healthy ones at 50 days ×96

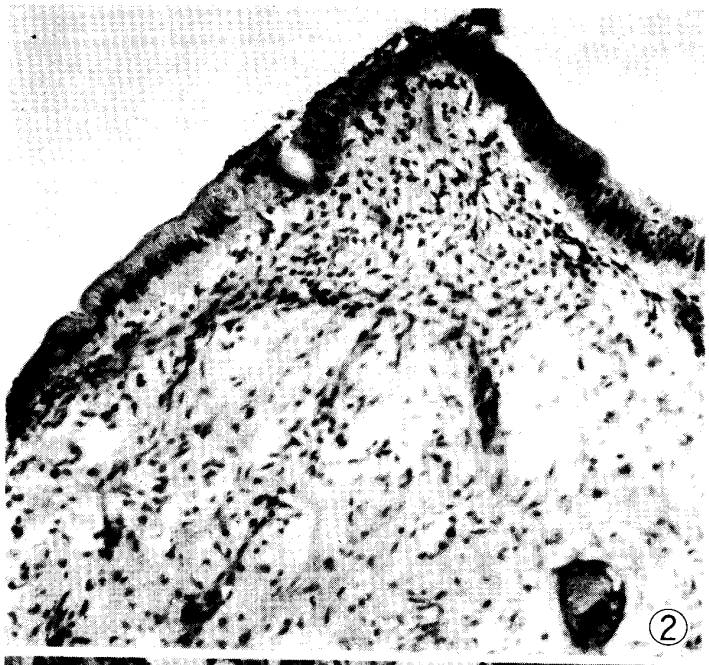
②


④


③

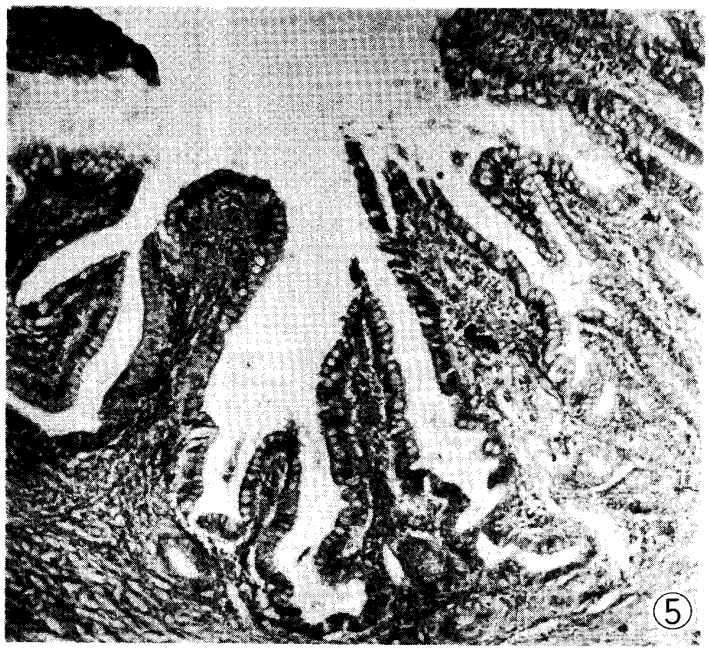
⑤

PLATE II Angiographic findings of anastomoses

Figs. 6～ 9 Longitudinal section ×3.0

Figs. 10～13 Cross section ×4.5

First row 3 days, second 7 days, third 15 days and forth 50 days

6

10

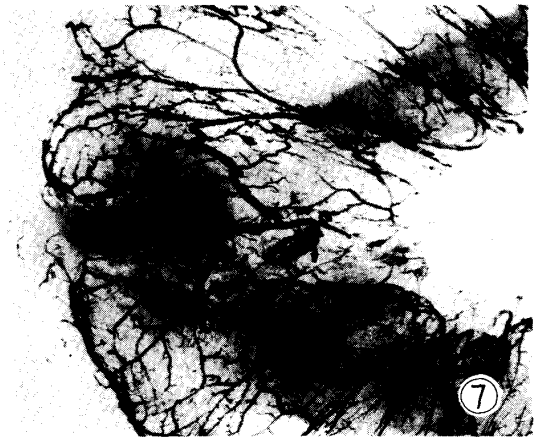

7

11

8

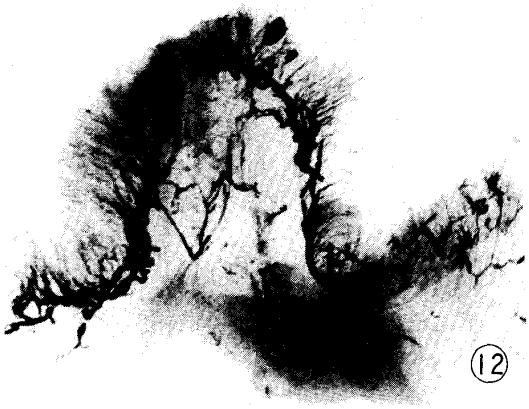

12

9



13

PLATE III Angiographic findings of anastomoses. Specimens were obtained from the cases in which the intestine of one side of the anastomosis was separately injected with contrast medium

Figs. 14~17 Longitudinal section ×3.0

Figs. 18~21 Cross section ×4.5

First row 5 days, second 10 days, third 15 days, and forth 20 days


14

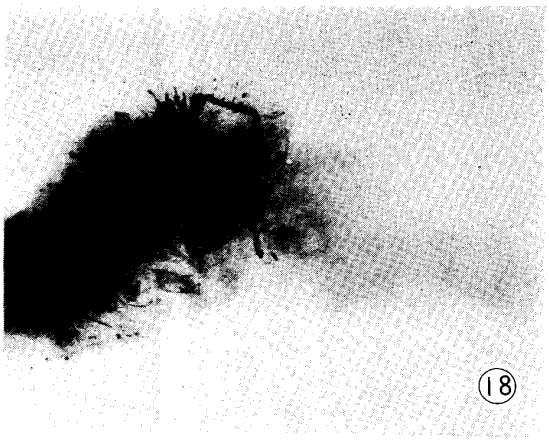
18


15

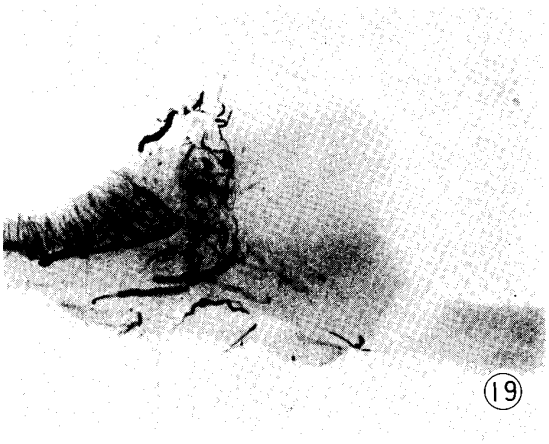
19


16


20

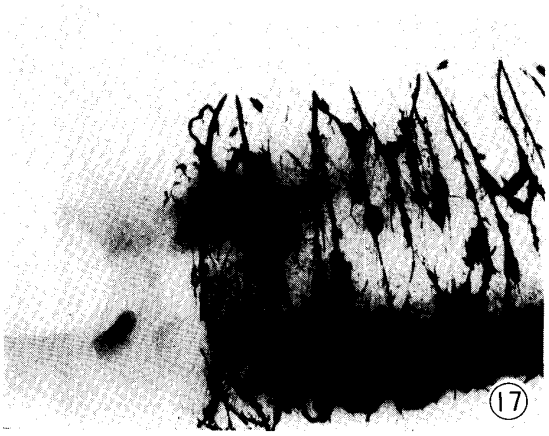
17


21