Jap. J. vet. Res., **24**, 77~86 (1976)

SEGMENTATION OF THE RAT OVIDUCT

Jae-Hyun LEE, Makoto SUGIMURA and Norio KUDO
Department of Veterinary Anatomy
Faculty of Veterinary Medicine
Hokkaido University, Sapporo, Japan

(Received for publication, May 17, 1976)

The histological observation was carried out by extending the whole length of rat oviducts. Eight distinguishable types of epithelial cells were seen depending on the morphology and stainability. According to the distribution of these cells, the oviduct could be divided into five segments. The length of each segment varied during the sexual cycle.

INTRODUCTION

Segmentation of the mammalian oviduct was described in the mouse by AGDUHR ('27), and in the rat by ALDEN ('42) and KELLOGG ('45). NILSSON & REINIUS ('69) described it mainly in the mouse and the rat. They divided the oviduct into several segments by the size of the folds, the morphology of the epithelial cells and muscular layers, but not by the detailed cell types.

In addition, the differences in the number and character of the epithelial cells of the mammalian oviduct depending on the species, the sampling portion, and the sexual cycle have been described by SCHAFFER ('08) and BRENNER ('67); however the relationship between the traditionally nominated segments and the types of the association of the epithelial cells is not yet clear. Moreover, even in the same species and by the same methods, different results were reported by investigators (ALDEN, '42 ; BORELL et al., '59 ; DEANE, '52 ; ODOR, '53 ; SCHAFFER, '08).

In order to know the morphology and the function of the rat oviduct, it seems necessary to clarify in detail the oviductal segmentation from the basic point of cell types and their distribution. Segmentation may contribute to a deeper understanding of the structure and function of the rat oviduct.

In the first step toward the systematic study of the rat oviduct, each of the segments was investigated along the entire length of the extended oviducts by the light microscope.

MATERIALS AND METHODS

Albino rats of the Wistar strain were used for the experiment. Virgin females aged 3 to 5 months (150~200 g B. W.), were placed in a constant

environment of 14 hours of artificial light and 10 hours of darkness (ISHIBASHI et al., '70). During two or three weeks, their sexual cycles were examined daily by vaginal smear within two hours after the darkness began. Among the animals which had four normal cycles, five rats in each stage were sacrificed by chloroform anesthesia.

The oviducts were dissected out and trimmed free of the mesometrial fat, and then placed in a physiological saline solution under the stereo-microscope. The oviducts were extended into their full lengths, pinned with sealant (Aron Alpha) on slide glasses, and immediately fixed in Zenker's or formalin fixative agent for 12~24 hours. After the fixation, the tissues were prepared by a routine method for paraffin embedding. Serial sections were conducted at 6 to 8 μ along the course of the extended oviducts (fig. 1).

Hematoxylin-eosin, PAS-hematoxylin, alcian blue (pH 2.6)-hematoxylin, PAS-alcian blue-hematoxylin, and toluidine blue stains were used.

RESULTS

I Cell types of the oviductal epithelium

According to the stainability of the PAS-hematoxylin stain and other morphological characteristics, the epithelial cells of the rat oviduct were

TABLE 1 *Cell distribution and cell type in each segment of the rat oviduct*

CELL TYPE	SEGMENT					
	I	II	III	IV	V IM	V EM
C. C	+++	++	++	+	−	−
L. C. C	++	+	−	−	−	−
J. C	−	−	−	−	++	++
PAS ±~+	−	+	−	−	++	−
AP. PAS ±~+	−	++	+	−	−	+
PAS ++	−	−	++	+++	−	−
PE −	+	+	−	−	−	−
PE+	−	−	−	−	+	−

C. C: Ciliated cell L. C. C: Light ciliated cell
J. C: Junctra cell PAS ++: PAS strongly positive cell
PAS ±~+: PAS slightly positive cell
AP. PAS ±~+: PAS slightly positive apocrine-like cell
PE+: PAS positive peg cell PE−: PAS negative peg cell
IM: Intramural part EM: Extramural part
+++: Numerous ++: Moderate +: Slight −: Absent

classified into eight types as follows: (tab. 1).

1) Ciliated cell (C. C.) was PAS negative, and had cilia. The cell was cubical in shape. The cytoplasm was pale in staining. The nucleus was large, round, or oval in shape (fig. 2).

2) Light ciliated cell (L. C. C.) was PAS negative and cubical to columnar. The cytoplasm was similar to the C. C. but much paler. The nucleus was round or elliptical (fig. 2).

3) Junctra cell (J. C.) was cubical or columnar and PAS slightly positive on the cell surface. No cilia were found on the cell surface. The cytoplasm was very pale and the nucleus was oval or elliptical. The cells frequently formed tubular gland-like structures (figs. 8 & 9). We named it the junctra cell because of its location only in the junctral portion.

4) PAS slightly positive cell (PAS±~+) was columnar and PAS slightly positive in the cytoplasm. Microvilli were found. The nucleus was oval or elliptical and located in the apical portion of the cytoplasm (fig. 6).

5) PAS slightly positive apocrine-like cell (AP. PAS±~+) had apocrine-like structures on the cell free surface. The small PAS positive granules were found in the cytoplasm, especially in the apical portion. Microvilli were found on the cell surface. The nucleus was oval or round and was found usually at the side of the basement membrane (fig. 4). Nuclear protruding was found frequently.

6) PAS strongly positive cell (PAS++) had numerous PAS positive granules in the apical portion of the cytoplasm. This cell also had long microvilli and much PAS positive secretory substances attached to the microvilli. The cell was cuboidal or columnar and the nucleus was oval or elliptical. These cells were found mainly in the covering epithelium of the folds (fig. 7).

7) PAS negative peg cell (PE−) was PAS negative and rod-like or columnar in shape. The nucleus was found in the apical portion of the cytoplasm, and it protruded frequently. This cell corresponded to the so-called peg cell or intercallary cell (fig. 2).

8) PAS positive peg cell (PE+) was the same as the PE− in shape but was PAS positive (fig. 9).

A cyst-like structure was found in segments I and II, as described below

II Segmentation of the rat oviduct

According to the distribution of the above-mentioned epithelial cells as shown in table 1, the rat oviduct can be distinguished into five segments (fig. 1) as follows:

1) Segment I: This segment included the proximal portion of the

preampulla and fimbria. The epithelium of segment I was characterized as having a great number of C.C. or L.C.C.. A few PE− and cyst-like structures were also found. This segment consisted almost entirely of PAS negative cells (figs. 2 & 3).

2) Segment II: This segment included the main portion of the ampulla. This segment was characterized by the presence of numerous AP. PAS±~+. A few PE− also appeared. The epithelium consisted mainly of the C. C. and AP. PAS±~+. Cyst-like structures were also found (figs. 4 & 5).

3) Segment III: This segment included the distal portion of the ampulla and the proximal part of the isthmus. A few PAS++ and AP. PAS±~+ were noted. The C. C. decreased in number (fig. 6).

4) Segment IV: This segment occupied the main portion of the isthmus. The epithelium of this segment consisted of numerous PAS++ which were strongly PAS positive on the cell surface and in the apical portion of the cytoplasm. A few C. C. were found at the bottom between the folds (fig. 7).

5) Segment V: This segment was unique in the appearance of J. C. and included the junctra portion and the distal part of the isthmus. Both the intramural and extramural parts were seen. The J. C., PAS±~+, PE+ and tubular gland-like structures characterized this segment. The J. C. and PAS±~+ were found in moderate amounts; only a few PE+ cells could be found in the intramural part, while the AP. PAS±~+ cells were found in the extramural part (figs. 8 & 9).

III Relative length of each segment during sexual cycle

The relative length of each segment of the rat oviduct varied during the sexual cycle. The percentages are listed in table 2.

In segment I, there were no significant differences among the 4 stages. Segment II was much longer in the proestrus than in the diestrus and the metestrus. Segment III was longest in the proestrus and shortest in the metestrus. Segment IV was longer in the diestrus and the metestrus than in other two stages. Segment V was significantly longer in the estrus and the metestrus than in the proestrus and the diestrus.

DISCUSSION

It is well known that the oviducts of adult animals have highly specialized structures, and that during the reproductive period, the organs assume one of the most basic roles in the reproductive process by receiving the ovum, providing the appropriate environment for its fertilization and transporting the fertilized ovum to the uterus (NILSSON & REINIUS, '69; BLOOM & FAWCETT, '75).

TABLE 2 *Relative length of each segment of rat oviduct in sexual cycle*

SEGMEMT	STAGE OF SEXUAL CYCLE			
	Proestrus (5)	Estrus (5)	Metestrus (5)	Diestrus (5)
I	13.9 ± 2.1	13.8 ± 4.3	16.1 ± 1.6	17.4 ± 3.4
II	18.0 ± 3.1	14.0 ± 5.5	11.5 ± 0.6	9.6 ± 2.3
III	14.8 ± 0.9	12.0 ± 2.1	8.5 ± 0.8	11.1 ± 1.4
IV	39.7 ± 2.5	42.9 ± 4.1	48.0 ± 1.5	48.1 ± 3.6
V	13.6 ± 1.8	17.3 ± 1.4	16.6 ± 0.5	13.8 ± 1.0

( ): Number of examined rats

Numeral shows mean ± standard deviation (%).

t-test for pair comparison

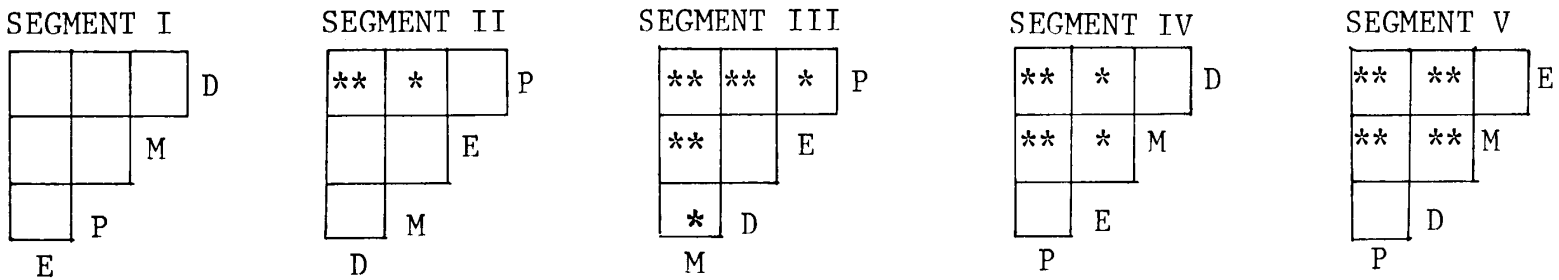

Remarks. **: P<0.01 *: P<0.05

P: proestrus E: estrus M: metestrus D: diestrus

There are a number of morphological studies on the mammalian oviduct: (AGDUHR, '27; ALLEN, '22; AUGUSTIN & MOSER, '55; BJÖRKMAN & FREDRICSSON, '61, '62; BRENNER et al., '68; FAWCETT & WISLOCKI, '50; FROMMEL, 1886; HADEK, '55; LOMBARD et al., '50; LJUNKVIST, '67; NAYAK & ELLINGTON, '72; NILSSON & REINIUS '69; RESTALL, '66; SCHAFFER, '08; SCHULTKA, '63), and a few reports regarding the rat oviducts (BORELL et al., '59; BRENNER, '69; DEANE, '52; ODOR, '53; SCHAFFER, '08). In the epithelial cells of the rat oviduct, only four types of cells, ciliated and secretory cells (BORELL et al., '59), rod-like or peg cells and basal cells (BRENNER, '69) are reported.

According to the present investigation conducted with PAS-hematoxylin staining, however, the oviductal epithelium of the rat can be distinguished into eight types of cells (tab. 1). Among them, the C. C. and L. C. C. may correspond to the ciliated cells and the basal bells, and the PAS++, PAS±~+ and AP. PAS±~+ to the secretory cells, whereas PE− and PE+ may correspond to the peg cells reported by BORELL et al. ('59) and BRENNER ('69). Up to now, however, no description of the J. C. and tubular gland-like structures has been available.

With regard to segmentation of the oviduct, AGDUHR ('27) reported on the mouse, ALDEN ('42) and KELLOGG ('45) on the rat, and NILSSON & REINIUS ('69) on the rat and other species. According to AGDUHR ('27), the mouse's oviduct was divided into seven segments, a, b, c, d, e, f and g, owing to the morphology of the epithelial folds and epithelia. On the other hand, ALDEN ('42) divided the rat oviduct into five segments relating to the epithelium, cephalic ampulla, caudal ampulla, transition to the isthmus, isthmus, and caudal isthmus. KELLOGG ('45) also divided the rat oviduct mainly into four segments depending on the character of all the layers comprising the oviduct wall.

On the other hand, we distinguished the whole length of the rat oviduct into five segments, I, II, III, IV and V starting from the ovarian side, depending on the distribution of different cell types and their morphological characters.

Segment I consists mostly of ciliated cells, which accords with the description by DEANE ('52). This segment corresponds to the proximal portion of the preampulla and fimbria described by NILSSON & REINIUS ('69) and to the segment g in the mouse reported by AGDUHR ('27). AGDUHR ('27) found a great number of the so-called club-cells and also squeezed-up cells in this area in the mouse oviduct, whereas we could find out only a few PE−. The cyst-like structure was also observed among the C. C..

Segment II consists of numerous AP. PAS±~+, while ODOR ('53) reported that there were mostly ciliated cells in the ampulla and isthmus of the rat oviductal epithelium. This segment corresponds to the main portion of the

ampulla and preampulla described by NILSSON & REINIUS ('69), and to segments e and f found in the mouse by AGDUHR ('27).

Segment III consists of the C. C. and PAS++ in the same ratio and a few AP. PAS±~+. This segment corresponds to the distal part of the ampulla and the proximal part of the isthmus found by NILSSON & REINIUS ('69). It may also correspond to the segment d in the mouse described by AGDUHR ('27).

Segment IV consists of numerous PAS++, and corresponds to the isthmus indicated by NILSSON & REINIUS ('69) and to the segment c in the mouse described by AGDUHR ('27). AGDUHR ('27) found numerous intraepithelial crypts and a balloon-secretion. We could not find such balloon-secretions in this area. The C. C. was found at the bottom between the folds. The ratio of C. C. and L. C. C. accords well with that found by NILSSON & REINIUS ('69).

Finally, segment V corresponds to the junctra found by NILSSON & REINIUS ('69) and also the segments a and b described in the mouse oviduct by AGDUHR ('27). NILSSON & REINIUS ('69) reported that the junctra included both the intramural and extramural parts, while the epithelium consisted of only the nonciliated cells. The balloon-secretion (AP. PAS±~+) mentioned by AGDUHR ('27) was also found in the extramural part in our observations. It is very interesting to notice that the J. C. appears and forms tubular gland-like structures in this segment, whose function and morphology have not yet been reported.

AUGUSTIN & MOSER ('55) reported on the rat oviduct that the alkaline phosphatase activities of the junctra segment were minimal in the diestrus, and reached a maximum in the estrus and metestrus. The present writers found that the length of segment V mainly occuping the junctra becomes minimal in the proestrus and diestrus, and reaches to a maximum length in the estrus and the metestrus. A relationship between the changes in length of this segment and the alkaline phosphatase activity is not yet examined, but it is assumed that there may be one between them.

In the text-figure, a comparison is made between the present writers' segments and the corresponding ones presented by NILSSON & REINIUS ('69), as the left and right histograms, respectively, for each stage of the sexual cycle (text-fig.).

According to the above-mentioned investigation, we may conclude that, firstly, the range of each segment does not always accord with the traditionally named regions, junctra, isthmus, ampulla and preampulla regions, and secondly, that the length of each segment changes during the sexual cycle. It means that the distribution of cells also changes.

In order to understand the morphological and functional changes of the

TEXT-FIGURE *Segmentation of rat oviduct*

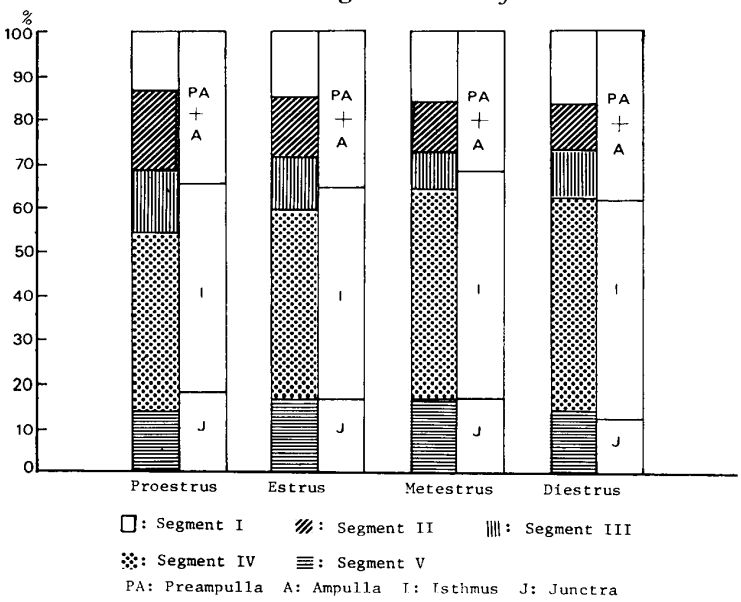

oviductal epithelium during the sexual cycle and to solve the still-existing confusions of their traditionally assigned roles, it will be necessary to make a precise sampling of these five segments.

REFERENCES

1) AGDUHR, E. (1927): *Acta zool.*, **8**, 1
2) ALDEN, R. (1942): *Anat. Rec.*, **84**, 137
3) ALLEN, E. (1922): *Am. J. Anat.* **30**, 297
4) AUGUSTIN, E. & MOSER, A. (1955): *Arch. Gynaek.*, **185**, 759
5) BJÖRKMAN, N. & FREDRICSSON, B. (1961): *Z. Zellforsch. mikrosk. Anat.*, **55**, 500
6) BJÖRKMAN, N. & FREDRICSSON, B. (1962): *Int. J. Fert.*, **7**, 259
7) BLOOM, W. & FAWCETT, D. W. (1975): A textbook of histology, 10 ed. 880, Philadelphia, London, Toronto: W. B. Saunders
8) BORELL, U., GUSTAVSSON, K. H., NILSSON, O. & WESTMAN, A. (1959): *Acta obstet. gynec. scand.*, **38**, 203
9) BRENNER, R. M. (1967): *J. Cell Biol.*, **35**, 16 A
10) BRENNER, R. M. (1969): *Fert. Steril.*, **20**, 599
11) BRENNER, R. M., ANDERSON, R. G. W. & KAMM, M. J. (1968): *J. Cell Biol.*, **39**, 16 A
12) DEANE, H. W. (1952): *Am. J. Anat.*, **91**, 363
13) FAWCETT, D. W. & WISLOCKI, G. B. (1950): *J. natn. Cancer Inst.*, **12**, 213
14) FROMMEL, R. (1886): *Arch. Gynaek.*, **28**, 458
15) HADEK, R. (1955): *Anat. Rec.*, **121**, 187
16) ISHIBASHI, I., TANAKA, H. & TAKAHASHI, K. (1970): *Jap. J. Anim. Reprod.*, **16**,

14 (in Japanese with English summary)
17) KELLOGG, M. (1945): *Anat. Rec.*, **93**, 377
18) LJUNKVIST, H. I. (1967): *Acta endocr.*, **56**, 391
19) LOMBARD, L., MORGAN, B. B. & MENUTT, S. H. (1950): *J. Morph.*, **86**, 1
20) NAYAK, R. K. & ELLINGTON, E. F. (1972): *J. Anim. Sci.*, **35**, 250
21) NILSSON, O. & REINIUS, S. (1969): "Light and electron microscopic structure of the oviduct", The mammalian oviduct Ed. HAFEZ, E. S. E. & BLANDAU, R. J., 1 ed. 57, Chicago and London: Univ. of Chicago Press
22) ODOR, D. L. (1953): *Anat. Rec.*, **115**, 434
23) RESTALL, B. J. (1966): *Aust. J. biol. Sci.*, **19**, 673
24) SCHAFFER, J. (1908): *Mschr. Geburtsh. Gynäk.*, **28**, 526
25) SCHULTKA, R. (1963): *Acta histochem.*, **15**, 285

Explanation of plates

Plate I

Fig. 1 Whole section of extended rat oviduct

Fig. 2 Segment I in the diestrus
Numerous C.C. and L.C.C. are observed; a few PE- and vacuoles are also found.
PAS-hematoxylin × 440

Fig. 3 Segment I in the diestrus
Numerous C.C. are found.
PAS-hematoxylin × 440



UTERUS	JUNCTRA IM | EM	ISTHMUS		AMPULLA + PREAMPULLA	
	SEG. V	SEG. IV	SEG. III	SEG. II	SEG. I

IM: Intramural part
EM: Extramural part
SEG: Segment

①

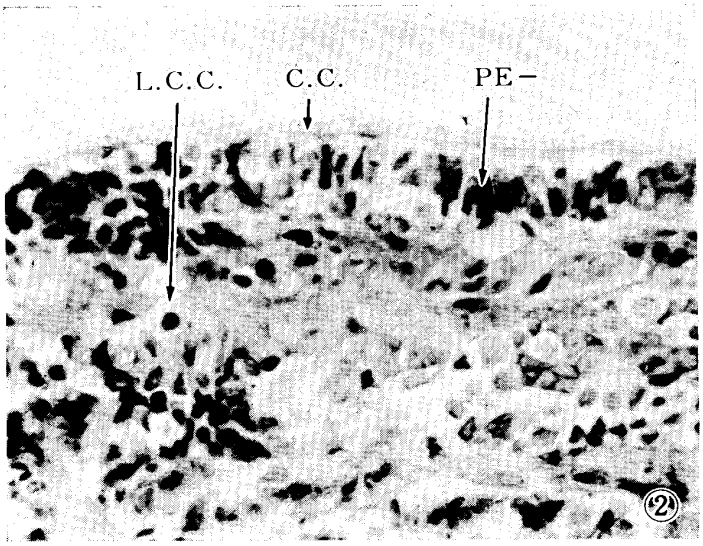

②

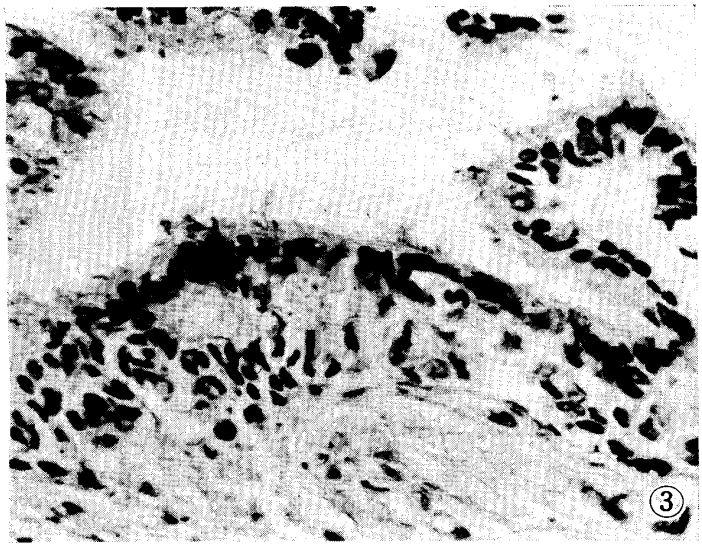

③

PLATE II

Fig. 4 Segment II in the metestrus
Numerous AP. PAS ± ~ + are observed.
PAS-hematoxylin × 440

Fig. 5 Segment II in the metestrus
Numerous AP. PAS ± ~ + are also found. Cyst-like structures (Cy) are observed.
PAS-hematoxylin × 440

Fig. 6 Segment III in the metestrus
Moderate C. C. and PAS ++ are intermingled; a few AP. PAS ± ~ + and PAS ± ~ + are found.
PAS-hematoxylin × 440

Fig. 7 Segment IV in the metestrus
Numerous PAS ++ are observed.
PAS-hematoxylin × 440

Fig. 8 Segment V in the metestrus
J. C. and tubular gland-like structures (T) are observed.
PAS-hematoxylin × 440

Fig. 9 Segment V in the diestrus
J. C. and PE + are found. Tubular gland-like structures are also observed.
PAS-hematoxylin × 440

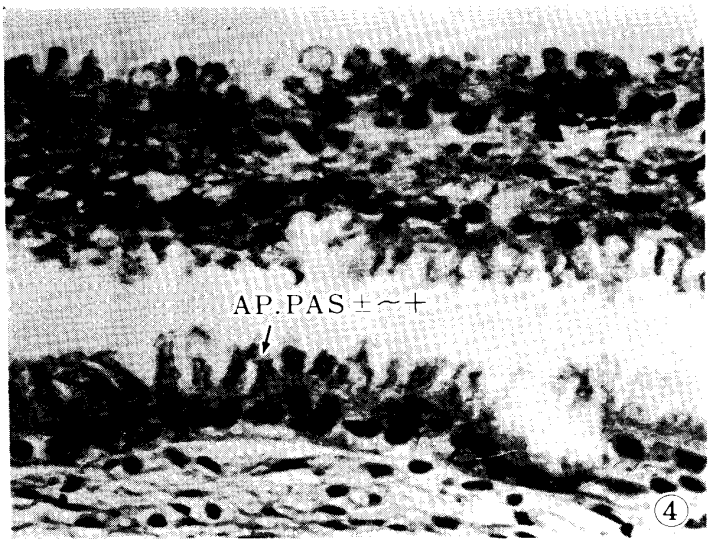
AP.PAS ±~+
④

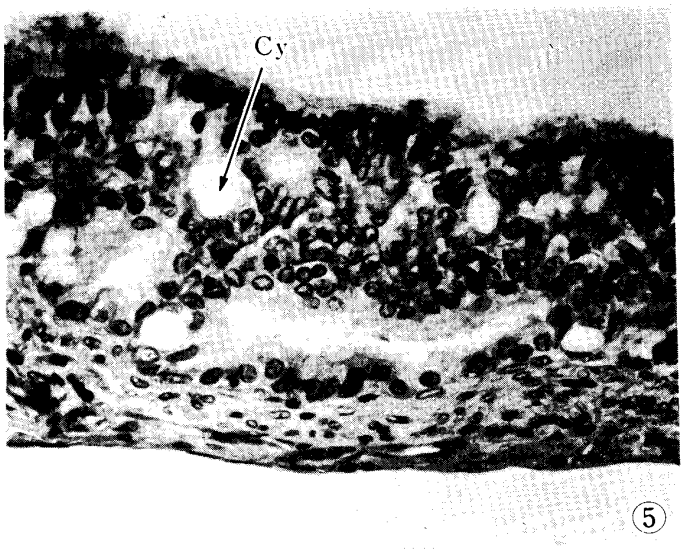
Cy
⑤

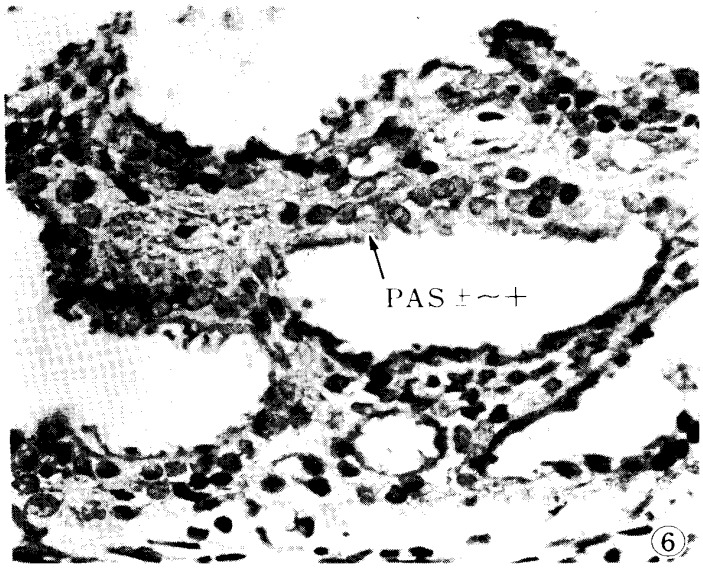
PAS ±~+
⑥

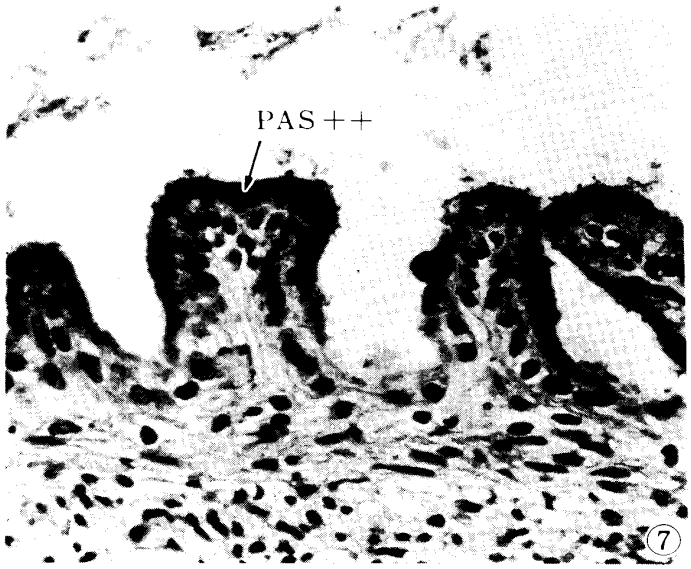
PAS ++
⑦

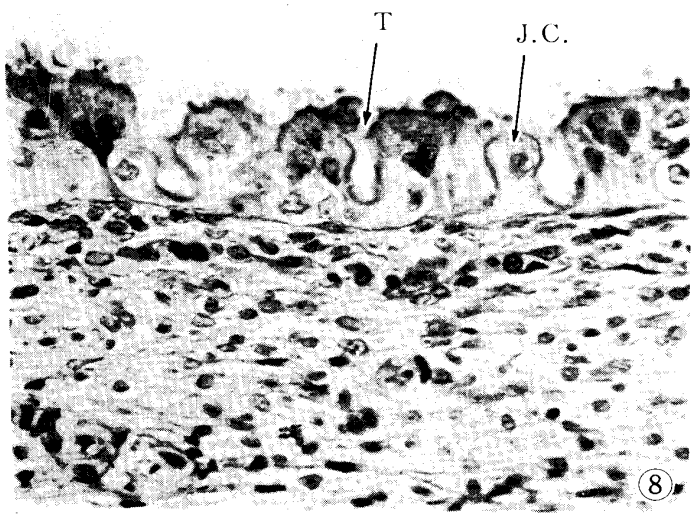
T
J.C.
⑧

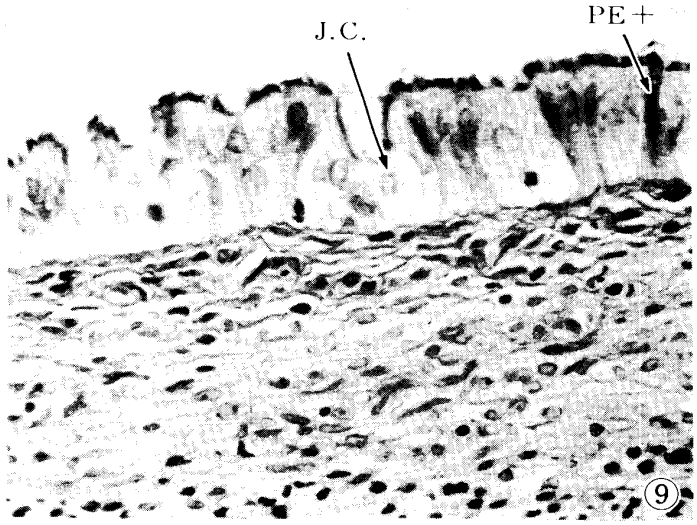
J.C.
PE +
⑨