



Title	SOME HISTOCHEMICAL AND FINE STRUCTURAL ASPECTS OF GROWING SCALES OF THE RAINBOW TROUT
Author(s)	MAEKAWA, Koji; YAMADA, Juro
Citation	北海道大學水産學部研究彙報, 21(2), 70-78
Issue Date	1970-08
Doc URL	http://hdl.handle.net/2115/23415
Type	bulletin (article)
File Information	21(2)_P70-78.pdf



[Instructions for use](#)

SOME HISTOCHEMICAL AND FINE STRUCTURAL ASPECTS OF GROWING SCALES OF THE RAINBOW TROUT

Koji MAEKAWA* and Juro YAMADA*

The teleost scale is one of the calcifying tissues lying in the dermal connective tissue. Since its availability in the age determination of fishes was proposed by Hoffbauer in 1899, the scale has long been subjected to the interest of many fisheries biologists. A considerable number of investigations concerning the structure, the chemical organization, and the growth mechanism have been carried out for the purpose of finding a scientific basis for a possible relationship between the scale pattern and the life history of fishes (Green and Tower, 1901; Taylor, 1916; Paget, 1920; Neave, 1940; Dietrich, 1953; Lindahl and Wallin, 1955; Wallin, 1957; Yamada, 1961; Moss, 1964). However, the knowledge so far obtained seems to leave still much to be solved.

According to these previous works, the teleost scale is composed of two different layers, an upper calcifying bony or osseous layer and a lower uncalcifying fibrillary plate. A study on a fish scale of such a peculiar structure as having either calcifiable and uncalcifiable components, could also provide a clue to the general rule for biological calcification, that has long been sought for because of its importance to the dental and medical sciences.

Keeping these points in mind, some histochemical and electron microscopic observations of growing scales have been made in this study, because only little information can be available through these approaches (Wallin, 1956, 1957; Yamada, 1956, 1961; Cooke, 1967).

We wish to express our hearty thanks to Professor Shinjiro Kobayashi for his invaluable suggestions and encouragement in the course of the present study and kind reading of the manuscript.

Material and Methods

One- and two-year-old rainbow trout (*Salmo gairdnerii irideus*) ranging from 9 to 14 cm in body-length and from 8 to 80 g in body-weight, were used as material. They had been reared in a pond of our campus giving them a boiled mixture of dried shrimp and wheat meal. All the healthy fish were found to be growing actively. Small pieces of the skin, taken from the left side of the body, were treated for microscopic observations as follows.

* *Laboratory of Physiology and Ecology, Faculty of Fisheries, Hokkaido University*
(北海道大学水産学部生理学生態学講座)

For light microscopy, 10% neutral formalin and Bouin's solution were used as fixatives. Paraffin sections, cut 5 to 10 μ thick without any special decalcifying procedure, were submitted to the following staining solutions or histochemical reactions: Delafield's hematoxylin and eosin, McManus' orcein and Weigert's resorcin fuchsin for elastic fibers, Van Gieson's picrofuchsin for collagen fibers, polychrome stain for identification of immature collagen (Herovici, 1963), periodic acid-Schiff (PAS) reagent, toluidine blue (pH 2.3, 3.4 and 7.0) and Alcian blue (pH 2.3) for acid mucopolysaccharides, and the von Kossa's method for calcium salts. The digestion tests of PAS-positive materials with saliva (Lison, 1960) and of acid mucopolysaccharides with testicular hyaluronidase (Bélanger, 1956) were also made. For further analyses of carbohydrate groups, techniques of methylation-acetylation and methylation-saponification were applied to some sections prior to staining procedures for acid mucopolysaccharides and PAS-positive materials (Lison, 1960).

For electron microscopy, small skin pieces were fixed either in cold 1% osmium tetroxide (Millonig's solution) for 1 hour or in cold 6% glutaraldehyde for 1.5 hours followed by 1 hour fixation in osmium tetroxide. Some specimens were decalcified after fixation with 6% glutaraldehyde by bringing them into a cold 0.1 M solution of disodium EDTA (adjusted to pH 7.4 with sodium hydroxide) containing 4% glutaraldehyde (Baird *et al.*, 1968), and then, they were washed with a phosphate buffer solution (pH 7.4) and postfixed with osmium tetroxide for 1 hour.

Fixed specimens were embedded in Epon epoxy resin mixture and sectioned with a Porter-Blum microtome. Ultrathin sections were stained with either uranyl acetate or lead monoxide. Some sections were observed without staining for the identification of mineral crystals. Together with the ultrathin sections, 1 μ -thick-Epon sections were obtained for light microscope examination. These plastic sections were stained with toluidine blue after Yamamoto (1963).

Results

Light microscopy

The examined scale was composed of two different layers, an upper osseous layer showing a strong basophilia and a lower eosinophilic fibrillary plate (Fig. 1). The concentric circuli in cross section appeared to be serrated ridges on the surface of the osseous layer. The growing margin of the scale, beneath which the fibrillary plate was not yet developed, was found to be continuous with the osseous layer. The basophilic nature of this zone was greatly reduced. In contrast to the other calcified zone of the scale, histochemical detection of calcium salts by the von Kossa's method showed to be negative in this marginal zone only.

Accordingly, the scale margin showing a feeble basophilia should be called a "preosseous" or "osteoid" zone.

Both orcein and resorcin fuchsin stained the osseous layer much more deeply than did the osteoid zone. On the other hand, the osseous layer and the osteoid zone were both stained pinkish red with Van Gieson's picrofuchsin for collagen, and faint blue with polychrome stain which has been known to help distinguish pre-collagen (blue) from mature collagen (red).

Both the osseous layer and the osteoid zone showed an intense reaction to the PAS-reagent, even after digestion with saliva (Fig. 2). The PAS-positivity was recovered by saponification after making it negative by acetylation. An intense metachromasy was observed in the osseous layer with toluidine blue (pH 2.3, 4.2 and 7.0), while it was faint or negative in the osteoid zone (Fig. 3). Staining reaction with Alcian blue similarly showed a marked difference between the osseous layer and the osteoid zone. The metachromasy of the osseous layer with toluidine blue was not restored by saponification after blocking both carboxyl and sulfate groups by methylation.

The fibrillary plate was found to be composed of several lamellae. It was stained deeply red with Van Gieson's picrofuchsin and polychrome. Only the lowest lamella being in direct contact with the underlying cells, however, turned out blue with the polychrome stain. The fibrillary plate, as a whole, was faintly stained with PAS-reagent, but was unstained with Weigert's resorcin fuchsin. It was characteristic that the plate showed neither metachromasia with toluidine blue nor positive staining with Alcian blue (Fig. 3). In company with a negative reaction of the von Kossa's, this characteristic of the fibrillary plate was found to form a striking contrast with the osseous layer.

The results obtained from the present histochemical and histological observations are summarized in Table 1. From these findings, a chemical nature of the scale may be estimated as follows. The osseous layer including the osteoid zone is composed of neutral heteropolysaccharides, acidic sulfated mucopolysaccharides, and both mature and immature collagens. The acidic sulfated mucopolysaccharides are probably chondroitin sulfate A and/or C in nature. The osseous layer, except for the osteoid zone, retains deposits of calcium salts, while the fibrillary plate remains uncalcified. The fibrillary plate is composed of collagen fibers cemented by mucopolysaccharides.

Electron microscopy

The matrix of the osteoid zone, showing various width and thickness according to certain regions of the scale, was identified as to consist of amorphous ground substance in which fine collagen fibers were dispersed randomly (Fig. 4). Each fiber measured about 300 A thick, showing periodic bands. The inner region of the osteoid zone was filled with an amorphous substance which appeared to be denser

Table 1. Comparison of staining and histochemical characteristics of osteoid zone, osseous layer and fibrillary plate in the scale of rainbow trout. Intensities of histochemical reactions are indicated; ## very strongly positive, + strongly positive, + moderately positive, ± feebly positive or negative, and - negative.

	Reactions		
	Osteoid zone	Osseous layer	Fibrillary plate
Hematoxylin-eosin	weak blue	blue	red
Van Gieson	weak red	weak red	red
Polychrome	blue green	blue green	red
Verhoff's elastic stain	weak black	black	unstain
McManus' orcein	weak black	black	unstain
Weigert's elastic stain	weak black	black	unstain
von Kossa	-	##	-
PAS	+	##	+
after saliva digestion	+	##	+
after acetylation-saponification	+	##	+
Toluidine blue (metachromasia)			
pH 2.3	±	##	-
pH 3.2	±	##	-
pH 7.0	±	##	-
after hyaluronidase digestion	±	±	-
after methylation-saponification	-	-	-
Alcian blue	±	##	-

than that in the newly formed peripheral zone. A number of small dense particles with no limiting membrane, about 500 A in diameter, were found within the denser ground substance. The calcification of the matrix seems to occur by filling these particles with needle-shaped hydroxyapatite crystals (Figs. 4, 6 and 7). The situational relationship between the crystals and the collagen fibers is not evident in the present study (Figs. 4 and 5).

At the distal end of the osteoid zone, the matrix was continuous to the intercellular material between the round cells lying around this zone. These cells were found to be characterized by their extensive endoplasmic reticulum and also by relatively large nuclei. Occasionally, a Golgi apparatus and small dense bodies of 1000 to 4000 A in diameter were noted in their cytoplasm. Each of the latter bodies was provided with a single limiting membrane. Many pinocytotic vesicles were found in the ectoplasm of these cells. The intercellular spaces distant from the osteoid were filled with bundles of fine collagen fibers (Fig. 4).

In the transitional zone between the osteoid and the central osseous region, it was characteristic that the cells became gradually flattened in shape and extended to form one or two layers covering the osseous layer. In the cytoplasm of these flattened cells were noted a parallel array of extensive granular endoplasmic reticulum (GER), a well developed Golgi apparatus and a moderate number of elliptical mitochondria having abundant cristae (Fig. 5). These cells also contained a few small dense bodies and pinocytotic vesicles, both of which appeared to be identical with those found in the cells around the osteoid zone. The deposits

of hydroxyapatite crystals were found to increase gradually in amount as the osseous region approaches. There was found no distinct boundary between two regions as to the state of calcification. An observation of the decalcified matrix of a highly calcified portion of osseous layer revealed an accumulation of randomly oriented collagen fibers and a dense amorphous substance, a structure similar to the osteoid matrix (Fig. 8). The deeper portion of the osseous layer showed a heavier deposit of crystals, but a sign of calcification was found to occur at the superficial region just beneath the flattened cells where large crystals were already present. Dense particles like those observed in the osteoid zone were also present in this superficial region (Figs. 5 and 6). Within the highly calcified region, narrow remaining uncalcified areas were occasionally recognized. It should be noted that a characteristic of these islands free from calcium salts was an orderly arrangement of collagen fibers (Fig. 9).

The scale ridge was observed to be a wedge-shaped projection of the osseous layer being held between two upper cells. The outermost ridge was indiscernible from the osteoid owing to its fine structure. The second ridge from the outer margin was measured to grow about 3μ in height, and was found to be as highly calcified as the osseous layer.

Cells lining the fibrillary plate were rectangular in shape being linked in one layer. The most striking feature of these cells was their fully developed GER and large nuclei. The fibrillary plate was composed of several lamellae. In each lamella of about $2-3\mu$ in thickness, thick collagen fibers were found to run orderly in a definite direction. An alteration of the direction of fibers made it possible to distinguish one lamella from another. These collagen fibers measured about 600 A in diameter and were characterized to be much thicker than those (about 300 A) found in the osteoid and in the osseous layer (Figs. 10 and 11). Newly formed fibers in direct contact with the underlying cells, however, were of about 300 A in diameter, and seemed to grow larger and thicker as they left the cell surface (Fig. 10). The lamellae of the fibrillary plate should be formed after the completion of the formation of the osseous layer because no such structure was observed under the osteoid zone (Fig. 4).

Discussion

The histochemical evidence in the present study has shown that the scale growth in the rainbow trout begins with the formation of collagen fibers and PAS-positive materials by the osteoblastic cells lying around the scale margin. A subsequent infiltration of sulfated mucopolysaccharides is suggested both by the methylation-saponification technique and the digestion test with hyaluronidase. The electron microscope observation seems to support this assumption.

A sequential occurrence of the following three major components of the scale matrix has been demonstrated: (1) the collagen fibers of 300 A filling the intercellular spaces between the marginal osteoblasts, (2) the dense amorphous ground substance in the osteoid as well as in the osseous region, and (3) the transitional increase of dense particles within the amorphous substance. It is of particular interest that mineral crystals appear first within these dense particles, suggesting that they act as nucleation seeds in calcification of the scale matrix.

The occurrence of acid mucopolysaccharides has hitherto been recognized in calcifying areas of many tissues such as bone, tooth, cartilage and others as reviewed by Mathews (1967) and Kobayashi (1970). It has been also reported that there is a rapid synthesis of chondroitin sulfate in relation to the calcification of the epiphyseal cartilage (Dziewiatkowski *et al.*, 1968). Maekawa and Yamada (unpublished) have observed in a histochemical study of the regenerating scale in goldfish that a metachromatic substance appears at the same time or just before the initiation of calcification. Neuman and Neuman (1958) have introduced the concept of epitaxy into the calcification of biological systems and directed the worker's attention to the mechanism for the nucleation of mineral salts. Sobel and Burger (1954) have proposed an idea that collagen interacting with a sulfated mucopolysaccharides or mucoprotein should be the nucleating entity. This idea seems to be supported by recent electron microscopic evidence. Nylen and Scott (1960) have suggested that the initiation of pathological calcification in the turkey leg tendon is associated with an appearance of polysaccharides and phospholipids in the ground substance surrounding the collagen fibers. Takuma (1960) has observed in the developing cartilaginous epiphysis that areas previously occupied by mineral crystals show a dense or solidified appearance after complete removal of the crystals by staining with phosphotungstic acid. Bonucci (1967, 1969) has observed roundish osmiophilic bodies in the costochondral junction of the guinea pig, suggesting that those bodies are composed of thin and rod-shaped protein like structure surrounded and sheathed by acid polysaccharide. Such bodies have been observed also in other calcifying tissues (Scherft, 1968; Matukas and Krikos, 1968). The dense particles observed in this study are considered to be identical with the roundish bodies found by Bonucci. The amorphous ground substance is thought to play a secondary role in the calcification of the scale as cementing material. In considering the histochemical evidence altogether, the dense particles may possibly be related to a structure of sulfated mucopolysaccharide or protein-polysaccharide complex, and the amorphous ground substance to PAS-positive materials.

Metachromatic staining with toluidine blue has been reported to be unrecognizable in fully calcified bone (Cabrini, 1961) and in the intact osseous layer of some fish scales (Wallin, 1956; Yamada, 1961). In the present material,

however, the metachromasia was clearly shown to appear both before and after its decalcification treatment. This may be due to a structural difference between scale and bone, or to any different state of a combination of mucopolysaccharide with protein molecules (Sugiyama, 1964).

The role of the collagen fibers of 300 A playing in the mineralization of the organic matrix is not evident. The arrangement of collagen fibers, however, may affect the calcification of the scale, since the uncalcified islands and the fibrillary plate are composed of orderly arranged collagen fibers whereas they are dispersed in random directions in the calcified matrix. It would be desirable to clarify possible relationships between collagen, chondroitin sulfate and mineral crystals by further electron microscopic and biochemical analyses.

The cells forming the osseous layer are similar in morphology to osteoblasts of the bone as shown by the abundance of GER, mitochondria and Golgi apparatuses (Dudley and Spiro, 1961; Robinson and Cameron, 1964; McLean and Urist, 1968).

The difference between the osseous layer and the fibrillary plate is quite conspicuous in both histochemical nature and fine structure. Since no such a fibrillary structure is observed under the osteoid zone, the fibrillary plate must grow by taking new fibrous lamellae onto the undersurface of the scale after some extension of the osseous layer as has been insisted by Neave (1940) and Yamada (1961), although Wallin (1957) has suggested that both the fibrillary plate and the osseous layer originate from one germ structure. No materials other than the collagen fibers and PAS-positive material were identified in the fibrillary plate from the present histochemical and electron microscopic observations. This PAS-positive material may play a role in the formation of an interfibrillar cementing substance. The activity of the cells engaged in the production of these materials is represented in their cytoplasmic feature as shown by finely developed cisternae of GER in parallel array, a characteristic of fibroblastic cells in general connective tissues (Ross, 1968). The lamellar structure of the fibrillary plate reported by Neave (1940) and Dietrich (1953) is demonstrated to be formed by an alteration of the orientation of collagen fibers. However, it is not clear at present how this alteration could occur.

Summary

Some histochemical and electron microscope observations on the growing scale of juvenile and young rainbow trout were made with a particular note on the structure of the growing margin, an osteoid zone.

The upper layer of the scale is shown histochemically to be mainly composed of neutral heteropolysaccharides, acidic sulfated mucopolysaccharides and collagen. Most of the reactions tested are more intense in the osseous layer than in the

osteoid zone. Both metachromasia with toluidine blue and Alcian blue staining are negative or weakly positive in the osteoid zone in correspondence with negative reaction for calcium salts. Electron microscopy revealed the occurrence of the following characteristic substances or structures in the growing scale matrix: (1) fine collagen fibers (300 A) filling the intercellular spaces between marginal scale-forming cells, (2) dense amorphous ground substance in addition to the collagen fibers in the osteoid zone, and (3) a transitional increase of dense particles within the amorphous substance from the osteoid zone to the osseous zone. Incipient mineral crystals appear within these dense particles. In considering the histochemical evidence in connection with the electron microscope observation, an intimate relation to the calcification of the scale may possibly be associated with sulfated mucopolysaccharides of the dense particles and also with PAS-positive materials of the amorphous ground substance.

The lamellar structure of the fibrillary plate is formed by an alteration in the orientation of 600 A collagen fibers cemented by PAS-positive materials.

References

- Baird, I.L., Winborn, W.B. & Bockman, D.E. (1968). A technique of decalcification suited to electron microscopy of tissues closely associated with bone. *Anat. Rec.*, **159**, 281-290.
- Bélangier, L.F. (1956). Autoradiographic studies of the formation of the organic matrix of cartilage, bone and the tissues of teeth. In: "*Bone structure and metabolism*". pp. 75-88. (Wolstenholme, G.E.W. & O'Conner, C.M. eds.), J. & A. Churchill Ltd., London.
- Bonucci, E. (1967). Fine structure of early cartilage calcification. *J. Ultrastr. Res.*, **20**, 33-57.
- (1969). Further investigation on the organic/inorganic relationships in calcifying cartilage. *Calc. Tiss. Res.*, **3**, 38-54.
- Cabrini, R.L. (1961). Histochemistry of ossification. *Intern. Rev. Cytol.*, **11**, 283-306.
- Cooke, P.L. (1967). Fine structure of the fibrillary plate in the central head scale of the striped killifish, *Fundulus majalis*. *Trans. Amer. Microsc. Soc.*, **86**, 273-279.
- Dietrich, M.A. (1953). A histological study of the development of the scale of the largemouth black bass (*Micropterus salmoides*). *Quart. J. Microsc. Sci.*, **91**, 71-82.
- Dudley, H.A. & Spiro, D. (1961). The fine structure of bone cells. *J. Biophys. Biochem. Cyt.*, **11**, 627-649.
- Dziewiatkowski, D.D., Tourtellotte, C.D. & Campo, R.D. (1968). Degradation of protein-polysaccharide (chondromucoprotein) by an enzyme extract from cartilage. In: "*The chemical physiology of mucopolysaccharides*". pp. 63-80. (Quintarelli, G. ed.), Little, Brown & Co., Boston.
- Green, E. & Tower, R.E. (1901). The organic constituents of the scales of fishes. *Bull. U. S. Fish. Commiss.*, **21**, 97-102.
- Herovici, G. (1963). A polychrome stain for differentiating precollagen from collagen. *Stain Technol.*, **38**, 204-205.
- Kobayashi, S. (1970). Acid mucopolysaccharides in calcified tissues. *Intern. Rev. Cytol.*, **30**, (in press).
- Lindahl, P.E. & Wallin, O. (1955). On the relationship between the growth structure of the

- bone and the fibrillary layers of the roach-scale. *Arkiv f. Zool.*, Ser. 2., 8, 561-563.
- Lison, L. (1960). "Histochimie et Cytochimie Animales" 3^e éd., Gauthier-Villars, Paris.
- McLean, F.C. & Urist, M.R. (1968). *Bone. Fundamental of the physiology of skeletal tissue.* Univ. Chicago Press, Chicago and London.
- Maekawa, K. & Yamada, J. (unpublished).
- Mathews, M.B. (1967). Macromolecular evolution of connective tissue. *Biol. Rev.*, 42, 499-551.
- Matukas, U.L. & Krikos, A. (1968). Evidence for change in protein polysaccharide associated with the onset of calcification in cartilage. *J. Cell. Biol.*, 39, 43-48.
- Moss, M.L. (1963). The biology of acellular teleost bone. *Ann. N. Y. Acad. Sci.*, 109, 337-350.
- Neave, F. (1940). On the histology and regeneration of the teleost scale. *Quart. J. Microsc. Sci.* 81, 541-568.
- Neuman, W.F. & Neuman, M.W. (1958). "The chemical dynamics of bone mineral". Univ. Chicago Press, Chicago.
- Nylen, V. & Scott, D.A. (1960). Basic studies in calcification. *J. Dental Med.*, 15, 80-84.
- Paget, G.W. (1920). Report on the scales of some teleostean fish with special reference to their method of growth. *Fish. Invest.*, Ser. 2., 4 (3), 1-28.
- Robinson, L.P. & Cameron, D.A. (1964). Bone. In: "Electron microscopic anatomy". pp. 315-340. (Kurtz, S.M. ed.), Academic Press, New York & London.
- Ross, R. (1968). The fibroblast and wound repair. *Biol. Rev.*, 43, 51-96.
- Scherft, L.P. (1968). The ultrastructure of the organic matrix of calcified cartilage and bone in embryonic radii. *J. Ultrastr. Res.*, 23, 333-343.
- Sobel, A.F. & Burger, M. (1954). Calcification (XIV). Investigation of the role of chondroitin sulfate in the calcified mechanism. *Proc. Soc. Exptl. Biol. Med.*, 87, 7-13.
- Sugiyama, J. (1964). Histochemical studies on acid mucopolysaccharides. I. On some new methods and differentiation in tissue section. *Acta. Path. Jap.*, 14, 413-433.
- Takuma, S. (1960). Electron microscopy of the developing cartilaginous epiphysis. *Arch. Oral Biol.*, 2, 111-119.
- Taylor, H.F. (1916). The structure and growth of the scales of the squetague and the pigfish as indicative of life history. *Bull. Bur. Fish.*, 34, 289-330.
- Wallin, O. (1956). Mucopolysaccharides and the calcification of the scale of the roach. *Quart. J. Microsc. Sci.*, 97, 329-332.
- (1957). On the growth and developing physiology of scale of fishes. *Rep. Inst. Freshw. Res. (Drottningholm)*, 38, 385-447.
- Yamada, J. (1956). On the mechanism of the appearance of the scale structure. V. The possible role of alkaline phosphatase in the formation of the teleost scale. *Bull. Fac. Fish., Hokkaido Univ.*, 7, 185-201.
- (1961). Studies on the structure and growth of the scales in the goldfish. *Mem. Fac. Fish., Hokkaido Univ.*, 9, 181-226.
- (1964). On the feature of scales developed in the regenerated skin of the goldfish, with special reference to the formation of their concentric ridges. *Bull. Fac. Fish., Hokkaido Univ.*, 14, 199-207.
- Yamamoto, T. (1963). A method of toluidine blue stain for epoxy embedded tissues for light microscopy. *Kaibogaku Zasshi*, 38, 124-128. (in Japanese).

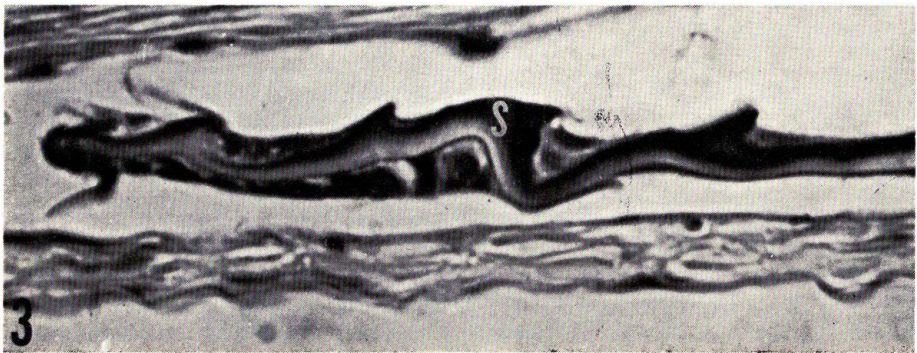

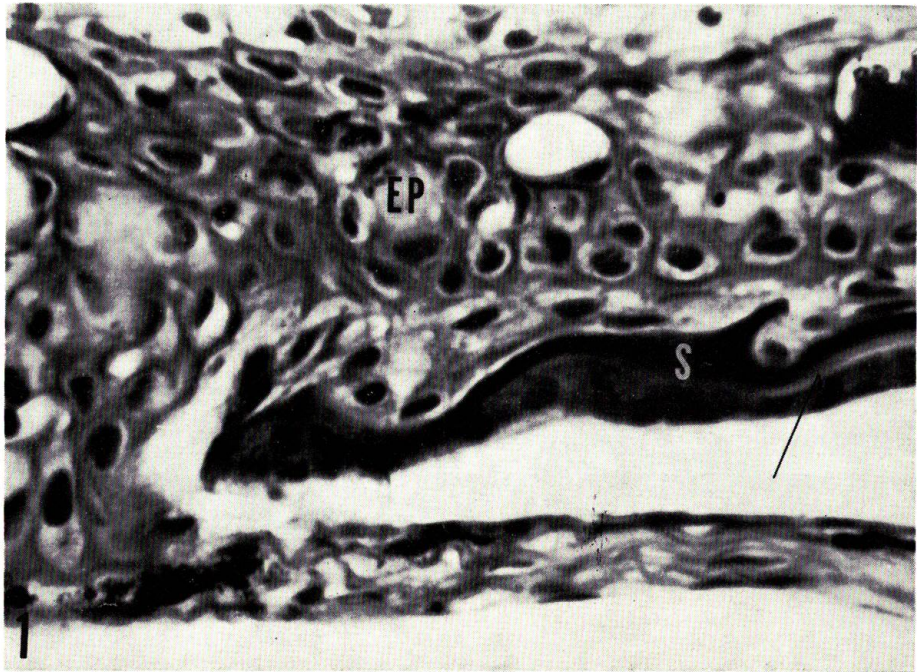
Explanation of Plates

PLATE I

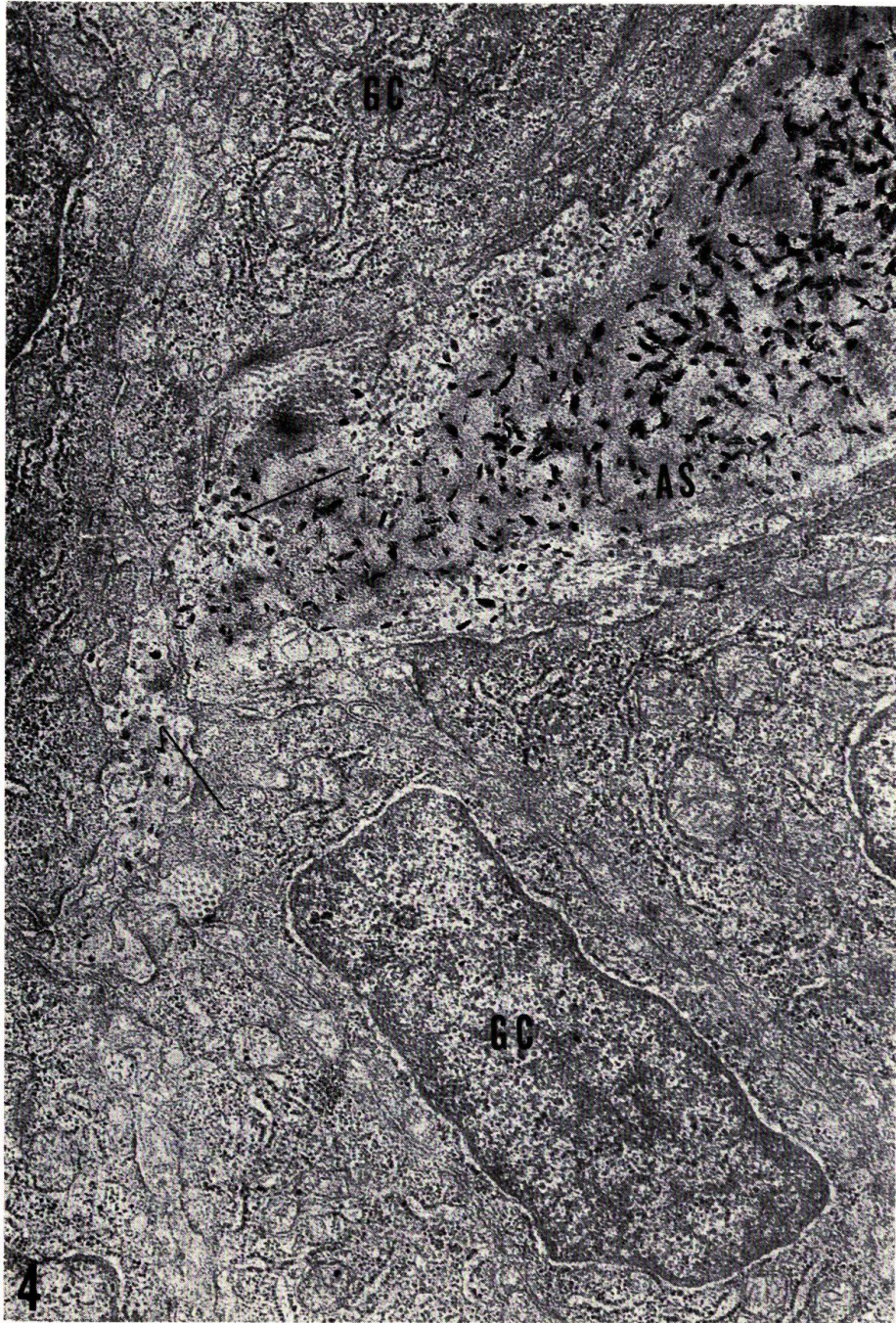
Fig. 1. Posterior growing margin of scale and associating cells both showing a basophilia. Eosinophilic fibrillary plate (arrow) which is not extended to the extreme end, is sandwiched between the upper basophilic osseous layer and the lower cell layer. EP, epidermis; S, scale. Hematoxylin-eosin. $\times 1,000$.

Fig. 2. Osteoid zone and osseous layer both showing an intense PAS-positive reaction. The fibrillary plate is also PAS-positive but less intense. S, scale. PAS. $\times 800$.

Fig. 3. Metachromasia with toluidine blue occurred in the osseous layer. Note weakly positive or negative staining in the osteoid zone. S, scale. $\times 1,000$.



K. Maekawa & J. Yamada: Histochemistry and fine structure of trout scale



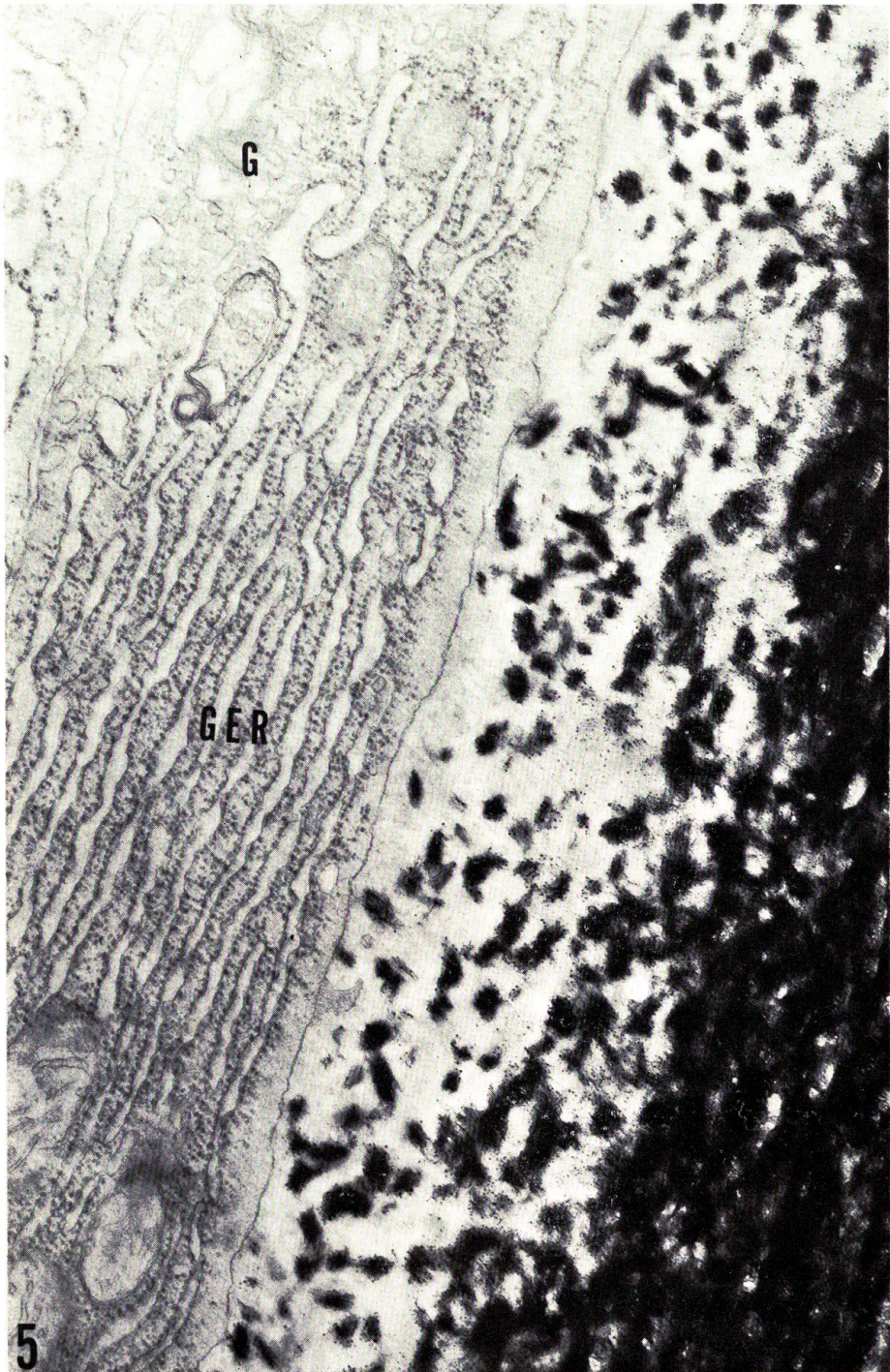
K. Maekawa & J. Yamada: Histochemistry and fine structure of trout scale

PLATE II

Fig. 4. Osteoid zone and cells engaged in growth of the scale margin. Note dispersed calcium crystals in relation to dense particles in the background of amorphous substance (AS). Arrows indicate dense particles in which calcium crystals are not yet contained. The deposits of hydroxyapatite crystals are found to increase gradually in amount as the osseous region approaches. GC, cells of the growing margin. No stain. $\times 20,800$.

PLATE III

Fig. 5. Upper surface of the osseous layer in progress of calcification and thin elongated cell in close adherence to it. G, Golgi apparatus. GER, granular endoplasmic reticulum. Lead stain. $\times 30,800$.



K. Maekawa & J. Yamada: Histochemistry and fine structure of trout scale

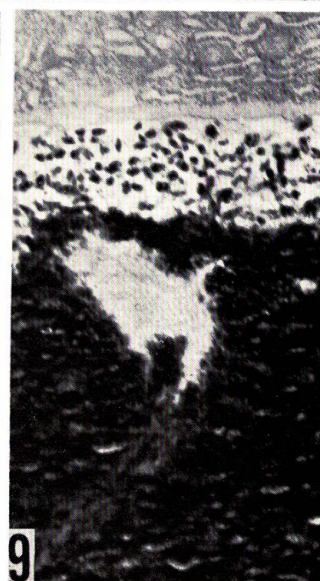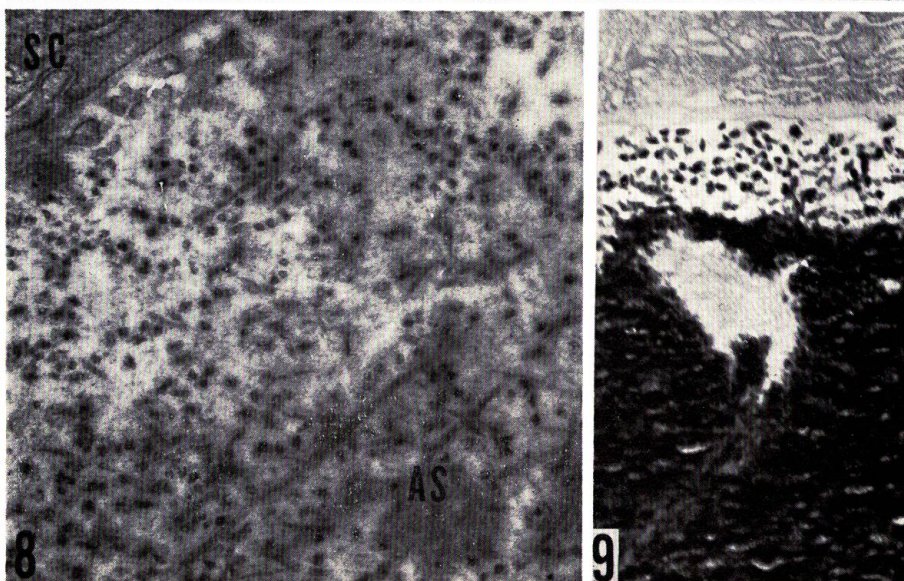
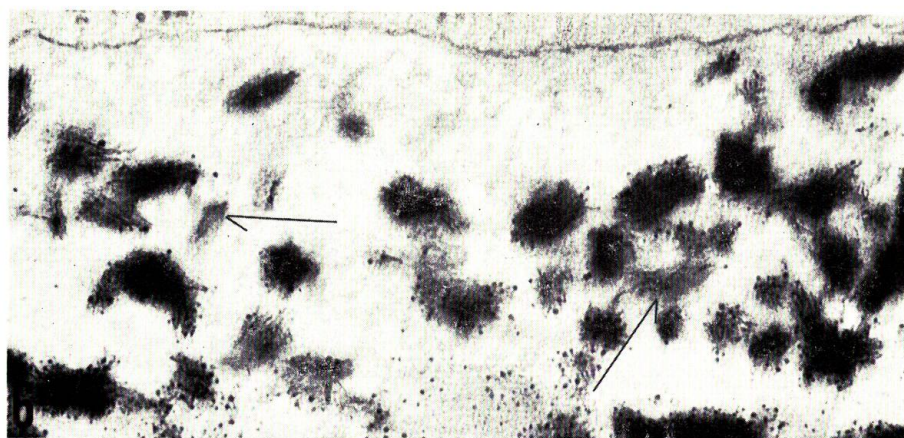


PLATE IV

Fig. 6. A partial magnification of the section shown in Fig. 5. Arrows indicate dense particles in which calcium crystals are not yet found. Lead stain. $\times 47,000$.

Fig. 7. Needle-shaped hydroxyapatite crystals at high magnification. No stain. $\times 111,000$.

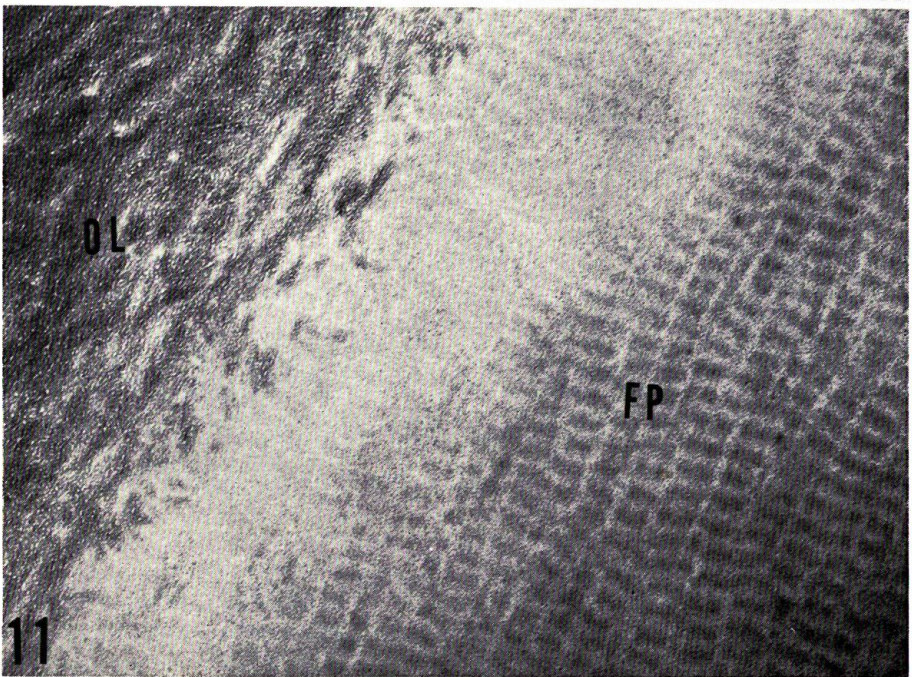
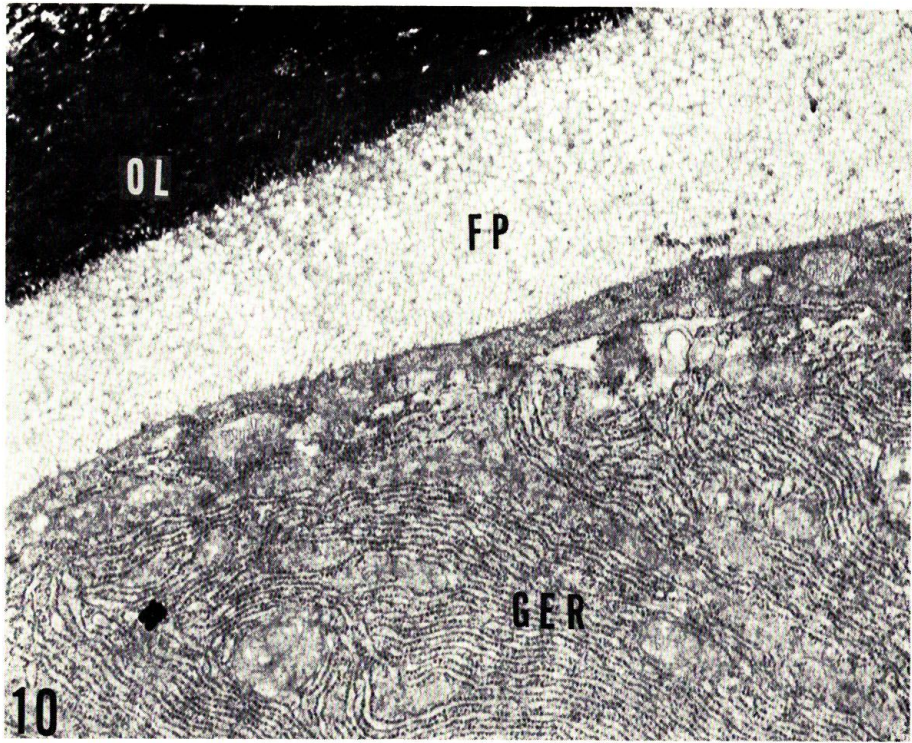
Fig. 8. A decalcified section of a highly calcified portion of the osseous layer. An accumulation of randomly oriented collagen fibers (300 A) and dense amorphous substance are noted. AS, amorphous background substance; SC, scale-forming-cell. Uranyl acetate stain. $\times 32,000$.

Fig. 9. A part of the osseous layer leaving an uncalcified island in the highly calcified zone. Note an orderly arrangement of collagen fibers in this island. Lead stain. $\times 12,000$.

PLATE V

Fig. 10. Fibrillary plate and a part of two adjacent cells under formation of collagen fibers. The granular endoplasmic reticulum (GER) is fully developed in the cells. Extracellular collagen fibers of the plate are running orderly in a definite direction. FP, fibrillary plate; OL, osseous layer. Lead stain. $\times 9,000$.

Fig. 11. A high magnification of the fibrillary plate showing a periodic banding pattern in orderly arranged thick (600 A) collagen fibers. FP, fibrillary plate; OL, osseous layer. Lead stain. $\times 51,600$.



K. Maekawa & J. Yamada: Histochemistry and fine structure of trout scale