Bull. Fac. Fish. Hokkaido Univ.
32(2), 120-135. 1981.

Changes of Two Types of Pituitary Gonadotrophs of the Loach, *Misgurnus anguillicaudatus*, during Gonadal Development and Reproductive Cycle*

Hiroshi UEDA**

Abstract

Two types of gonadotrophs, termed the globular and the vesicular cell, in the proximal pars distalis (PPD) of the pituitary gland of the loach, *Misgurnus anguillicaudatus*, showed different ultrastructural changes both during the course of gonadal development in young fish and during the reproductive cycle in adult fish of both sexes. The globular cells, which had already existed in the PPD of young loaches of both sexes, displayed a notable increase in size and in number in harmony with the progressive maturation of ovaries and testes. The cells revealed a conspicuous depletion of small granules, extensive dilation of the rough endoplasmic reticulum, and subsequent pycnotic changes of the nucleus in ovulating females and spermiating males. In the loach, the globular cells may secrete a gonadotropin which promotes gonadal changes mainly concerned with ovulation and spermiation. The vesicular cells in the loach made their first appearance in the PPD concurrently with the commencement of exogenous vitellogenesis in ovarian oocytes or with the formation of spermatocytes in the testes. During the subsequent course of vitellogenesis and spermatogenesis, the vesicular cells did not show any conspicuous change, even at the time of ovulation and spermiation. The cells appeared to become active a few months after the end of the spawning period, before exogenous vitellogenesis in the ovarian oocytes and spermatognesis in the testes had taken place. The vesicular cells may secrete a gonadotropin which is implicated in the onset of vitellogenesis and spermatogenesis in the loach.

Previous investigations on some teleost species of the genus *Misgurnus* have indicated the presence of two types of pituitary gonadotrophs by light and electron microscopy[1)2)]. However, these studies did not refer to cytological changes in the cells of fishes under different physiological conditions. In *M. anguillicaudatus*, as reported previously[3)4)5)6)], two types of pituitary gonadotrophs have been identified and demarcated through their ultrastructural changes effected by several experimental treatments causing decisive alterations of gonadotropic activities of the pituitary gland of the fish. However, possibly different gonadotropic roles played by the two types of cells in gonadal development of the loach still remained to be studied.

In the present study, ultrastructural studies on changes of the pituitary gonadotrophs were carried out in female and male loaches during the reproductive cycle

* This paper was submitted to the Hokkaido University as a part of the thesis for the degree of Doctor of Fisheries.

** *Laboratory of Fresh-Water Fish-Culture, Faculty of Fisheries, Hokkaido University*
(北海道大学水産学部淡水増殖学講座)

and during the course of gonadal development in young fish, in order to solve the problem as to when the two types of gonadotrophs may exert their respective gonadotropic potencies.

The writer is deeply grateful to Professors H. Takahashi and J. Yamada, and Associate Professor K. Takano, Faculty of Fisheries, Hokkaido University, for their interest and important suggestions given to the present study.

Material and Methods

A total of 169 loaches, *Misgurnus anguillicaudatus*, ranging from 4.3 to 15.1 cm in body length and from 0.5 to 20.6 g in body weight, were collected, monthly from April 1977 to May 1978, from brooks in the vicinity of Hakodate, Hokkaido. About 10–15 young and adult fish of both sexes were sampled at a time. They were killed by decapitation and their pituitary glands were excised out immediately. Some of the glands were preserved in Bouin-Hollande-sublimate for about 3 days, cut at 6 μm in thickness and stained with alcian blue-PAS-orange G. Others were prefixed with glutaraldehyde in 0.1 M phosphate buffer (pH 7.4) at 4°C for 3 hours or with glutaraldehyde-paraformaldehyde mixture in 0.2 M cacodylate buffer (pH 7.4) at room temperature for about 3 hours, and then postfixed in Millonig's osmium tetroxide solution or in 1% osmium tetroxide in 0.2 M cacodylate buffer (pH 7.4) for about 2 hours at 4°C. Epon-embedded, ultrathin sections were stained double with uranyl acetate and lead citrate, and examined with a Hitachi HU–12 electron microscope. Parallel semithin sections of Epon-embedded specimens of about 1 μm thick were stained with methylene blue for light microscopic comparison. Pieces of gonads were fixed in Bouin's fluid or Bouin-Hollande solution and stained with Delafield's hematoxyline and eosin.

Results

Changes during gonadal development in young loaches

Young female and male loaches, averaging 5.2 cm in body length and 0.9 g in body weight, had quite immature ovaries with oogonia only and immature testes with spermatogonia only, respectively. In these fish, alcian blue- and PAS-positive cells distributed in the central part of the proximal pars distalis (PPD) were only a few in number. These cells were mostly oval or elongate in shape with oval-shaped nuclei (Fig. 1). They contained many small, electron dense granules of 150–300 nm in size and a few large, less electron dense globules of 400–600 nm in size (Fig. 5). In these cells, flattened cisternae of the rough endoplasmic reticulum were sparse, the Golgi apparatus was poorly developed, and mitochondria were a few in number and small in size. These cytological features appeared to correspond to those of the globular type of gonadotrophs existing in the PPD of adult loaches. No cells with cytological characteristics of typical vesicular type of gonadotrophs could be detected in these young fish. However, in the dorsal and central parts of the PPD, there were some cells with clear cytoplasm (Fig. 1), in which cytoplasmic organelles were scarcely developed (Fig. 5). These cells were termed non-granulated cells in the present study.

Yearling females, measuring 8.0 cm in body length and 2.5 g in body weight,

had ovaries with many oocytes of the yolk vesicle stage, and yearling males, measuring 7.0 cm in body length and 1.5 g in body weight, had testes with a small number of cysts of the first spermatocytes together with many spermatogonia. The globular cells in their pituitaries showed almost the same features as those found in the preceding stage. In these fish, some cells with clear vacuoles in the cytoplasm had appeared in the central and dorsal parts of the PPD. These cells were round or oval in shape with mostly round-shaped nuclei, and were strongly positive to PAS but almost negative to alcian blue (Fig. 2). They were marked ultrastructurally by the constant occurrence of numerous cytoplasmic vesicles, or rounded cisternae of the rough endoplasmic reticulum, with finely granular contents of moderate electron density (Fig. 6). These cytoplasmic vesicles were relatively uniform in size in females, but a few of them were extraordinarily large in males on some occasions (Fig. 6). Small granules of 100–300 nm in size were accumulated in groups in their cytoplasm, and a few large globules of 500–800 nm in size were also present. The Golgi apparatus was moderately active and rod-shaped mitochondria occurred in the juxtanuclear region. These cells were thought to be gonadotrophs of the vesicular type that had differentiated during the early phase of the life-cycle, presumably from the non-granulated cells preexisting in the PPD, since the non-granulated cells could hardly be detected in pituitaries of the fish examined at that stage of gonadal development.

In yearling females of 8.8 cm in mean body length and 4.0 g in mean body

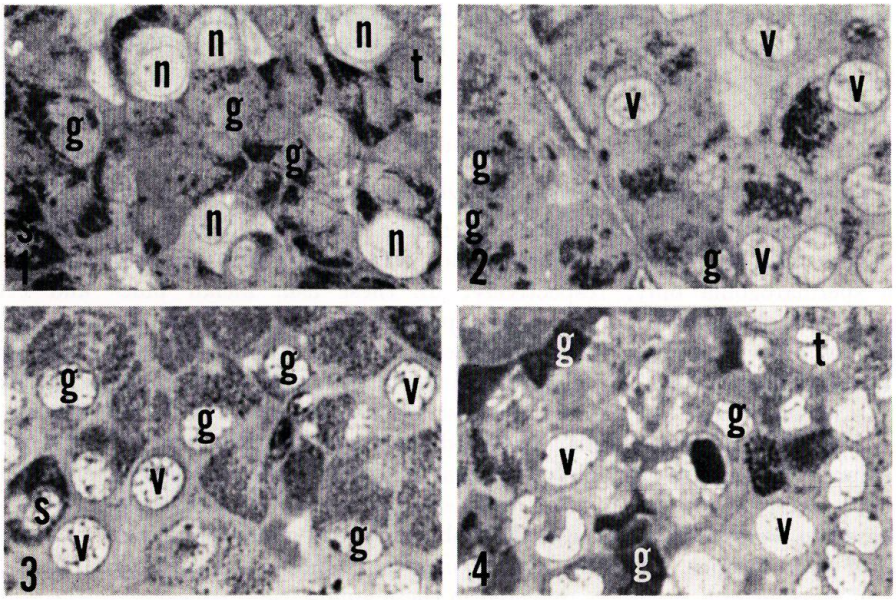

Figs. 1–4. Light microscopic pictures of Epon-embedded, methylene blue-stained sections of the pituitary gland of female loaches having oocytes in the oogonial stage (Fig. 1), in the yolk vesicle stage (Fig. 2), in the tertiary yolk stage (Fig. 3), and in the postspawning stage (Fig. 4). *g*, globular cell; *n*, non-granulated cell; *s*, somatotroph; *t*, thyrotroph; *v*, vesicular cell. × 1000.

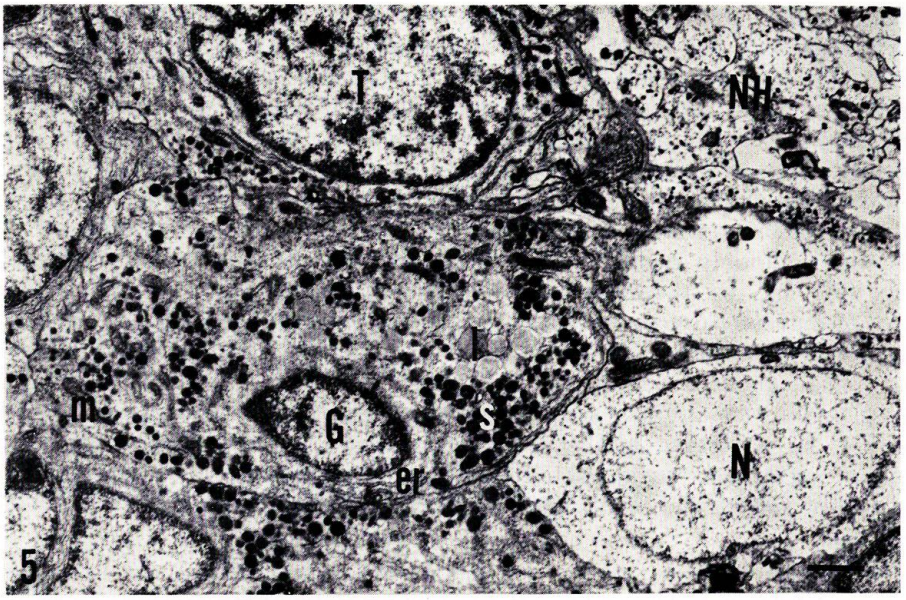

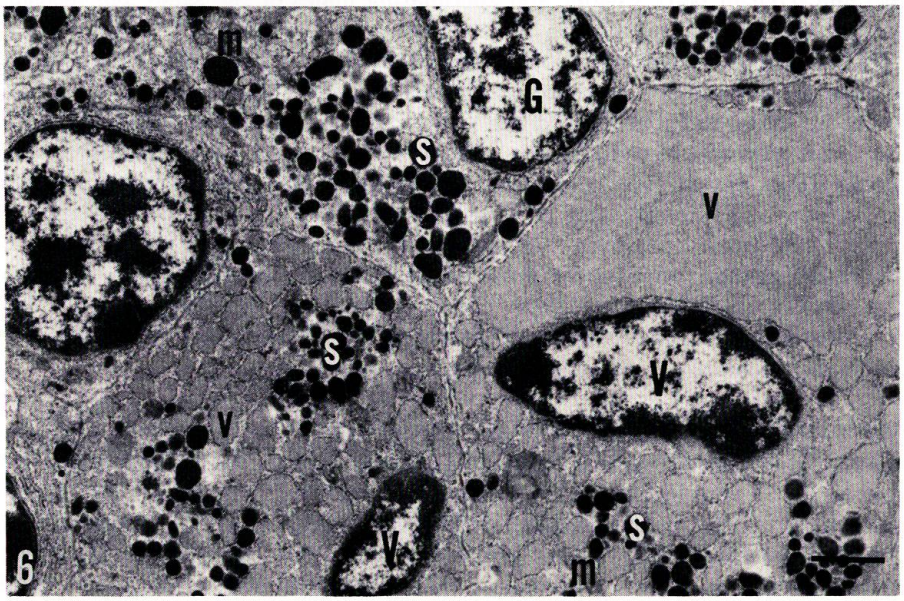

Figs. 5 and 6. Electron micrographs of globular cells (*G*) and vesicular cells (*V*) in pituitaries of a female loach having oocytes in the oogonial stage (Fig. 5) and a male loach having testes with a small number of first spermatocytes (Fig. 6). *er*, rough endoplasmic reticulum; *l*, large globule; *m*, mitochondrion; *N*, non-granulated cell; *NH*, neurohypophysis; *s*, small granule; *T*, thyrotroph; *v*, cytoplasmic vesicle. Scale, 1 μm.

weight, ovaries were filled with many oocytes in advanced vitellogenesis. In yearling males of 7.0–8.0 cm in body length and 2.0–3.5 g in body weight, germ cell cysts in various spermatogenetic stages were present in their testes, and a varying amount of spermatozoa was always accumulated in expanded lumina of testicular lobules. In the pituitary gland of these fish, a considerable number of the vesicular cells were found in the dorsal and central regions of the PPD (Fig. 3). In the cytoplasm of these cells, small granules were enlarged to 150–450 nm in size, but large globules remained unchanged in size. Cytoplasmic vesicles of the cells were uniformly round in shape, and the Golgi apparatus was moderately active (Fig. 7). On the other hand, the globular cells came to exhibit a highly active feature in harmony with the progress of gonadal development. The cells were observed to have increased in number and in size (Fig. 3). In their cytoplasm, small granules were increased evidently in size to attain 200–500 nm, and large globules were also increased both in number and in size to measure 600–1200 nm (Fig. 7). Cisternae of the rough endoplasmic reticulum were dilated to various extents and contained electron lucent material. The Golgi apparatus was highly active, and sometimes immature granules were present within the Golgi field.

Female loaches that had spawned for the first time measured 9.5 cm in body length and 5.0 g in body weight, and spermiating males of the same age measured 8.5 cm in body length and 4.3 g in body weight. In these fish, the globular cells in the PPD displayed a degenerative feature: the cells have been atrophied and were unusually dark in light microscopic figures (Fig. 4). Their nuclei were quite irregular in shape and unusually dense. Their cytoplasm was also highly electron dense, with the rough endoplasmic reticulum consisting of irregularly dilated cisternae (Fig. 8). In the condensed cytoplasm, a decreased number of small granules were still present, and large globules appeared to remain unchanged in number. The Golgi apparatus was sparse in these cells. On the other hand, degenerative changes were never detected in the vesicular cells which were seen to be similar in feature to those observed in the preceding period. Their characteristic cytoplasmic vesicles were relatively uniform in size, and their granular inclusions remained to be a few in number (Fig. 8).

Changes during the reproductive cycle of adult loaches

Seasonal changes of gonadal weight of loaches used in the present study were shown in Fig. 9 in which gonadal weight was expressed in terms of the gonadosomatic index (GSI: gonad weight $\times 100$/body weight). In the present study, six sequential stages (I-VI), which were composed of two successive months each, were set through the year. Cytological changes of pituitary gonadotrophs of the loach were examined in these six stages of a reproductive cycle, using adult females and males larger than 9.5 and 8.3 cm in body length, respectively.

In the stage I (January and February), females had ovaries with many oocytes in the primary yolk stage or in the yolk vesicle stage, and males had testes with a large amount of spermatozoa besides a few spermatogonia, primary spermatocytes and spermatids. In pituitaries of these fish, a considerable number of the vesicular cells were found in the PPD (Fig. 10). Their cytoplasmic

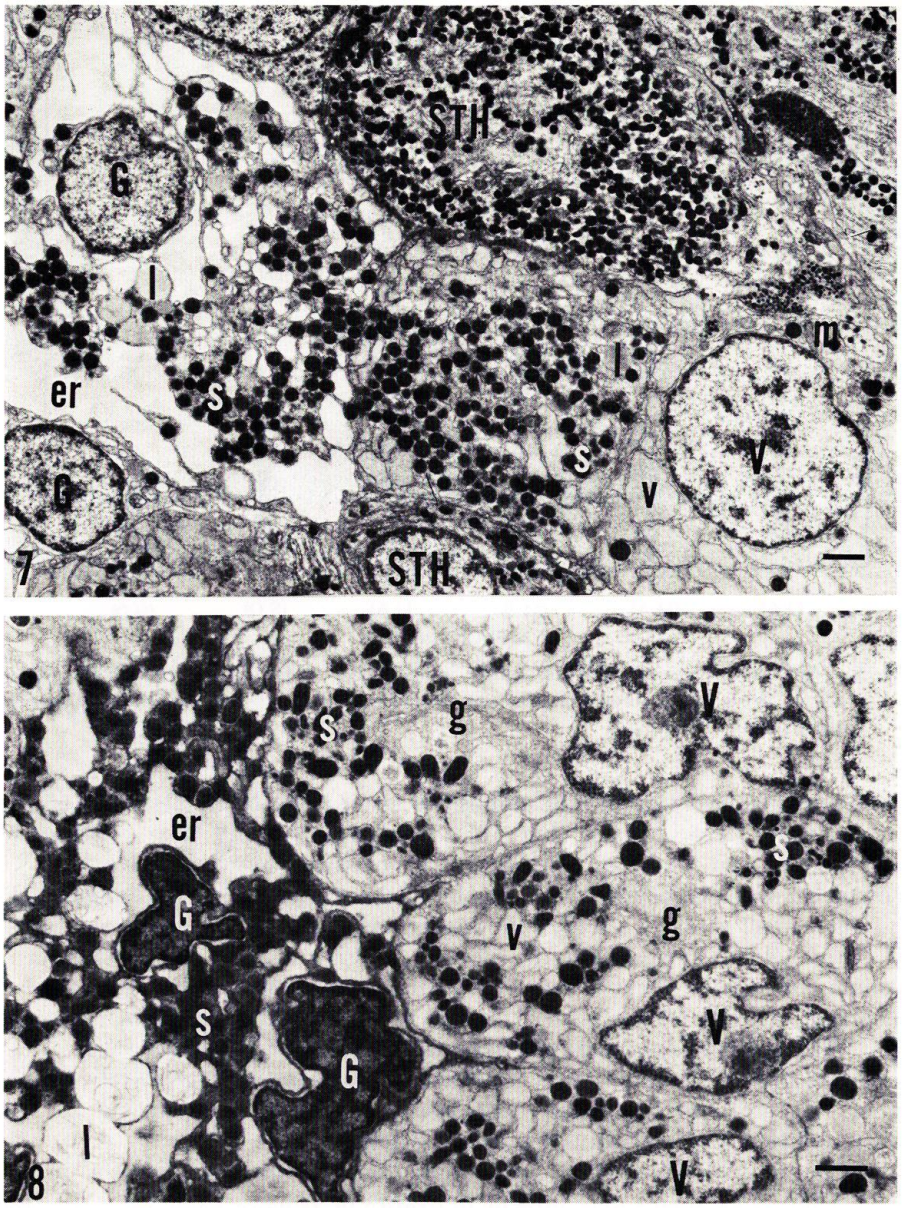

Figs. 7 and 8. Electron micrographs of globular cells (*G*) and vesicular cells (*V*) in pituitaries of a female loach having oocytes in the tertiary yolk stage (Fig. 7) and a postspawning female loach (Fig. 8). *er*, rough endoplasmic reticulum; *g*, Golgi apparatus; *l*, large globule; *m*, mitochondrion; *s*, small granule; *STH*, somatotroph; *v*, cytoplasmic vesicle. Scale, 1 μm.

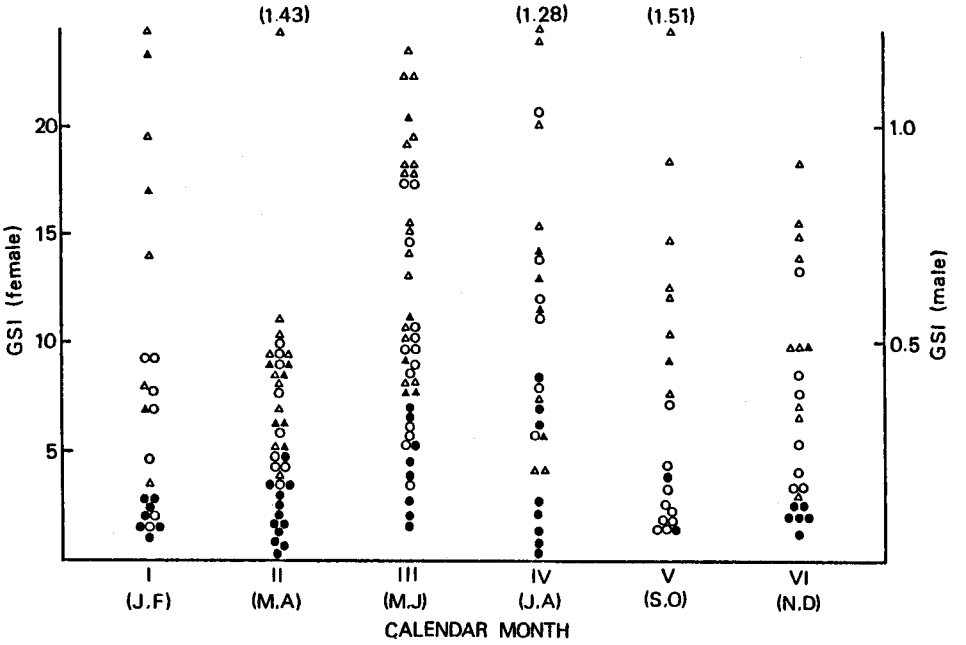

Fig. 9. Annual changes of gonadosomatic index (GSI) of female loaches above (○) or below (●) 9.5 cm in body length, and of male loaches above (△) or below (▲) 8.3 cm in body length.

vesicles were relatively small and uniform in size in females, while some of them were sometimes large in males (Fig. 16). Small granules and large globules were few in number, and the Golgi apparatus was moderately active in these cells. On the other hand, the globular cells in females of the stage I were few in number (Fig. 10). Their small granules were few in number and small in size, measuring 100–400 nm. Large globules were low in electron density. The rough endoplasmic reticulum was dilated slightly, and the Golgi apparatus was sparse in these cells. In contrast, the cells of males in this stage were observed to be in an inactive phase. The nucleus of the cells was irregular in contour and electron dense. Their granular inclusions mounted in concentrated cytoplasm were relatively small in amount. Cisternae of the rough endoplasmic reticulum were dilated to some extents, and the Golgi apparatus was scarcely detected (Fig. 16).

In the stage II (March and April), many oocytes advancing to the primary and secondary yolk stages were present in ovaries of females examined. In testes of males of this stage, spermatogonia were clearly increased in number whereas spermatozoa were reduced in amount. There was a little structural change in the vesicular cells in these fish (Fig. 11). Cytoplasmic vesicles of the cells became larger in size than before in females, while they were relatively uniform in size in males (Fig. 17). Both small granules and large globules were still small in number. The Golgi apparatus was rarely observed in the cells. On the other hand, the globular cells in females were increased slightly in number and in size to exhibit

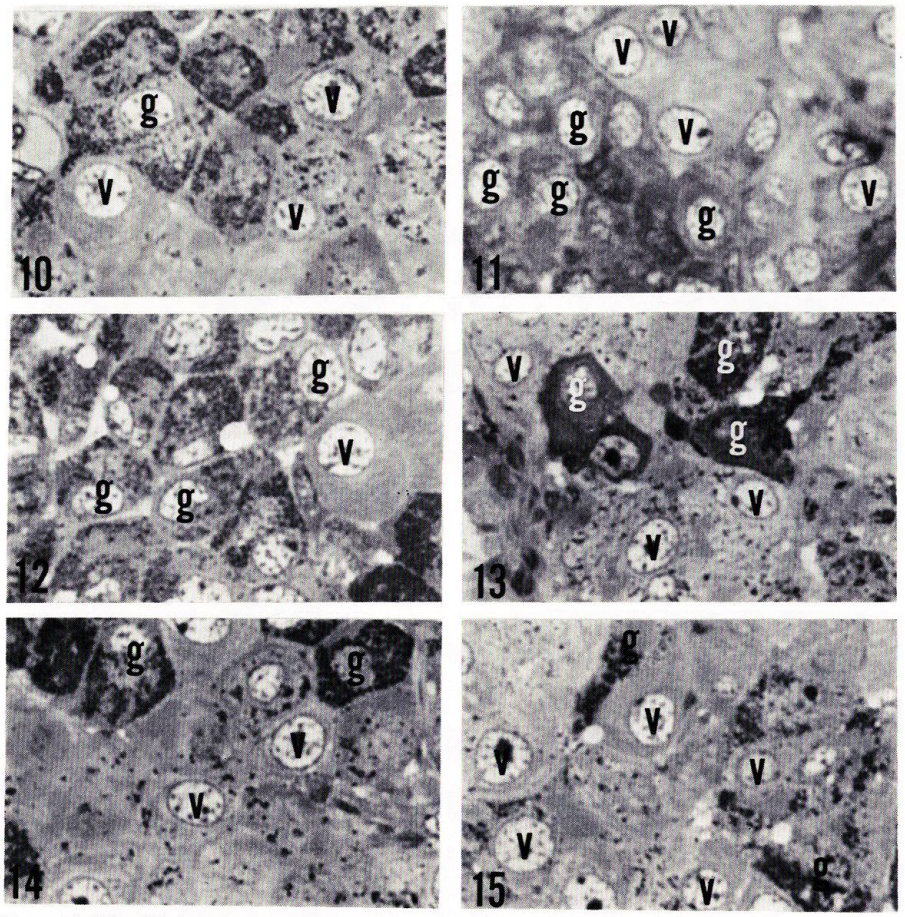

Figs. 10–15. Light microscopic pictures of Epon-embedded, methylene blue-stained sections of pituitary glands of female loaches sampled in stage I (Fig. 10), stage II (Fig. 11), stage III (Fig. 12), stage IV (Fig. 13), stage V (Fig. 14), and stage VI (Fig. 15). *g*, globular cell; *v*, vesicular cell. × 1000.

some active features (Fig. 11). The number of small granules in these cells was slightly increased, while large globules remained unchanged in number though they became more electron dense. The rough endoplasmic reticulum were composed of irregularly vesicular or flattened cisternae, and the Golgi apparatus appeared to be moderately active. The globular cells in males became loaded, in expanded and clear cytoplasm, with small granules of 100–300 nm which were much smaller in size than those in the other stages, and with large globules of 400–600 nm in size (Fig. 17). The rough endoplasmic reticulum consisted of flattened cisternae and was never dilated, and the Golgi apparatus was moderately active.

In the stage III (May and June), females had ovaries with many oocytes in the secondary and tertiary yolk stages, and males had testes containing many cysts of spermatocytes, spermatids and spermatozoa together with a decreased number of

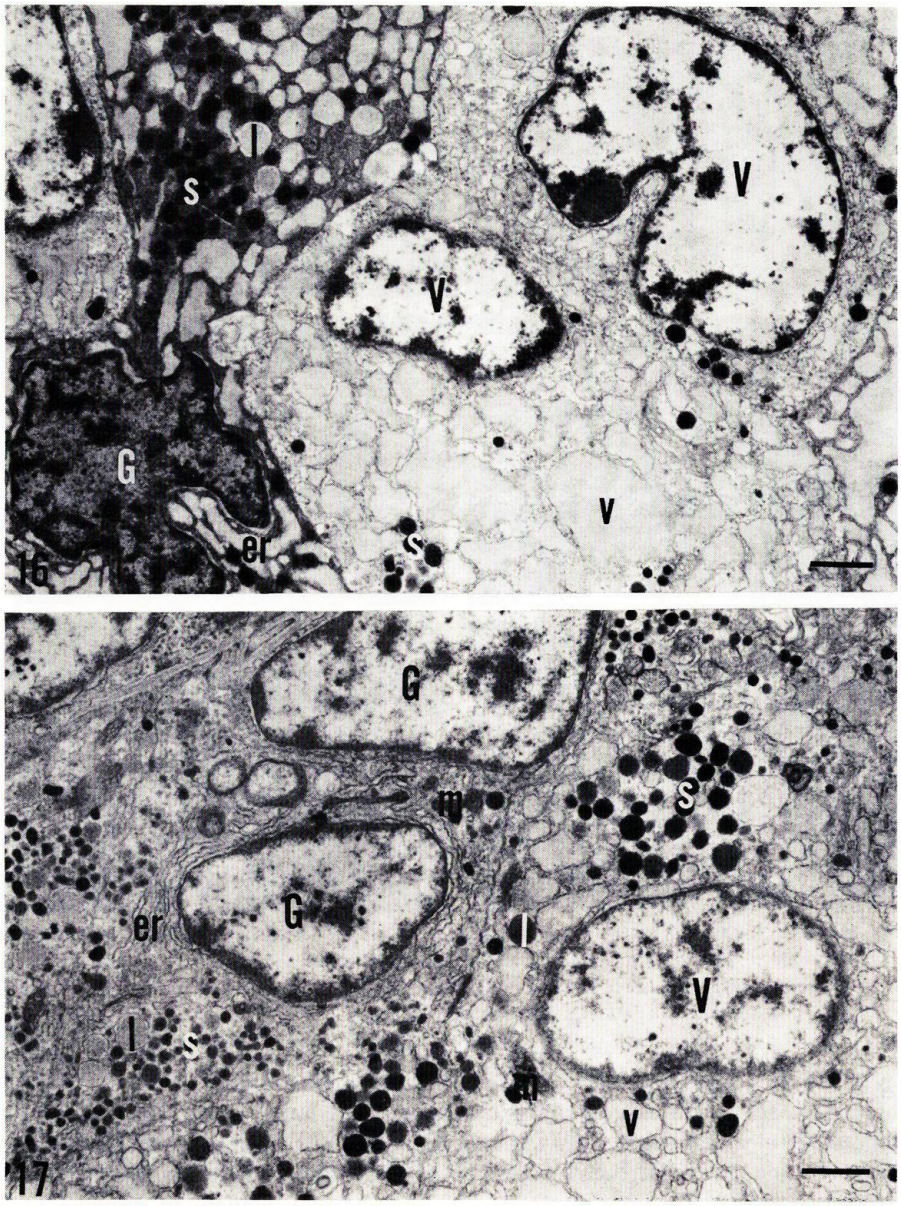

Figs. 16 and 17. Electron micrographs of globular cells (*G*) and vesicular cells (*V*) in pituitaries of male loaches sampled in stage I (Fig. 16) and stage II (Fig. 17). *er*, rough endoplasmic reticulum; *l*, large globule; *m*, mitochondrion; *s*, small granule; *v*, cytoplasmic vesicle. Scale, 1 μm.

spermatogonia. In females in this stage, the vesicular cells showed only a slight change (Fig. 12): cytoplasmic vesicles were relatively uniform but smaller in size than those in the previous stage, and the Golgi apparatus was observed to be slightly activated (Fig. 18). In males, no notable structural changes were observed in the vesicular cells. On the other hand, the globular cells in females were observed to be clearly increased in number and in size with an evident increment of their small granules (Fig. 12). Moreover, it was notable in this stage that cisternae of the rough endoplasmic reticulum of the globular cells became dilated irregularly throughout the cytoplasm. The Golgi apparatus was highly active around which immature granules appeared frequently (Fig. 18). The globular cells in males were observed to become numerous and also hypertrophied. Small granules in the cytoplasm were evidently increased in number and in size, measuring 200–500 nm in size. Large globules also became augmented in size to 600–1200 nm. Cisternae of the rough endoplasmic reticulum were not dilated but remained flat. The Golgi apparatus appeared to be highly active in feature in these cells.

In the stage IV (July and August), females and males were at the peak of their spawning period. In pituitaries of the females that had ovulated, the vesicular cells showed no notable structural changes as compared with those in the preceding stage (Fig. 13), though large globules in their cytoplasm became rarely observed and the Golgi apparatus was somewhat active in feature (Fig. 19). The vesicular cells of males also showed only a slight change in their cytoplasmic vesicles, which were mostly uniform in shape but were extraordinarily large on some occasions. On the other hand, the globular cells of ovulating females displayed remarkable changes (Fig. 13). These cells had been shrunk considerably, and their cytoplasm as well as their nucleus was quite irregular in contour and unusually electron dense. In the dark cytoplasm, large globules tended to gather in groups and small granules were clearly decreased in number. The rough endoplasmic reticulum was dilated to various extents and contained moderately electron dense material. The Golgi apparatus was obscure in these atrophied globular cells (Fig. 19). In contrast, the globular cells of spermiating males seemed to be highly active. Cisternae of their rough endoplasmic reticulum were dilated to form an irregular vacuolar system. Small granules in these cells were larger in amount than in those of the stage III. The Golgi apparatus was still active in these globular cells.

In the stage V (September and October), when breeding of the loach had almost ceased, ovaries of females had many postovulatory follicles together with many yolk-laden, atretic oocytes and yolkless oocytes, and testes of males had a large amount of spermatozoa in widely expanded lobule lumina and a small number of cysts of spermatocytes and spermatids in testicular lobules. In the pituitary gland of females, the vesicular cells were seen to be larger in size and in number than those in the previous stages (Fig. 14). The cells contained cytoplasmic vesicles which were relatively larger in size than those observed in the stage IV. Small granules in their cytoplasm existed in groups among the dilated vesicles, and large globules were few in number. The Golgi apparatus was moderately active in the cells (Fig. 20). The vesicular cells of males in the stage V were quite similar in feature to those observed in the preceding stage, except that large cytoplasmic vesicles appearing in the stage IV did not occur and small granules were somewhat increased

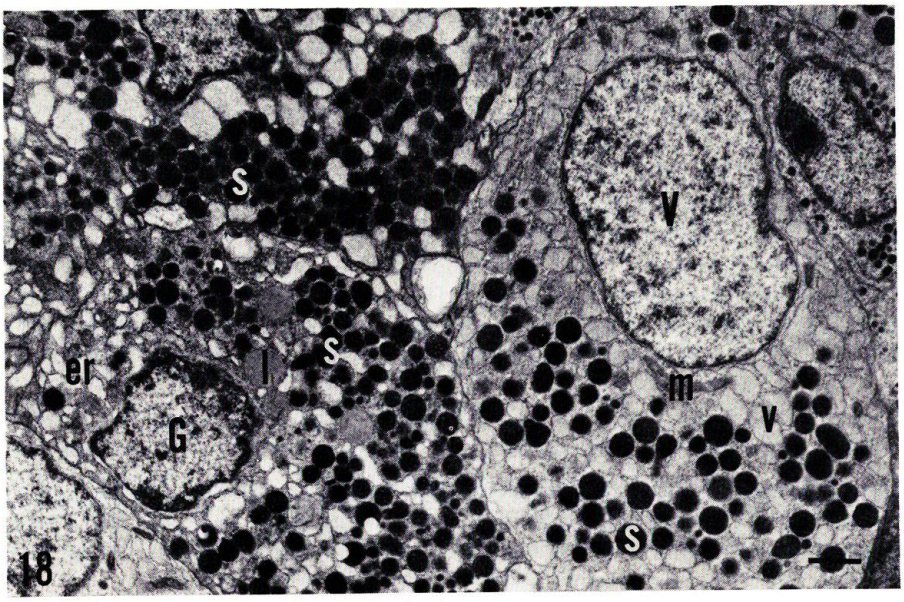

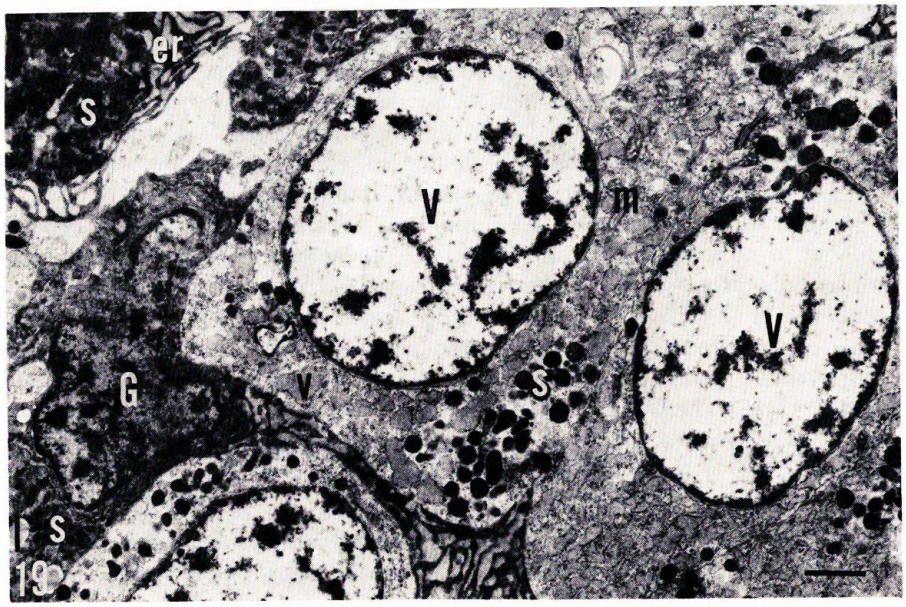

Figs. 18 and 19. Electron micrographs of globular cells (*G*) and vesicular cells (*V*) in pituitaries of female loaches sampled in stage III (Fig. 18) and stage IV (Fig. 19). *er*, rough endoplasmic reticulum; *l*, large globule; *m*, mitochondrion; *s*, small granule; *T*, thyrotroph; *v*, cytoplasmic vesicle. Scale, 1 μm.

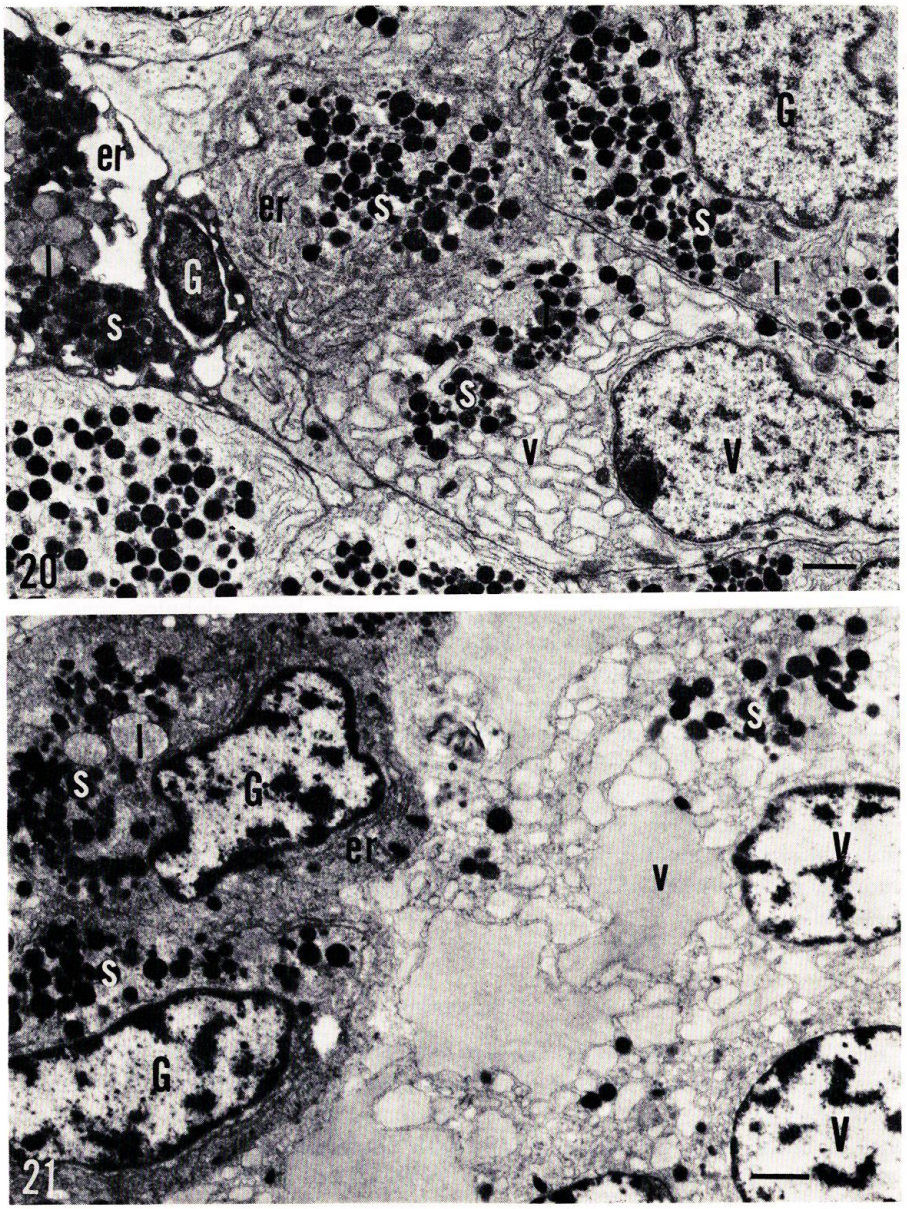

Figs. 20 and 21. Electron micrographs of globular cells (*G*) and vesicular cells (*V*) in pituitaries of female loaches sampled in stage V (Fig. 20) and stage VI (Fig. 21). *er*, rough endoplasmic reticulum; *l*, large globule; *s*, small granule; *v*, cytoplasmic vesicle. Scale, 1 μm.

in number. On the other hand, some of the globular cells of females were still in the degenerative phase in the stage IV, but others became regranulated with many small granules and a few large globules in clear cytoplasm (Figs. 14 and 20). The globular cells in males were, however, decreased prominently in size and in number, displaying some degenerative features. In their atrophied and dense cytoplasm, small granules were clearly diminished in number, and large globules were lowered in electron density. The rough endoplasmic reticulum was reduced in amount and never dilated, and the Golgi apparatus was hardly detected in the cells.

In the stage IV (November and December), ovaries of females had many oocytes in the yolk vesicle stage and some oocytes in the primary yolk stage, and testes of males had a small number of first spermatocytes, together with a few spermatogonia and many spermatozoa. The vesicular cells of females exhibited some active features (Fig. 15). Their cytoplasmic vesicles were rather uneven in size, and some of them were atypically dilated. Small granules were clearly diminished in number and large globules were scarcely detected. The Golgi apparatus was moderately active in these cells (Fig. 21). The vesicular cells in males were observed to be increased in size and in number. Their cytoplasmic vesicles were relatively uniform but slightly reduced in size. Small granules in the cytoplasm tended rather to be accumulated in groups, and large globules made their appearance in this stage. On the other hand, the globular cells of females had mostly been recovered to show distinct regranulation, though they were still few in number as those found in the stage I (Fig. 15). Small granules and large globules were few in number, and their rough endoplasmic reticulum and the Golgi apparatus were poorly developed (Fig. 21). In contrast, the globular cells of males were still in a regressed state in the stage VI. The cells were quite irregular in contour and had darkly concentrated cytoplasm. Their nucleus was very electron dense and irregular in shape. Small granules and large globules in the cytoplasm were few in number, and cisternae of the rough endoplasmic reticulum were slightly dilated in these cells.

Discussion

Results of the present study suggest that the globular and the vesicular cells in the pituitary gland of the loach have their respective gonadotropic potencies in different phases of the reproductive cycle. In the pituitary gland of young, immature loaches of both sexes, the globular cells with immature cytoplasmic granules had already existed in the central part of the PPD of the pituitary gland. Although the globular cells did not show any conspicuous changes in early stages of gonadal development, they displayed a notable increase in size and in number in harmony with progressive maturation of ovaries and testes of the loach. Moreover, they were conspicuous for a depletion of small, secretory granules, extensive dilation of the endoplasmic reticulum, and pycnotic changes of the nucleus subsequent to ovulation and spermiation. This indicates that the globular cells of the loach may secrete a gonadotropin which promotes later stages of gonadal maturation, especially at the time of ovulation and spermiation. Similar changes of

pituitary gonadotrophs of the globular type during gonadal development have been noted light microscopically in various fishes such as *Fundulus heteroclitus*[7], *Salmo gairdneri*, *Oncorhynchus tshawytscha*, *O. nerka*[8][9], *Embiotoca jacksoni*[10], *Oncorhynchus nerka*[11][12], *Oryzias latipes*[13], *Tilapia mossambica*[14], *Perca fluviatilis macedonica*[15], and *Boops salpa*[16].

On the other hand, the vesicular cells were indetectable ultrastructurally in the PPD of the pituitary gland of young loaches with ovaries at the oogonial stage or with testes at the spermatogonial stage. The cells made their first appearance in the PPD concurrently with the appearance of oocytes at the yolk vesicle stage in ovaries or of first spermatocytes in testes. They revealed little cytoplogical alterations during the period of advancing vitellogenesis and spermatogenesis, or even at the time of ovulation and spermiation which were accompanied with remarkable cytological modifications of the globular cells as described above. The vesicular cells appeared to become active a few months after the end of the spawning period, at some time before exogenous vitellogenesis in ovarian oocytes or spermatogenesis in testes had taken place, exhibiting an enlargement of cytoplasmic vesicles, a development of the Golgi apparatus and an accumulation of cytoplasmic granules. Cook and van Overbeeke[17] observed that vesicular gonadotrophs in the pituitary gland of the sockeye salmon, *Oncorhynchus nerka*, became largely degranulated near the time of full maturation when globular gonadotrophs abounded in the gland, and suggested that the vesicular gonadotrophs may have their essential gonadotropic potency in early stages of gonadal development. In the Atlantic salmon, *Salmo salar*, no vesicular gonadotrophs were detected in the pituitary gland of immature parr, and they became apparent and highly active when the gonadosomatic index was still very low[18]. Olivereau[19] has mentioned similar cytological alterations of two types of pituitary gonadotrophs in the rainbow trout, *Salmo gairdneri*, and the brown trout, *Salmo fario*, too.

Peute et al.[20] reproted that, in the rainbow trout, a predominant occurrence of pituitary gonadotrophs of the cisternal (vesicular) stage was also correlated with vitellogenesis in females and spermatocyte formation in males, though these cells were observed to be shifted into the globular stage by gradual regranulation toward the spawning season, leading to absolute predominance of cells of the globular stage. In contrast, in the loach examined in the present study and in the previous studies[3][5][6], any intermediate cell type between the two types of gonadotrophs was never detectable in the pituitary gland. This is also the case for two types of gonadotrophs of whitespotted char, *Salvelinus leucomaenis*[21]. The two gonadotropic cell types of the whitespotted char showed characteristic changes, which fairly coincided with those observed in the loach, during gonadal development.

Thus, possible explanation of the function of the vesicular cells in female fish may be that their secretion is implicated in vitellogenesis in ovarian oocytes and that, once the vitellogenesis has been initiated, its subsequent course extending over a long period of time depends only on a rather stable maintenance of synthesis and release of the vesicular cell hormone. The globular cells may also have an action on vitellogenesis, presumably through stimulation of secretion of estrogen which has been shown to increase in the blood with the advancement of vitellogenesis[22]. Precise roles played by the vesicular cells in testicular develop-

ment of male fish remain to be clarified. However, Hyder and his collaborators [23)24)25)] suggest that two pituitary hormones (a FSH-like and a LH-like hormone) may control testicular development in *Tilapia*: the FSH-like principle is probably active largely in early phases of testicular growth, while the LH-like principle probably exerts its maximal effect on the testis at the spermiation period. It is interesting to compare this suggestion given for *Tilapia* with that obtained in the present study, in terms of some possible correlation between the FSH-like activity and a function of the vesicular cells and between the LH-like activity and a function of the globular cells in male fish.

References

1) Jasiński, A. (1973). Electron microscopic study of the pars distalis of the hypophysis in the pond loach, *Misgurnus fossilis* L. *Acta anat.* **86**, 228–252.
2) Oota, Y. (1975). Electron microscopic studies on the adenohypophysis of the loach, *Misgurnus anguillicaudatus*. *Rep. Fac. Sci. Shizuoka Univ.* **10**, 87–99.
3) Ueda, H. and Takahashi, H. (1977). Promotion of ovarian maturation accompanied with ovulation and changes of pituitary gonadotrophs after ovulation in the loach, *Misgurnus anguillicaudatus*, treated with clomiphene citrate. *Bull. Fac. Fish. Hokkaido Univ.* **28**, 106–117.
4) Ueda, H. (1979). Effect of thiourea treatment on pituitary basophilic cells of the loach, *Misgurnus anguillicaudatus*. *Bull. Fac. Fish. Hokkaido Univ.* **30**, 116–123.
5) Ueda, H. and Takahashi, H. (1980). Responses of two different types of pituitary gonadotrophs of the loach, *Misgurnus anguillicaudatus*, to gonadectomy and to exogenous sex steroids. *Gen. Comp. Endocrinol.* **40**, 463–472.
6) Ueda, H. and Takahashi, H. (1981). Effect of continuous light exposure on pituitary gonadotrophs of the loach, *Misgurnus anguillicaudatus*. *Bull. Fac. Fish. Hokkaido Univ.* **32**, 107-119.
7) Sokol, H.W. (1961). Cytological changes in the teleost pituitary gland associated with the reproductive cycle. *J. Morph.* **109**, 219–236.
8) Robertson, O.H. and Wexler B.C. (1962). Histological changes in the pituitary gland of the rainbow trout (*Salmo gairdnerii*) accompanying sexual maturation and spawning. *J. Morph.* **110**, 157–170.
9) Robertson, O.H. and Wexler, B.C. (1962). Histological changes in the pituitary gland of the Pacific salmon (genus *Oncorhynchus*) accompanying sexual maturation and spawning. *J. Morph.* **110**, 171–185.
10) Lagios, M.D. (1965). Seasonal changes in the cytology of the adenohypophysis, testes, and ovaries of the black surfperch, *Embiotoca jacksoni*, a viviparous percomoph fish. *Gen. Comp. Endocrinol.* **5**, 107–221.
11) van Overbeeke, A.P. and McBride, J.R. (1967). The pituitary gland of the sockeye (*Oncorhynchus nerka*) during sexual maturation and spawning. *J. Fish. Res. Board Can.* **24**, 1791–1810.
12) Kawashima, S., Ichikawa, M., Mori, T., Ueda, K. and Shirahata, S. (1976). Histological changes in the pituitary gland of the kokanee (*Oncorhynchus nerka*) during sexual maturation and spawning. *J. Fac. Sci. Univ. Tokyo* **13**, 423–434.
13) Kasuga, S. and Takahashi, H. (1971). The preoptico-hypophysial neurosecretory system of the medaka, *Oryzias latipes*, and its changes in relation to the annual reproductive cycle under natural conditions. *Bull. Fac. Fish. Hokkaido Univ.* **21**, 259–268.
14) Sasayama, Y. and Takahashi, H. (1975). Notes on the development of the pituitary gland in *Tilapia mossambica*. *Bull. Fac. Fish. Hokkaido Univ.* **25**, 273–282.
15) Dimovska, A. (1977). Données cytologiques sur l'adénohypophyse de perche de Doïran

(*Perca fluviatilis macedonica* Kar.) dans certaines périodes du cycle sexuel. *Inv. Pesq.* **41**, 15–32.

16) Malo-Michele, M. (1978). Evolution de cellules gonadotropes de *Boops salpa* L. (téléostéen Sparidae) au cours de la spermatogenèse. *Ann. Biol. anim. Bioch. Biophys.* **18**, 911–915.

17) Cook, H. and van Overbeeke, A.P. (1972). Ultrastructure of the pituitary gland (pars distalis) in sockeye salmon (*Oncorhynchus nerka*) during gonad maturation. *Z. Zellforsch.* **130**, 338–350.

18) Olivereau, M. (1976). Les cellules gonadotropes hypophysaires du saumon de l'Atlantique: unicité ou dualité ? *Gen. Comp. Endocrinol.* **28**, 82–95.

19) Olivereau, M. (1978). Les cellules gonadotropes chez lea salmonidés. *Ann. Biol. anim. Bioch. Biophys.* **18**, 793–798.

20) Peute, J., Goos, H.J.Th., de Bruyn, M.G.A. and van Oordt, P.G.W.J. (1978). Gonadotropic cells of the rainbow trout pituitary during the annual cycle. Ultrastructure and hormone content. *Ann. Biol. anim. Bioch. Biophys.* **18**, 905–910.

21) Ueda, H. (1980). Changes of two types of pituitary gonadotrophs in whitespotted char, *Salvelinus leucomaenis*, during gonadal development. *Bull. Fac. Fish. Hokkaido Univ.* **31**, 1–15.

22) Lambert, J.G.D., Bosman, G.I.C.G.M., van den Hurk, R. and van Oordt, P.G.W.J. (1978). Annual cycle of plasma oestradiol-17β in the female trout *Salmo gairdneri*. *Ann. Biol. anim. Bioch. Biophys.* **18**, 923–927.

23) Hyder, M. (1970). Histological studies on the testes of pond specimens of *Tilapia nigra* (Günther) (Pisces: Chichlidae) and their implications of the pituitary-testis relationships. *Gen. Comp. Endocrinol.* **14**, 198–211.

24) Hyder, M., Shah, A.V., Campbell, C.M. and Dadzie, S. (1974). Methallibure studies on *Tilapia*. II. Effect of *Tilapia* pituitary homogenate (TPH), human chorionic gonadotropin (HCG) and testosterone propionate (TP) on the testes of methallibure-treated *Tilapia nigra*. *Gen. Comp. Endocrinol.* **23**, 245–255.

25) Hyder, M., Shah, A.V. and Hartree, A.S. (1979). Methallibure studies on *Tilapia*. III. Effects of tilapian partially purified pituitary gonadotrophic fractions on the testes of methallibure-treated *Sarotherodon sperulus* (=*Tilapia nigra*). *Gen. Comp. Endocrinol.* **39**, 475–480.