HOKKAIDO UNIVERSITY

Title	Induction of Autoimmune Responses to Testes in a Tilapia, Oreochromis niloticus
Author(s)	LOU, Ya-Huan; TAKAHASHI, Hiroya
Citation	北海道大學水産學部研究彙報, 38(1), 14-26
Issue Date	1987-02
Doc URL	http://hdl.handle.net/2115/23937
Type	bulletin (article)
File Information	38(1)_P14-26.pdf

Instructions for use

Hokkaido University Collection of Scholarly and Academic Papers : HUSCAP

Bull. Fac. Fish. Hokkaido Univ.
38(1), 14-26. 1987.

Induction of Autoimmune Responses to Testes in a Tilapia, *Oreochromis niloticus*

Ya-Huan LOU* and Hiroya TAKAHASHI*

Abstract

The occurrence of immune responses to allogeneic testes was studied histologically and ultrastructurally in male and female tilapias, *Oreochromis niloticus*. Intramuscular or intraperitoneal injections of mature testes of the tilapia emulsified in Freund's complete adjuvant into males with maturing testes could effectually induce testis-specific cellular immune responses. The same treatment could not cause any notable change in ovaries, and injections of the adjuvant alone failed to induce the response even in testes. The response was initially marked by the occurrence of massive infiltrations of monocytes and lymphocytes, the former predominating in number, into interspaces between seminal lobules and between efferent ducts of the affected testes. The cells further invaded into lobule lumina by rupturing the wall of efferent ducts, and actively phagocytized mature spermatozoa. Only monocytes were involved in the phagocytosis, but lymphocytes were also seen to play some role in eliminating spermatozoa. Cysts of spermatids and other spermatogenic cells were retained intact on the lobule wall. Sera from male and female tilapias, which had been injected with maturing or mature testes combined with the adjuvant, had the ability to agglutinate allogeneic spermatozoa, though the sera from immature fish treated with maturing testes seemed to be weaker in sperm agglutination titres than those from maturing fish injected with mature testes. These results were compared with those obtained to date for salmonid fishes.

It is well known that the injection of an isogeneic or allogeneic testis homogenate into mammalian animals can induce injuries of testes leading to aspermatogenesis which may be applied to the control of fertility (for review, see Bishop, 1970, and Setchell, 1982). Considering the possibility of developing an artificial induction of autoimmunity as an efficient device for the control of gonadal maturation in fish culture, Laird et al. (1978, 1980) produced for the first time some histological evidence of immune responses occurring in the gonads of Atlantic salmon, *Salmo salar*, when injected with a mixture of allogeneic testes and Freund's complete adjuvant. Using a similar approach, Secombes et al. (1985a, b, c) reported histological observations on the occurrence of definite cellular immune responses in gonads of rainbow trout, *Salmo gairdneri*, autoimmunized by allogeneic testis.

Secombes et al. (1982, 1984) first confirmed the production of sperm agglutinating antibodies in the rainbow trout in response to autoimmunization. The presence of some specific antigens on germ cells has been shown in common carp, *Cyprinus carpio*, rainbow trout and some other teleosts using monoclonal antibodies raised against carp spermatozoa (Parmentier et al., 1984, 1985). Quite recently, Secombes et al. (1986) revealed that some of the monoclonal antibodies could kill spermatozoa

* *Laboratory of Fresh-Water Fish-Culture, Faculty of Fisheries, Hokkaido University*
(北海道大学水産学部淡水増殖学講座)

of the rainbow trout and the common carp through a complement-mediated cytotoxicity, presenting a new approach for the control of gonadal maturation in fishes.

Generally speaking, immunopathological reactions seem to be ascribed to a complex interaction between humoral and cellular immunity. As to cellular autoimmune responses observed in the testes of fishes, the investigations reported thus far have been made only on the light microscopic level, and have remained somewhat obscure on the nature of induced pathological changes. Moreover, these studies have been limited mostly to salmonid species with an annual reproductive cycle.

It is the aim of the present paper to provide preliminary information about histological and ultrastructural changes caused by the treatment with allogeneic testes combined with Freund's complete adjuvant in the testes of tilapia, *Oreochromis niloticus*, which show a continuous gonadal maturation throughout the year. Furthermore, the appearance of possible sperm agglutinating antibodies in the serum of the autoimmunized fish is also dealt with in the present paper.

Before going further, we wish to express our thanks to Messrs. Fuminari Ito, Akihiro Takemura, and Kazuo Maekawa for their kind technical assistance.

Material and Methods

Immature and maturing tilapias, *Oreochromis niloticus*, of both sexes used in the present study were obtained from a fish farm in Shimamaki, Hokkaido. They were maintained in indoor concrete ponds at 18-28°C and fed a commercial diet for carp culture (Nihhai Fish Food Co.). During experiments, fish were kept in 60-liter glass aquaria with well-aerated water kept at 22±2°C under natural light conditions.

The two sets of experiments performed for the present study are described in Table 1. Allogeneic testis material was used as an antigen for immunization of the tilapia. Maturing (experiment 1) and mature (experiment 2) testes from freshly killed fish were mechanically homogenized at 3°C in a glass homogenizer with 0.7% saline to form a 50% solution of testis material. The homogenate was then

Table 1. Description of experiments for inducing autoimmunity to testes in the tilapia.

Experiment	Mean body weight of fish at start of treatment Mean±SE (g)	Number of fish treated		Material injected*	Maturity of donor testis	Number of injection (Route)**
		Male	Female			
1	10.42±2.53	3	6	Saline	Maturing	4 (i.p.)
	9.85±2.16	2	7	FCA		
	9.57±3.03	1	6	TM		
	10.43±2.60	4	9	TM+FCA		
2	14.18±3.89	4	1	TM+FCA	Mature	4 (i.p.)
	24.82±3.15	4	1	FCA		4 (i.m.)
	26.26±6.13	4	1	TM+FCA		4 (i.m.)
	26.48±4.39	3	2	TM+FCA		3 (i.m.)

* FCA, Freund's complete adjuvant; TM, testis homogenate; TM+FCA, TM combined with FCA.

** i.m., Intramuscular injection; i.p., intraperitoneal injection.

emulsified in an equal volume of Freund's complete adjuvant (FCA). Each fish to be immunized received 3-4 intraperitoneal or intramuscular injections of testis material emulsified in FCA (TM+FCA) at a dosage of 2.5 μl per g body weight at intervals of one week. A group of fish in experiment 1 received injections of testis material alone at a dosage of 1.25 μl per g body weight. Some other groups of fish in each experiment were injected with saline or FCA and served as controls.

Eight weeks after the first injection, fish were bled under light anesthesia with ethyl 4-aminobenzoate for measuring antibody titres of the serum, and their gonads and some other peritoneal organs (spleen, liver, pancreas, and mesentery) were fixed in Bouin's fluid for light microscopic examination. Serial paraffin sections of the specimens were cut at 5 μm in thickness and stained with hematoxylin and eosin. The median portion of each testis was usually selected for histological examinations, and the maturity of testes was determined according to the criteria proposed by Hyder (1969) for tilapia testes.

Small pieces of each testis were also processed for electron microscopy. The tissues were fixed with 2.5% glutaraldehyde-4% paraformaldehyde mixture in 0.1 M cacodylate buffer (pH 7.2) at room temperature for 2-4 h, rinsed in the same buffer overnight at 4°C, then postfixed in 1% OsO_4 solution in 0.1 M cacodylate buffer for 2 h and embedded in Epon. Ultrathin sections of the testis were cut with glass knives on a Porter-Blum MT-1 ultramicrotome, stained with uranyl acetate and lead citrate, and observed with a Hitachi H-300 electron microscope. Parallel 1 μm sections of the specimens stained with methylene blue for light microscopy were used for the orientation of affected tissues.

Blood samples were collected with a syringe from the caudal vein in most fish and by amputating the caudal peduncle in others. The serum was isolated by centrifugation at 1,500 g for 15 min, and stored at −40°C until use. A sperm agglutination test was made according to the method described by Secombes et al. (1982, 1984). For the test, serum was decomplemented at 50°C for 30 min, and was serially diluted in Baker's phosphate-buffered saline (PBS) to get a volume of 25 μl for each sample in microtitre plates. An equal volume of fresh allogeneic tilapia spermatozoa adjusted to $2.8\text{-}3.6\times10^7$ cell/ml PBS was added to each well of the plate. After being incubated at room temperature for 3 h, microtitre plates were kept at 4°C overnight to settle the spermatozoa. Sperm agglutination titres (SAT) were determined by calculating $SAT=-\log_2 X$, where X was the dilution of serum at which sperm agglutination could not be detected. Controls for the agglutination test included saline and normal sera under the same conditions as described above.

Results

Histology

Only in the fish which received intraperitoneal injections of Freund's complete adjuvant (FCA) alone, many whitish globate structures of various sizes were present, adhering to the surface of various peritoneal organs, particularly the mesentery, the liver and the gonad. These globate structures appeared to be unabsorbed liquid paraffin of FCA enclosed in a thin capsule of connective tissue (Fig. 1). Following intraperitoneal injections of FCA, with or without testis material (TM), some regions of the surface of the mesentery, peritoneum and some visceral organs of the treated

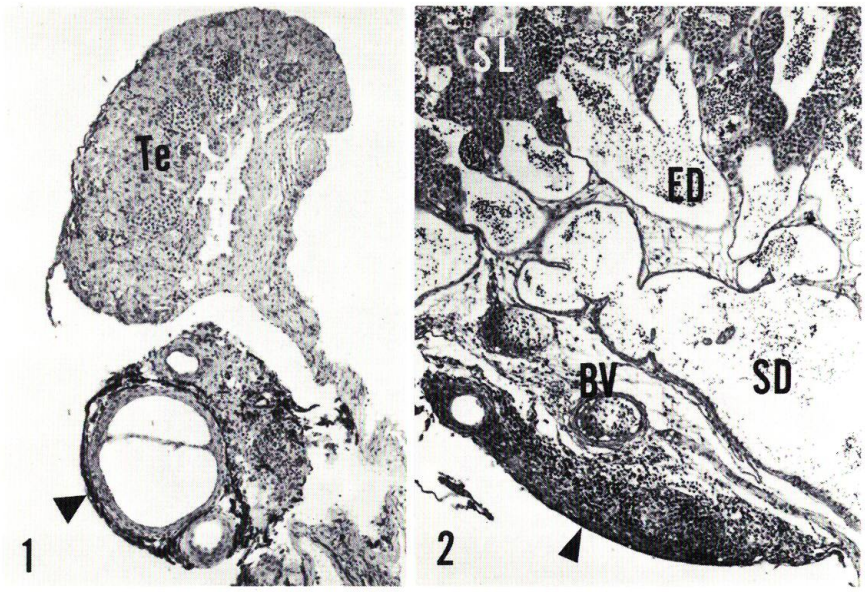

Fig. 1. A globate structure (arrow head) occurring on the mesorchium of an FCA-injected fish. Note the testis (*Te*) retaining normal structure. ×75.

Fig. 2. An aggregation of cells (arrow head) on the testis capsule of an FCA-injected fish. *BV*, blood vessel ; *ED*, efferent duct ; *SD*, main sperm duct. ×85.

fish became coarse and were extensively darkened in appearance. These regions were composed of dense aggregations of small cells deeply stained with hematoxylin. Although the clusters of cells were seen to enclose visceral organs, they did not infiltrate deep into the tissues, thus leaving organ parenchyma unaffected (Fig. 2). In contrast, intramuscular injections of FCA resulted in the formation of neither the globate structures nor the non-infiltrative cell clusters on the surface of visceral organs of treated fish, though they caused an extensive necrosis of muscle tissues at the site of injections.

At the time of autopsy, 2 males used in experiment 1 had immature testes with only spermatogonia and spermatocytes in seminal lobules, being in stage II of Hyder (1969), while 2 others had developing testes which contained a few spermatozoa in lobule lumina (stage III). In experiment 2, all males had testes in stage III, with a much larger amount of spermatozoa than the maturing males in experiment 1.

Gonads of immature fish in experiment 1 showed no changes other than the appearance of non-infiltrative cell clusters along their periphery, whether the fish were injected with FCA alone or with maturing testis material combined with FCA (TM+FCA). The fish injected with TM alone also had no notable changes in their gonads.

In experiment 2, 2 out of 4 immature and all 11 maturing males showed inflammatory responses of various forms in their testes, when injected with mature TM+FCA intramuscularly or intraperitoneally. Cell infiltrations were commonly observed in these immunized testes. The cells infiltrating into testicular tissue were much smaller in size and deeply stained by hematoxylin, which made it possible to

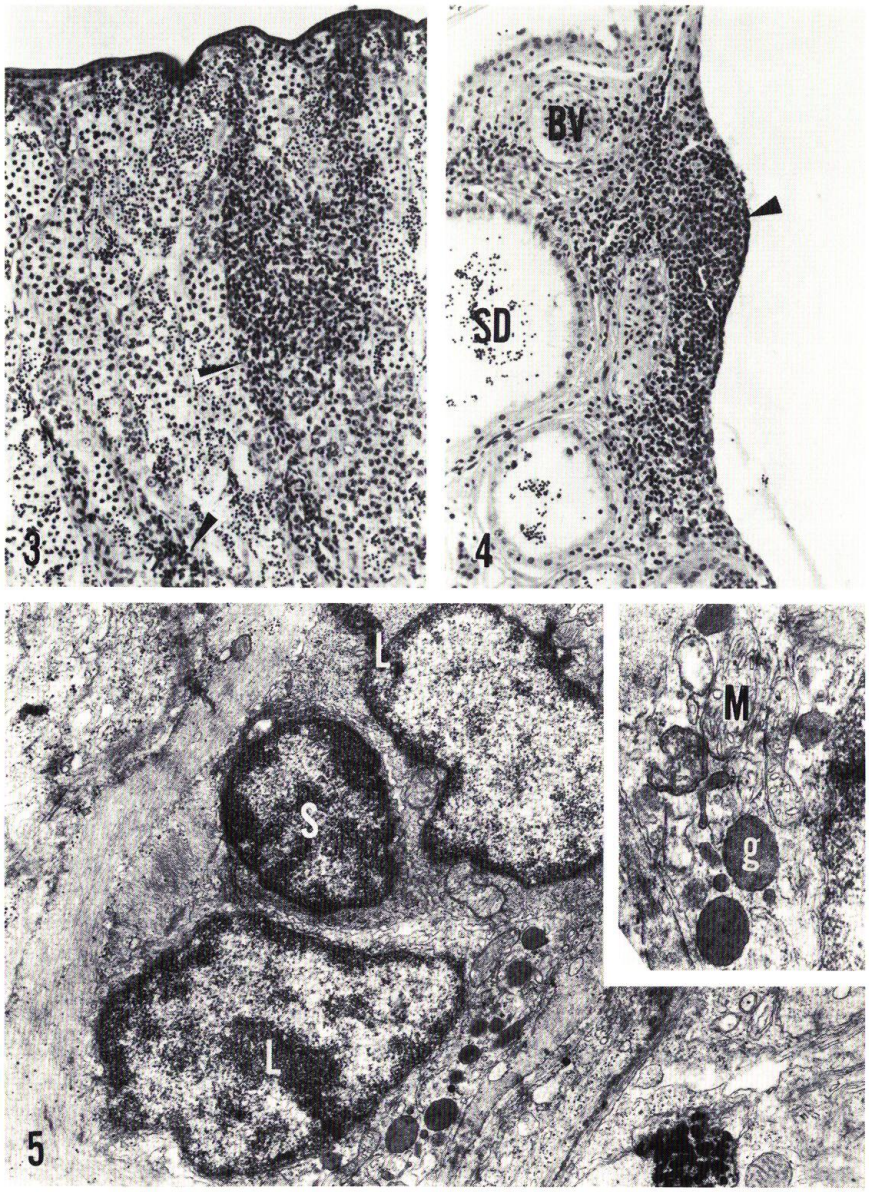

Figs. 3 and 4. Cellular infiltrations (arrow heads) developing in interspaces between seminal lobules (Fig. 3) and between the testis capsule and the main sperm duct (Fig. 4, *SD*) of a TM+FCA-injected fish. *BV*, blood vessel. ×150.

Fig. 5. Electronmicrograph of large cells (*L*) and a small cell (*S*) consisting of an infiltrative tissue found in a TM+FCA-injected fish. ×10,600. Inset: electronmicrograph showing cytoplasmic organelles and inclusions of a large cell. *g*, Granule; *M*, mitochondrion. × 19,900.

distinguish them from adjacent normal tissues even by light microscopic observations under a low magnification. The cell infiltrations were found mostly in the testicular interstitium. They were commonly seen to exist in interspaces between seminal lobules, and extended some cell streams through narrow spaces between the basement membranes of adjacent seminal lobules (Fig. 3). They could sometimes be seen to gather in a colony occupying a large space, appearing between squeezed seminal lobules. Leydig cells were occasionally seen to be surrounded by the infiltrating cells, but appeared to be left unchanged after the infiltration. In some cases, cell infiltrations of a tumor-shape were located near the blood vessels running along the testicular hilus (Fig. 4). The infiltration of this type was very similar in appearance to the non-infiltrative cell cluster described before (Fig. 2), but the former was definitely infiltrative. In some other cases, cell infiltrations, which seemed to play an important role in achieving an invasion of cells into lobule lumen, were observed to be in proximity to the seminal lobules.

Ultrastructurally, all the infiltrations consisted of cells of larger and smaller sizes (Fig. 5). The large cells, which were the dominating cell type of the infiltration, were about 4 μm in diameter, with an oval nucleus and abundant cytoplasm containing numerous electron-dense granules of various sizes, and were identified as monocytes (Fig. 5). The membrane-bound granules usually grouped at one pole of the cell with one or two of them being very large in size (inset in Fig. 5). Many mitochondria with enlarged cristae and clear matrix, and moderately

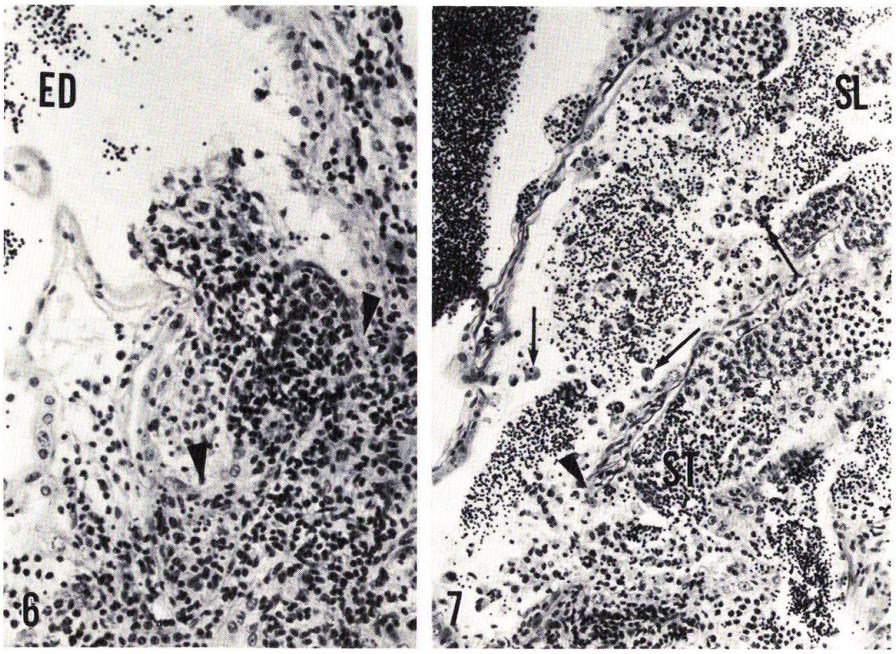

Figs. 6 and 7. Invasion of immune cells into the lumen of efferent duct (*ED*) and seminal lobule (*SL*) through ruptured wall (arrow heads) of the efferent ducts in the testis of a mature TM+FCA-injected fish. Arrows in Fig. 7 show macrophages ingesting spermatozoa. *ST*, cyst of spermatids. Fig. 6, ×260 ; Fig. 7, ×180.

developed rough endoplasmic reticulum were also present in the cells. In comparison, the small cells, 2.5 μm in diameter, had scanty cytoplasm and a round, heterogeneous nucleus with dense chromatin, and were observed to be lymphocytes. There were only a few mitochondria and ill-developed rough endoplasmic reticulum in their cytoplasm.

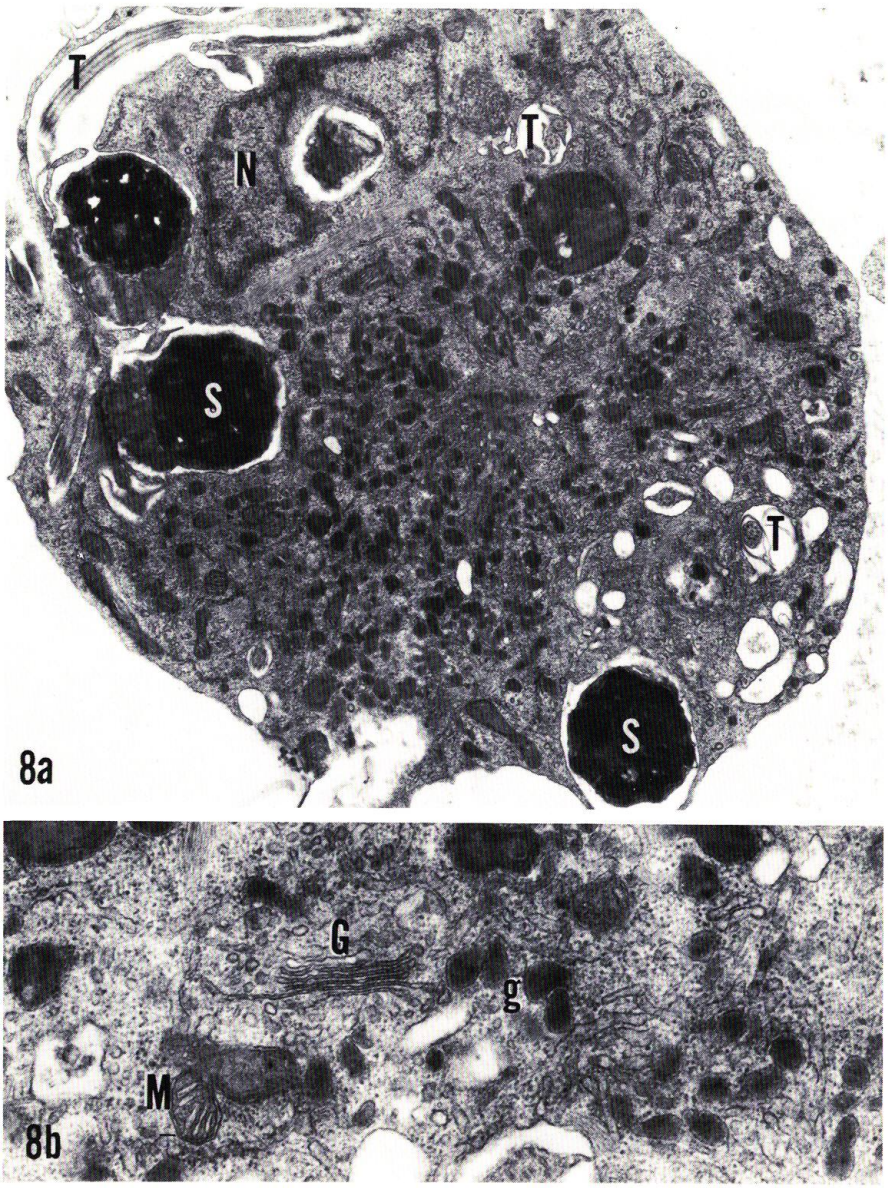

Fig. 8. Electronmicrographs of a monocyte-line macrophage (a) and its cytoplasmic organelles and inclusions (b). *G*, Golgi apparatus; *g*, membrane-bound granule; *M*, mitochondrion; *N*, nucleus; *S*, sperm head; *T*, sperm tail. a, ×9,600; b, ×24,700.

Some immunized fish were subjected to very strong pathological effects on the testes, in which immune cells extensively invaded efferent ducts and associated seminal lobules. The invasion was highly localized and appeared to originate from the cell infiltrations occurring between the efferent ducts (Fig. 6). In the region where the cell invasion was evident, the wall of the efferent ducts had lost its normal structure and a large number of cells, mainly monocytes, were invading in clusters through the ruptured wall into the duct lumen filled with mature spermatozoa. They further spread into the neighbouring efferent ducts by destroying the wall or, on limited occasions, by passing through holes which perforated the wall (Fig. 7). In the duct lumen, the cells had enlarged cytoplasm and were dispersed among spermatozoa, many of them containing sperm heads in their cytoplasm. The phagocytosis was restricted to mature spermatozoa in the lumen, and other spermatogenic cells in cysts were observed to remain intact. In some cases the phagocytosis of spermatozoa was so extensive as to make the seminal lobules almost completely devoid of spermatozoa.

The invading cells had a kidney-shaped or lobated nucleus in an eccentric position, and were characterized by having numerous electron-dense granules of various sizes and well-developed Golgi apparatus in their cytoplasm (Fig. 8a, b). They were ultrastructurally similar to the large cells composing the infiltrative tissue, indicating that they were monocytes at some developmental stage. They had many small vacuoles along the periphery of the cytoplasm, and stretched many ruffles and pseudopods from the cell surface to the outside. Heads and tails of spermatozoa at various stages of disintegration were found packed in their cytoplasm. Two types of cells of smaller sizes were also observed to have entered the lumen of efferent ducts and seminal lobules. One type of cell had a round, heterogeneous nucleus and scanty cytoplasm in which a few mitochondria with dense matrix, a few cisternae of rough endoplasmic reticulum and a few small granules were present; their ultrastructural features were quite similar to lymphocytes (Fig. 9a). They were variable in shape and always projected some pseudopods (Fig. 9b). They did not seem to phagocytize spermatozoa but were often seen to come into contact with the latter. The other type of cell was round or oval in shape and had a nucleus with one or two prominent nucleoli. Cytoplasmic processes of any form were not observed to have developed from the cells. Mitochondria, with a less dense matrix, in the perinuclear region and some small vacuoles along the periphery were observed in rather scanty cytoplasm. It was interesting to note that, around these cells, some dead spermatozoa with swollen nuclei were seen (Fig. 10).

Inflammatory responses were not observed in the control fish, with the exception of one male in which a slight cellular infiltration was observed to have occurred between seminal lobules in the testis following injections of FCA alone. Also, no notable changes were detected light microscopically in the ovary of all female tilapias in both the experimental and control groups.

Antibody titres

A quality test for agglutination of allogeneic spermatozoa was done with sera from immunized fish. Three to five min after spermatozoa were mixed with the serum from immunized fish in a well of the microtitre plate, the spermatozoa began

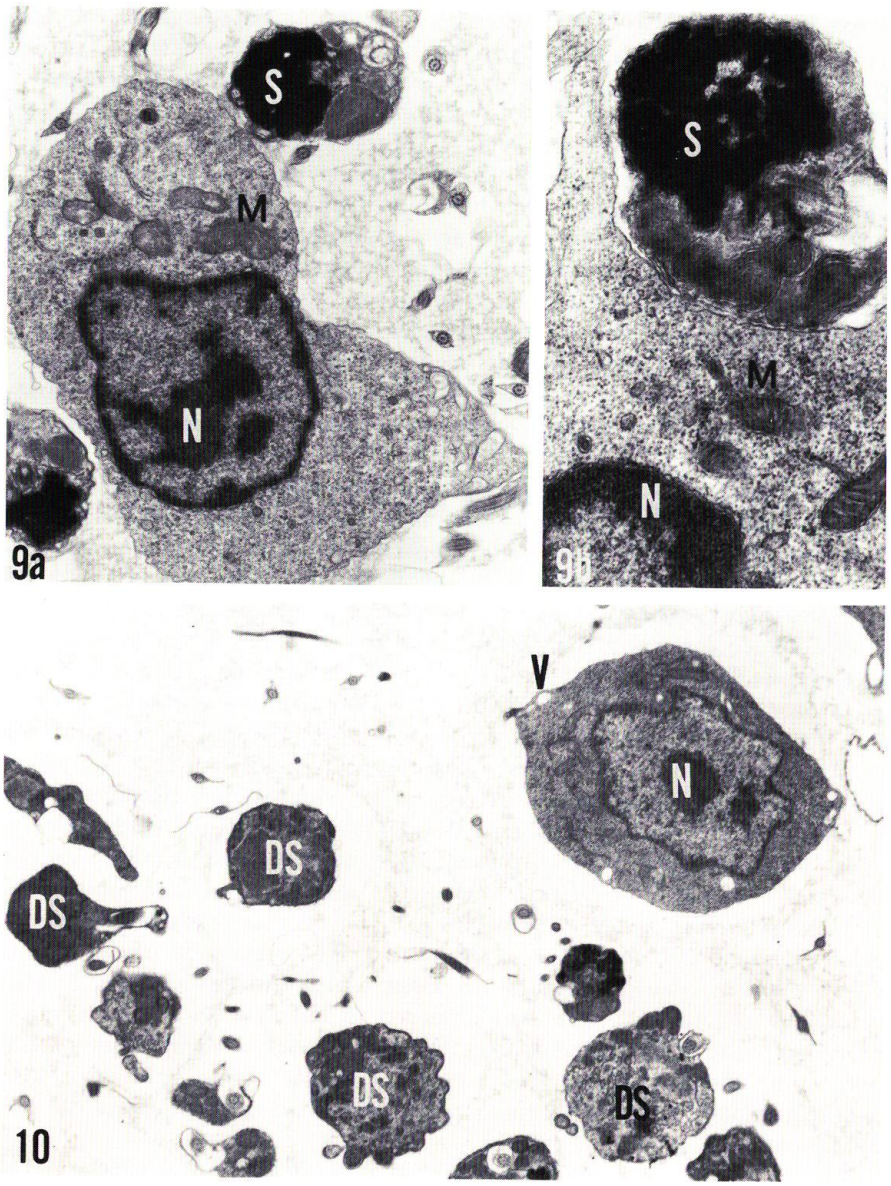

Fig. 9a, b. Electronmicrographs of lymphocytes of the first type invading the lumen of efferent ducts, revealing their direct contact with spermatozoa (*S*). *M*, mitochondrion; *N*, nucleus. a, ×7,400; b, ×20,000.

Fig. 10. Electronmicrograph of a lymphocyte of the second type. Note the presence of small vacuoles (*V*) along the peripheral region of the cell, and the occurrence of dead spermatozoa (*DS*) around the cell. ×5,700.

Table 2. Mean sperm agglutination titres of the sera from the tilapia injected 4 times intraperitoneally with saline, Freund's complete adjuvant (FCA), testis homogenate (TM), and TM emulsified in FCA (TM+FCA) in experiment 1.

Sex of fish treated	Material injected			
	Saline	FCA	TM	TM+FCA
Male	<1.0	<1.0	2	3.4±1.25
Female	<1.0	<1.0	1.75±0.46	2.6±2.25

Table 3. Mean sperm agglutination titres of the sera from the tilapia injected with Freund's complete adjuvant (FCA) alone or in combination with testis homogenate (TM+FCA).

Sex and maturity of fish treated		Meterial injected and number of injection (Route)*			
		FCA 4 (i.m.)	TM+FCA 4 (i.m.)	TM+FCA 3 (i.m.)	TM+FCA 4 (i.p.)
Male	Immature (Stage II)	—	—	—	6.5±0.68
	Maturing (Stage III)	<1.0	7.2±1.15	6.9±1.09	—
Female		<1.0	6	4.0±1.0	6

i.m., Intramuscular injection; i.p., intraperitoneal injection.

to agglutinate and then formed a network-like mass which could be detected even by the naked eye 2-3 h later. Serum antibody titres for sperm agglutination in experiments 1 and 2 are shown in Tables 2 and 3, respectively.

In experiment 1, the sera from the fish immunized by injections of maturing TM+FCA or maturing TM alone showed low, but significant, sperm agglutination titres, though injections of TM alone only caused relatively low titres. The sera from saline- or FCA-injected control fish showed no titres for sperm agglutination.

In experiment 2, all of the fish immunized by injections of mature TM+FCA showed high sperm agglutination titres in their sera, irrespective of the routes of injections. The titres for immature males in experiment 2, some of which attained a value as high as 8, were much higher than those for immature fish immunized with maturing TM+FCA in experiment 1. Maturing males which received 3 and 4 intramuscular injections of mature TM+FCA similarly had high sperm agglutination titres without showing any significant differences between them. The titres in the immunized males seemed to be slightly higher than those in immunized females. Sperm agglutination could hardly be caused by the sera from the fish injected with FCA alone.

Discussion

Results of the present study clearly show that when mature testes of tilapia, *Oreochromis niloticus*, emulsified in Freund's complete adjvant (mature TM+FCA),

are injected intraperitoneally or intramuscularly into maturing male tilapia 3 to 4 times, at intervals of one week, it successfully results in the production of sperm agglutinating antibodies in the blood as well as the occurrence of cellular immune responses that are apparently testis-specific. Intraperitoneal injections of FCA alone caused dense aggregations of cells on the surface of visceral organs, including the testes, but the aggregated cells did not appear to have infiltrated the organs. In addition, such cells did not appear on the visceral organs following intramuscular injections of FCA, suggesting that they were nothing but a result of an inflammation of the epithelial tissue of visceral organs against foreign bodies such as the killed bacteria contained in FCA, as suggested by Secombes et al. (1985a). Furthermore, in contrast to the results obtained by Secombes et al. (1985b) in rainbow trout, *Salmo gairdneri*, intraperitoneal injections of FCA alone in the present study did not result in the production of anti-sperm antibodies in the tilapia. These facts may indicate that injection of FCA alone cannot lead to a testis-specific autoimmunity, at least in the tilapia.

In the present study, there was a massive invasion of monocytes and lymphocytes into the lumen of efferent ducts and seminal lobules of the testes of immunized tilapias. A large number of macrophages of monocyte line, defined from their ultrastructural aspects, were present in the lumen and were seen to actively ingest mature spermatozoa. Similar results were reported by Secombes et al. (1985a) in mature male rainbow trout which received injections of mature or maturing allogeneic testes emulsified in FCA. The cellular immune responses observed in the tilapia seemed to be less prominent than those in the rainbow trout, notwithstanding that the experiments on the tilapia were carried out at a higher water temperature than that on the rainbow trout. This was also reflected by the fact that ovaries of female tilapias completely failed to respond to the treatment with mature TM+FCA in the present study. In Atlantic salmon, *Salmo salar*, (Laird et al., 1980) and the rainbow trout (Secombes et al., 1985), ovaries of female fish also showed mild but definite pathological changes in response to immunization.

Secombes et al. (1985c) described autoimmunologically induced giant cell granulomas appearing in seminal lobules and sperm duct in the testes of rainbow trout several months after immunization. It seems likely that clusters of macrophages in the lumen of efferent ducts and seminal lobules of immunized tilapias observed in the present study may eventually form such granulomas as a long-term effect of autoimmunization. It has been shown in the Atlantic salmon that a granuloma initially formed on the testicular capsule of immunized fish represented a cellular autoimmune response occurring in the testis, and that immune cells that later invaded testicular tissues originated from the granuloma (Laird et al., 1980). Such was not the case for the tilapia observed in the present study. In the tilapia, immune cells first appeared and clustered in the region adjoining blood vessels beneath the testis capsule, then deeply infiltrated the interspaces between seminal lobules and between efferent ducts. Invasion of the lumen of seminal lobules by these cells occurred invariably through the wall of efferent ducts; the wall of seminal lobules themselves being always retained intact. Secombes et al. (1985b) observed that, in the rainbow trout immunized by allogeneic testes, an invasion of mononuclear cells into the lumen of seminal lobules followed a thickening of the lobule wall. They also observed that spermatids as well as spermatozoa were phagocytized by the

cells invading the lobule. In the tilapia, however, phagocytosis by invaded macrophages was restricted to free spermatozoa, and cysts of spermatids on the lobule wall were always observed to be normal.

Cells with ultrastructural characteristics of lymphocytes were also seen to invade through efferent ducts into seminal lobules of the testes in immunized tilapias, though they were much less in number in the lobule lumen than the monocyte-line macrophages. The lymphocytes may play a role in eliminating spermatozoa from the seminal lobule, for they might possibly secrete a kind of cytotoxin to kill the spermatozoa existing near these cells.

In the present study, possible antibodies capable of agglutinating allogeneic spermatozoa could be detected in high titres in the sera of the tilapia showing clear cellular immune responses to TM+FCA. No significant differences were found in the sperm agglutination titres whether the injection of TM+FCA was done intramuscularly or intraperitoneally. A similar finding has been reported for autoimmunization of the rainbow trout (Secombes et al., 1982, 1985a, b). It has also been shown that, in the rainbow trout, the induced antibodies could agglutinate autologous spermatozoa (Secombes et al., 1985a). It is generally said that immunopathological reactions are ascribed to a complex interaction between humoral and cellular immunity. There was, however, no correlation between the titre of sperm agglutinating antibodies and the degree of cellular responses to TM+FCA in the testes of the tilapia.

It is interesting to note in this context that, while the male tilapias used in experiment 1 of the present study had evident sperm agglutinating titres in their sera in response to TM+FCA, they showed no development of infiltrative tissues in their testes. In this case the antibody titres were apparently lower than those measured for the fish used in experiment 2, possibly due to low maturity (stage III) of the donor testes in which only a small amount of spermatozoa was present. Also in the rainbow trout, an injection of maturing testis material induced significantly lower titres of sperm agglutination than that of mature testis material (Secombes et al., 1985b). Moreover, the treated males in experiment 1 were quite low in maturity, with only a few spermatozoa in their testes at the time of autopsy. Similar conditions of testicular maturation were found in 2 males in experiment 2 in which no obvious histological and ultrastructural changes occurred in the testes following immunization. The maturity of testes of the fish to be treated is evidently of decisive importance in the induction of immune responses to testes, at least in the tilapia used in the present study.

The development of a blood-testis barrier in the testis of some teleost fishes has been confirmed cytochemically and ultrastructurally (Abraham et al., 1980; Marcaillou and Szöllösi, 1980; Parmentier et al., 1985), and its significance in the establishment of autoimmunity in fishes has also been discussed (Secombes et al., 1985b). Series of long-term experiments using the tilapia at different stages of sexual maturity are now being carried out in our laboratory with these considerations in mind.

References

Abraham, M., Rahamim, E., Tibika, H. and Golenser, E. (1980). The blood-testis barrier in

Aphanius dispar (Teleostei). *Cell Tissue Res.* **211**, 207-214.

Bishop, D.W. (1970). Immunological responses of the testis. p. 41-66. In Johnson, A.D., Gomes, W. R. and Vandemark N.L. (eds.), *The Testis*, Vol. 3. 596p. Academic Press, New York.

Hyder, M. (1969). Histological studies on the testis of *Tilapia leucosticta* and other species of the genus *Tilapia* (Pisces: Teleostei). *Trans. Amer. Microsc. Soc.* **88**, 211-231.

Laird, L.M., Ellis, A.E., Wilson, A.R. and Holliday, F.G.T. (1978). The development of the gonadal and immune systems in the Atlantic salmon (*salmo salar* L.) and a consideration of the possibility of inducing autoimmune destruction of the testis. *Ann. Biol. anim. Bioch. Biophys.* **18**, 1101-1106.

Laird, L.M., Wilson, A.R. and Holliday, F.G.T. (1980). Field trials of a method of induction of autoimmune gonad rejection in Atlantic salmon (*Salmon salar* L.). *Reprod. Nutr. Dévelop.* **20**, 1781-1788.

Marcaillou, C. and Szöllösi, A. (1980). The "blood-testis" barrier in a nematode and a fish: a generalizable concept. *J. Ultrastruct. Res.* **70**, 128-136.

Parmentier, H.K., Timmermans, L.P.M. and Egberts, E. (1984). Monoclonal antibodies against spermatozoa of the common carp (*Cyprinus carpio* L.) I. A study of germ cell antigens in adult males and females. *Cell Tissue Res.* **236**, 99-105.

Parmentier, H.K., van den Boogaart, J.G.M. and Timmermans, L.P.M. (1985). Physiological compartmentation in gonadal tissue of the common carp (*Cyprinus carpio* L.). A study with horseradish peroxidase and monoclonal antibodies. *Cell Tessue Res.* **242**, 75-81.

Secombes, C.J., Laird, L.M. and Priede, I.G. (1982). Fish sterilisation: the autoimmune approach. p. 81. In Richter, C.J.J. and Goos, H.J.Th. (eds.), *Reproductive Physiology of Fish*. 256p. Pudoc, Wageningen.

Secombes, C.J., Lewis, A.E., Laird, L.M., Needham, E.A. and Priede, I.G. (1984). Agglutination of spermatozoa by autoantibodies in the rainbow trout, *Salmo gairdneri*. *J. Fish Biol.* **25**, 691-696.

Secombes, C.J., Lewis, A.E., Laird, L.M., Needham, E.A. and Priede, I.G. (1985a). Experimentally induced immune reactions to gonad in rainbow trout (*Salmo gairdneri*). p. 343-355. In Manning, M.J. and Tatner, M.F. (eds.), *Fish Immunology*. 374p. Academic Press, London.

Secombes, C.J., Lewis, A.E., Needham, E.A., Laird, L.M. and Priede, I.G. (1985b). Appearance of autoantigens during gonad maturation in the rainbow trout (*Salmo gairdneri*). *J. Exp. Zool.* **233**, 425-431.

Secombes, C.J., Needham, E.A., Laird, L.M., Lewis, A.E. and Priede, I.G. (1985c). The long-term effects of auto-immunologically induced granulomas on the testes of rainbow trout, *Salmo gairdneri*. *J. Fish Biol.* **26**, 483-489.

Secombes, C.J., van Winkoop, A., van den Boogaart, J.G.M., Timmermans, L.P.M. and Priede, I.G. (1986). Immunological approaches to control maturation in fish. 1. Cytotoxic reactions against germ cells using monoclonal antibodies. *Aquaculture* **52**, 125-135.

Setchell, B.P. (1982). Spermatogenesis and spermatozoa. p. 63-101. In Austin, C.R. and Short, R. V. (eds.), *Reproduction in Mammals*, Vol. 1. 177 p. Cambridge Univ. Press, London.