



Title	STUDIES ON SEXUALITY OF AMPHIBIA : I. Transplantation of Testis in a Newt, <i>Triturus pyrrhogaster</i> (BOIE) (With 3 Text-figures and 5 Plates)
Author(s)	UCHIDA, Tohru
Citation	北海道帝國大學理學部紀要, 4(4), 231-253
Issue Date	1935-12
Doc URL	http://hdl.handle.net/2115/26989
Type	bulletin (article)
File Information	4(4)_P231-253.pdf



[Instructions for use](#)

STUDIES ON SEXUALITY OF AMPHIBIA

I. Transplantation of Testis in a Newt, *Triturus pyrrhogaster* (BOIE)¹⁾

BY

Tohru UCHIDA

Zoological Institute, Faculty of Science,
Hokkaido Imperial University

(With 3 Text-figures and 5 Plates)

It was MEYNS' finding (1910 & 1912), that in transplanted testicular fragments of *Rana temporaria* on the castrated males ova were frequently found inside as well as between the seminiferous tubules. As reported in the writer's previous paper, this finding has been confirmed by the following investigators also even in homoplastic transplants in castrated females of other Amphibians; PONSE (1924) for *Bufo vulgaris*, WELTI (1928) for *Bufo vulgaris*, De BEAUMONT (1929) for *Triturus cristatus* and also in 1932 in a heteroplastic graft of *T. vulgaris* on a castrated female of *T. cristatus*, and recently by BECCARI (1933) for *T. cristatus*. On the other hand negative results in similar experiments have been obtained by LAUCHE (1915) for *Rana temporaria*, DEAL (1929) for *Rana pipiens*, MOSZKOWSKA (1932) for *Bombinator pachypus* and UCHIDA (1933) for *Rana temporaria*. Because in his former experiment the duration of grafting was short, the writer repeated an experiment concerning the Japanese newt, with more prolonged intervals between operation and fixation. The cost of the experiment was defrayed through the Imperial Academy. Before proceeding further, the writer would like to express cordial thanks to the Imperial Academy for this financial aid, and also to Messrs. S. MAKINO, H. YAMAGUCHI and K. HANAOKA for making sections and taking photographs.

1) Contribution No. 98 from the Zoological Institute, Faculty of Science, Hokkaido Imperial University.

Material and Methods

The newt occurs very commonly in ponds and pools of Japan proper. The breeding season of the animal, though somewhat different in localities and variable according to the climatic conditions of the year, generally begins from the end of March and lasts to the end of May. In addition to the spring breeding, the autumnal mating, which occurs not so frequently, has been reported by TSUTSUI (1931). After the breeding season in spring there take place remarkable changes in the gonads of the newt. In the testis of this stage degenerated spermatozoa still left in the seminiferous tubules become gradually degenerated and absorbed, and then the seminiferous tubules become evacuated, shrunk and degenerated. In the meantime, the spermatogonia and interstitial cells, on the other hand, make rapid multiplications. The spermatogonia repeating divisions form cysts and develop into spermatocytes which are contained in the seminiferous tubules. The spermatocytes passing through the growth period and the meiotic divisions eventually metamorphose into spermatozoa. During the spermatogenesis a single testis of the Urodelan contains generally germ cells in different developmental stages, it is thence often observed during May to June, that one end of the testes has spermatogonia still proliferating intermingled with active interstitial cells, while the opposite end is composed of seminiferous tubules with spermatocytes in the stages, diplotene and diakinesis. In July and August, therefore, one can observe in a testis almost every stage of spermatogenesis, from spermatogonia intermingled with interstitial cells to spermatids just in the process of metamorphosis. The spermatogenesis lasts in general till the end of September. From the beginning of October to the next breeding season the testes usually remain quiescent, with well-formed seminiferous tubules full of spermatozoa (Fig. 1). In this quiescent period, however, one can frequently observe in the testes a small part containing spermatogonia and spermatocytes (Fig. 2). This part is always attached to the crest of the testis and is easily distinguished from

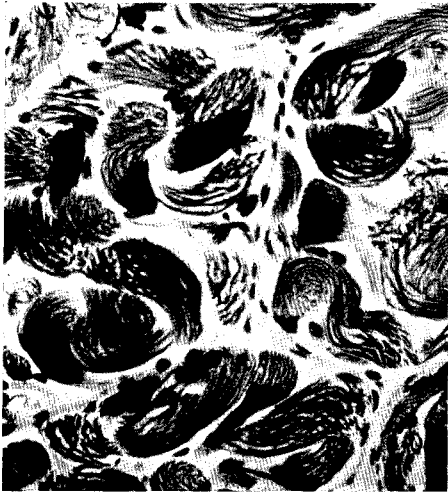

Fig. 1. Section of a normal testis fixed on Feb. 15, 1933. $\times 160$

the rest by the naked eye. Inferring from the presence of germ cells in different stages of development in a testis, it is surmised that the germ cells of this part developed last and have ceased spermatogenesis, since the quiescent period set in. The material used in the experiment was bought from a dealer who collected the newts in the neighbourhood of Sendai. The newts of Sendai have already been used by UEKI (1930) for statical and by NAGASAKA (1935) for

morphological works, and seem to be ones repeating the normal sexual cycles, as stated before.

About one hundred individuals, including males and females, were operated at two different seasons of the year 1933; the first operation was performed before and the second was carried out after the breeding season. The first group of experimentals was killed in the summer several months after the operation, while the second was examined after the breeding season of the next year. The grafts available for examination were 35 in number for the former and 28 for the latter group. The operation was easily done as follows. After narcotizing

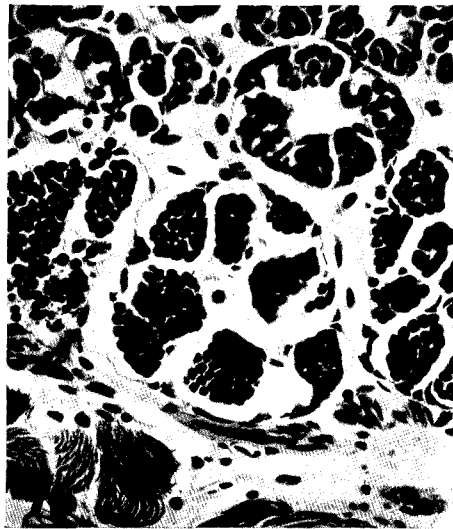


Fig. 2. Section of a part of a normal testis containing spermatogonia and spermatocytes in the quiescent stage, fixed on Feb. 25, 1933. $\times 160$

with 0.2% water solution of chloretone, auto- and homoplastic graftings of testicular pieces were executed. In the winter operation the portion consisting of spermatozoa was mostly utilized for transplantation (Fig. 1), but in a few exceptional cases, the part containing spermatocytes (Fig. 2) was engrafted. In grafting the testicular pieces were fastened by means of silk thread to the mesentery near the duodenum of males, normal or castrated, or of females, normal or castrated; this place of transplantation had been chosen, because it yielded the best results in the writer's previous experiment (1933). These transplants in due time after the operations were fixed with Bouin's solution, sectioned in paraffin and doubly stained with Heidenhain's haematoxylin and eosin.

Behavior of grafts

When the grafts were taken out, they were generally found at or near the places to which they had been attached. There were, however, some which were found to have translocated from the original place of transplantation and taken root in other parts of the mesentery. It is noticeable that several grafts were observed to be in contact with the mesentery near the urogenital organs, though not in exactly the position as in the normal individuals. When the transplantation was successful, testicular transplants were found in most cases to have enlarged, but some of them, though having become smaller than at the time of engrafting, were in the process of vigorous spermatogenesis throughout their entire extent. On the other hand, some grafts, which became considerably larger than before, were found to contain degenerated cells alone, having vestiges of the seminiferous tubules and inactive interstitial cells in clumps. It is highly probable that these grafts, after operation, regenerated and enlarged at one time, but afterwards, owing to some unfavourable conditions, passed into degeneration.

As the transplants were mostly fixed from May to September, the regenerated ones invariably were observed to display progressing stages of spermatogenesis. After the implantation, spermatozoa in

the seminiferous tubules of the testicular grafts degenerate at first. Subsequent to the degeneration of the spermatozoa, the phagocytes clear up these residia and then the lumen of the tubules become evacuated and to some extent shrunk. In this stage, when the grafting was successful, young spermatogonia left on the periphery of the seminiferous tubules increase by repeated multiplications, and gradually develop into spermatocytes and spermatozoa. The spermatogenesis observed in the grafts from May to September is due

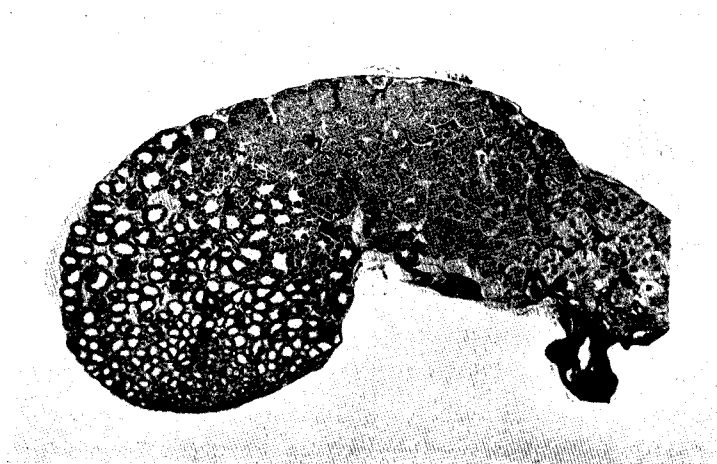


Fig. 3. Section of a regenerated testicular graft resident in a castrated female (No. 33) from Feb. 25-July 11, 1933, articulated in three parts; right one containing spermatozoa in metamorphosis, associated with the degenerated lobe of the original graft; middle one consisted of spermatids and spermatocytes; left one having spermatogonia. \times about 11

to the germ cells which had proliferated after the degeneration of the former spermatozoa. When the transplants contain solely young germ cells as spermatogonia and first spermatocytes, however, these young germ cells directly develop to spermatozoa. The phenomenon is shown in Fig. 1, Pl. XV photographed from the section of a testicular graft which included at the implantation only spermatogonia and spermatocytes (see Fig. 2 in text) and was fixed about one and half months afterwards. The degenerated spermatozoa in the seminiferous tubules shown in the figure are probably metamorphosed from spermatocytes at the time of grafting and the spermat-

cytes packed in the seminiferous tubules possibly have been developed from comparatively young spermatogonia of the former transplant or newly proliferated spermatogonia.

When the transplantation was a failure, spermatozoa at first and then other germ cells of the graft degenerated, and subsequently the interstitial cells became gradually inactive as shown in Fig. 5, Pl. XI. Utterly degenerated testicular pieces about ten months after the operation were usually represented by a hyaline structure, containing a few inactive interstitial cells alone. Even well-regenerated testicular transplants were generally accompanied by a remnant of degenerated parts which was generally considerably smaller in size in contrast to the regenerated portion and contained only interstitial cells.

The degenerated grafts or degenerated parts of regenerated transplants were frequently associated with a tissue similar to the fat bodies. The tissue has been, of course, formed during degeneration. The tissue contains a small number of nuclei sparsely distributed and is found only on the periphery of degenerated tissue containing only interstitial cells or making several lobes arising from the original tissue. In some transplants the lobes were found to be very long and to number five or six. A few transplants were found to be mainly composed of the tissue, with a part containing only interstitial cells in small limited regions. This tissue seems to be undoubtedly derived from the interstitial cells. A few of degenerated grafts were found to be bordered by the tissue of the pancreas which is frequently folded into degenerated parts of the grafts. In the transplants, in which the degeneration probably suddenly occurred on the whole, the interstitial cells are generally inactive and sparsely distributed as shown in Fig. 2, Pl. XV, while in the grafts, in which only the germ cells have entirely been degenerated, the interstitial cells often increased and were found to form several nodules as is illustrated in Fig. 6, Pl. XI. The ruins of seminiferous tubules are generally observed in the grafts immediately after the degeneration and represented by round hyaline spaces which are surrounded by

inactive interstitial cells. These ruins would soon or later disappear on account of degeneration of the interstitial cells or be invaded by the active interstitial cells.

In grafts grown on the normal males or females from 1½ to 5 months the writer frequently encountered a peculiar kind of degeneration process. After the evacuation of degenerated spermatozoa, multiplication and development of the remaining spermatogonia are at first invariably observable in the grafts on both the normal and the castrated individuals. But about two months afterwards, there is a marked difference between these two kinds of grafts. The spermatogenesis of the grafts on castrated newts goes on as in the normal case, while those implanted in non-castrated ones become gradually vacuolated in the seminiferous tubules. The degeneration begins for the first time with degeneration of spermatocytes universally packed in the seminiferous tubules, and then probably of spermatogonia and interstitial cells. The time at which the degeneration takes place, varies somewhat according to conditions but seems to range from one to two months after the operation. The graft, of which the section is illustrated in Fig. 1, Pl. XI, has resided in a normal female from February 21, 1933 to April 7, 1933. In this section germ cells are active and vigorously proliferating in more than the lower half, but a seminiferous tubule situated near the upper right corner is nearly vacuolated. A further stage of the degeneration is pictured in Fig. 2, Pl. XI photographed from a section of the graft which was attached to a normal male on February 18, 1933 and fixed on May 23, 1933. In this figure are shown several vacuolated seminiferous tubules of which some contain a few inactive or some no germ cells at all, while some are in the process of the degeneration. In Figs. 3 and 4 are shown the states immediately after this degeneration. After the degeneration of the seminiferous tubules the interstitial cells invade the ruined part, thus destroying the vestiges of the tubules. Though in Fig. 3 one can still see a few small surviving seminiferous tubules containing spermatogonia or spermatocytes, among the degenerated tissue having only interstitial cells, in Fig. 4 there are no distinct tubules or germ cells among

the interstitial cells. In this stage one can still perceive parts probably corresponding to the vestiges of seminiferous tubules, but Fig. 5, Pl. XI made from a graft located in a normal male from Feb. 16, 1933 to July 10, 1933 shows no remnants of tubules and has merely inactive interstitial cells distributed in ruined tissue. The degeneration above mentioned takes place only in seminiferous tubules having rather well differentiated germ cells such as spermatocytes. It is the usual case that, while the degeneration is progressing in the central portion, spermatogonia intermingled with the interstitial cells are active and repeating proliferation on the peripheral part of the same graft (Fig. 4, Pl. XV). It remains undecided, however, whether in these grafts young germ cells can survive further or gradually disappear, but it was observed in this experiment that some germ cells can live through to the next spring only in a restricted small area. The reason why the germ cells thus degenerate, or why the germ cells of only a small area can survive, will be discussed later. The gonads of the hosts were always observed to be uninfluenced by the grafts (Fig. 4, Pl. XIII).

Relations between transplants and hosts

a) *Transplants on castrated males (Pl. XII)*. Out of 15 transplants harboured in castrated males, eleven were found to contain active germ cells and 4 degenerated, having interstitial cells alone, as shown in Table I. In the grafts examined from May to July the spermatogenesis was proceeding; they were found to contain germ cells from spermatogonia vigorously proliferating to spermatids in the process of metamorphosis. The spermatozoa present at the time of implantation or developed after implantation seem to have been already absorbed. In graft No. 82, which was transplanted on Aug. 5 and fixed on Sept. 11 of the same year, are found many spermatozoa now metamorphosing. From these facts it is surmised that the spermatogenesis performed in the regenerated transplants generally agrees with that in the normal male. Moreover, it is noticeable that the testicular pieces engrafted from May to September in 1933, when examined in June, 1934 were repeating the germ cycles as if in the testes of the normal newts.

TABLE I (Castrated males)

(The numbers in italics designate grafts with active germ cells.)

No. of animal	Duration of grafting	Size and condition of graft	The graft consists of
No. 1	8, II, 1933-30, V, 1933.	enlarged but degenerated.	only interstitial cells, with lobes of the structure similar to the fat bodies.
<i>No. 1'</i> (Host being same as No. 1; a testicular piece was transplanted from No. 50)	30, V, 1933-17, VII, 1933.	enlarged, generally regenerated but some places degenerated.	active spermatogonia intermingled with interstitial cells, spermatocytes in various stages to pachytene.
No. 17 (Died)	18, II, 1933-17, V, 1933.	diminished in size and degenerated,	only interstitial cells.
No. 21	21, II, 1933-11, VII, 1933.	enlarged but degenerated.	only interstitial cells, with lobes similar in structure to the fat bodies.
<i>No. 29</i>	23, II, 1933-10, VII, 1933.	somewhat enlarged, vacuolated, with isolated seminiferous tubules containing spermatogonia and spermatocytes. One end with proliferating gonias forming cysts.	spermatocytes in seminiferous tubules, active spermatogonia in the process of forming cysts.
<i>No. 37</i>	25, II, 1933-11, VII, 1933.	enlarged and well regenerated.	germ cells from proliferating spermatogonia to spermatids in the process of metamorphosis, a small lobe containing only interstitial cells.
<i>No. 52</i>	1, VI, 1933-11, VII, 1933.	approximately equal to that at the operation, spermatogenesis in progress.	spermatogonia making cysts and spermatocytes to the stage of diplotene.
<i>No. 7'</i> (Secondary transplantation was executed on the experimental (No. 7) after castration)	2, VI, 1933-11, VI, 1934.	enlarged, developed, as in the normal male.	almost every stage of spermatogenesis from spermatogonia to spermatids.

TABLE I (Continued)

No. of animal	Duration of grafting	Size and condition of graft	The graft consists of
No. 50	30, V, 1933-11, VI, 1934.	somewhat enlarged and as in the normal spermatogenesis.	almost every stage of spermatogenesis, germ cells mostly in the stages leptotene and diplotene, the most developed ones being spermatids.
No. 51	31, V, 1933-11, VI, 1934.	diminished in size, degenerated.	no germ cells, but only inactive interstitial cells.
No. 58	29, VII, 1933-18, IV, 1934.	reduced in size, a half part degenerated, the other half with active germ cells.	in a half only interstitial cells and in the other half active germ cells and interstitial cells, in the process of making cysts.
No. 70	2, VIII, 1933-11, VI, 1934.	enlarged and as in the normal testes.	germ cells, from spermatogonia intermingled with interstitial cells to spermatocytes of the leptotene stage.
No. 82 (Two testicular pieces transplanted)	5, VIII, 1933-11, IX, 1933.	one piece wholly degenerated, another one well developed.	germ cells, from spermatocytes forming seminiferous tubules to spermatozoa now in matamorphosis.
No. 89	19, IX, 1933-11, VI, 1934.	enlarged and well developed, with a small degenerated part.	spermatogonia in the process of forming cysts, spermatocytes to the stage leptotene, parts similar to the fat bodies attached to small degenerated end.
No. 93	20, IX, 1933-11, VI, 1934.	somewhat enlarged, mostly in good condition.	spermatogonia scarcely found, spermatocytes mostly in the stages leptotene and diplotene, with a part like the fat bodies attached to a small degenerated hyaline portion.

b) *Transplants on non-castrated males (Pl. XI & Pl. XIII).* Among 17 transplants to normal males, only three were observed to have active germ cells. The results are summarized in Table II. In these regenerated testicular pieces the following findings were

made; in the pieces No. 19 and No. 25 only a half or a small lobe of them contained active germ cells (Figs. 1 & 5, Pl. XIII), while the larger part of them was vacuolated and degenerated; the graft, No. 64 containing active germ cells was small in comparison with the grafts put in castrated males. It is shown, however, that a graft transplanted after the breeding season in a normal male is able to repeat the spermatogenesis after the next breeding season (see No. 64). As shown in Table II, it occurs that degenerated grafts were frequently found to have been enlarged from the time of implantation. From these facts one can conjecture that these grafts had once regenerated and enlarged, but after several months became vacuolated and then degenerated. The phenomenon of this degeneration is observable in No. 22, No. 23 and even in No. 19 which has active germ cells in a half part. It is surmised that, subsequent to the degeneration, these grafts decrease in size and in the next year would have been entirely absorbed as in Nos. 68, 80 and 91. It is probable that the enlarged grafts, Nos. 60, 72 and 84, had once regenerated but after the next breeding season degenerated. The reasons why in non-castrated males the degeneration occurs or why active germ cells are restricted only to a small piece or a limited part of the graft, will be discussed later on.

TABLE II (non-castrated males)

(The numbers in italics designate grafts with active germ cells.)

No. of animal	Duration of grafting	Size and condition of graft	The graft consists of
No. 3 (Gonad on one side spayed)	14, II, 1933- 2, V, 1933.	reduced and degenerated.	no germ cells but active interstitial cells.
No. 7	15, II, 1933- 2, VI, 1933.	diminished in size and degenerated	only interstitial cells, with vestiges of seminiferous tubules.
No. 11	16, II, 1933- 10, VII, 1933.	decreased in size and degenerated.	only interstitial cells, with vestiges of seminiferous tubules.

TABLE II (Continued)

No. of animal	Duration of grafting	Size and condition of graft	The graft consists of
No. 19	18, II, 1933-23, V, 1933.	enlarged, a half vacuolated and the other half regenerated.	the vacuolated half associated with parts similar to the fat bodies and in the other half active spermatogonia and spermatocytes.
No. 22	21, II, 1933-10, VII, 1933.	enlarged and vacuolated.	only interstitial cells, some of which invaded the vacuolated portion, with a part like the fat bodies in structure.
No. 23	21, II, 1933-10, VII, 1933.	somewhat enlarged but vacuolated.	interstitial cells which are universally distributed or making nodules showing the stage soon after the degeneration.
No. 25 (Gonad on one side castrated)	25, II, 1933-4, VI, 1933.	generally degenerated, with a small lobe containing active germ cells.	degenerated spermatozoa in seminiferous tubules and vigorously proliferating spermatogonia in a small lobe.
No. 27	22, II, 1933-10, VII, 1933.	degenerated.	only active interstitial cells and parts similar to the fat bodies.
No. 37 (Died)	25, II, 1933-17, III, 1933.	wholly degenerated.	only dead spermatozoa and a small number of interstitial cells.
No. 60	29, VII, 1933-11, VI, 1934.	somewhat enlarged but degenerated.	active interstitial cells but no germ cells, vestiges of seminiferous tubules remaining as small elliptical spaces stainable with eosin and surrounded by interstitial cells.
No. 64	31, VII, 1933-11, VI, 1934.	slightly enlarged in size and good in condition.	in general young spermatocytes to the stage diplotene, spermatogonia proliferating with interstitial cells, with a part similar to the fat bodies.
No. 68	1 VIII, 1933-11, VI, 1934.	almost absorbed.	

TABLE II (Continued)

No. of animal	Duration of grafting	Size and condition of graft	The graft consists of
No. 72	2, VIII, 1933-11, VI, 1934.	slightly enlarged but degenerated.	only inactive interstitial cells, with processes similar in structure to the fat bodies.
No. 80	5, VIII, 1933-11, VI, 1934.	absorbed.	
No. 84	13, IX, 1933-11, VI, 1934.	somewhat enlarged but degenerated.	interstitial cells mostly active, parts similar to the fat bodies.
No. 91	19, IX, 1933-11, VI, 1934.	absorbed.	
No. 95	20, IX, 1933-11, XI, 1934.	degenerated.	only interstitial cells.

c) *Transplants on castrated females (Pl. XIV)*. Out of 18 transplants on castrated females, ten were found to have regenerated and enlarged, containing active germ cells. In the series of transplants left from before the breeding season to July of the same year, the spermatogenesis was most vigorously proceeding as in the control male, but the overwintered grafts mostly displayed degeneration, though two grafts, No. 67 and No. 79, were well regenerated and repeating the spermatogenesis. The graft, No. 79 lodged in a castrated female from Aug. 5, 1933 to Jun. 11, 1934 was found to contain in larger part active spermatogonia and spermatocytes, but to retain a few seminiferous tubules containing degenerated spermatozoa. These spermatozoa had presumably developed from the spermatogonia or spermatocytes at the time of grafting and had remained without being emptied or absorbed. It is remarkable that the overwintered grafts, such as No. 63, No. 83, No. 87 and No. 94, were considerably enlarged but largely degenerated. From the presence of vestiges of seminiferous tubules it can be concluded that

they had once regenerated and then degenerated. The reason of the degeneration is not clear for the present. It is noticeable that the graft, No. 83, was found to contain a seemingly distinct ovum among the degenerated tissue which has only interstitial cells. No similar case was found in this experiment. The transplantation in castrated females seems to be somewhat more successful than in castrated males, so far as intervals of grafting from February to July of the year are concerned, but the case is distinctly the opposite in the overwintered grafting. The results of this series of transplantation are shown in Table III.

TABLE III (castrated females)

(The numbers in italics designate transplants having active germ cells.)

No. of animal	Duration of grafting	Size and condition of graft	The graft consists of
<i>No. 2</i>	8, II, 1933-31, V, 1933.	enlarged and well regenerated.	germ cells in various stages, from proliferating spermatogonia forming cysts to spermatids.
No. 6	15, II, 1933-10, VII, 1933.	diminished in size and degenerated.	only interstitial cells, accompanying a part similar to the fat bodies.
No. 10	15, II, 1933-10, VII, 1933.	enlarged but degenerated.	only interstitial cells with a part like the fat bodies.
<i>No. 14</i>	17, II, 1933-10, VII, 1933.	slightly enlarged, mostly degenerated, with an active proliferating part.	mostly interstitial cells. In a limited locality are found proliferating germ cells, from spermatogonia to the stage leptotene.
<i>No. 18</i>	18, II, 1933-10, VII, 1933.	enlarged and well regenerated.	germ cells in diverse stages, from spermatogonia forming cysts to spermatids.
<i>No. 26</i>	22, II, 1933-29, III, 1933.	peripheral part regenerated but larger part containing dead spermatozoa.	in most part dead spermatozoa and on the periphery spermatogonia forming cysts.

TABLE III (Continued)

No. of animal	Duration of grafting	Size and condition of graft	The graft consists of
No. 34	24, II, 1933-11, VII, 1933.	enlarged and well regenerated, with a small degenerated part.	almost every stage of spermatogonia intermingling with active interstitial cells to spermatids in the process of metamorphosis.
No. 38	25, II, 1933-11, VII, 1933.	considerably enlarged and well regenerated.	active germ cells as in No. 34.
No. 42	1, III, 1933-7, IV, 1933.	mostly degenerated, with active peripheral parts.	mostly dead spermatozoa in the seminiferous tubules, and on the limited peripheral margin active spermatogonia forming cysts.
No. 53	2, VI, 1933-11, VII, 1933.	enlarged and well regenerated.	almost every stage of spermatogenesis as in No. 34.
No. 63	31, VII, 1933-11, VI, 1934.	enlarged but mostly degenerated.	many vestiges of seminiferous tubules, active interstitial cells in one end.
No. 67	1, VIII, 1933-17, IV, 1934.	enlarged and well regenerated.	germ cells from vigorously proliferating spermatogonia among interstitial cells to spermatocysts in the stages, leptotene and diplotene, with a lobe of cells similar to those of the fat bodies.
No. 75	3, VIII, 1933-11, IV, 1934.	diminished in size and degenerated.	no germ cells but active interstitial cells, and parts similar to the fat bodies.
No. 79	5, VIII, 1933-11, VI, 1934.	enlarged and regenerated.	in a half part dead spermatozoa and active interstitial cells, and in the other half multiplying spermatogonia and active spermatocytes.
No. 83	13, IX, 1933-11, VI, 1934.	enlarged but degenerated.	interstitial cells which are more active than in Nos. 87 and 94. One large ovum was found.
No. 87	15, IX, 1933-11, VI, 1934.	enlarged but almost degenerated, with vestiges of seminiferous tubules.	a few inactive interstitial cells and a part like the fat bodies.
No. 90	19, IX, 1933-3, V, 1934.	diminished in size and almost degenerated.	only a few inactive interstitial cell in hyaline structure.
No. 94	20, IX, 1933-11, XI, 1934.	enlarged but almost degenerated as in No. 87.	a few interstitial cells like No. 87.

d) *Transplants on non-castrated females (Pl. XI & Pl. XV).* The results obtained from these transplants are in general agreement with those from non-castrated males. Thirteen transplants were available from non-castrated females. Out of them eight were found to contain germ cells. The regenerated testicular pieces can be divided into two groups; one including those harboured in the hosts from February to July of the same year and the other consisting of overwintered ones. Those belonging to the former group are all enlarged and always bear a large degenerated (vacuolated) part. The degeneration is the same as in the grafts on non-castrated males. The grafts of the latter group are 4 in number and always small in size. One of them (No. 92) is almost degenerated but in a limited portion active solitary spermatogonia are scattered among the interstitial cells (Fig. 6, Pl. XV). Another graft (No. 69) was found to have taken root on the mesentery near the urogenital system and to be in better condition than No. 92. Though the size may be small, it contains active spermatogonia and spermatocytes, in spite of the presence of the well-developed ovaries of the host (Figs. 3 & 5, Pl. XV). All degenerated transplants have been reduced in size. The results obtained from the grafting seem to coincide generally with those in non-castrated males. For details the following table (Table IV) may be referred to.

TABLE IV (non-castrated females)

(The numbers in italics designate grafts containing active germ cells.)

No. of animal	Duration of grafting	Size and condition of graft	The graft consists of
No. 4	14, II, 1933- 1, VI, 1933.	reduced in size and degenerated.	only active interstitial cells.
No. 8	15, II, 1933- 10, VII, 1933.	smaller and degenerated.	only active interstitial cells.
No. 16	17, II, 1933- 16, IV, 1933.	diminished in size and degenerated.	only interstitial cells.

TABLE IV (Continued)

No. of animal	Duration of grafting	Size and condition of graft	The graft consists of
No. 20	18, II, 1933-10, VII, 1933.	somewhat enlarged; a half part degenerated, the other half regenerated.	in the degenerated half only interstitial cells and in the regenerated half active spermatogonia and spermatocytes.
No. 28	22, II, 1933-7, IV, 1933	enlarged; a half part degenerated, the other half regenerated.	in the degenerated half only interstitial cells and dead spermatozoa and in the regenerated half proliferating spermatogonia and spermatocytes to the stage leptotene.
No. 32	23, II, 1933-11, VII, 1933.	enlarged and regenerated.	in a half part vacuolated tissue and in the other half active spermatogonia and spermatocytes to pachytene.
No. 36	24, II, 1933-29, V, 1933.	enlarged, regenerated but in the process of degeneration.	in most part vacuolated seminiferous tubules in the process of degeneration but in one locality active spermatogonia and spermatocytes.
No. 40	25, II, 1933-27, III, 1933.	somewhat regenerated but mostly vacuolated.	dead spermatozoa, vacuolated tissue, and periperal regions containing spermatogonia in cysts.
No. 44	1, III, 1933-11, VII, 1933.	diminished in size and degenerated.	only interstitial cells.
No. 69	1, VIII, 1933-11, VI, 1934.	somewhat diminished in size but in good condition with sufficient blood supply.	germ cells from spermatogonia forming cysts to spermatocytes in the stage leptotene.
No. 73	2, VIII, 1933-11, VI, 1934.	reduced in size and almost degenerated.	only meagre interstitial cells in limited portions of hyaline substance.
No. 77	3, VIII, 1933-11, VI, 1934.	diminished in size and degenerated.	inactive interstitial cells sparsely scattered in hyaline substance.
No. 92	19, IX, 1933-11, VI, 1934.	smaller, degenerated, but with germ cells.	in general hyaline structure with interstitial cells, a part similar to the fat bodies, and in the central part active spermatogonia intermingled with active interstitial cells.

Discussion

From the results obtained by the former investigators, it is ascertained that the testicular pieces of Amphibians engrafted on castrated males can regenerate under favorable conditions. The writer's findings are in accordance with these results; the implants of this kind were mostly found to have regenerated and to repeat the normal germ cycle. It has also been confirmed by PONSE (1924), WELTI (1928), De BEAUMONT (1929), and MOSZKOWSKA (1932), that the testicular grafts are able to develop in castrated females. The present experiment frequently yielded satisfactory results as is given in Table III. There is, however, the remarkable fact that these grafts were generally found to remain in good condition for several months, but out of the eight overwintered only two were enlarged and regenerated, four enlarged but degenerated, and two diminished in size and degenerated. The four grafts of the second series coincide with each other in the respects that they have grown to rather large sizes as in well-regenerated grafts, and that they are provided with vestiges of seminiferous tubules but have no germ cells at all. Especially two of them lack even active interstitial cells. Judging from the enlarged sizes and degenerated states of these grafts, it is easily concluded that they must have once regenerated and enlarged, but probably at or immediately after the breeding season have suddenly degenerated. Whether this degeneration was accidental or whether it is liable to occur in the female hosts can not be determined at present.

According to the previous reports, grafts made upon normal males and normal females were found to be always degenerated within a few months. By reference to Tables II and IV, however, it may be noted that grafts on normal males as well as on normal females can also regenerate and perform spermatogenesis for several months, and, moreover, under favorable conditions can repeat the spermatogenesis after the next breeding season. MOSZKOWSKA (1932), who observed degeneration of testicular pieces engrafted on the fire toad, *Bombinator pachypus*, pointed out the important role

of the anterior hypophysis for the regeneration of the transplants. As shown in the present writer's experiment, grafts on the castrated individuals are more likely to regenerate than those on the non-castrated, probably because of the fact that in the normal individuals most of the hormone from the anterior hypophysis is consumed by their own gonads, and owing to the insufficiency of this hormone, the growth of the grafts is arrested. It is observable that the transplants on the normal individuals develop at first, so far as regeneration does not occur to any large extent, but that they become gradually degenerated and vacuolated along with the enlargement of the regenerated area. The degeneration seems to result from the insufficient supply of the hormone of the anterior hypophysis over the grafts, especially due to the excess of the graft. But if the transplants are small in amount, the production and supply of the hypophysial hormone are not too meagre for the development of both the creature's own original gonads and the graft. Accordingly, it will follow that the grafts which have been survived and repeated spermatogenesis in the normal newts are invariably small in size. Inferring from the good condition of the testicular pieces implanted on the normal female, in spite of the presence of the well developed ovaries, it is established that the adult testicular pieces are not much influenced by the hormone of the adult female.

In his grafting experiment with Urodelans De BEAUMONT (1929 & 1932) reported the occurrence of ovocytes in a testicular graft on a castrated female of *Triturus cristatus* (p. 227) and in a heteroplastic transplant of *T. vulgaris* on a spayed female of *T. cristatus* (p. 446). BECCARI (1933) repeating the same experiment on *T. cristatus* recorded several cases of the appearance of ova, singly or in clumps, in testicular grafts on castrated individuals including both the sexes. Amongst about eighty testicular grafts examined by the writer only one seemingly distinct ovum was found in a degenerated testicular transplant engrafted on a female. Though the germ cells generally known as "testis ova" are often found in the normal testis of animals belonging to several groups, their essential characters mostly remain

unknown. It seems to the writer that these testis ova may be diverse in essential characters according to animal groups and can not be summarized in a category. In the following paragraphs will be discussed the testis ova only as they occur in the Amphibia. The testis ova are often met with in the testes of the Amphibia, including the Urodela and Anura. The most frequent occurrence of the ova, so far as investigated, is seen in toads. According to WITSCHI (1934), these cells in toads make an atypical oogenesis omitting the synaptic phenomena and accordingly the term "oviform degeneration" may justly be applied to the phenomena. He pointed out further that the formation of testicular eggs in grafts and in regenerating fragments belongs to the same type of oviform degeneration. Regarding the testis ova in toads and also some of the similar cases in other species the case may be the same, but the occurrence of the regenerated testis ova, at least those in Fig. 12, Tav. VI, photographed by BECCARI (1933) seems to have thrown a fresh light on the relationship of the testis ova to the phenomena of intersexuality. So far as the writer is aware, in the following three experiments only, has the occurrence of ova in the testicular tissue been recorded:

- 1) After the involution of the testes of *Triturus alpestris* by prolonged starvation, the undifferentiated germ cells of the newts developed to ovocytes by feeding (CHAMPY, 1922 and De BEAUMONT, 1928).

- 2) After a male of *Triturus cristatus* was castrated, the remnant of a testis gave rise in the proximal half to a part containing spermatozoa and in the distal half to a portion containing ovocytes (De BOIS and De BEAUMONT, 1928; De BEAUMONT, 1929).

- 3) Several cases were reported on the appearance of seemingly distinct ova in testicular grafts on castrated individuals (see p. 231 in this paper).

In the first and third cases it is always observed that the testicular tissue degenerate at first, though to differing degrees, and then the residual germ cells begin to develop as spermatocytes or as

ovocytes. In the second case the testicular pieces generally displays also some degenerative phenomena due to traumatic condition. The three cases causing the occurrence of ovocytes in the testicular tissue, therefore, coincide in the fact that they are at first somewhat degenerated under unfavourable conditions. The writer is of the opinion that the occurrence of ovocytes in testicular tissue is comparable to the phenomenon of parasitic castration, as GOLDSCHMIDT formerly suggested. But there is a slight difference between the two phenomena; in parasitic castration the metabolic condition of the host becomes unfavourable, causing the degeneration of its own gonads which after removal of parasites begin to regenerate under a different metabolic condition from before, while in the testicular transplants brought into a new environment metabolic change is mostly restricted to the graft itself. Such being the case, sex reversal may possibly occur in individuals in the case of parasitic castration, but this phenomenon must usually be restricted to the graft itself in the grafting experiments. With the assumption that the occurrence of ovocytes in the testicular tissue, normal or engrafted, of the Amphibia has bearing on intersexuality, it is probable that these phenomena are liable to be seen in sexually undifferentiated species or races of Amphibia.

Summary

1) The testicular pieces of the adult newt were implanted on the mesentery of the normal or castrated adults of both sexes.

2) The grafts resident in castrated males displayed the best regeneration and were found to repeat the germ cycle as in the normal testes.

3) The grafts harboured in castrated females also manifested good development but some of them, probably immediately after the next breeding season, suddenly degenerated.

4) The grafts attached to the normal adults, irrespective of sex, develop and enlarge at first, when successful in transplantation, but gradually become vacuolated and degenerated from the central

portion containing the most developed germ cells. But a part of the testicule can survive and repeat spermatogenesis after the next breeding season.

5) This degeneration of the transplants seems to be due to the deficient supply of the hormone from the anterior hypophysis with the transplants, because the activity of the anterior hypophysis is usually restricted to the gonads of the host animal.

6) When production of the hormone from the anterior hypophysis is more than sufficient for its own gonads, a small piece of the transplant can survive and repeat the germ cycle.

7) The testicular graft which has survived in the normal female can stand unchanged under the influence of the ovaries of the host.

8) An ovum was found in a degenerated testicular graft in a castrated female.

9) The occurrence of ovocytes in testicular grafts of Amphibians may be comparable to the parasitic castration occurring in the Arthropoda.

Literature

- 1) BEAUMONT, J. De 1929. Les caractères sexuels du *Triton* et leur déterminisme. Masculinisation et féminisation. Arch. d. Biol., Tome 39.
- 2) ———. 1932. Hétérogreffes testiculaires chez les Urodèles. Arch. Zool. exp. et gén., Tome 74.
- 3) BECCARI, N. 1933. Cellule genitali femminili nella rigenerazione sperimentale del testicolo degli Anfibi. Monitore Zool. Italiano, Suppl. al Vol. 44.
- 4) CHAMPY, C. 1922. Étude expérimentale sur les différences sexuelles chez les Tritons (*Triton alpestris* LAUR.). Paris.
- 5) IRIKI, S. 1932. Studies on Amphibian chromosomes. 6. On the chromosomes of *Diemyctylus pyrrhogaster*. Sci. Rep. Tokyo Bunrika Daigaku, 1 sec. B, vol. 1.
- 6) LAUCHE, A. 1915. Experimentelle Untersuchungen an den Hoden, Eierstocken und Brunstorganen erwachsener und jugendlicher Grasfrösche (*Rana fusca* RAS.). Arch. mikr. Anat., Bd. 86.
- 7) MEYNS, R. 1910. Ueber Froschhodentransplantation. Arch. ges. Phys., Bd. 132.

- 8) MEYNS, R. 1912. Transplantation embryonaler und jugendlicher Keimdrüsen auf erwachsene Individuen bei Anuren nebst einem Nachtrag über Transplantation geschlechtsreifer Froschhod. Arch. mikr. Anat., Bd. 79.
 - 9) MOSZKOWSKA, A. 1932. Études endocrinologiques (Testicule et Hypophyse) chez le *Bombinator*. Bull. Biol. de la France et de la Belgique, Tome 36.
 - 10) NAGASAKA, K. 1935. Note on the changes occurring in the body of the male newt (*Triturus pyrrhogaster*) during the breeding season. Sci. Rep. Tohoku Imp. Univ., ser. 4, Biol., vol. 9.
 - 11) PONSE, K. 1924. L'organe de Bidder et la déterminisme des caractères sexuels secondaires du crapaud (*Bufo vulgaris*). Rev. Suisse Zool., Tome 31.
 - 12) SATO, I. 1932. Chromosome behavior in the spermatogenesis of Urodele Amphibia, *Diemyctylus pyrrhogaster* (BOIE). Jour. Sci. Hiroshima Univ., ser. B, Div. 1, vol. 2.
 - 13) TSUTSUI, Y. 1931. Notes on the behavior of the common Japanese newt, *Diemyctylus pyrrhogaster* BOIE. 1. Breeding habit. Mem. Coll. Sci., Kyoto Imp. Univ., ser. B, vol. 6.
 - 14) UCHIDA, T. 1933. Testis grafts in a frog and their relation to sexuality. Jour. Fac. Sci. Hokkaido Imp. Univ., ser. 6. Zool., vol. 11.
 - 15) UEKI, T. 1930. On the sexual differences in the newt, *Diemyctylus pyrrhogaster* (BOIE). Sci. Rep. Tohoku Imp. Univ., ser. 4, Biol., vol. 5.
 - 16) WELTI, E. 1928. Evolution des greffes de glandes génitales chez le crapaud. (Auto-, Homo, Hétérogreffes). Fac. Sci. Lab. Zool. et Anat. comp. Thèse No. 835, Univ. de Genève.
 - 17) WITSCHI, E. 1927. Testis grafting in tadpoles of *Rana temporaria* and its bearing on the hormone theory of sex determination. Jour. Exp. Zool., vol. 47.
 - 18) ———. 1934. Genes and inductors of sex differentiation in Amphibians. Biol. Rev. & Biol. Proc. Cambridge Phil. Soc., vol. 9, No. 4.
 - 19) YAMAMOTO, S. 1922. Notes on Japanese common newt, *Diemyctylus pyrrhogaster* (BOIE), I. (In Japanese with English resumé) Dobutsugaku Zasshi, vol. 34.
-

Plate XI

Explanation of Plate XI

(Stages of degeneration)

- Fig. 1. Section of graft (No. 28) harboured in a non-castrated female, from Feb. 22, 1933 to April 7, 1933, showing a vacuolated seminiferous tubule at the upper right corner. $\times 160$.
- Fig. 2. Section of graft (No. 19) harboured in a non-castrated male, from Feb. 18, 1933 to May 23, 1933, indicating seminiferous tubules conspicuously vacuolated in the upper half. $\times 160$.
- Fig. 3. Section of graft (No. 36) located in a non-castrated female, from Feb. 24, 1933 to May 29, 1933, representing a condition soon after the degeneration, with some small surviving seminiferous tubules. $\times 160$.
- Fig. 4. Section of graft (No. 23) transplanted on a non-castrated male, from Feb. 21, 1933 to July 10, 1933, showing the degeneration, having seminiferous tubules ruined. $\times 160$.
- Fig. 5. Section of graft (No. 11) taken from a non-castrated male after having been left from Feb. 16, 1933 to July 10, 1933, showing whole degeneration of the tissue without any germ cells. $\times 160$.
- Fig. 6. Section of graft (No. 95) from a non-castrated male after being left from Sept. 20, 1933 to Jun. 11, 1934, showing a nodule formed by interstitial cells of degenerated part. $\times 160$.

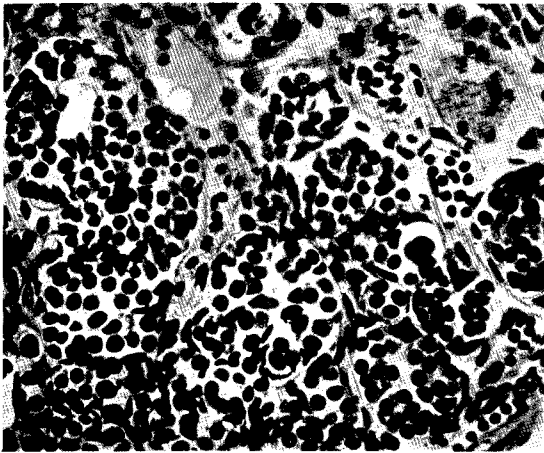


Fig. 1.

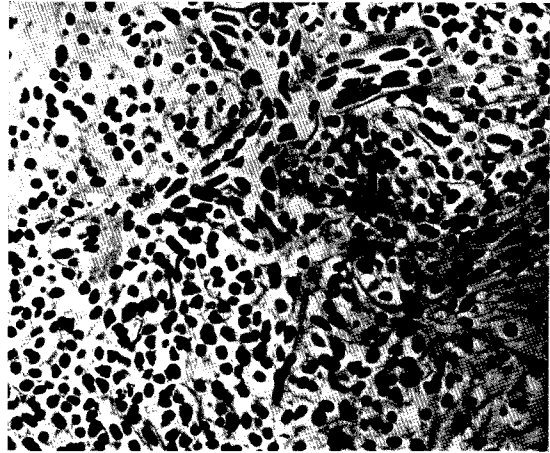


Fig. 4.

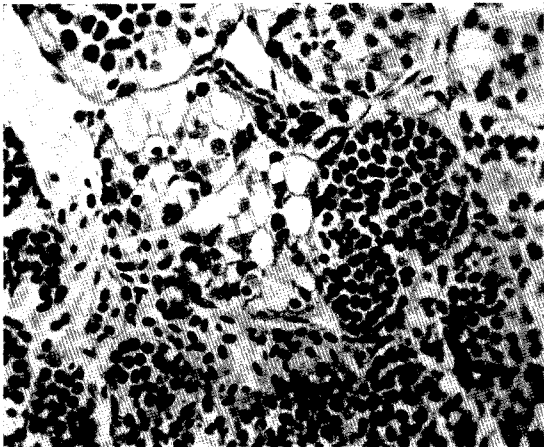


Fig. 2.

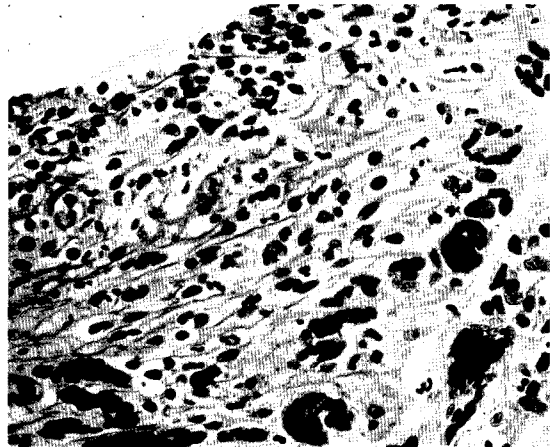


Fig. 5.

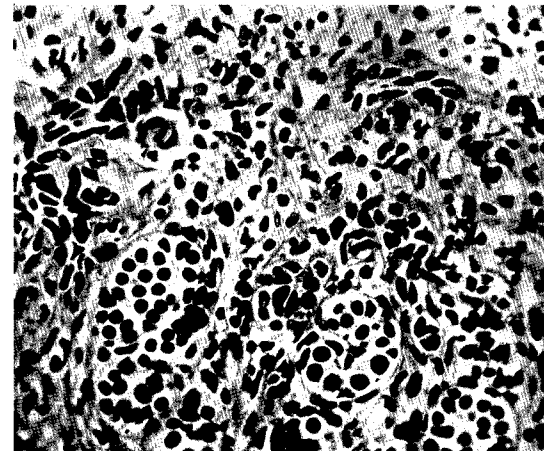


Fig. 3.

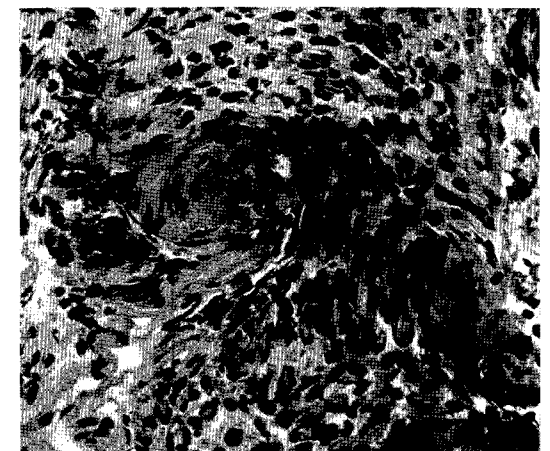


Fig. 6.

Plate XII

Explanation of Plate XII

(Grafts on castrated males)

- Fig. 1. Section of graft (No. 37) resident in a castrated male, Feb. 25, 1933 to July 11, 1933, showing seminiferous tubules containing spermatozoa in metamorphosis. $\times 160$.
- Fig. 2. Section of graft (No. 93) harboured in a castrated male, Sept. 20, 1933 to June 11, 1934, containing spermatocytes mostly in the pachytene stage. $\times 160$.
- Fig. 3. Section of graft (No. 82) attached to a castrated male, Aug. 5, 1933 to Sept. 11, 1933, having seminiferous tubules containing spermatids and spermatozoa. $\times 100$.
- Fig. 4. Section of graft (No. 82) left in a castrated male, from Aug. 5, 1933 to Sept. 11, 1933, furnished with spermatids and spermatozoa in metamorphosis. $\times 160$.
- Fig. 5. Section of graft (No. 58) harboured in a castrated male, July 29, 1933 to April 18, 1934, containing spermatogonia in vigorous proliferation. $\times 160$.
- Fig. 6. Section of graft (No. 50) placed in a castrated male, from May 30, 1933 to June 11, 1934, having spermatocytes in various developmental stages. $\times 160$.

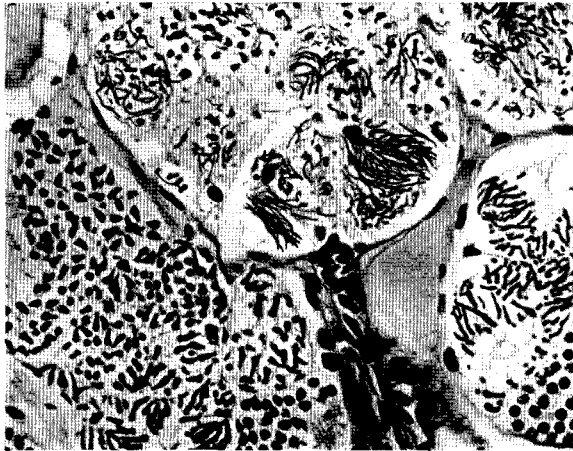

Fig. 1.

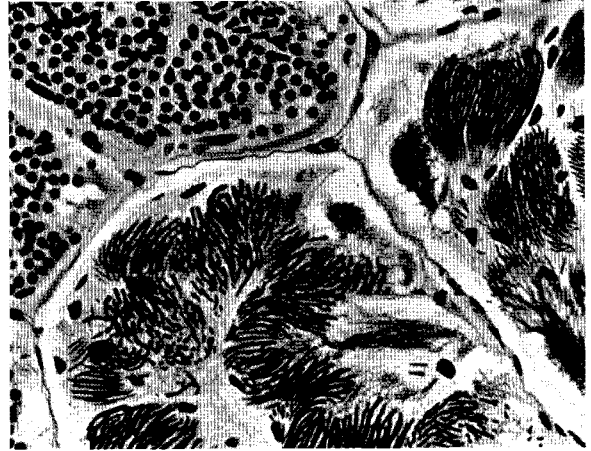


Fig. 4.

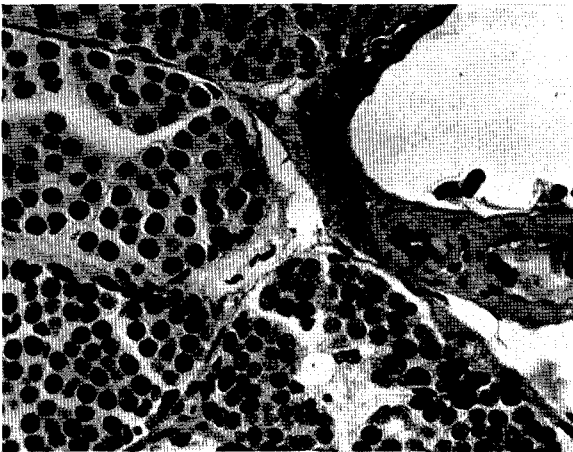

Fig. 2.

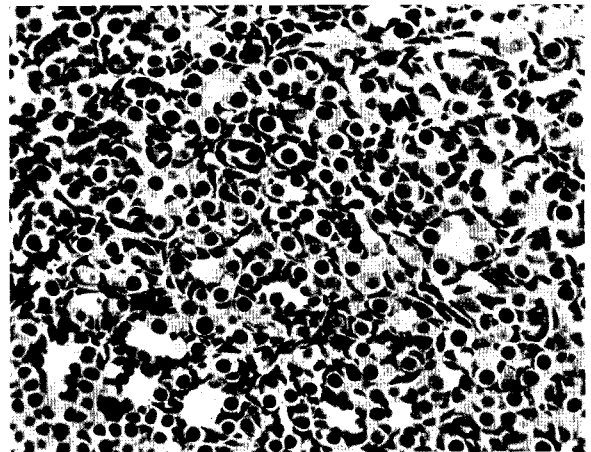


Fig. 5.

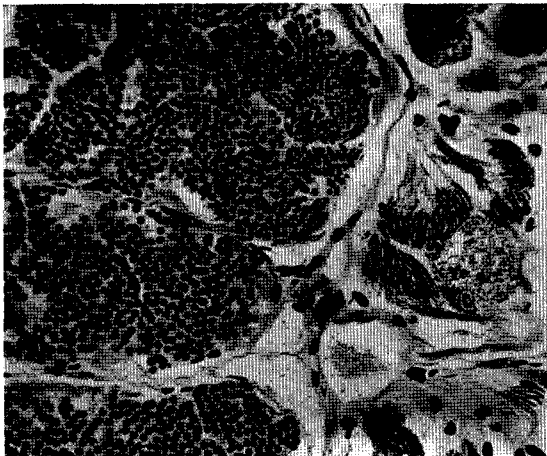


Fig. 3.

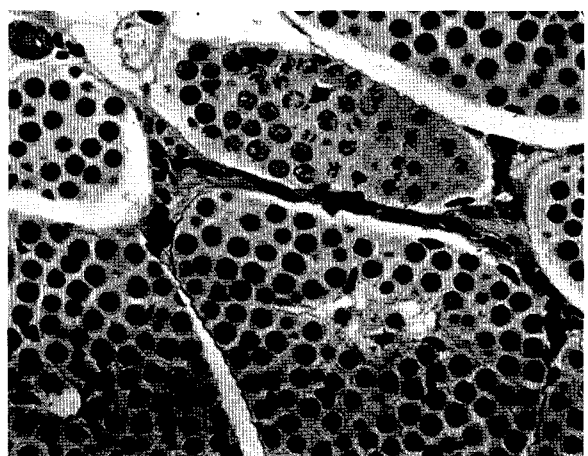


Fig. 6.

Plate XIII

Explanation of Plate XIII

(All grafts on non-castrated males except Fig. 4)

- Fig. 1. Section of graft (No. 25) resident in a half-castrated male, from Feb. 22, 1933 to April 4, 1933, showing a lobe containing active spermatogonia. $\times 100$.
- Fig. 2. Section of graft (No. 19) attached to a non-castrated male, Feb. 18, 1933 to May 23, 1933, indicating vigorous spermatogenesis near the periphery. $\times 100$.
- Fig. 3. Section of graft (No. 25) harboured in a non-castrated male, from Feb. 22, 1933 to April 4, 1933, showing proliferating spermatogonia and interstitial cells in the regenerated lobe. $\times 160$.
- Fig. 4. Section of a testis of the host (No. 91) fixed on June 11, 1934, containing active spermatocytes in seminiferous tubules. The graft has been entirely absorbed. $\times 160$.
- Fig. 5. Section of a regenerated lobe of graft (No. 64) incorporated with a non-castrated male, July 31, 1933-June 11, 1934. $\times 160$.
- Fig. 6. Section of graft (No. 72) taken from a non-castrated male after having been left, from Aug. 2, 1933 to June 11, 1934, showing the structure similar to the fat bodies. $\times 160$.

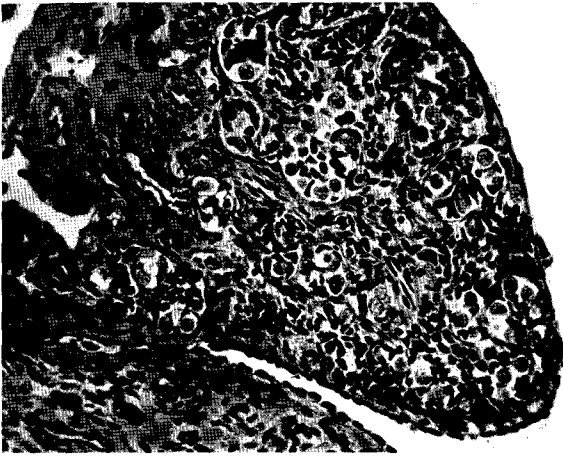


Fig. 1.

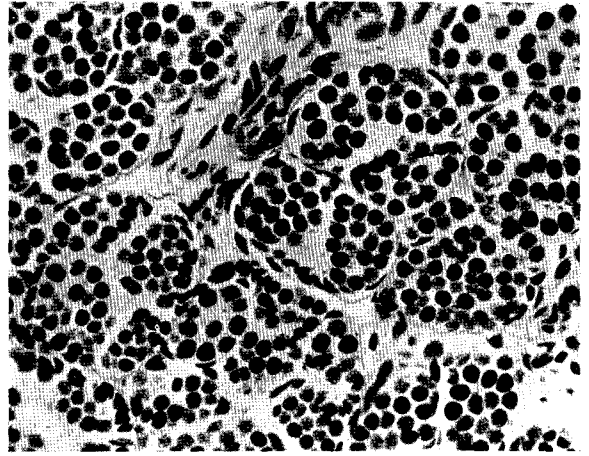


Fig. 4.

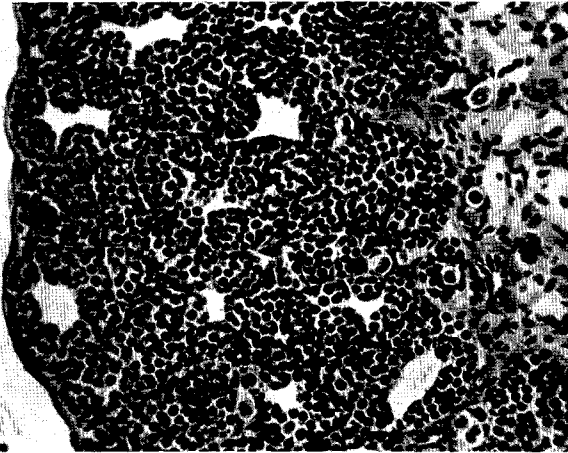


Fig. 2.

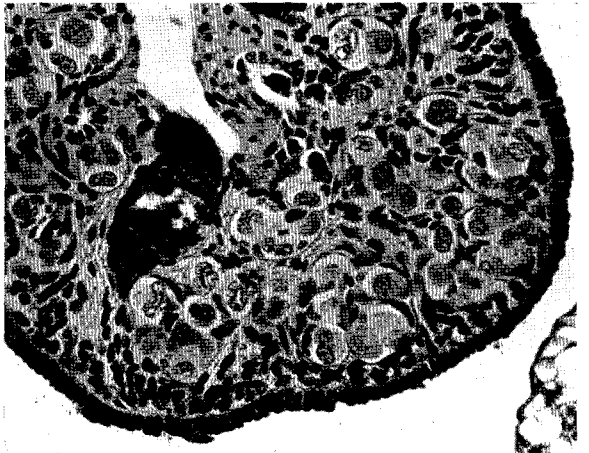

Fig. 5.

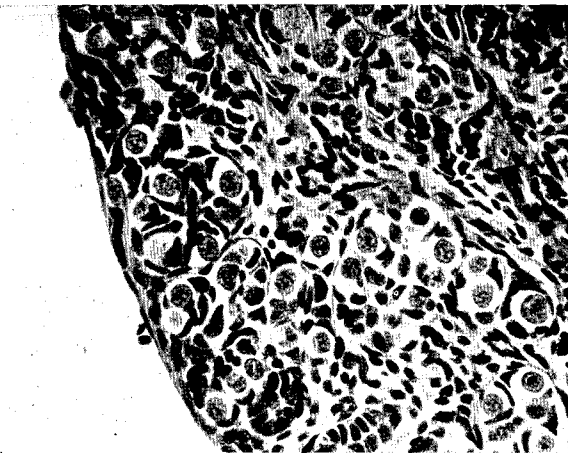


Fig. 3.

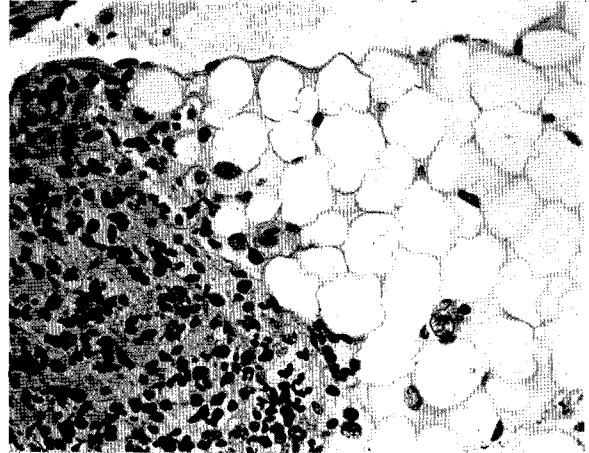


Fig. 6.

Plate XIV

Explanation of Plate XIV

(Grafts on castrated females)

- Fig. 1. Section of graft (No. 38) resident in a castrated female, Feb. 25, 1933–July 11, 1933, containing spermatids and spermatozoa nearly metamorphosed. $\times 160$.
- Fig. 2. Section of graft (No. 34) left in a castrated female, Feb. 24, 1933–July 11, 1933, containing active spermatocytes and spermatids. $\times 160$.
- Fig. 3. Section of graft (No. 67) attached to castrated female, Aug. 1, 1933–April 17, 1934, having well developed seminiferous tubules containing spermatogonia and spermatocytes. $\times 160$.
- Fig. 4. Section of graft (No. 83) obtained from a castrated female after having been left from Sept. 13, 1933 to June 11, 1934, showing a seemingly distinct ovum in the degenerated tissue. $\times 160$.
- Fig. 5. Section of graft (No. 53) located in a castrated female, June 2, 1933–July 11, 1933, showing various stages of spermatocytes, spermatids and spermatozoa in metamorphosis. $\times 160$.
- Fig. 6. Section of graft (No. 79) left in a castrated female, Aug. 5, 1933–June 11, 1934, containing spermatocytes in the left lower half and degenerated spermatozoa in the right upper half. The spermatozoa probably had been formed in the autumn of 1933 and have degenerated after the breeding season of 1934. $\times 160$.

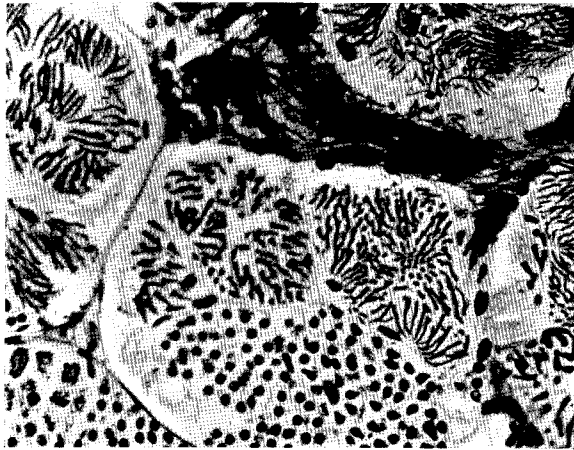


Fig. 1.

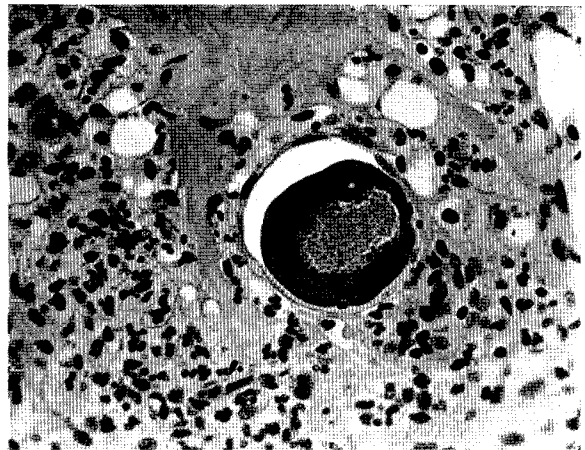


Fig. 4.

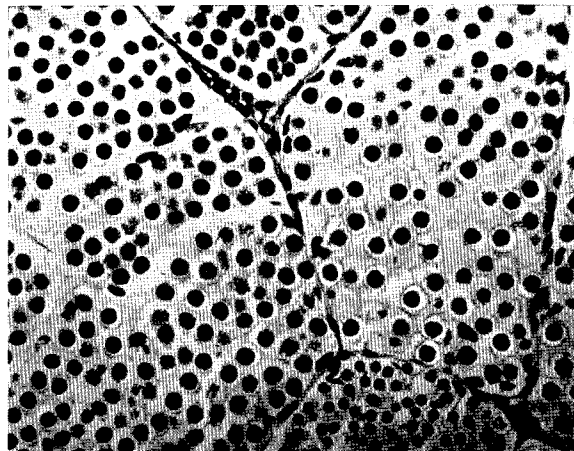


Fig. 2.

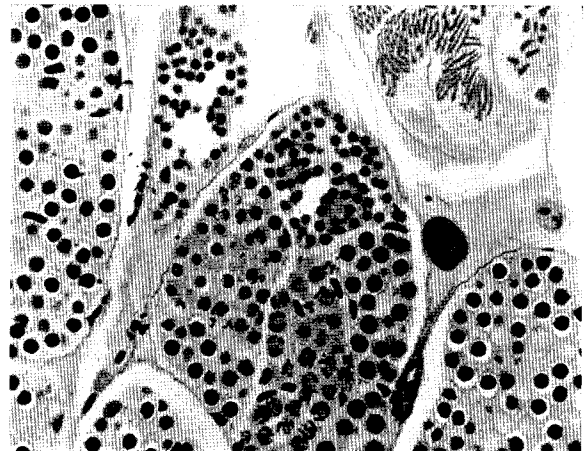


Fig. 5.

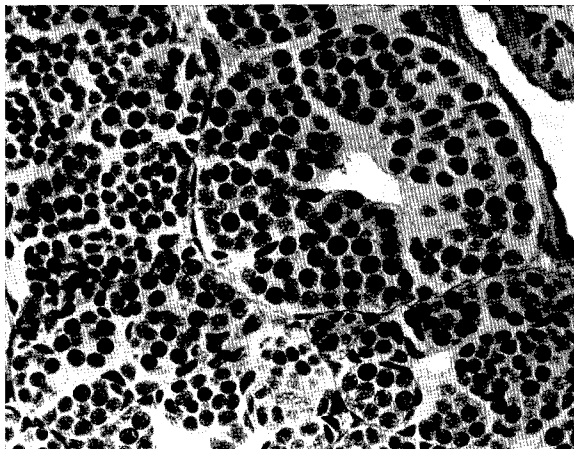


Fig. 3.

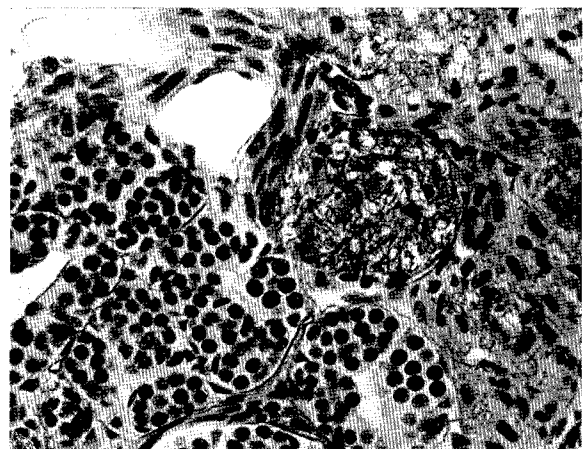


Fig. 6.

Plate XV

Explanation of Plate XV

(All grafts on non-castrated females except Fig. 2)

- Fig. 1. Section of graft (No. 28) taken from a non-castrated female after having been allowed to remain from Feb. 22, 1933 to April 7, 1933, containing in the left half seminiferous tubules with degenerated spermatozoa and in the right half tubules full of spermatocytes. $\times 100$.
- Fig. 2. Section of graft (No. 94) resident in a castrated female, from Sept. 20, 1933 to June 11, 1934, showing vestiges of seminiferous tubules. $\times 160$.
- Fig. 3. Section of graft (No. 69) attached to a non-castrated female, from Aug. 1, 1933 to June 11, 1934, containing active spermatocytes in various stages. $\times 160$.
- Fig. 4. Section of graft (No. 40) left in a non-castrated female, from Feb. 25, 1933 to March 27, 1933, indicating the degeneration of some seminiferous tubules. The graft contained only spermatogonia and spermatocytes (see Text-fig. 2, p. 233) at the time of implantation. $\times 100$.
- Fig. 5. Section of graft (No. 69) placed in a non-castrated female, from Aug. 1, 1933 to June 11, 1934, containing active spermatogonia in the process of forming seminiferous tubules. $\times 160$.
- Fig. 6. Section of graft (No. 92) taken from a non-castrated female, after remaining from Sept. 19, 1933 to June 11, 1934, having spermatogonia distributed among interstitial cells. $\times 160$.

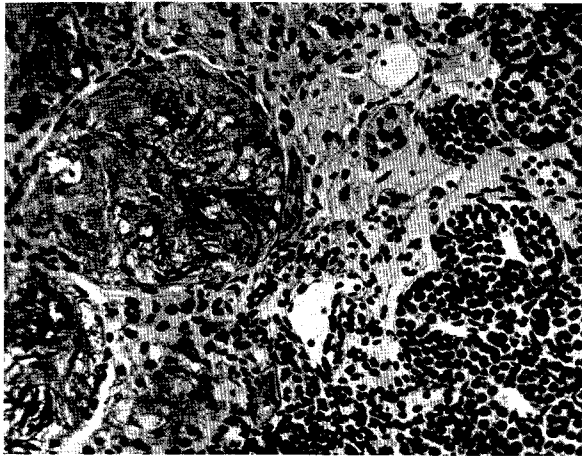


Fig. 1.

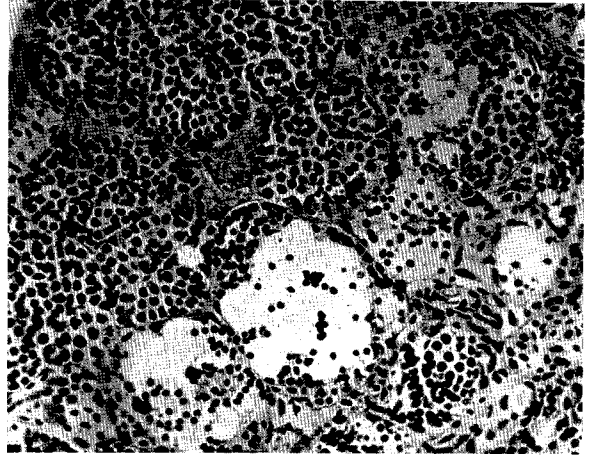


Fig. 4.

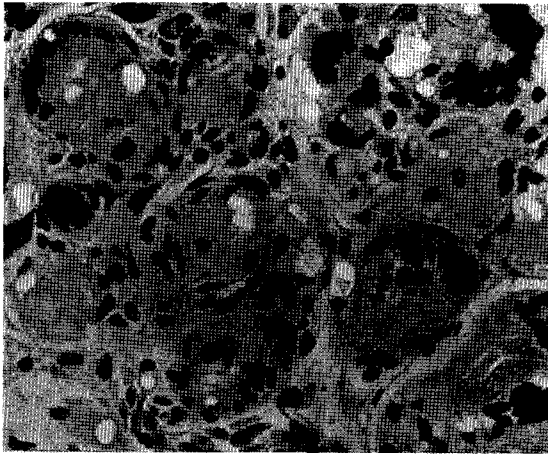


Fig. 2.

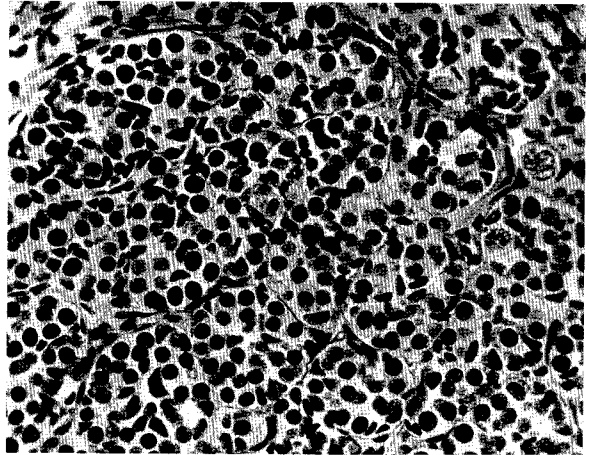


Fig. 5.

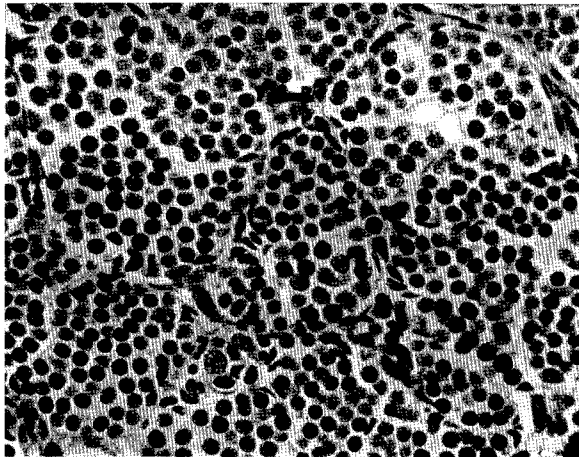


Fig. 3.

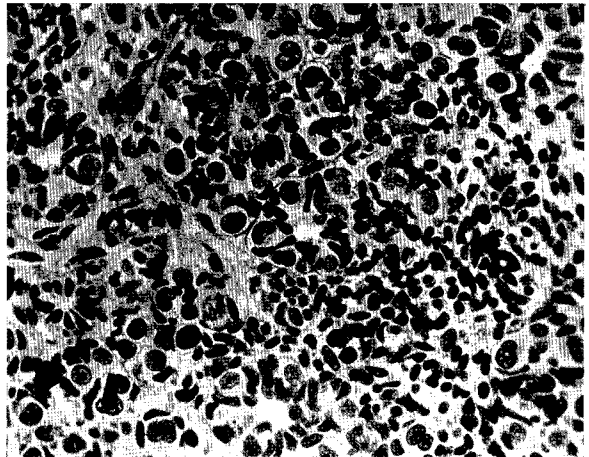


Fig. 6.