HOKKAIDO UNIVERSITY

Title	Masculinization and Feminization of Adult Triturus pyrrhogaster. : Pituitary-induced Sexual Reaction in the Experimented Animals (With Plates II-VI, 1 Table, and 2 Textfigures)
Author(s)	ICHIKAWA, Atsuhiko
Citation	北海道帝國大學理學部紀要, 7(2), 39-58
Issue Date	1940-05
Doc URL	http://hdl.handle.net/2115/27021
Type	bulletin (article)
File Information	7(2)_P39-58.pdf

Instructions for use

Hokkaido University Collection of Scholarly and Academic Papers : HUSCAP

Masculinization and Feminization of Adult *Triturus pyrrhogaster*. Pituitary-induced Sexual Reaction in the Experimented Animals[1]

By

Atsuhiko Ichikawa

Zoological Institute, Faculty of Science, Hokkaido Imperial University, Sapporo

(*With Plates II-VI, 1 Table, and 2 Textfigures*)

Problems

Host-graft experiments in adult form in which castration is followed by implantation of gonadal tissue of the opposite sex, have given us most of the evidences concerning masculinization and feminization effects in salamanders, notably the genus *Triturus* (Beaumont, 1929, *T. cristatus;* Adams, 1930, *T. viridescens;* and Ichikawa, 1937, *T. pyrrhogaster*). The subject animals given above in brackets are those of the works in which either transformation of rudimentary male oviducts in feminized males to a state of structure approaching that of the female, or marked hypertrophy of the female wolffian ducts in masculinized females, has been made very demonstrative, and the results of which have given us sufficient encouragement to pursue the subject further.

The experiments to be reported in the present paper deal with the masculinization and feminization effects of gonadal grafts of the opposite sex on the castrated or spayed bodies of the adult *Triturus pyrrhogaster* and are a continuation of my previous work (1937).

Under the experimental conditions where the sex hormone originating in the grafted gonad of opposite sex type has acted upon the host, it is seen that the direct stimulation of the hormone causes the development of all the rudiments of the sex characters

1) Contribution No. 139 from the Zoological Institute, Faculty of Science, Hokkaido Imperial University.

Jour. Fac. Sci., Hokkaido Imp. Univ., Series VI, Zoology, Vol. VII, No. 2, 1940.

of the opposite sex remaining in the host body. Owing to castration, however, the functional gonoducts are placed in an unfavourable state. The atrophy of these ducts is usually not accelerated but rather inhibited to some extent when the hormones of opposite sex type have been introduced by engrafting heterosexual gonadal tissue.

In the experiment reported in 1937 and the experiments which will be shown in successive pages, castration was always followed by implantation of gonadal tissue of the opposite sex after the lapse of a considerable length of time, *i.e.* about one year. The technique employed in these studies has an advantage over the methods used by previous investigators in which removal of gonads and implantation of heterosexual gonadal tissue were made simultaneously in one operative procedure; inasmuch as an unpublished protocol deposited in our laboratory tells us an experiment in which two procedures, *i.e.* castration and implantation, were performed simultaneously with this species without any distinct effect. According to the foregoing experiment it ought to be possible that the grafted gonad of the heterosexual nature may also in some manner favour the maintenance of the structure of the gonoducts representing the original sex type and this will indirectly interfere with the development of the parts of gonoducts appropriated to the hormone presumed to be acting. While, some considerable lapse of time between castration and gonadal transplantation will be instrumental in avoiding this possible contamination, because the gonoducts of original sex type have already been atrophied before the host is engrafted with the heterosexual gonadal tissue.

In the experiments of rather similar tendency that have hitherto been performed, the investigators have agreed in that certain length of survival (over 6 months) of the flourishing graft is necessary to secure decisive results. We must concede, however, that how long can persist the control of the somatic sex characters of the host by the grafted gonad of the opposite sex is still to be seen, since concrete evidence is lacking concerning the length of survival of grafted gonad which reacts upon the host body through the release of its own sexual hormone. Upon this, the experimental data herein reported will throw some light.

Inseparable from those problems of morphology of the affected parts are others relating to possible functions *i.e.* transmission of germ cells produced in grafted gonad, of the developed gonoducts

which are sexually heterotypic in relation to the original sex type of the host. But the latter have received little attention and have failed of experimental confirmation, despite the repeated experiments of this nature which have ultimately reached general agreement on what may be accomplished with the morphological changes.

In wishing to fill the existing gap, it seems of especial interest to study the effects of injections of the pituitary substances on the grafted ovary and developed oviducts of the feminized males. In fact, ovulation had occurred and mechanism which caused the ova to find and enter the fimbriated mouth of the oviduct, the ostium abdominale, had been established. At autopsy, the ova set free could be found in the peritoneal cavity on its way to the ostium abdominale or in the oviduct.

The kidney of this species is divisible into two regions of about equal extent: an anterior part, the sexual (genital) kidney, and a posterior part, the lumber (pelvic) kidney. And it is well known that the anterior part is sexually dimorphic. In the male it undergoes structural modification correlated with the assumption of the epididymal function.

Degeneration of the nephrostomes and structural modification of the parts of the renal tubule to male type, both of which are found in the masculinized females in this experiment, deserve especial mention. Taken as a whole, it is believed that the present contribution represents a fairly complete demonstration of masculinization and feminization in adult *Triturus pyrrhogaster*. The writer would like to take this opportunity, to acknowledge his indebtedness to Professor T. Uchida, whose advice and criticism in the course of work have been no little assistance to him.

The experiment

The experiments may be arranged in three procedures as follows; 1) the removal of the testes or of the ovaries; the effects of castration have been secured in both sexes; 2) the implantation of a small testicular piece into the females previously spayed and the implantation of a juvenile ovary into the males previously castrated are then to be followed. Reversal of somatic sex characters may proceed in either direction; 3) the administration of the whole pituitary glands of the same species by injections of suspensions of

the macerated glands into the masculinized and the feminized animals.

In the 'masculinization experiment' the subjects were 55 adult females of *T. pyrrhogaster*, which were submitted to the first operation at the beginning of April, 1936 for the removal of both ovaries with fat-bodies. Each experimental animal received a small testicular piece, consisting mainly of gonia and cytes, from the adult male of this species. These second operations were performed from January 21st to February 3rd of the next year (1937), and the testicular graft was brought to anchor to the right oviduct in the body cavity. The plan of the operative technique in this 'masculinization experiment' is essentially similar to that of my previous work (1937) in which a fuller account is given but for the sake of brevity it is omitted here.

For another series of experiments, *i. e.* the 'feminization experiment', 10 adult males of this species, each of which had been castrated in the middle of April, 1936, were prepared. Only three could be used as recipients of ovarian grafts in January, 1937, since seven had died in the interval between the time of castration and that of grafting. Later it was revealed that the experiments were successful with the result that in every individual with the engrafted ovary the feminization effects had been secured. The ovaries used were juvenile ones without any large oocyte with a goodly amount of yolk and pigment. At grafting, one such ovary was fixed with silk thread to the right wolffian duct that had been gashed at the level of the anterior end of the lumbar kidney.

As stated above, 55 spayed females were used as animals to receive testicular transplantation. The transformation of the female tail into the male type with well-developed fins was striking in 15 cases (about 27%). In eight of them the nuptial coloration was barely evident even in the tail region, whereas the remaining ones (7 in number) were found to be uniform in showing the distinct nuptial colouring. Accordingly, the most successful cases in this 'masculinization experiment' are found in these 7 animals, *i. e.* Nos. 4, 13, 14, 20, 23, 46 and 55 (Table I, Section A).

Two feminized males (Nos. 57 and 59) and one masculinized female (No. 55) were subjected to the pituitary administration. Suspensions were made by macerating in 0.5 cc distilled water the whole glands (2–5) of adult individuals and injections were made

TABLE I

Section A. Masculinization and feminization

Specimen	Date of castration	Date of grafting	Degree of influence	Months of high nuptial coloration
Masculinized female				
No. 4	4/ 1/36	1/22/37	+ + +	June—July, 38; Oct.—Dec., 38
No. 13	4/ 2/36	2/ 1/37	+ +	May, 38
No. 14	4/ 4/36	2/ 1/37	+ + +	June—Sep., 38; Nov.—March, 39
No. 20	4/ 6/36	2/ 1/37	+ +	Nov.—Jan., 39
No. 23	4/ 6/36	2/ 2/37	+ +	April, 39
No. 46	4/ 9/36	2/ 3/37	+ + +	June —Sep., 38
No. 55	4/10/36	1/27/37	+ + +	March—April, 38 (killed, 4/14/38)
Feminized male				
No. 57	4/16/36	1/19/37	+ + +	
No. 59	4/21/36	1/20/37	+ + +	
No. 60	4/22/36	1/20/37	+ + +	

Section B. Pituitary administration

Specimen No.	Date of 1st series of injections, total of glands in parentheses	Date of 2nd series of injections, total of glands in parentheses	Reaction
No. 57	April 11-18, 38 (19)	June 6-10, 38 (7)	Eggs in developed müllerian duct
No. 59	April 13-18, 38 (14)	April 13-25, 39 (26)	Eggs in peritoneal cavity and in developed müllerian ducts
No. 55	April 11-13, 38 (8)		Redevelopment of oviducts; engrafted testis was filled with spermatozoa
Control, ♀	April 11-13, 38 (8)		Laid eggs

into the body cavity of the experimental animal. Totals of the glands received by per animal are presented in Table I, B.

Observations

1. *Masculinizing effects of the engrafted testis*

In going through an account of the essential data of this 'masculinization experiment', it may not be redundant here to recall the writer's earlier work (1937), in which he (p. 78) described as follows: "in general, a survey of the observations made for the external changes which determine the male characters showed the following facts. The tail becomes wide and thin on account of the development of the dorsal and ventral fins. .....The head and tail skins become soft and smooth suggestive of those of the male, but in the trunk the coarse female skin is retained. Moreover, the tail skin is conspicuous for the appearance of the nuptial coloration. The parotoid glands behind the eyes enlarge greatly and the dorso-lateral and ventro-lateral ridges of dermal glands become distinct." Concerning the transformation of the female wolffian ducts into a state approaching that of the vasa deferentia, he found "the wolffian ducts, which in the female sex serve simply as urinary duct, assume some considerable size, though not up to the male standard (p. 78). The minute structure of these ducts, on microscopical examination, shows much resemblance to that of the male wolffian (urinogenital) ducts." Furthermore, the hypertrophied collecting ducts of the lumbar kidney and the development of all three sets of glands (pelvic, cloacal and abdominal) which lined the cloaca had been consulted.

All such symptoms of masculinization have also developed in each of the seven cases (respective numbers are 4, 13, 14, 20, 23, 46 and 55) in the present series. And the writer is in a position to deal with further evidence which should be added to them.

As compared with the experiment performed in 1937, the present series has a longer duration of grafting experiment. In relation to survival of the graft, the above seven stand as follows:

No. 4	No. 13	No. 14	No. 20	No. 23	No. 46	No. 55
758 days	730 days	864 days	711 days	799 days	650 days	443 days

No. 55 is an exception. The injections of the pituitary suspensions were made to it on 3 successive days and it was killed on the following day (April 14th, 1938). To this the writer will return later.

Nuptial coloration. In four animals (numbers 4, 14, 46 and 55) a deep shade of blue attained to such a degree as it appears in the normal male. The nuptial coloration was discernible not only in the skin of the tail but also in the neck and the trunk skins. The coarse female skin had already been replaced with the glandular one characteristic of the male. Further it was to be noted that in No. 4 and No. 14 animals two phases of high nuptial coloration had appeared in the course of the experiment. In No. 4 the first and the second phases persisted from June to July and from October to December, 1938 respectively, and in No. 14 the respective duration of the first and second was from June to September and from November to March of the next year (1939). Nos. 20 and 23 differ from others in that the first appearance of the high phase was lagging behind. It was not till November or even April of the next year that the nuptial coloration attained to the high phase. The essential data concerning the appearance of the nuptial coloration are presented in the right column of Table I, A.

The renal tubules of the sexual kidney. In considering the structural modification of the renal tubules of the sexual kidney found in the experimental animals, we may, for convenience, begin with a brief description of the normal structure of both sexes. The sexual kidney of *T. pyrrhogaster* is sexually dimorphic. In the female it consists of a single, longitudinal row of 15–20 renal tubules (Yamagiwa, 1924). Each tubule begins at a malpighian corpuscle and opens separately into the wolffian duct. The lumen of the malpighian corpuscle opens into a short, narrow ciliated tube which is known as 'ciliated neck' (Figs. A and B, Pl, III). The ciliated neck passes directly into a long, much convoluted part of the tubule, the epithelium of which is of a glandular character. This part may be called 'secretory part' or 'proximal convoluted tubule' (Fig. C, Pl. III). On the other hand, each renal tubule opens into the body cavity by a funnel-shaped opening, the 'nephrostome', through a ciliated tubule, the 'outer tubule' which passes into the ciliated neck (Figs. D. E. and F, Pl. III).

In the male, the malpighian corpuscle, the proximal convoluted

part and also more distal parts of the tubule are especially modified for carrying off spermatozoa. The renal tubules are connected at their malpighian corpuscles with the longitudinal duct of the kidney and the nephrostomes degenerate (Figs. L and M, Pl. III). Spermatozoa pass from the testis, through the vasa efferentia, the longitudinal duct and the renal tubules, to the wolffian duct. In the female the renal tubules of the sexual kidney are functional nephric units. While in the male, in virtue of the above-mentioned modification in structure, the tubules also acquire secondarily the function of the sperm conductor.

Closely allied to the aforesaid structural modification in the male, there was also found that in the renal tubules of the sexual kidney of the highly masculinized females. The nephrostomes always detach from the kidney units and at the same time show degenerative changes to a considerable extent as seen in figures G to J and K of plate III. The outer tubule, as such, cannot be made out. The ciliated neck passes directly to the proximal convoluted tubule, the epithelium of which displays a close resemblance to the male one (compare Figs. G–K and L, M, Pl. III). It is clear from the above description that the drastic changes which had been done with the female tubules resulted in the conversion of these structures into the male type. And it may safely be said that the male hormone originating from the engrafted testis acts directly but in a negative manner on the female tubules, since the outer tubule and the nephrostome have been eliminated from the sexual part of the kidney.

2. *Feminizing effects of the engrafted ovary*

In this section the subjects are the three animals (respective numbers are 57, 59 and 60). In every case of them the distinct feminizing action of the engrafted ovary upon the castrated host had uniformly been secured (Table I, A).

External appearance. While the operations for the ovarian implantation were done (on January 19th and 20th, 1937, 260, 255 and 254 days after castration, respectively), a search was being made for the remains of testicular tissue which might have been left behind. No such remains, however, were found in any of the three cases. Externally, the general integument of these animals in castrated condition became less slimy owing to the weakening

secretory activities of the dermal glands. The parotoids and also the dermal ridges formed of aggregated glands in the trunk region were much reduced. The dorsal and ventral fins of the tail shrank to some extent. Of the nuptial coloration no trace remained. The cloaca regressed in size.

Speaking generally, these morphological changes which follow castration were preserved after the ovarian graft. But in the course of the experiment a certain indication of the development of the engrafted ovary could be seen in the bulginess of the belly, though slight in degree. Thus the experimental animals took apparent femaleness in external features (Fig. G, Pl. II).

Textfig. 1. Photograph of dissection of No. 60 feminized male. Note enlargement of müllerian ducts and ovarian graft. × 1.

The gonoducts. One of the highly feminized males (No. 60) was killed in February 26th, 1938, 392 days after being engrafted with an ovary. When the animal was opened, the enlargement of the rudimentary müllerian ducts was striking. These ducts had widened throughout their length, following the convolutions of the wolffian ducts, since the former ducts ran longitudinally along, and in the same sheath with, the latter ducts. Anterior to the kidney these enlarged müllerian ducts had also shown much convolution (Textfig. 1).

In the male sex of this species, the part of the müllerian duct anterior to the kidney is a slender cord containing a narrow lumen lined with an epithelium, composed of from five to seven cells per cross section (Fig. E, Pl. V). Serial sections throughout its extent show that this lumen is closed with the collapsed epithelium in places. Anteriorly this cord reaches the limits of the body cavity just behind the pericardium. Here it bends laterally and opens into the body cavity by a vestigial ostium abdominale.

Redevelopment of the vestigial ostium abdominale to a state equalling that of the functional female structure had been made

very demonstrative in this experimental animal (No. 60). The wall of the anterior end of the enlarged müllerian duct flared out to form a sizable, funnel-like opening. The differentiation of the ciliated epithelium was well established in the anterior part of the duct. Thus the opening which marks its anterior end may display a close resemblance to the fimbriated ostium of the female oviduct. At the level of the anterior part of the kidney, the lining epithelium of the duct formed longitudinal plications of somewhat irregular arrangement which, in cross-section, were nearly obliterating the lumen of the duct. The epithelium was composed of tall, columnar, glandular cells whose cytoplasm stained a faint pink in the hematoxylin-eosin slide and was coarsely granular in structure. Among the glandular cells were scattered a relatively small number of conical, ciliated cells. Their cytoplasm was homogeneous, finely granular and eosinophilic.

In the posterior part of the duct which lay along the lumbar kidney the convolution was rather slight, in comparison with that of the anterior part. The mucosa which lined this part of the duct was characteristically composed of cells full of eosinophile granules. Concerning the wolffian duct of this experimental animal, it is sufficient here to say that it appeared much like that of the castrate without ovarian graft, except that it was in a more dilated condition and contained more secretion than was found in the castrate, especially in the anterior part of this duct.

3. *The effect of pituitary administration in the feminized male*

It is clear from the description given above that morphologically the hypertrophy of the rudimentary oviducts of the male is nearly so perfect as to assume the functional female structure. But we are quite at a loss to understand the possible function of these hypertrophied müllerian ducts. This aspect of the problem has been studied with the method of the pituitary administration. The essential data concerned have already been given in table I, section B. Here the writer will give a somewhat fuller account of the No. 59 animal. In this very animal he was able to demonstrate to his satisfaction the process which set free the ova originating from the

engrafted ovary and enabled them to find and enter the abdominal end of the hypertrophied müllerian duct.

The No. 59 animal, whose photograph taken in March of 1938 is shown in Fig. G, Pl. II, has the following history. On April 21st, 1936, the testes were removed on both sides. On January 20th of the next year, it underwent the second operation and one of the long and slender ovaries of a juvenile female was placed in a slit through the vas deferens of the right side with a silk thread for a ligature. About one year later, in early spring of 1938, the external appearance in general was much like that of a female. From April 13th to 18th, 1938, the animal received a total of 14 whole pituitary glands (macerated in distilled water) administered in four doses. Just one year later, 26 whole glands were for the second time injected over a period of 13 days (from April 13th to 25th, 1939). This time the glands administered were approximately twice as much as in the former procedure. Two days later (April 27th), it was anaesthetized in 0.5 per cent chloretone and the vivisection was made in a dissecting dish containing Ringer's solution. The freshly opened animal was pinned out and photographed, in order to expose hypertrophied müllerian ducts and grafted ovary by the removal of the gastro-intestinal tract, as shown in Fig. A, Pl. IV. Figure B in the same plate is also a photographic representation of it, after being fixed *in toto* in Bouin's fluid.

When the animal was opened, ten ova which had been freed from the grafted ovary could be seen in the abdominal cavity. Most of the free ova were found in the cephalic part of the cavity and the fact that the wide funnel of the right oviduct (hypertrophied müllerian duct of the male) had been blocked up with one of these ova may be clearly represented in Figs. A and B, Pl. IV (note arrows). A section through the flaring wall of the right funnel including the ovum is shown in Fig. D, Pl. IV. Further, some ova which had entered both of the oviducts through their respective funnel were seen through their translucent wall. But all the ova engulfed in the anterior part of the oviduct had been disintegrated in a considerable degree. That in the posterior part only the remains of destroyed ova could be seen was later confirmed, together with the fact just stated above, by histological study. Accordingly, the complete ovulation could not be induced in this animal, though

the mechanism which causes the ovum to find and enter the abdominal end had been well established.

It is important to note that in both right and left wolffian ducts, at the level of the sexual kidney, an anomaly which is not simple and is worth going into at some length has been found. In some parts of the duct of this region, there was a considerable expansion while in others the diameter was much reduced and the connective tissue sheath appeared much thicker and the tissue was more compactly arranged than in the expanded part. In transection, the thickness of the connective tissue sheath and the height of the glandular cells forming the lining epithelium of the expanded parts varied somewhat with the state of distension. The free border of the lining epithelium was rather irregular. The cytoplasm was finely granular and was usually more or less deeply stained in eosin (Fig. I, Pl. V and Figs. A, B, Pl. VI). A remarkable fact was that in some places the lumen of the expanded part of the wolffian duct became continuous with that of the hypertrophied müllerian duct, which was bound by the same peritoneal membrane that supported the former duct. Thus it is natural that the remains of destroyed ova can enter the parts of the wolffian duct through the hypertrophied müllerian duct. This is shown in figure I in plate V.

As shown by textfigure 2 A–E, drawings from appropriate sections representing the anterior part of the urinogenital system of this animal were made with the aid of a camera lucida. The most distal part of the renal tubule (I) runs towards the lateral edge of the kidney to form a collecting tube (II). Figure H in plate V is a photomicrograph of the same section from which textfigure 2 C was drawn. Histologically, the epithelium of the collecting tube consists of cuboidal cells, the cytoplasm of which is finely granular and eosinophilic. It is surrounded by a thin connective tissue layer. A gradual transition exists between the epithelium of the most distal part of the renal tubule and the epithelium which lines the collecting tube. The lumen of the collecting tube opens into duct III. This duct is continuous distally with a large, much convoluted duct (IV–VII) which has a wide lumen lined with a columnar epithelium, the cells of which have basally located nuclei and a coarsely granular cytoplasm in which are scattered many vacuoles. This part is the hypertrophied müllerian duct. The epithelium is continuous with and indistinguishable from that of duct III. Hence

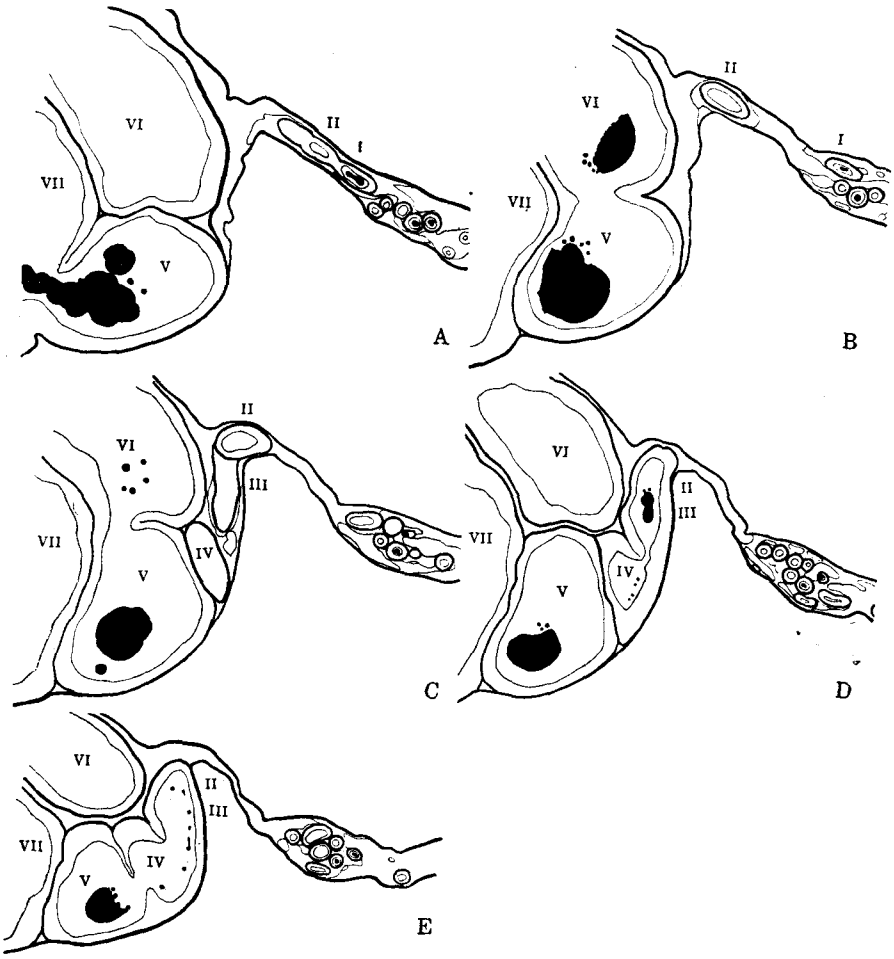

Textfig. 2 A-E. Camera lucida outline drawings from serial sections through hypertrophied müllerian ducts and kidney of No. 59 feminized male, illustrating the incorporation of müllerian duct with wolffian duct. Only right side is shown: I, distal end of renal tubule; II, collecting tube of kidney which opens into III, structurally modified and expanded part of wolffian duct; IV-VII, parts of hypertrophied müllerian duct; yolk mass, solid black, × 35ca.

in these sections there is no trace of the original structure of the male wolffian duct. It seems probable that duct III is the structurally modified and expanded part of the wolffian duct. The lumen of the hypertrophied müllerian duct of this region contained many frag-

ments of the destroyed ova, and small masses of degenerating yolk granules which in all probability might have originated from these broken ova were found in the renal tubules (Textfig. 2 A–E—solid black).

At the level of the lumbar kidney, however, the lumen of the müllerian duct never joined that of the wolffian duct. As stated in the preceding section, the müllerian duct had become a prominent duct and ran along the ventral wall of the wolffian duct, enclosed in the same connective tissue sheath (Fig. C, Pl. VI), finally opening into the cloaca (Fig. D, Pl. VI). The epithelium of the wolffian duct had lost its histological character and became very thin. The connective tissue sheath on the other hand had thickened (Fig. C, Pl. VI). As the wolffian duct passed posteriad it gradually diminished in size. Near the posterior end of the lumbar kidney the duct was a narrow tube lined with closely packed, cuboidal epithelium and finally opened into the cloaca by a minute pore (Fig. E, Pl. VI). In figures C and D in plate VI the degenerating yolk masses in the lumen of the wolffian duct are to be seen. It will give added proof of the fact that the hypertrophied müllerian duct communicates with the wolffian duct in this animal.

4. The effect of pituitary administration in the masculinized females

In every one of the highly masculinized females of the present experiment, marked hypertrophy of the female wolffian duct had been secured, although the transformation of the duct into a vas deferens was quite imperfect as compared with the conversion of the rudimentary müllerian duct of the feminized males to a state equalling that of the functional oviduct. On the other hand, the system of vasa efferentia and the longitudinal duct of the kidney was lacking. Only degeneration of the nephrostomes and the structural modification of the parts of the renal tubule to male type were found in the anterior part of the kidney.

The effect of the pituitary hormones from without upon the grafted testis and the urinogenital ducts of such a masculinized female as No. 55 had been studied by the injections of the pituitary suspensions. It received a total of eight whole glands administered in three doses. The injections were performed on three successive

days, from April 11th to 13th of 1938. The animal was killed on the following day and after it had been dissected and fixed *in toto* in Bouin's fluid, the grafted testis and the urinogenital system were cut for microscopic study (Table I, Section B).

In serial sections it was revealed that the whole of the grafted testis consisting of mature spermatozoa which had been released into all of the seminiferous tubules. Since any structure such as the vasa efferentia which connect the testis with the kidney was not found in this animal, these seminiferous tubules came to be filled with aggregations of spermatozoa destined to degenerate remaining in the tubules. It may safely be said that this release of spermatozoa is a direct response of the grafted testis to the pituitary hormones from without. On the other hand, the pituitary administration did not bring about any heightened activity in the wolffian duct, but it had an added effect which was so definite as to require special consideration.

The oviduct of this animal, at the time of autopsy, appeared much like those of the feminized male No. 59 which had been injected with the same pituitary hormones. Histologically the resemblance was most striking. It was found that the hypertrophied oviduct had recovered its secretory activity and the glandular cells of the lining epithelium had thickened, nearly obliterating the lumen. But the outer sheath had remained very thin and the duct, throughout its extent, appeared somewhat translucent. From the description presented above it is in highest degree probable that the pituitary hormones from without had stimulated, in some way or other, the oviduct of this experimental animal. We come next to the question of the manner in which the pituitary hormones exert their effect on the degenerated oviduct. Is the effect due directly to the pituitary hormones from without or to the presence of the grafted testis which has become stimulated and will release the 'male sex hormone'? But a discussion of this question must be reserved for further study.

In passing, it is of interest to note that in only one case (No. 13) the seminiferous tubules of the grafted testis was found to open into the right oviduct, to which the graft had been brought to anchor, through a short, narrow duct which was lined with more or less closely packed, non-ciliated, cuboidal epithelium. As judged from its cellular picture it might be a continuation of the collecting

duct of the grafted testis. This connection between the duct and the right oviduct will be seen in figures F and G in plate IV. That the duct had actually conveyed spermatozoa to the right oviduct was further confirmed by the fact that sperm masses were found in the lumen of the latter duct posterior to the point where it had become communicated with the former duct (Fig. H, Pl. IV). The right oviduct, as well as the left, had been much reduced in size. The collapsed condition of the cells forming the lining epithelium (Fig. G, Pl. IV) was similar to that found usually in other masculinized females of this experiment. But in some posterior regions of the right oviduct, the state of distension caused by the mass of spermatozoa was seen (Fig. H, Pl. IV). In the part which lay next to the lumbar kidney, the lumen had become narrower and contained no spermatozoa. The openings of the oviducts into the coloaca had also been narrowed on both sides (compare Figs. F and D, Pl. VI). The pituitary administration in such an individual as No. 13 must be of special interest. But the experimental confirmation for this has failed.

Conclusions

As a result of the analysis presented in this paper a number of factual conclusions have been reached regarding the effects of the grafted testis on the spayed females of *Triturus pyrrhogaster* and also the ovarian graft on the castrated males of the same species. In his preceding study (1937) the writer showed the fact that in his host-graft experiment the testicular grafts were often so successful and the female hosts completely ovariotomized were so responsive that the external appearance had become masculinized completely; the hypertrophy of the female wolffian duct and the development of the secretory activity characteristic of the male in the hypertrophied collecting ducts of the lumbar kidney had been secured nicely. The first series of the present experiments, *i. e.* the 'masculinization experiment' has been carried on by essentially the same procedures and the same material used by him previously. And the earlier results were extended by the demonstration of the mode of appearance of nuptial coloration in the female skin and the structural modification of the anterior part of the female kidney to male type.

Of major interest is the fact that in two of the highly masculinized females (Nos. 4 and 14; see table I, section B) had been shown two definite phases of high nuptial coloration. This may also give an indirect proof of the fact that season had some influence on the activity of the potent graft.

Likeweise the rudimentary müllerian ducts of the castrated male gave a definite response to ovarian hormones originating from the grafted ovary. The activity provoked in the rudimentary müllerian ducts was demonstrated by the histological preparations. Furthermore, the partial ovulation, *viz.* the process which frees the ovum and enables it to find and enter the abdominal end of the developed müllerian duct, was induced in the pituitary stimulated individuals (Nos. 57 and 59).

The injections of the pituitary substance were also made into the masculinized female (No. 55). The grafted testis had become stimulated and all of the seminiferous tubules were filled with mature spermatozoa. There was no evidence of the stimulation on the wolffian ducts. Even more puzzling is the fact that the degenerating oviducts were restored.

Literature

ADAMS, A. E. 1930 Studies on sexual conditions in *Triturus viridescens*. The effects of ovarian grafts in castrated males. Jour. Exp. Zoöl., vol. 55, pp. 63–85.

——— 1938 Sexual conditions in *Triturus viridescens*. Artificial hermaphroditism. Jour. Exp. Zoöl., vol. 78, pp. 233–269.

ADAMS, A. E. and J. DUDLEY. 1933 Sexual conditions in *Triturus viridescens*. Artificial hermaphroditism with pituitary treatment. Anat. Rec., vol. 57, no. 4, p. 34, abs.

BEAUMONT, J. DE. 1929 Les caractères sexuels du *Triton* et leur déterminisme. Masculinisation et féminisation. Arch. d. Biol., t. 39, pp. 175–245.

——— 1933 La Différenciation sexuelle dans l'appareil uro-génital du *Triton* et son déterminisme. Roux' Arch., Bd. 129, S. 120–178.

BURNS, R. K., JR. 1938a Hormonal control of sex differentiation. Am. Nat., vol. 72, pp. 207–227.

——— 1938b The effects of crystalline sex hormones on sex differentiation in *Amblystoma*. I. Estrone. Anat. Rec., vol. 71, pp. 447–467.

——— 1939 The effects of crystalline sex hormones on sex differentation in *Amblystoma*. II. Testosterone propinate. Anat. Rec., vol. 73, pp. 73–93.

CHASE, S. W. 1923 The mesonephros and urogenital ducts of *Necturus maculosus*, Rafinesque. Jour. Morph., vol. 37, pp. 457-531.

HANAOKA, K. I. 1936 Experiments on the nuptial coloration of the common Japanese newt, *Triturus pyrrhogaster* (Boie). Jour. Fac. Sci., Hokkaido Imp. Univ., Ser. 6, Zool., vol. 5, pp. 113–119.

ICHIKAWA, A. 1936 Masculinization by testicular transplantation in spayed female *Triturus pyrrhogaster* with remarks on testis-ova and the modification of lateral-line organs. Jour. Fac. Sci., Hokkaido Imp. Univ., Ser. 6, Zool., vol. 6, pp. 71–86.

MCCURDY, H. M. 1931 Development of sex organs in *Triturus torosus*. Am. Jour. Anat., vol. 47, pp. 367–403.

RODGERS, L. T. and P. L. RISLEY. 1938 Sexual differentiation of urogenital ducts of *Ambystoma tigrinum*. Jour. Morph. vol. 63, pp. 119–141.

UCHIDA, T. 1935 Studies on sexuality of Amphibia. I. Transplantation of testis in a newt, *Triturus pyrrhogaster* (Boie). Jour. Fac. Sci., Hokkaido Imp. Univ., Ser. 6, Zool., vol. 4, pp. 231–253.

WITSCHI, E. 1936 On the separate chemical control of embryonic sex differentiation and of secondary sex characters. Bull. Soc. Biol. Lettonie, vol. 5, pp. 79–85.

——— 1937 Stimulative and inhibitive induction in the development of primary and secondary sex characters. Proc. Nat. Acad. Sci., vol. 23, pp. 35–39.

YAMAGIWA, S. 1924. Das Urogenitalsystem der Urodelen. Jour. Coll. Agri., Hokkaido Imp. Univ., vol. 15, pp. 37–82.

Explanation of Plate II

All figures were photographed while under a chroletone anaesthetic.

A. Lateral view of a normal female. ×1.

B. Lateral view of a normal male. ×1.

C. Lateral view of a masculinized female, No. 55. ×1.

Figures A, B and C were photographed on April 4th, 1938.

D. Dorsal view of a normal male. ×1.

E. Dorsal view of a masculinized female, No. 55.

Photograph taken in March, 1938. ×1.

F. Dorsal view of a normal female. ×1.

G. Dorsal view of a feminized male, No. 59.

Photograph taken in March, 1938. ×1.

Explanation of Plate III

Photomicrographs of serial sections through the sexual kidney of a normal female (A—F), of a masculinized female, No. 55 (G—K) and of a normal male (L, M), illustrating the sequence and arrangement of parts of renal tubules. The renal corpuscle situates close to midventral surface of the sexual kidney. All figures are at the same magnification of ×65: c, 'ciliated neck' d, degenerating nephrostome; 1, longitudinal duct of male kidney; n, nephrostome; o, 'outer tubule;' s, 'secretory part.'

Explanation of Plate IV

A. Freshly opened feminized male, No. 59, two days after being injected with pituitary suspensions. Removal of the gastro-intestinal tract exposes the urino-genital organs. Note especially that the wide funnel of the right oviduct is blocked up with an ovum. ×2.3.

B. The same as A, but fixed *in toto* in Bouin's fluid. ×2.

C. Dissection of a normal female. Fixed in Bouin's fluid. ×2.

D. Cross-section through the right ostium abdominale of No 59. Part of the ovum contained is shown. ×50.

E. Part of cross-section through the left oviduct of No. 59 just posterior to the ostium abdominale. Differentiation of ciliated cells is remarkable in the lining epithelium. ×165.

F and G. Two successive sections showing the connection (c) between the collecting duct of the grafted testis and the right oviduct of a female host (No. 13) : e, emptied seminiferous tubule. ×50.

H. Part of cross-section at the level of lumber kidney showing the right oviduct which is in the state of distension caused by the mass of spermatozoa (No. 13). ×35.

Explanation of Plate V

A. Cross-section through the right oviduct of a normal female near its anterior end. Three sections (1, 2 and 3) of the convoluted duct are seen. 1 is morphologically most anterior and has ciliated epithelium. The most part of the lining epithelium of 2 is composed of tall, columnar cells seated on the longitudinal ridges of connective tissue. ×50.

B. Cross-section through the anterior part of the right oviduct of No. 13. Note the collapsed condition of the lining epithelium. ×50.

C. Cross-section through the right oviduct of No. 59 just posterior to the ostium abdominale. The duct is distended by the engulfed ovum (D in Pl. IV), only a part of which is shown in this figure ×50.

D. Cross-section at the same level of C showing the left oviduct of No. 59. ×50.

E. Male müllerian ducts anterior to the kidney. Note small size of the ducts. ×50.

F. and G. Right (F) and left (G) oviducts of No. 57 near their anterior ends. Hypertrophy of the ducts is less perfect as compared with C and D. ×50.

H. Cross-section through much convoluted part of the oviduct which lies along the sexual kidney of No. 59. The distal end of collecting tube of the kidney (ck) is shown in cross-section, the renal tubule is also seen at the extreme right. Explanatory sketch of the same section is presented in Text-fig. 2C. ×50.

I. Cross-section taken more posteriorly showing the expanded and structurally modified wolffian duct containing the remains of destroyed ova. The mucosa of the oviducal part is shown in pale tone. ×50.

Explanation of Plate VI

A. Cross-section at the level of posterior part of sexual kidney showing expanded wolffian (2) and hypertrophied müllerian ducts of No. 59. Two different mucosae of the oviduct are seen, one (1) is composed of cells full of eosinophile granules and the other (3, 4) has cells whose cytoplasm stains a faint pink. ×50.

B. Three cross-sections of wolffian and müllerian ducts at the level of lumber kidney of No. 59. Note that the thickness of the outer wall of wolffian duct varies with the state of distension. ×50.

C. Part of the cross-section through posterior part of lumbar kidney of No. 59 showing wolffian and müllerian ducts of this level. Note closely packed, low epithelium of wolffian duct in which yolk mass appears dark: K, kidney; M, müllerian duct; Uc, urinary collecting duct; W. wolffian duct. ×50.

D. Cross-section showing the opening of müllerian duct into cloaca (C) of No. 59. Note small size of wolffian ducts near their posterior ends. ×50.

E Cross-section taken more posteriorly showing openings of wolffian and urinary collecting ducts into cloaca of No. 59. ×50.

F. Cross-section through cloaca of a masculinized female (No. 13) showing the opening (X) of degenerating oviduct into cloaca. ×50.

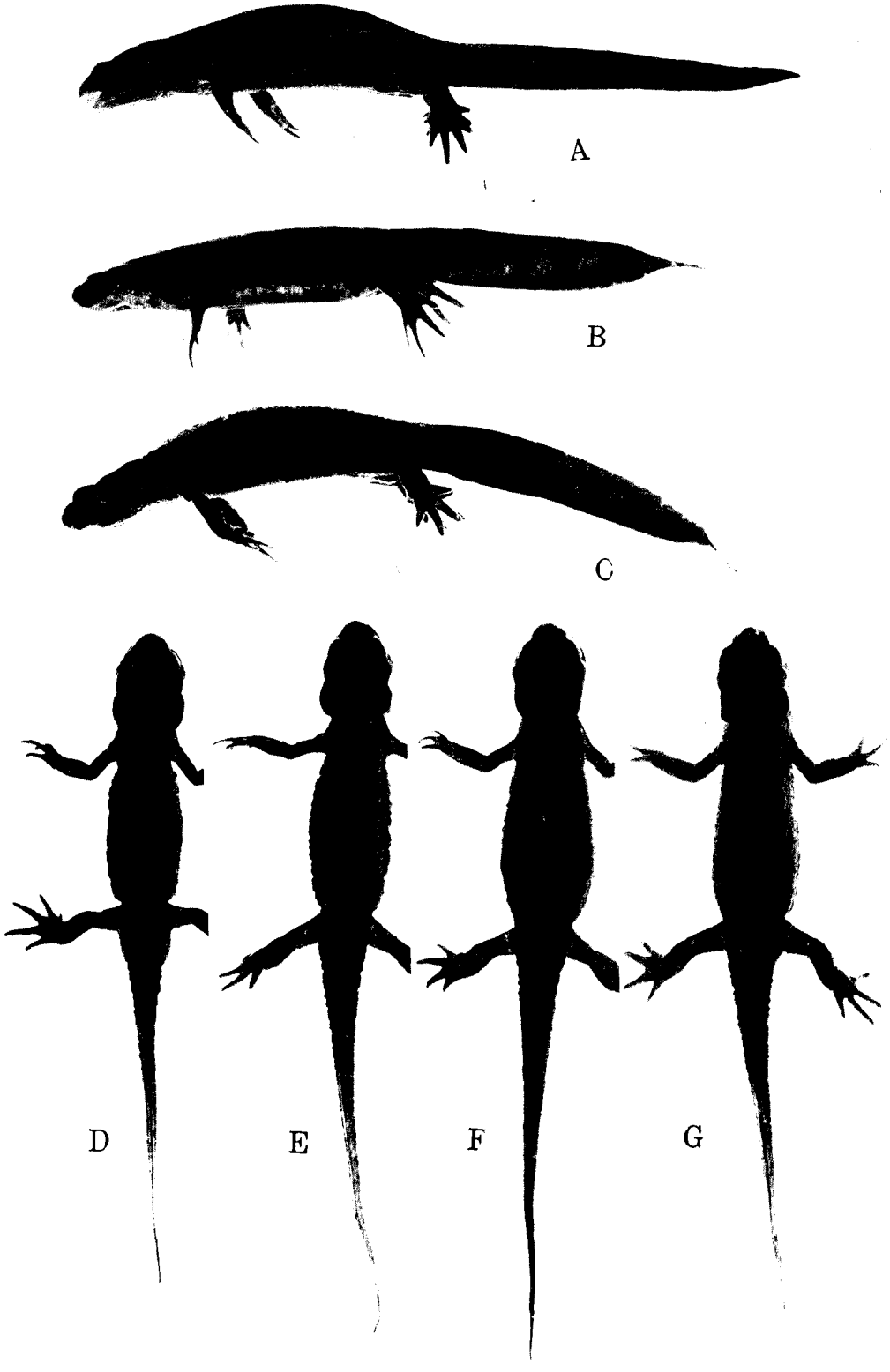

A. Ichikawa : Masculinization and feminization

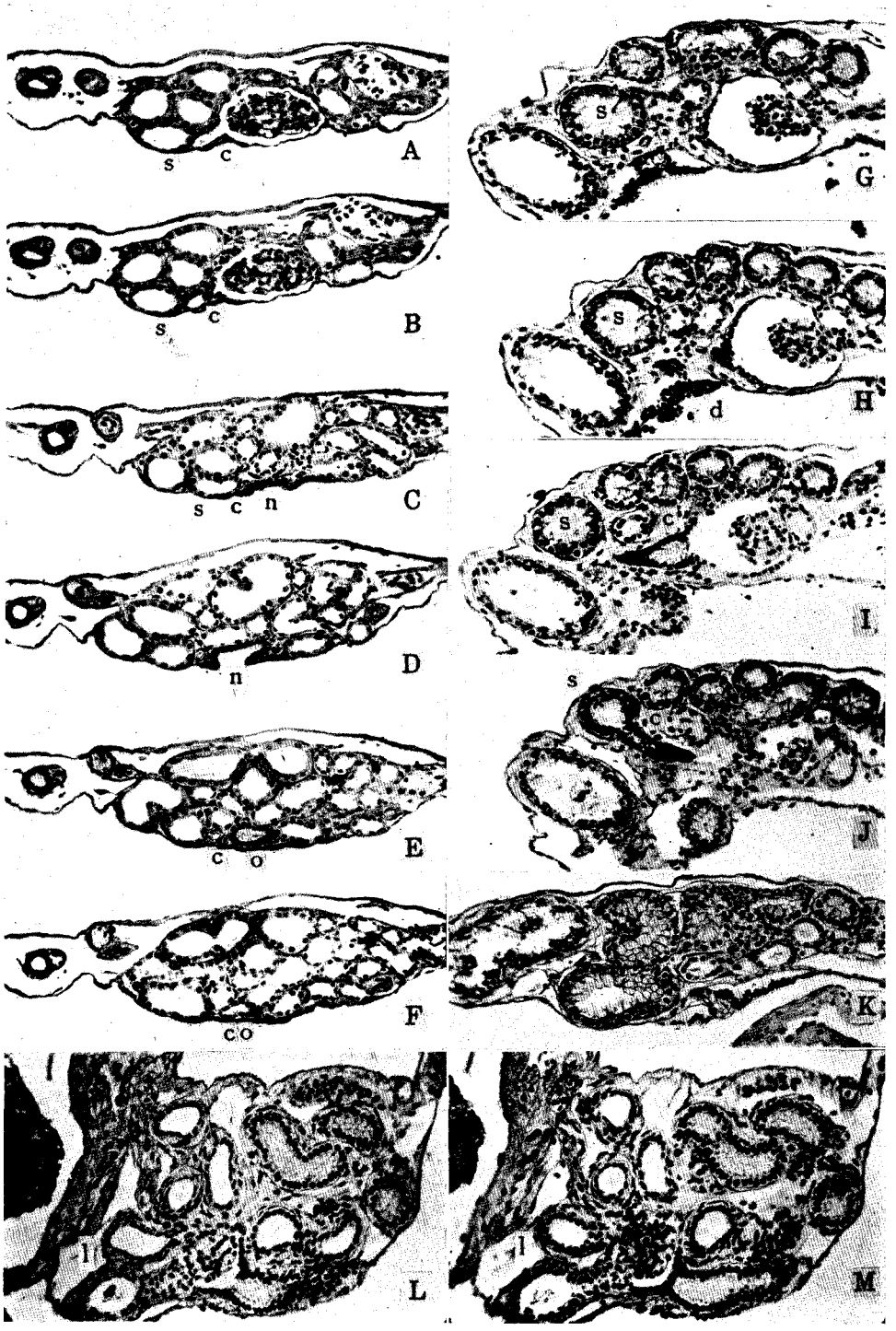

A. Ichikawa : Masculinization and feminization

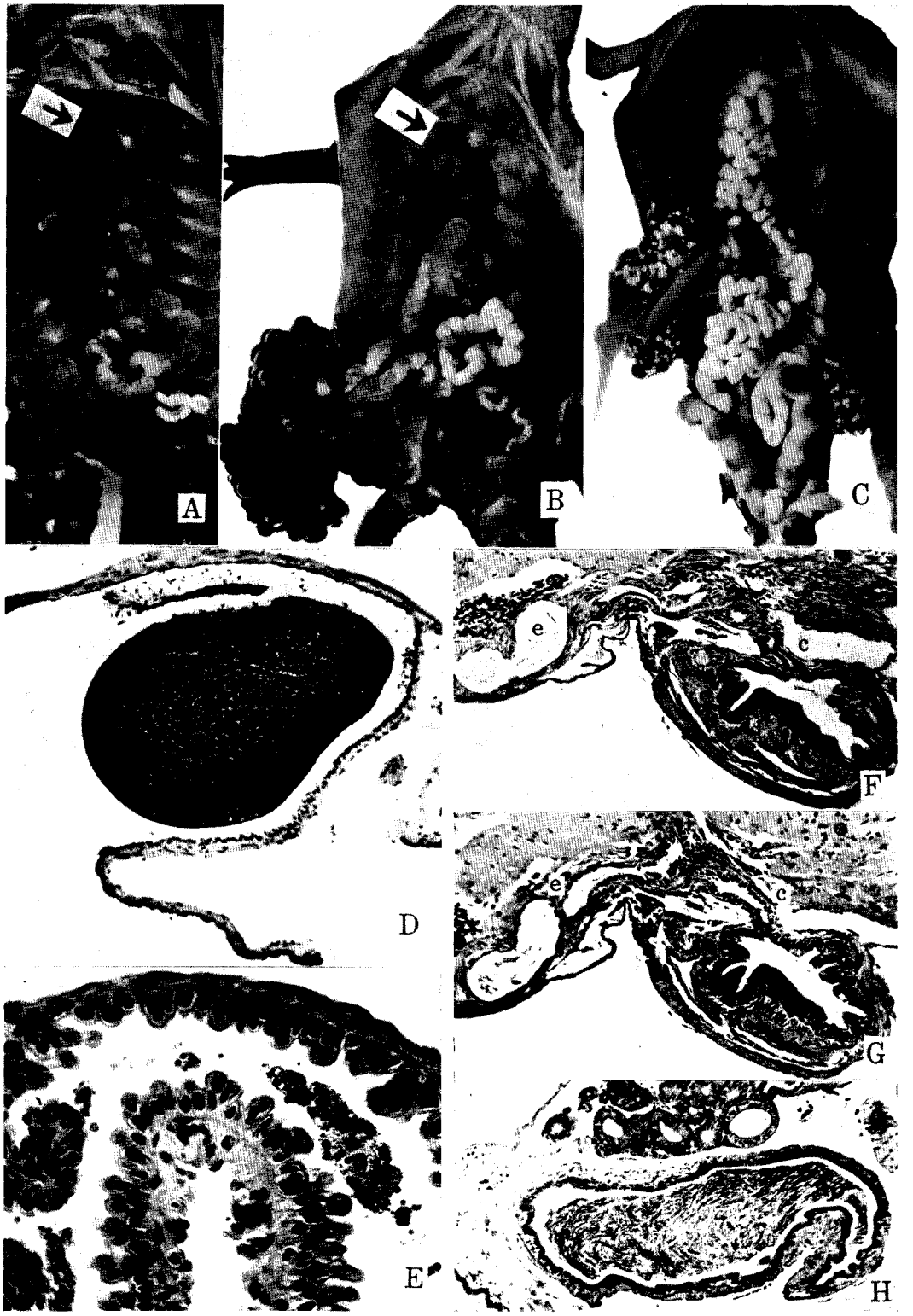

A. Ichikawa: Masculinization and feminization

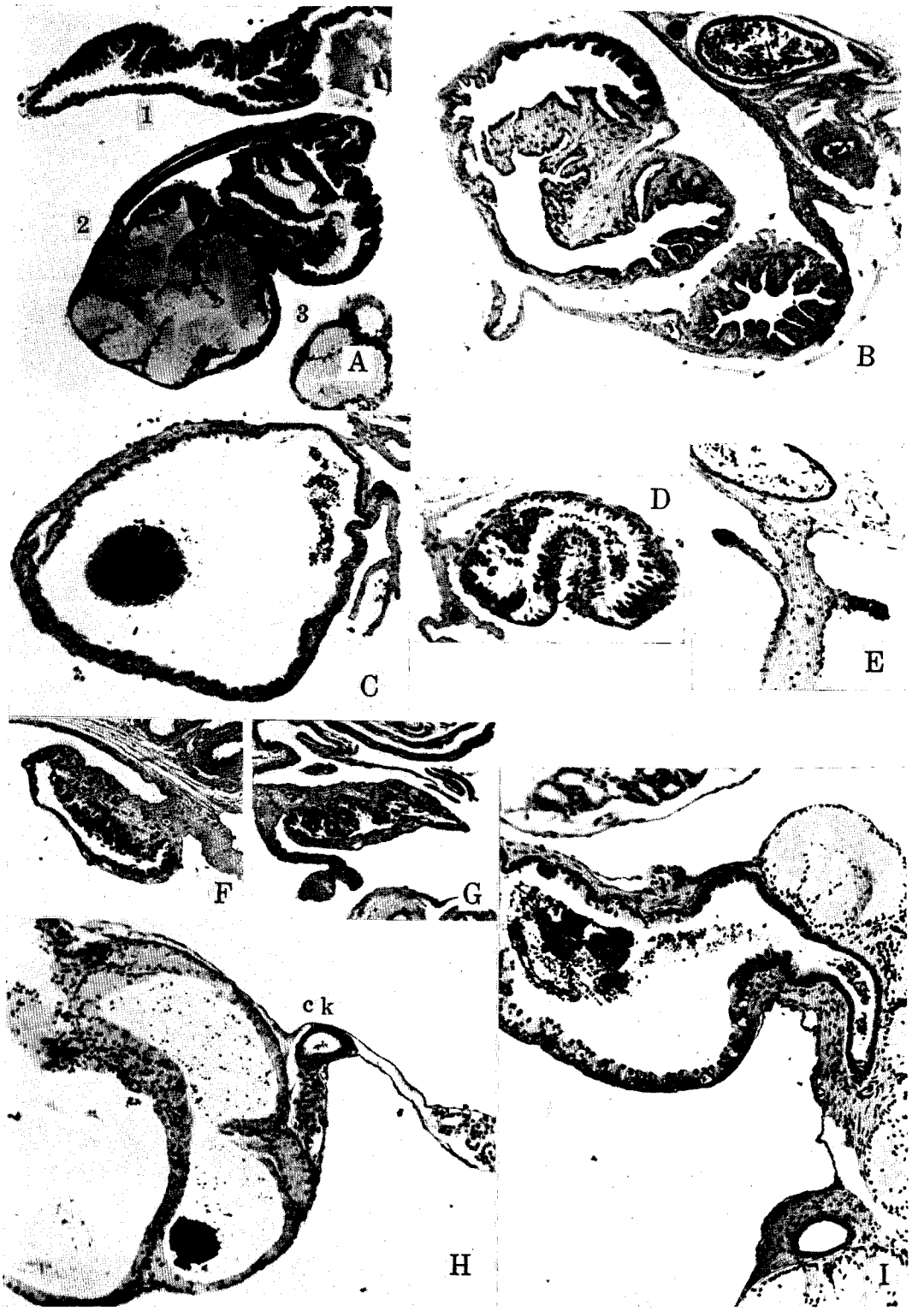

A. Ichikawa: Masculinization and feminization

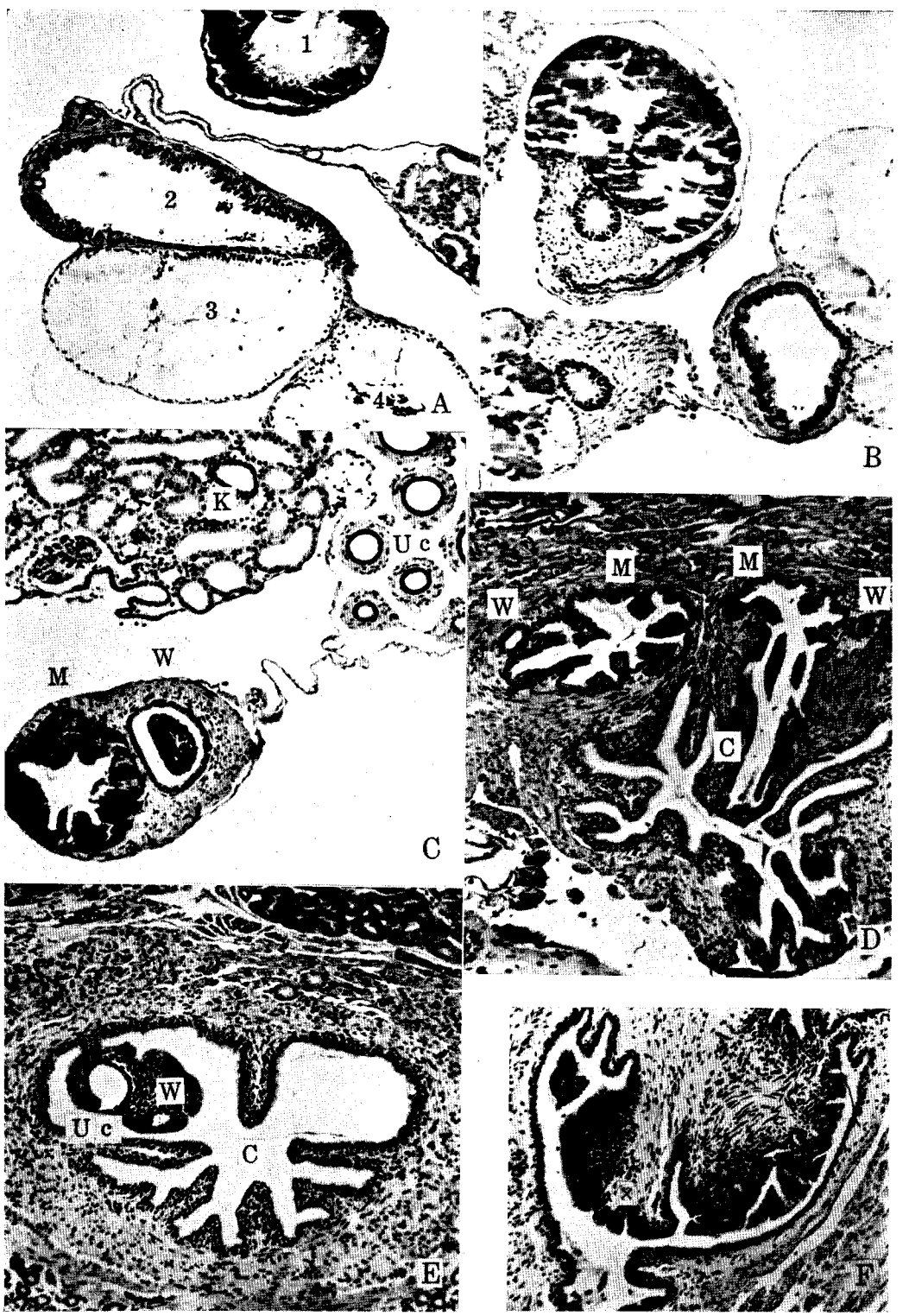

A. Ichikawa: Masculinization and feminization