A Remarkable Swelling of Male Skin of a Salamander (*Hynobius retardatus* Dunn) in the Breeding Season[1)]

By

Tomoji Aoto

Zooiogical Institute, Faculty of Science, Hokkaido University, Sapporo

(*With* 2 *Textfigures*, 1 *Table and* 1 *Plate*)

It is well known that in *Hynobius retardatus*, the only urodelan insulator in Hokkaido island, the male undergoes a marked dermal swelling during its breeding season. Leydig (1892) observed a similar phenomenon in *Triton cristatus* and *Rana fusca*. Regarding its morphological significance, however, no studies have yet been attempted. Thence, the writer studied this problem and obtained the following results.

Prior to description of the work, the writer takes pleasure to express his gratitude to Prof. Tohru Uchida of our institute at whose suggestions the work was begun and by whose valuable guidance it has taken its shape. The writer is also indebted to Prof. Atsuhiko Ichikawa for his helpful criticism.

The adult of the salamander is a terrestrial inhabitant all the year round except for during its breeding season which begins in early April and lasts about three weeks in the vicinity of Sapporo. The male remains in water rather longer, or perhaps throughout the period, whereas the femule leaves water immediately after the spawning. Thus, roving around the egg clusters, males can be easily captured in large numbers.

The phenomenon above mentioned does not maintain long in the laboratory so that the animals must be fixed upon their caption. Before killing and fixation anesthesia by 0.5 % chloreton solution is always occurred. They were fixed at first *in toto*, and then, after having been

1) Contribution No. 232 from the Zoological Institute, Faculty of Sclence, Hokkaido University, Sapporo, Japan.

Jour. Fac. Sci. Hokkaido Univ. Ser. VI, Zool. **10**, 1950.

partially fixed they were separated into several pieces in the fixative. For fixation 10% formal solution, Bouin's solution and Zenker's solution were used. Serial sections were cut 10μ thick and were stained with Delafield's haematoxylin and eosin. For special purpose, Bielschowsky's silver impregnation method was employed.



1

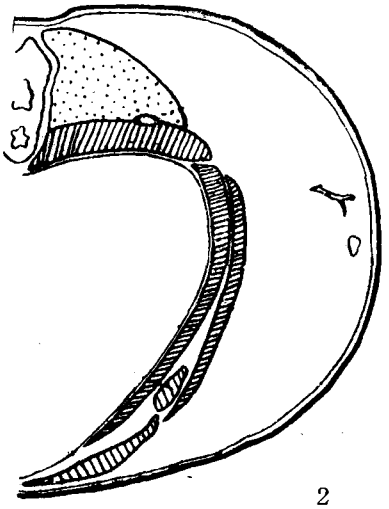

2

Textfig. 1. *Hynobius relardatus* during breeding seasn. The male (left) represents a remarkable swelling of the skin throughout the body, while in the female (right) swelling occurs only in the belly owing to fully grown ova in the oviducts.

Textfig. 2. Schematic drawing of the cross section through the middle part of body, showing a dermal swelling in the male of the breeding season.

Observations

Male specimens in the season show a marked swelling of the dermis of the head, neck and trunk, especially in the lateral sides, with distinct rib furrows (Text-fig. 1), On the other hand, the female shows a remarkable swelling in the belly before the spawning on account of fully grown eggs in the oviducts but after spawning on indication of swelling is observed. Having removed the skin with pincettes in the trunk of the male, one can see a semitransparent white layer overlying the body musculatures. The layer is rich in fluidal substance, and the fact that it contains various types of blood cells can be ascertained by the smear method. Very little amount of this layer is inserted in the tail where the adipose tissue replaces it.

In amphibians, the skin is characteristic of having a large number of two kinds of epithelial glands, i. e. the poison (acid) gland and the mucous gland, which are underrun by *muscularis mucosa*. Between this muscular

sheath and body musculature or even among musculatures there lies a loose connective tissue layer (Text-fig 2). The swelling of the animals seems to be due to the layer of the connective tissue which occupies the vast spaces above mentioned in the male of the breeding season. The cells contained in the tissue are finely fibrous and branch irregularly, and lie in parallel direction with the body surface. Connected, or rather in contact, with each other in their terminal ends they form a sponge-like network (Fig. 3). The tissue is richly supplied with blood vessels and also with the lymph vessels embedded which contain large numbers of lymphocytes. The tissue itself, also containing various types of free cells, is a sort of lymphoid. The tissue is different in figure in different physiological conditions of the animals.

Breeding Males: In breeding males, the tissue in question reaches its maximum extent of development (Fig. 1). The increase in volume is due both to the enlargement of the tissue spaces and to the swollen protoplasm of the reticular cells. The nuclei of the tissue cells are elongated at different rates and are lightly stained by basic dyes containing several dark stained granules within them. Among these reticular meshes various types of free cells can be seen. They are all lymphocytes and all have a very thin periphery of protoplasm and a relatively large nucleus. The majority of them are small lymphocytes. They appear scattered among the reticular fibers or, sometimes, entangled with them (Fig. 3). As has been mentioned above, small lymphocytes can be seen also in the lymphatic vessels which pass very near to the body surface through the reticular tissue. The most conspicuous lymphatic vessel lies bilaterally in the cervical region of the animal. They are attached very close to the ventral surface of the thymus gland, and, as the gland is known to be a lymphocytopoietic organ, brief reference to these morphological significance will be stated.

The Thymus Gland: The thymus gland of *Hynobius retardatus* is a paired, three-lobed (although actually fused with each other with very thin strands of connective tissue), elongated structure on each side of the dorso-lateral surface of the head just caudad to the mandibular angle. It is also flattend laterally and assumes an obscure triangular shape in cross section (Fig. 4). In well swollen animals, the gland is surrounded by well-developed loose connective tissue which is morphologically identical with the reticular fibrous tissue above described. In the head, the reticular tissue contains more abundant free cells, especially near the thymus gland (Fig 5). As is generally accepted that the gland is a lymphocytopoietic organ rather than a hormone-producing one, the free cells can probably be derived from the periphery of the gland.

Indeed, the largest number of the cellular constituents of the thymus gland are the *small thymocytes* (small lymphocytes) which are round or

oval in shape and have a very thin layer of light eosinophilic protoplasm surrounding dark stained round nucleus with several chromatin particles. They form densely packed masses in the cortical zone of the gland and frequently are extruded into the surrounding loose connective tissue. Besides, from the fact that the gland occurs adjacent to the large lymphatic vessel as mentioned above, and that a relatively few numbers of lymphocytes are present in the lymphatic vessels of other parts the body, these lymphocytes found in the cervical lymphatic vessels seem to be derived from the periphery of the thymus gland, thus, bringing about such a remarkable dermal swelling in breeding males. The increase in volume of the lymph is of course another main factor for dermal swelling. There are scattered among reticular meshes as well as in lymphatics weak basophilic substance of no structure. But the spaces in meshes, in general, are thoroughly transparant probably for the reason that the lymph may have been washed away during procedures of preparation. On this point further studies must be continued. At any rate, it seems certain that the substance is neither fat nor lipoid but lymphatic one.

Breeding Females: In breeding females the reticular tissue is apparent but meagre, especially in the trunk (Figs. 2, 6). The tissue is here only represented by a string barely visible in cross section. Even in the cervical region, where the tissue reaches its highest degree of development, it occupies much narrower position of about 1 *mm.* as compared with that of the breeding male which is about 3 *mm.* The tissue also gives as a whole a similar appearance to that in the breeding males; containing various types of lymphocytes in the reticular tissue. However, it should be noted that in the reticular tissue there are embedded many fat cells in different stages of development (Fig. 7). They are at first solitary and, sometimes showing no nuclei in sections, assume a little vacuolated reticular cells with somewhat thick wall and fine protoplasmic processes, containing an ovoid nucleus within. Along development, the larger the fat droplet grows, the thinner the protoplasmic rim reduces, and finally they contact each other and form an adipose tissue. In the animal used in this study, however, the adipose tissue was not yet completely formed and had not entirely covered the reticular tissue. Another characteristic feature in this group of animals lies in the reticular fibers which aggregate and form a winding connetive tissue band, running through the reticular tissue in irregular directions (Fig. 8). The band, in cross section, consists of the fibrous cells in periphery and anastomosing protoplasmic mass with nuclei in diverse shapes in the core. In longitudinal sections the band has much elongated nuclei of the cells which are arranged in the same direction of the band and the cellular constituent on the periphery of the band is hardly discriminated from surrounding reticular cells, because they are quite similar in structures.

The band, being situated often in close contact with body musculatures, appears to be a transition from reticular connective tissue to muscle.

The interrelations between the thymus gland and its surrounding reticular tissue and those between the thymus gland and its attaching lymphatic vessel are identical as in the case of breeding males. Here there are scattered many single fat cells in the reticular tissue surrounding the gland. The reticular tissue almost vanishes in the trunk region of this group of animals. The tissue loses its reticular structure and remains as a fibrous thin layer or densely paked connective tissue band above and between musculatures. With elongated nuclei and tightly conjugated protoplasmic processes they assume a muscular nature.

The numbers of the acid and mucous glands in the dermis were counted in both males and females (Table I). The acid glands are extremely few in number in the trunk of females where the reticular tissue is poorly developed.

Table 1. The number of dermal glands counted in cross section of breeding animals (an example)

Sex	Breeding Males		Breeding Females	
Glands / Region of Body	Acid gland	Mucous gland	Acid gland	Mucous gland
Head	24	50	20	32
Trunk	24	67	8	90

Changes in Males: In the course of the one-month-captivity, reticular structure of the subcutaneous loose connective tissue undergoes a remarkable change. Spaces of the meshes become reduced and their cells are compressed to each other, so that they assume to have a stronger affinity to basic dyes in microscopical preparations than in breeding males (Fig. 9). Free cells in meshes reduce in number. There can be seen the aggregation of reticular tissue which gradually form connective tissue bands. In the thymus glands no distinct histological changes occur.

The male in captivity apparently rather resembles a female than the breeding male. This tends to increase in accordance with the lapse of time.

Experiment

In the following the experiment will be stated for the purpose to clarify

the effects of thymectomy on the subcutaneous loose connective tissue in male salamanders. Besides the breeding seaon, it is very hard to collect any adult individuals. Therefore, all the animals used in this experiment were collected in a pond of Mt. Moiwa, in the vicinity of Sapporo City, on April 21, 1949. Some of them were thymectomized on April 25 and were fed with living earthworms under the same terraqueous condition as the other normal control animals for 1-2 months. At due time the animals were fixed and furnished to microscopical studies. The thymus gland was easily removed through a longitudinal cut on the skin of the neck of anesthesized animals. All the animals endured operation and lived in good health except three, which soon died, out of the rest two indicated a marked albinisation throughout the body. During the capturation the experimental animals did not show any distinct differences in external appearance or in behavior from the normal controls.

One month after thymectomy the reticular tissue becomes greatly reduced, thus, making the animal considerably slender. The tissue almost vanished throughout the body, especially in the trunk. Even in the cervical region, the tissue is transformed into swollen compact structure or into several strands of connective tissue (Fig. 19) between the musculatures, so that the epithelial covering partly becomes in direct contact with the underlying body musculatures. They are compressed so tightly to each other that neither vacuoles nor spaces remain among them. Being flattend and elongated, nuclei of the tissue cells are alike in appearance of those in muscular sheaths. Free cells are barely visible anywhere. Between boundaries of some two musculatures, is found a band or mass of the connective tissue which is predominant in size compared with the remnant of reticular structure.

From the results obtained in the thymectomized animals it may be concluded that, if these bands or masses of connective tissue are a derivative of the reticular loose connective tissue, the thymus gland plays an important rôle on the swelling of *Hynobius* dermis. As a matter of fact, the reticular tissue vanishes quickly and almost thoroughly in the thymectomized animals.

Discussion

Leydig (1892) described the incrassate integument of male amphibians during their mating period. He says the gelatinisation of lymph occurs in some of the lymph spaces, and believes that the primary cause for dermal swelling in *Triton cristatus* and *Rana fusca* is an absorption of water through the intercellular spaces of epidermis.

In the breeding male salamander, the writer observed a marked increase in volume of swollen reticular meshes, their spaces and in number of free cells. It is generally accepted that the thymus gland is a lymphocytopoietic organ (Spedial, '25; Maximow-Bloom '30; Dawson, '32: Bremer, '36 et al.). From the fact that the free cells in the dermis of thymectomized males almost vanish, that the tissue transforms into somewhat swollen structure with minute spaces or, sometimes, into several rather compact strands of connective tissue with large spaces in thymectomized animals, and that the thymus gland is a most probable source of lymphocytes in these parts of tissue, the writer is of opinion that the gland plays a principal rôle on this phenomenon. The increase of the amount of fluidal substance among reticular meshes would be the main factor which causes the dermal swelling in breeding animals. And the writer could not find any evidence that the fluidal substance in these tissues originated from surrounding medium. The substance, perhaps the lymph, would change its amount in the breeding season, thus making the body plump or lean.

The occurrence of fat cells is very common wherever loose connective tissue exists. They are found most conspicuously in head region of the female just before the spawning. At that time the breeding season did not yet set in, so the reticular tissue probably partially assumes adipose tissue as well in the males. The similar case in *Rana temporaria* and *R. esculenta* is reported by von Braunmühl (1926). It is interesting to note that even in the breeding males which show a maximum development of the reticular tissue in head and trunk, a distinct adipose tissue is observable in tail region.

The connective tissue band in the female, which is found windingly running in the loose connective tissue layer, seems to be a particular derivative of the latter. Thence, the band is formed from the muscle tissue, or *vice versa*. To determine the fact further studies are needed. But it must be noted that the band as well as the fat cells appear also in the breeding male though very scarce.

According to Hayashi (1930), the poison gland varies greatly in number in different parts of the body whereas the mucous gland exists almost commonly throughout the body. The writer finds that the poison (acid) glands are few in number in the trunk of females where the swollen reticular tissue is very poor. However, because of no changes in number of the glands in both captive and thymectomized males, this may be rather an expression of some physiological factors which will lead the swollen dermis in the male but not in the female. Indeed, the abundant supply of blood capillaries within the layer shows that there is somthing of physiological significance in it. Thus the writer can not hold the idea that the phenomenon is due merely to the mechanical factor caused by

an aquatic life which lasts for a considerable time in the male.

Summary

1) In the male of a salamander, *Hynobius retardatus* Dunn, a remarkable swelling of the dermis occurs during its breeding season.
2) The swelling of the dermis is due to a subcutaneous loose connective tissue which consists of reticular meshes, free cells and rich lymphoidal fluid.
3) In the female, on the other hand, the tissue layer distributes so poorly that it can be seen as a thin strand of connetive tissue between the *muscularis mucosa* and the body musculatures in section.
4) Under captivity, the tissue decreases its volume and subsequently the body becomes slender. In the tissue, decrease in number of free cells is also distinct.
5) The thymus gland gives rise to numerous small lymphocytes into surrounding connective tissue so that it is probable that the gland may play an important rôle on the dermal swelling.

Literature cited

Braunmühl, A. von. 1926. Ueber einige myelo-lymphoide und lymphoepitheliale Organe der Anuren. Zeitsc. mikr.-anat. Forsch. Bd. 4.

Bremer, J. L. 1936. A text-book of histology. Philadelphia.

Dawson, A. B. 1932. Hemopoietic loci in *Necturus maculosus*. Anat. Rec. Vol. 52.

Hayashi, T. 1930. On the dermal glands of *Hynobius retardatus*. (In Japanese). Nippon Gakujutsu-Kyôkai Hôkoku, Vol. 6.

Leydig, F. 1892. Integument brünstiger Fische und Amphibien. Biol. Centralbl. Bd. 12.

Maximow, A. A. and W. Bloom. 1930. A text-book of histology. Philadelphia.

Speidel, C. C. 1925. The significance of changes in the thymus glands of thyroid-treated frog tadpoles. Anat. Rec. Vol. 29, suppl.

Explanation of Plate II

1. Cross section through the trunk of a breeding male. A thick layer of loose connective tissue lies between the *muscularis mucosa* and the body musculatures. Note free cells scattering among the tissue. 70×. 2. Cross section through the trunk of a breeding female. Owing to less development of subcutaneous reticular tissue, the dermis is much thin compared with that of the males. 70 ×. 3. Mesh work of loose connective tissue in male. Being connected with each other, the fibrous reticular cells form a sponge-like network containing free cells entangled with them. Bielschowsky's silver impregnation method. ca. 650 ×. 4. Cross section of the thymus gland of breeding male. Note a large number of lymphocytes scattered in the reticular tissue surrounding the gland. 70×. 5. Portion of a cross section through the thymus gland of male. The gland extrudes many small lymphocytes into surrounding loose connective tissue. ca. 500 ×. 6. Higher magnification of figure 2. Reticular tissue is compressed so tightly here that it is barely visible as a strand of connective tissue element. 400×. 7. Fat cells occurred in single in the tissue of the head of breeding female. Connective tissue bands are also observable. 310×. 8. Winding of connective tissue bands occurred in adjacent to the head musculatures in female. They show longitudinally muscular natures. 400×. 9. Cross section through the trunk of normal male after 2 months in captivity. Lacking well-developed reticular tissue layer, it resembles that of female (fig. 6) except for fully grown acid glands. 400×. 10. Cross section of the neck of thymectomized male at 1 month after operation. The reticular tissue is transformed into several, rather compact, strands of connective tissue. Among them, few free cells are visible. 140×.

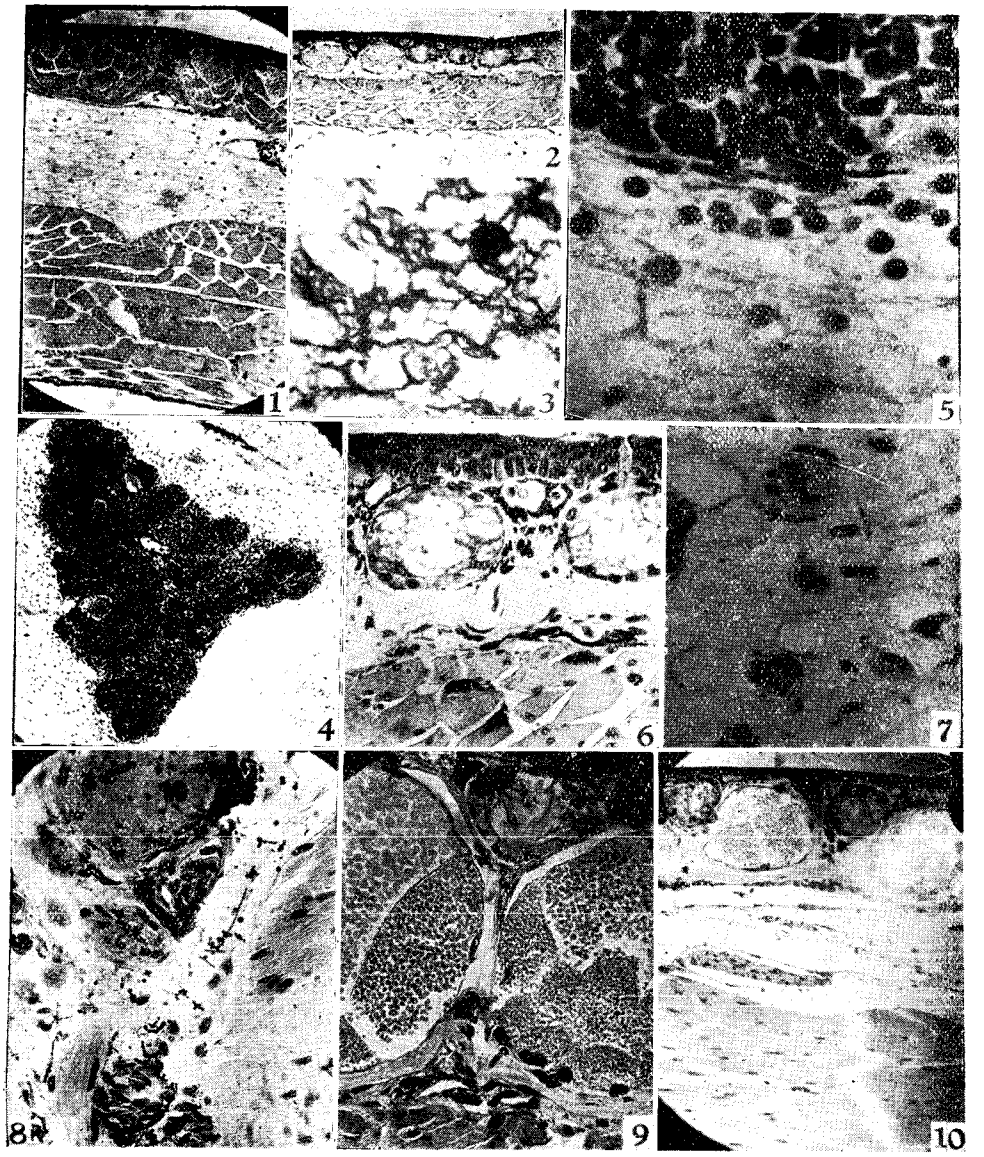

T. Aoto: Remarkable swelling of male skin of Hynobius in the breeding season