



Title	Anatomical and Histological Studies of Abnormal Genital Organs in Newborn Puppies of the Shepherd Breed (With 2 Text-figures and 1 Plate)
Author(s)	TAKENOUCHI, Yasushi
Citation	北海道大學理學部紀要, 11(1), 34-40
Issue Date	1952-12
Doc URL	http://hdl.handle.net/2115/27109
Type	bulletin (article)
File Information	11(1)_P34-40.pdf



[Instructions for use](#)

**Anatomical and Histological Studies of
Abnormal Genital Organs in Newborn
Puppies of the Shepherd Breed¹⁾**

By

Yasushi Takenouchi

(Biological Laboratory, Sapporo College, Hokkaido Gakugei University)

(With 2 Text-figures and 1 Plate)

Hermaphroditism has long since been attracted the intense interest of biologists, and a number of examples have been known in lower animals as well as higher animals including mammals. Although its occurrence in mammals has been considered relatively rare, it appears to be rather frequent in certain forms, such as goat, pig, horse and man. And, a few cases of intersex have been recorded in guinea-pig, cat, mouse and rat. But, the literature showed no reference to the dog, except the preliminary notes published by the present author (Takenouchi 1951), so far as the author is aware.

Recently, the author has had an opportunity to investigate four puppies having abnormal genital organs which were secured in the four litters of the shepherd dog. Uniformly they are characterized by having both of the Wolffian duct and the Mullerian duct along with the testes. In the first place, a puppy with no genital opening was unexpectedly born and died in January 1950 in the author's kennel. Its mother is one of the purely bred shepherd dogs. Other three puppies having also abnormal genital organs were obtained and died from different three mothers of shepherd breed in Sapporo. With these samples at hand, the author undertook the anatomical and histological studies of the reproductive organ under the guidance of Professors T. Uchida and S. Makino, Hokkaido University.

The author takes a great pleasure in recording here his hearty gratitude to Professors T. Uchida and S. Makino for their helpful advice and for the revision of the manuscript.

1) Contribution No. 272 from the Zoological Institute, Faculty of Science, Hokkaido University, Sapporo, Japan.

Jour. Fac. Sci. Hokkaido Univ., Ser. VI, Zool., 11, 1952.

Material

The specimens coming under study were born died or died after birth in two or three days. Their parents were externally normal in bodily characters. Previous to dissection the external feature of the abnormal specimens were observed. Then their reproductive organs were removed and fixed with Allen-Bonin's solution. Subjecting to the Paraffin method, sections were cut in 10 micra and stained with Delafield's haematoxylin and eosin. Table 1 gives the data at birth for four abnormal puppies, together with those of normal puppies.

Table 1. The data at birth from seven puppies.

Puppies	Age at anatomy	Litter size	Birth day	Body weight at the death	Testis (mm)	W. duct (mm)	M. duct (mm)
No. 1	Still born	4 (♂2, ♀1, ♀1)	1950 1.6	295gr	(1) 1.38×0.72 (2) 1.61×0.90	1.11×0.55	0.56×0.27
No. 2	died 2 days after birth	8 (♂3, ♀4, ♀1)	1950 5.13	375gr	(1) 3.6×1.8 (2) 3.8×1.6	1.06×0.63 1.43×0.64	0.62×0.47 0.84×0.56
No. 3	died next day of birth	5 (♂?, ♀?, ♀1)	1951 4.19	391gr	2.9×1.5	0.64×0.50 (thickest place) *1.58×0.82	0.56×0.26 0.56×0.58
No. 4	died next day of birth	7 (♂3, ♀3, ♀1)	1950 12.15	380gr	(1) 3.1×1.7 (2) 3.4×1.8	0.71×0.87 0.64×0.45 (thickest place) *2.5×1.04	0.23×0.11 0.24×0.11
Nor. 1	Still born	4 (♂2, ♀1, ♀1)	1950 1.6	422gr	(1) 3.2×1.08 (2) 3.2×1.48	0.82×0.43 1.59×0.68	
Nor. 2	died 2 days after birth	3 (♂2, ♀1)	1950 5.22	460gr	6.1×2.9	1.29×1.16 1.29×1.05	
Nor. Female	Still born	4 (♂2, ♀1, ♀1)	1950 1.6	428gr	(1) 3.4×1.5 (2) 3.4×1.37		0.47×1.21

Observation

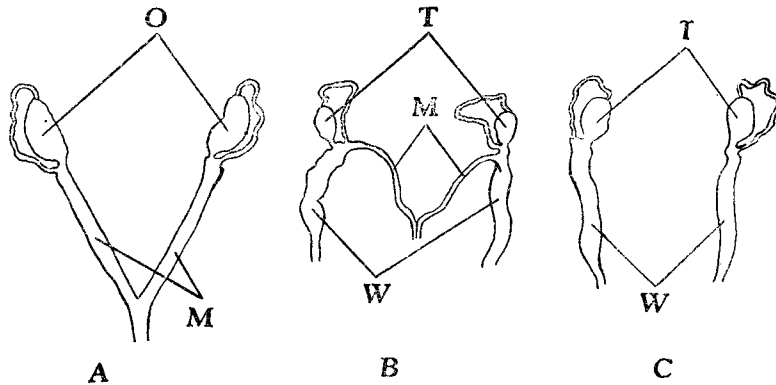
1) External view of the reproductive organs

Except for a specimen shown as No. 1, the remaining three specimens designated as Nos. 2, 3 and 4 were observed to be male from the study of the external genitalia. They showed the genital organs which were found in their own normal positions. No. 1 had, however, no external genital opening, so that it is entirely difficult to say about its sex from the external view alone.

2) Anatomical view of the reproductive organs

In the normal female puppy, two ovaries each having its respective

Mullerian duct leading to a uterus were found situated underlaying the kidneys (Textfig. 1), while the normal male puppy showed the testes which situated near kidneys. Each testis has its Wolffian duct that leads to the root of the penis (Textfig. 1). In both cases the gonads were oval and thick in outline.

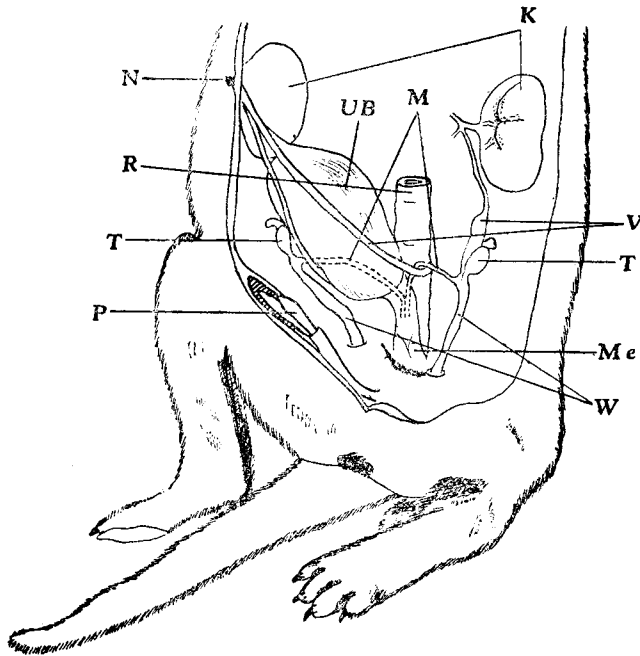


Textfig. 1. Anatomical view of the internal reproductive organs of the puppies. A, the normal female. B, the abnormal male. C, the normal male. M; Mullerian duct. O; ovary. T; testis. W; Wolffian duct.

Anatomical observations of four abnormal puppies revealed that the anatomical structures of genital organs were nearly similar in four specimens here concerned. The following descriptions are therefore made together. In each specimen, the gonads, two in each, were found in the situation characteristic to the normal male. Both the right and left gonads had in each its comparatively thick Wolffian duct leading to the penis. In addition, a thin duct which looks like the Mullerian duct of the normal female was observed on each side. The duct seems to branch from the Wolffian ducts at about 2 or 3 mm apart from the gonads, and then each runs passing to the uterus as occurred in the normal female. But no uterus was seen in these abnormal individuals, so that the two ducts on the both sides were fused with each other underside the undifferentiated urinary bladder adhering at. It was noticed that at this jointing part these two ducts were of double nature as shown in Textfig. 1, 2. Both the Mullerian and Wolffian ducts showed a little variation in thickness as seen in sections.

The results of the anatomical observations showed No. 1 to be male, though it was born without external genital opening. The details of the structure of the genitalia of No. 1 are shown in Textfigure 2.

Other specimens, Nos. 2, 3 and 4 also showed the internal genital organs apparently similar to that of No. 1.



Textfig. 2. Anatomical view of the internal reproductive organs of the specimen, No. 1. K; kidney. M; Mullerian duct. Me; membrane. N; navel. P; penis. R; rectum. T; testis. UB; urinary bladder. V; vessel. W; Wolffian duct.

3) Microscopical observations of the reproductive organs

The microscopical examination of the sections of internal genital organs of these abnormal puppies pointed out some histological differences between the abnormal puppies and the normal under study. In the Wolffian duct of the normal newborn puppy, there are basal membranes which cover the surface of the whole duct; the membranes consist of three distinct elements. The outermost layer contains the circular muscle, while the middle layer the longitudinal muscle. The innermost wall is columnar epithelium. The Wolffian duct is round or oval in cross section and the muscular layers are well developed in thickness. The structure of the Mullerian duct of the normal female puppy is seen to be nearly similar to that of the Wolffian duct, except that its muscular layer is thinner than that of the Wolffian duct. Especially the outer circular muscular layer is apparently thinner. The testes of newborn normal male are generally oval in shape and contain seminal tubules with primordial germ cells together with Sertoli cells. The loops of the spermatic cords can be clearly seen on the cortex of the testes.

The testes of the abnormal individuals here concerned were found to be much smaller in size and rather oval in shape as compared with those of the normal puppy. Especially in No. 1 the size of the testis nearly corresponds to about one-seventh that of the normal puppy. The blood vessels were found along the border of the gonad. In sections the loosely arranged connective tissue was filled in the testicular gland and no distinct seminal tubules could be seen at all. The blood vessels were distributed inside the gland. The Wolffian ducts of No. 1 show an irregular appearance in cross section, consisting of a loose tissue with irregularly scattering cells. In thickness, it is about one-seventh that of the normal male puppy. The Mullerian duct is nearly similar in structure to that found in the normal female puppy, showing the median canal developing to the sufficient length.

The testes of No. 2 are much larger than those of No. 1, having well developed interstitial tissue. A few germ cells containing in seminal tubules are found here and there in the testis. The Mullerian ducts of this individual assume a rather regular form as observed in cross sections, but show no canal formation in them. The Wolffian ducts are less developed than those of No. 1, being composed irregularly arranged tissue cells. Structurally they are nearly similar to those of the normal female puppy.

No. 3 is characterized by having a little more developed reproductive organs than the previous two specimens. The testes contain well-defined seminal tubules together with distinct blood vessels. The interstitial tissue is comparable to that of No. 2 in structure. The form of the Wolffian duct is nearly oval in cross section. It is extremely thinner in diameter than those of the other two, showing no canal formation in any portion. The diameter of the Mullerian duct is a little shorter than in No. 2, but the canal passes through entire the duct, as in No. 2.

The similar feature was found in No. 4; the Wolffian duct of this specimen is rather thick and the Mullerian duct is very thin. No canal is formed in the Wolffian duct, while the Mullerian duct forms a canal. At the posterior part, the Wolffian duct shows a remarkable diameter, but there is no canal even in the thickest place. In Table 2 are given the results of measurement of the size in several parts of the genital organs.

Remarks

Though there have been known several instances of mammals having abnormal reproductive organs, no case has been reported heretofore in dogs except a preliminary report by the present author, so far as the literature shows. As described in the foregoing pages, four puppies under study show abnormal genital organs which vary in structural detail. In general the genital organs of these abnormal specimens are small and less developed as compared with those of normal puppies of the same age. For example, No. 1 shows, in the measurement of

genital organs, much reduced weight and length as compared with those of the normal puppies from the same litter (cf. Table 1).

The goat is a form of mammals which show a frequent occurrence of individuals having abnormal sex organs. Recently Kondo (1949) has made a comparative anatomical investigation of abnormal reproductive organs in sufficient specimens of goat, and indicated that abnormal genital organs found in goat showed a wide variation in structural detail, ranging from those nearing the female sex to those like the male. The similar feature seems to occur in the abnormal genital organs of four puppies here observed; as described in the foregoing section, the testes, Mullerian ducts and Wolffian ducts show a range of variation in their development and structure.

In general, it has been known that the Mullerian duct can hardly be found in male mammals. Kondo (1949) reported that any remaining traces of the Mullerian ducts can hardly be found in the male goat and, further more that appearance of the Mullerian ducts and anomaly of the penis could not be observed as the result of castration. Therefore, the animals having both the Wolffian and Mullerian ducts should be regarded as intersex. On this basis, four puppies herein concerned which are characterized by having both Wolffian and Mullerian ducts may probably be of intersexual nature. And further, from the fact that all these specimens carry remarkable testes, they may be of the category belonging to male intersex.

There are two different opinions regarding the origin of intersex in goats. Goldschmidt (1931) held the view that intersex is caused by the combination of the sex-determining genes of different strength, whereas Eaton (1939) emphasized that intersexes of goats would be inherited due to a recessive gene. Concerning the present case of puppies, in turn, nothing can be stated about their origin, because of scanty samples at hand. But one thing is probable that the abnormality is of genetic nature, considered from the blood relation of the mother dogs.

Summary

Four newborn puppies having abnormal genital organs were obtained in four litters of the shepherd dog. It is remarkable that they are characterized by having both the Wolffian duct and the Mullerian duct along with the testes. The abnormal organs were investigated from both anatomical and histological stand points. The results of observations justified the conclusion that the puppies here concerned are male intersex.

Literature

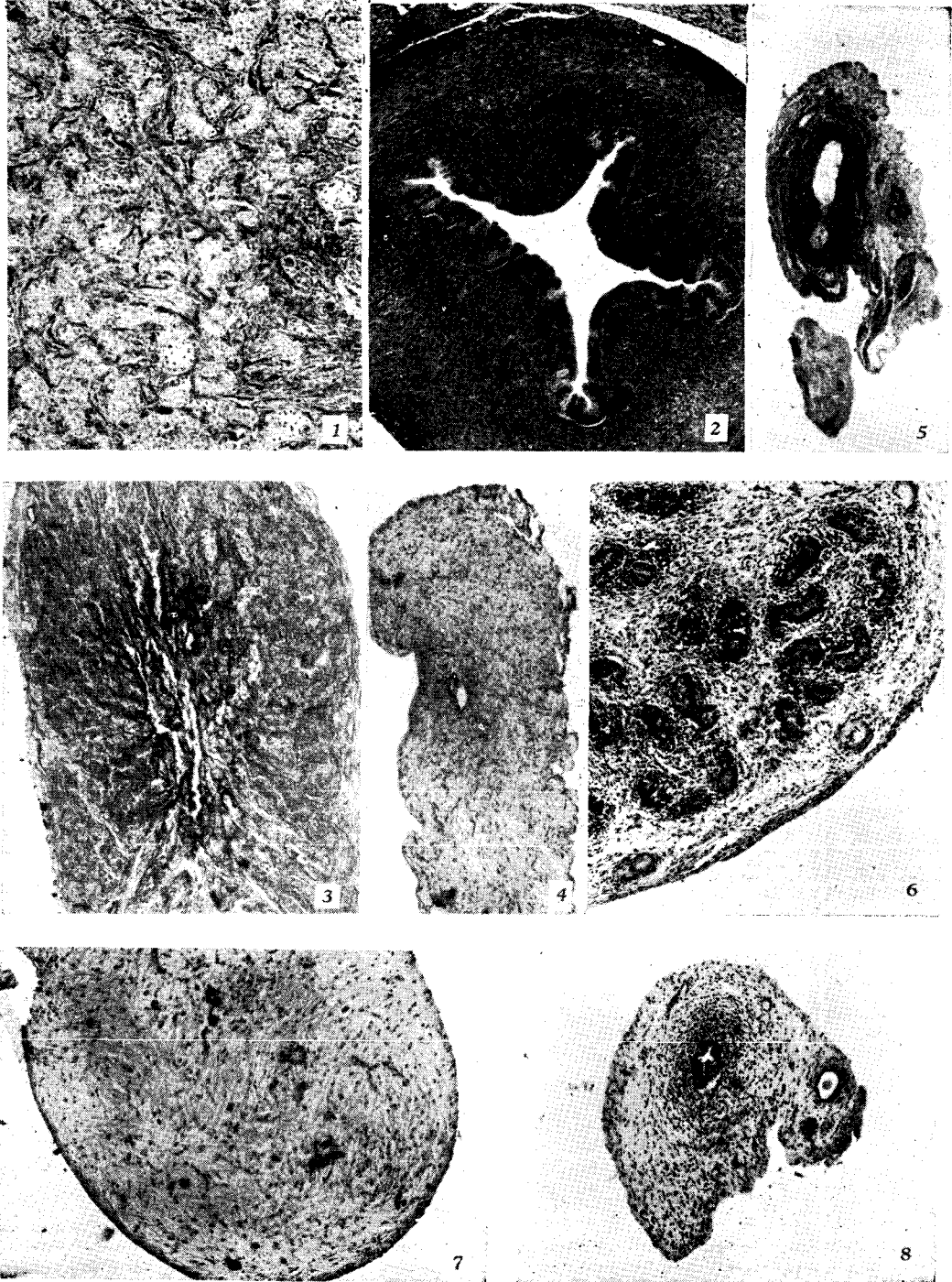
- Brambell, F. W. R. 1930. The development of sex in vertebrates.
Eaton, O. N. & V. L. Simmons 1939. Hermaphroditism in milk goat. *Jour. Hered.* 30 : 261-266.

- Goldschmidt, R. 1931. Die sexuellen Zwischenstufen.
- Kondo, K. 1949. Genetic studies on the intersex in milk goats. I. An anatomical study of intersexual goats. *Nitchiku Kaiho* Vol. 20; 55-62.
- Krediet, G. 1933. Kastration intersexueller Säugetiere.
- Makino, S. 1950. Contribution of the sex chromosome in an intersex goat. (A prel. note). *Coodinat. Commit. Res. Genet.* Vol. 1: 1-3.
- Masui, K. 1948. Studies on the intersex in milk goats. *Animal Husband.* Vol. 2: 421-424.
- . 1950. Intersex in animals, a review. *Gendai no Seibutsugaku.* Vol. 3: 291-348. (Tokyo).
- Meisenheimer, J. 1930. Geschlecht und Geschlechter im Tierreiche. II. Die Allgemeinen Probleme.
- Takenouchi, Y. 1951. Anatomical and histological studies of abnormal genital organs in two shepherd dogs. *Coodinat. Commit. Res. Genet.* Vol. II: 121-125.
- . 1952. Anatomical and histological study of the reproductive organ in an intersex puppy. *Gakugei, Sect. B.* Vol. 3, No.2: 89-92.
- Yamashina, Y. 1940. Studies on the sterility in hybrid birds. I. Histological researches on the reproductive organs of hybrid birds from the family Ploccidae. *Jap. Jour. Genet.* Vol. 16, No. 3: 97-105.
- . 1941. Studies on the sterility in hybrid birds. II. Histological studies of the reproductive organs in species hybrids of the family Columbidae. *Jap. Jour. Genet.* Vol. 17, No. 1: 1-12.
- Yoshikawa, T. 1935. Pedigree of intersex mammals, I. Goats. *Jap. Soci. Appl. Zool.* Vol. 7: 178-183.
- . 1935. Ditto, II. Pigs. *Jap. Soci. Appl. Zool.* Vol. 7: 234-241.

Explanation of Plate II

Photomicrographs taken with the aid of "Leitz-Makam" under magnification of $\times 100$. (Photo by Prof. S. Makino)

Fig. 1. Cross section of the testis of normal male puppy. **Fig. 2** Cross section of the Wolffian duct of the normal male puppy. **Fig. 3.** Cross section of the testis of the specimen No. 1. **Fig. 4.** Cross section of the Wolffian duct of the specimen No. 1. **Fig. 5.** Cross section of the Mullerian duct of the specimen No. 1. **Fig. 6.** Cross section of the testis of the specimen No. 3. **Fig. 7.** Cross section of the Wolffian duct of the specimen No. 3. **Fig. 8.** Cross section of the Mullerian duct of the specimen No. 3.



Y. Takenouchi : Abnormal Genital Organs in Puppies