



Title	Some Observations on Sex Differentiation in a Salamander, <i>Hynobius retardatus</i> , with Reference to Experiments on the Effects of Overripeness of Eggs (With 1 Text-figure and 3 Plates)
Author(s)	MIKAMO, Kazuya
Citation	北海道大學理學部紀要, 12(3), 282-295
Issue Date	1956-03
Doc URL	http://hdl.handle.net/2115/27159
Type	bulletin (article)
File Information	12(3)_P282-295.pdf



[Instructions for use](#)

**Some Observations on Sex Differentiation in a Salamander,
Hynobius retardatus, with Reference to Experiments
on the Effects of Overripeness of Eggs¹⁾**

By

Kazuya Mikamo

(Zoological Institute, Hokkaido University)

(With 1 Text-figure and 3 Plates)

In 1882 Pflüger reported the preponderance of males in egg-batches of *Rana temporaria* kept for an abnormally prolonged period in uteri of the mother. Following this work, R. Hertwig ('05, '12 and '21), Kuschakewitsch ('10) and Witschi ('14 and '24) showed that when the eggs were retained in the uteri for more than three days, frogs hatched out were all males in the differentiated race, while in the undifferentiated race the genetical 1:1 ratio was established at the larval stage. In the normal series, however, the phenomena above noted could be never seen by the end of the first year. On the other hand, O. Hertwig (1892), who observed teratological forms resulting from overripeness of the frog eggs, explained polyspermy as the direct cause of abnormal development. Zimmerman and Rugh ('41) using *Rana pipiens*, described the increase of effects in proportion to the degree of overripeness of eggs in uteri. Briggs ('41) proved that the eggs of the same species, which passed through overripeness and polyspermy, could not survive until after the cleavage stage. Measuring the R. Q. of overripe eggs, Bruner, Failer, Wenk and Witschi ('51) pointed out the similarity of their respiratory metabolism to that of cancer cells and their remarkable CO₂ content. Adding to his contributions of 1930 and 1934, Witschi ('52) reported a detailed observation on the teratological specimens. He stated that these abnormal specimens may be caused by toxic action of CO₂ to eggs in uteri and when the overripeness effects are severe, an abnormal development is produced, while, when the effects are moderate, the sex reversal from female to male occurs usually.

Despite numerous studies with anurans on this problem, so far as the writer is aware, no studies have been carried out in this field on urodeles. In view of this meagreness of works on urodeles, an attempt was made to gain information regarding the effects of overripeness in their case. The present study is mainly concerned with the sexual differentiation of a salamander, *Hynobius retardatus* developed from overripe eggs, the species being reported by Hanaoka ('34) as a

1) Contribution No.348 from the Zoological Institute, Faculty of Science, Hokkaido University, Sapporo, Japan.

Jour. Fac. Sci. Hokkaido Univ. Ser. VI, Zool. 12. 1956.

semidifferentiated type in regard to the gonadal development. Moreover, the writer's observations on the sexual differentiation of control animals differ in some points, from those of Hanaoka. Therefore, in the present paper, a detailed description will be presented on the normal development.

Before going further, the writer wishes to express his cordial thanks to Professor Tohru Uchida for helpful guidance during the course of this study, and also his hearty thanks are due to Assistant Professor Tomoji Aoto for kind advice. Furthermore, the writer is indebted to Professor Saji Makino for valuable suggestions from the standpoint of cytology.

Material and methods

Some fresh egg-masses were collected from a pond in the vicinity of Sapporo early in the springs of 1952 and 1953. Both the eggs and larvae were reared under the room temperature which raised gradually from 12°C to 26°C in the course of development in 1952. In 1953 all the eggs were kept in running tapwater ranging from 10°C to 12°C, and after hatching out the larvae were reared under the room temperature. The larvae and metamorphosed animals were fed on the fresh-water earthworms, *Tubifex* and *Limnodrilus*, which were placed in the same glass-vat. The developmental stages were determined after the stage series of *Amblystoma maculatum* published by Hamburger ('51) utilizing Harrison's photographs.

In the early springs of 1952 and 1953, twenty females were collected from the pond mentioned above. All these animals were surrounded with several males near the eggs which were already laid. They seemed to be just before spawning judging from their swollen belly. They were kept in running tapwater of about 10°C–12°C. About 60 hours after collection, the eggs were taken out from the uteri of their mothers, and were immediately fertilized with the sperm of males from the same locality. The eggs, larvae and metamorphosed animals were reared respectively under the same conditions as the untreated groups in the same year. Only five lots, three in 1952 and two in 1953, will be described as the experimental groups which showed distinct abnormality in cleavage and gastrulation, including, moreover, microcephaly, acephaly, polymelia and twinning which are generally characteristic of the development of overripe eggs.

From each lot considered, both the untreated and treated groups, several animals were fixed at each five or ten days' interval between the 65th and 120th day after fertilization in 1952. In 1953, animals, 110 days old, were first fixed and others were fixed at each ten or twenty days, with the oldest ones at 300 days. Bouin's solution was exclusively used as the fixative. The gonads were sectioned 10 μ in thickness, and stained with Delafield's haematoxylin and eosin.

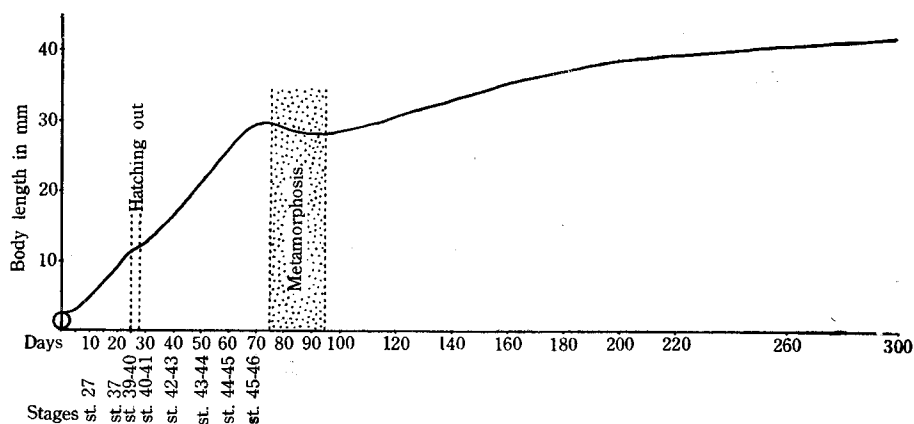
Normal sex differentiation in the control groups

Observations on the general aspects of development: In these two lots, no eggs failed in fertilization; all eggs grew normally until hatching out. The animals surviving at the autopsy were 60 in the group N-I ('52) and 89 in the group N-II ('53) respectively (Table 1). Hatching-out was completed during two days in both N-I and N-II and the metamorphosis took about ten days for each animal. The observations are summarized in Table 1; the disparity probably is due to temperature. The developmental stage and body length (from the tip of

Table 1

No. of groups	Days required from fertilization		No. of eggs studied	No. of animals examined	No. of deads by accidents
	to hatching-out	to completion of metamorphosis			
N-I	20-22	80-90	74	60	14
N-II	26-28	85-95	107	89	18

snout to anterior border of vent) observed in group N-II are summarized in Text-fig. 1. In the metamorphosed animals difference of the body length between N-I and N-II was negligibly slight. The animals in this study were, in average of total length, 5mm larger than those studied by Uchida ('37).



Text-figure 1. Graph expressing the growth rate of *Hynobius retardatus*. Body length: from the tip of snout to anterior border of vent. Stages: after the stage series of *Amblystoma maculatum* published by Hamburger utilizing Harrison's photographs.

Histological observations on the gonadal development: The process of the normal gonadal development until the beginning of sex differentiation generally corresponds to the observations of Hanaoka ('34). At the beginning of sex differentiation, the 70 th day, the indifferent germ glands possess the germinal epithelium on the peripheral part in which indifferent germ cells are arranged in a single row only, and the rete cords are formed from mesonephric blastemata which migrated through the hilum to pack the primary gonad cavity (Fig. 1). All these features are generally similar to indifferent gonads of larvae, 70 days old, reported by Hanaoka ('34). Gonads, which probably belong to the ovary, have the ovarian sac, with the distinct ovarian cavity, and the cortex layer which is formed of the germ cells arranged in one or two rows, accompanied by rete cells (Fig. 2). This

phase is observable only in the middle part of the gonad, while the anterior and posterior parts stand in indifferent stage. In regard to the differentiation of ovary, the writer's results agree with the description of Hanaoka in all aspects except for the differentiation being about ten days earlier than Hanaoka's. Testes were observed to enclose five or six germ cells together with rete cells in the medullary part. Both the rete cords and sex cords were seen in some sections (Fig. 3). They will form seminiferous tubules afterwards. In both sexes the differentiation proceeds from the middle part towards the two terminal ends. So far as four male larvae were examined, the testes seem to differentiate directly from the indifferent germ glands, but not through the passage of the morphological ovarian type as described by Hanaoka ('34).

In the larvae 75-80 days old, metamorphosis being in process, the sex differentiation has been completed. In the gonads of the animals identified as females, the germ cells were further increased in number and were arranged in two or three rows around the distinct ovarian cavity. There were observed a few germ cells in the synaptic stage. Both in the anterior and posterior regions the ovarian features were clearly seen. In the testes the seminiferous tubules were gradually forming. The multiplication of the germ cells was not so active as in the ovary.

In the animals 85-95 days of age, nearly metamorphosed, the gonads were distinctly differentiated throughout their length. The ovaries had enlarged by the multiplication of the germ cells, each three or four making a group in a common follicle. The progress of oogenesis seems to be proved by the appearance of a number of germ cells with typical leptotene or synizesis arrangements of chromatin. In the testes, the proliferation of the germ cells was also seen, but the spermatogenesis was somewhat retarded in process in comparison with the oogenesis, because the germ cells were not clearly distinguished from the primordial germ cells observed in the neutral germ glands. The formation of the seminiferous tubules was observed clearly by the penetration of the sex cords to the center of the gonads. In the metamorphosed animals 100-110 days old, the oocytes had entered into the growth period, but the spermatogenesis was proceeding slowly.

In the animals 120-140 days old, the ovaries had enlarged strikingly by the increase and growth of the oocytes, leaving the ovarian cavity narrowed (Fig. 4). In certain cases, however, growing oocytes could not be observed throughout the entire gonads. Such gonads showed the appearance of ovaries of animals, 90 days old, in the middle region, while on the other hand, in both the anterior and posterior regions, they lacked any trace of ovarian cavity. Their development was probably arrested. The structure of testes was fairly advanced, showing clearly the formation of seminiferous tubules (Fig. 5). In an animal, 120 days old, a gonad had a few oogonia in the terminal half part (Fig. 6), which will be possibly eliminated.

In the animals 150-190 days old, the ovaries were enlarged and packed with large oocytes (Fig. 9). Some changes were observable in ovaries of many animals

Table 2. Condition of gonads in the control groups

Days after fertilization	Indifferent	Ovary			Testis		Total	Remarks
		normal	deformed	degenerated	normal	hermaphroditic		
70	3	3			4		10	before metamorphosis
75		9			7		16	during metamorphosis
80								
85		7			8		15	nearly metamorphosed. germ cell-multiplication
95								
100		8			11		19	appearance of growing oocyte
110								
120		10	3		11	1	25	occurrence of deformed gonad
140								
150		6		8	6	3	23	occurrence of degenerating oocyte
190								
220		2		7	5		14	
250			(3)*					
270		7	2	14	4		27	
300			(1)*					
Total	3	52	5 (4)*	29	56	4	149	

* In the bracket shown the number of animals which are with the deformed ovaries, and moreover with the degenerated ovaries. They are included also under the column of "degenerated".

more than 150 days old. As is shown in Figs. 7, 10 and 12, the changes were proved by the degeneration of oocytes, the active migration of a number of eosinophile cells and mesonephric blastemata through the mesovarium to the ovary, and the penetration of these cells into the degenerating oocytes. The individuals changed in such manner were fairly numerous, although the grade of the changes was individually variable. The testis typically developed shows more advanced features than in the preceeding period (Fig. 8). Besides, there are a few testes displaying some hermaphroditic features. Some testes possessed germ cells in synizesis stage. In the animal photographed in Fig. 11, the gonads showed normal testicular form in certain regions (as shown in the upper gonad), but contained several oviform cells in other regions (as in the lower gonad).

In the animals 220-300 days old, those with typical ovaries decreased in number and those with ovaries showing degenerating tendencies increased gradually (Table 2). Moreover, there were found some deformed ovaries. They

possessed in the middle region the typical ovarian features with many well developed oocytes. On the contrary, in the posterior and anterior regions they had only a few less-developed oocytes, lacked ovarian cavity and were small in size. In the testes developed normally, seminiferous tubules were arranged radially in transverse sections, with germ cells fairly multiplied, though no spermatocyte was contained.

Consequently, it is to be said that the male differentiation began just before metamorphosis without the passage through the ovarian type reported by Hanaoka. Furthermore, gonads were divided into five types, namely, 1. ordinary, 2. deformed and 3. degenerating ovaries, and 4. ordinary and 5. hermaphroditic testes.

Observations on the development of Müllerian ducts: The anlage of Müllerian ducts in this species appears, in the animals 80 days old, along the lateral edge of the mesonephros, adjoining the mesonephric duct. Twenty days afterwards the ducts became formed of several epithelial cells radially arranged in transverse sections, in the upper gonadal region, with a mere thickening of the peritoneal epithelium in the lower part. In the animals of 140 days, they encircled almost the entire gonadal region. Epithelial cells had multiplied and were arranged radially. But there were some males retaining the condition of a mere thickening of the peritoneal epithelium in the middle gonadal region (Fig. 8). In the animals 190 days old, the ducts develop so distinctly that they could be observed generally even with the naked eye from the anterior gonadal to lumbar region (Fig. 9). At the 300th day, in all animals except a few males, the ducts were lined with many high columnar cells, especially showing expansion in the lumbar region. As to the organ, the males are individually highly variable.

Results on the experimental groups

Observations on the general aspects of development: During the course of development, many of eggs cleft irregularly, indicating various of abnormality. About a half of these abnormal ones ceased their development before the morula stage. The rest of them developed further to reach that stage. Some of these eggs presented delayed gastrulation and were equipped with abnormally proliferated tissue. Twinning, microcephaly and acephaly were observed before hatching out. Nearly all of these abnormalities died off by the time when the normal ones were hatching out. Only a small number of these monsters retained hatching ability, but they could not feed and immediately died after hatching out. Abnormalities observed are as follows:

At the time of fertilization. Depigmentation in the animal pole among a few unfertilized eggs.

In the early cleavage stage. At the 8-cell stage a fairly large number of eggs were observed to have smaller blastomeres in animal pole than in control. At the 16-cell stage in some eggs inequality of animal blastomeres was caused by irregular cleavages. Moreover, there was depigmentation in some eggs.

In the blastula stage. Depigmentation clearly observed.

In the gastrula stage. Abnormal gastrulation, showing delayed disappearance of yolk plugs.

In the neurula stage. Yolk plugs still observable in some eggs; though completely absorbed in most eggs. Some eggs with abnormally proliferated tissues.

In the tail bud stage. Double tail, microcephaly and abnormally large swollen belly.

In the embryonal stage before hatching out. Double monsters in various degrees. Microcephaly and acephaly. Abnormal large belly.

After hatching out. Microcephaly (Fig. 13), twinning (Fig. 14), double tail and slightly large belly.

A total of 219 animals survived until the time of sacrifice as shown in Table 3. Besides, days required until hatching out and completion of metamorphosis; the rate of death, etc. were summarized in Table 3 in each lot respectively. The groups of 1952 (H-I, H-II and H-III) required, in comparison with the groups of 1953 (H-IV and H-V), fewer days from fertilization to hatching out and completion of metamorphosis. This seems to have resulted from the different temperatures of rearing water, because the former were kept in the room temperature immediately after fertilization, while the latter were reared in running tapwater which ranged within 10°C–12°C.

Table 3. Statistical explanation of each experimental group

No. of groups	Egg-age in uteri (in hrs.)	Days required from fertilization		No. of eggs studied	No. of animals examined	Rate of abnormalities died (in%)		Rate of animals died by accidents (in%)
		to hatching-out	to completion of metamorphosis			eggs	embryos	
H-I	60	21-25	80-95	92	35	27.2	21.7	13.0
H-II	72	20-25	80-95	65	32	21.5	16.9	12.3
H-III	68	21-24	80-95	104	72	16.3	7.7	6.7
H-IV	60	25-30	85-100	85	36	18.8	18.8	20.0
H-V	60	25-30	85-100	83	44	21.7	19.3	6.0

In the present study, the types of deformities fairly coincided with those of frogs observed by Witschi ('52). In the experiment on the effects of oxygen deprivation at various developmental stages in *Amblystoma* sp., Detwiler and Copenhaver ('41) showed that the urodele is, like anuran amphibians, sensitive to O₂ deficiency.

Histological observations on the gonads of the animals developed from the overripe eggs: As the results of examination of the 219 experimental animals, it was found that the development of cortical germ layer was more or less arrested in fairly many animals, though different in degree in each lot. Of all animals,

14 were in indifferent or sterile condition, 105 had gonads of testicular type and 100 of ovarian type (Table 4).

The indifferent germ glands were small in size, having a few germ cells only in a small area of the middle region, and loosely packed with rete cells in other regions. Some of them remained compact and nearly sterile, having no germ cells. They were found still in animals 150 days old, in group H-IV (Fig. 24). Such conditions did not occur in the normal groups, so far as the writer has studied.

Of 100 animals of female type, only 13 were nearly normal. These normal ones were found only in older animals, 100 days old. The rest were all modified. The modification was considered to be more remarkable than that in the testis. These abnormalities were divided into the four types: 1. meagreness of germ cells, 2. arrested development, 3. deformation and 4. degeneration of oocytes (Table 4).

Type 1 shows the highest frequency among them. Before the 90th day, all animals except two belonged to this type. In all of them the cortical germ layers were observed being dotted with a few germ cells. The type can be divided further into two forms. In one form, the epithelial cell layers are nearly in contact with the lining cell layers (Figs. 15 and 25). In the other sort, the former are separated from the latter by a seemingly vacant space (Fig. 16). After the 100th day, cases of type 1 decreased and other types increased. Abnormalities of type 2 were noted in animals which were fixed after the 90th day. In their gonads, the germ cells multiplied fairly well. But these gonads were clearly in a delayed state of development (Figs. 21 and 26). Some of the gonads of abnormal types 1 and 2 had ovarian cavities which were deformed by immigrant rete cells. As shown in Fig. 17, in some sterilized gonads, the ovarian cavities had been entered more or less by some rete cells. The gonads photographed in Figs. 19 and 21 (upper) seem to be the suppressed ovaries of which the ovarian cavities were almost packed by the rete cells. In these gonads, however, masculinization is not yet ascertained. The gonads of animals exhibiting abnormalities of type 3 are small in size, provided with the ovarian cavity almost obliterated and with compact tissue composed of interstitial cells and a few oocytes (Fig. 20). These features, sometimes, were seen through nearly the whole gonad. Type 4 abnormality was represented by the degeneration of oocytes and the immigration of eosinophile cells and mesonephric blastemata through the mesovarium, just as seen in the control groups. These features were observed in animals older than 120 days. As shown in Table 4, there were found animals which possessed characters of both type 3 and type 4 (Fig. 27).

Of 105 animals which had the gonads differentiated in testicular characters, 29 were accelerated to develop in contrast to normal animals. But the remaining 76 showed more or less unusual features. These abnormalities were roughly divided into four types: 1'. meagreness of germ cells, 2'. arrested development,

3'. existence of vesicular tissues in peripheral parts and 4'. hermaphroditic features (Table 4).

Table 4. Condition of gonads in the experimental groups

Days after fertilization	Indifferent	Ovary						Testis						Remarks
		normal	abnormal				total	normal	abnormal				total	
			type 1	type 2	type 3	type 4			type 1'	type 2'	type 3'	type 4'		
$\frac{65}{70}$	6	—	13	—	—	—	13	3	12	—	—	—	15	before metamorphosis
$\frac{80}{90}$	3	—	30	2	—	—	32	12	19	2	—	—	33	during metamorphosis
$\frac{100}{110}$	1	4	2	8	—	—	14	4	8	5	—	—	17	after metamorphosis
$\frac{120}{130}$	1	4	3	4	1	—	12	2	3	1	5	1	12	appearance of oocyte
$\frac{140}{240}$	3	5	3	5	(4)*	16	29	8	1	3	11	5	28	appearance of degenerating oocyte
Total	14	13	51	19	$\frac{1}{(4)}^*$	16	100	29	43	11	16	6	105	

Table 4. Type 1: abnormal ovary with meagre germ cells, type 2: abnormal ovary showing arrested development, type 3: deformed ovary, type 4: degenerated ovary. Type 1': abnormal testis with meagre germ cells, type 2': abnormal testis showing arrested development, type 3': abnormal testis with vesicular tissue in peripheral parts, type 4': hermaphroditic testis. *) In the bracket shown the number of animals which are belonging to the type 3, and moreover are belonging to the type 4. They are included also under the column of "type 4".

The animals belonging to type 1' were more numerous than those of the other types. Before metamorphosis, all testes, except three normal ones, showed meagreness in number of the germ cells. In some gonads the germ cells could be scarcely found in both medulla and cortex (Fig. 18). These testes decreased in number gradually in older animals and could not be found after the 140th day excepting one animal, 170 days old. On the other hand, the rete cells were observed to be fairly well migrated and multiplied in the medullary part, enclosing a few germ cells. Type 2' abnormalities were observed in animals older than 90 days. Their gonads were similar in morphological features to those of younger animals which were of male type in nature. After the 140th day, some testes remained in condition of the testis of animals, 70 days old. Type 3' and 4'

appeared in animals older than 120 days. Type 3' was represented by what were seemingly vesicular and sparse connective tissues in peripheral parts of testes (Fig. 22). These testes were more frequently seen in H-IV than in other lots. In the animals belonging to type 4', the testes possessed oviform cells in synizesis stage (Fig. 23) or in growth period. They were of similar form to those in untreated males.

As mentioned above, the effects of the treatment are generally expressed by meagreness of germ cells. Each lot, however, showed some differences from the others in degree of modifications, suggesting variabilities of genetical constitution or of intensities of the effects. The three 1952 lots can be arranged in the order, H-II, H-I, H-III according to the degree of modifications. In H-I and H-II, there were found no normal ovary but only a few normal testes. Especially, all ovaries of H-II belong to abnormality type 1. H-III seems to be slightly affected, as there were found some normal testes. In the two 1953 lots, H-IV seems to be severely affected, compared with H-V. In H-IV, neither normal testes nor ovaries were found. On the other hand, in H-V many gonads were observed to have developed normally as in untreated animals.

Discussion

In regard to the gonadal development of *H. retardatus*, Hanaoka ('34) explained that this species belongs to the semidifferentiated type. He stated as follows: "The development of male gonads proceeds at first in exactly the same way as the female, having an ovarian cavity and a well developed cortex. But during the metamorphosis the ovarian cavity becomes gradually occluded by the rete cells, and germ cells migrate from the cortex towards the medulla." In the present study, there were observed two noticeable points different from his descriptions. One of them relates to the period of sex differentiation, and the other to the mode of male differentiation. All animals were observed to have sexually differentiated already during the metamorphosis, establishing the sex ratio of about 1:1. In the testes, there could not be seen the processes above given as stated by Hanaoka. In all testes which were examined by the writer, the multiplication of the germ cells was not so active as in the ovary. In certain testes photographed by Hanaoka, a considerable number of germ cells are already in the leptotene or synizesis stage. They are seemingly in the course of oogenesis. If these gonads completely switch to the male direction, such a large number of oocytes must be sooner or later fated to be degenerated or eliminated. The writer observed only a case of elimination of a few oocytes. This species seems to be more gonochoristic, so far as the writer has studied, at least before the metamorphosis. In this experiment, some hermaphroditic gonads and some deformed ovaries appeared after the 120th day. Moreover, the sex ratio is 4:23 in the animals between 270 and 300 days old. Consequently the predominance of the female sex is highly significant. After the 150th day, degeneration of

oocytes was observed in more than half of the females. In the present study, it remains still unknown what the predominance of female and the appearance of abnormalities may signify.

Overripeness obviously causes masculinization of genetical females in frogs as reported by the previous investigators. According to Witschi ('24), this is due to a change in the somatic but not in the germinal component of the gonads which brings about the masculinization. In the development of gonads this exerts more injurious effects upon the cortical than upon the medullar inductor system. In the ovary, suppression of the cortex, a dominant component, is followed by the compensatory growth of medulla, a recessive component, and results in the sex reversal from female to male.

In the present study, the effects are seen to take the forms of a remarkable suppression of cortical component and a slight activation of medullary component. When the process of the modification had fairly progressed, the germ cells were hardly to be found in either ovaries or testes. Generally, the germ cells observed in affected gonads were still in the condition of primordial germ cells similar to those in neutral germ glands. In the differentiation of ovary, two factors can be considered, namely, 1. cortical development and 2. formation of ovarian cavity. When only the action of the second factor was kept back to act, the ovaries, by the gradual loss of the suppressing power, proceed probably in normal process of gonadic development. This is supported by the decrease of abnormality type 1 and the increase of type 2, as the development proceeds (Table 4). When the effects were still more severe, the ovaries probably became sterile by the failure of the action of two factors.

As mentioned above, the cortical degeneration occurs obviously but the medullary development is not so remarkable as to complete the sex reversal. The ingrowth of rete cells on which the medullary development is based occurs, if at all, very slightly, following the suppression of cortical development. These results are similar to Uchida's ('37) on the effects of high temperature upon this salamander. The difference between the observations of Witschi ('29) in *Rana sylvatica* and Uchida in *H. retardatus* on the influence of high temperature treatment, lies probably in the amphibian groups, Urodela or Anura, as was observed also in this experiment. This may be interpreted by the species as specificity of activity of the mesonephric blastemata which were confirmed to be the component of gonadal medulla and efferent ductules by Witschi ('53) and Bruner and Witschi ('54). In Ranidae, when the development of cortex is suppressed, the activity of mesonephric blastema is so powerful that the genetically established cortico-medullary antagonism is completely changed. In the present salamander, however, this change can not be established. A similar case is also reported in *Pleurodelus wallii* by Mintz and Gallien ('54). Consequently, the affected ovaries gradually seem to recover only as ovaries but not as testes. There could be

seen no case observed by Witschi ('14) where the many individuals of the frog first pass through a regular female phase and then transform into males.

On the other hand, the testes were observed in this experiment to differentiate rather earlier than normal ones. It seems that a high potentiality of the mesonephric blastema of genetical male has been encouraged to develop by the exclusion of dominant antagonistic power of the cortex against the medulla in larval germ glands. After the 120th day, a hermaphroditic tendency, that is the oogenesis in peripheral region of some testes was noted, just as seen in the control groups. But in the testes affected fairly, most of these oogonia probably do not develop beyond a definite stage and are soon degenerated or eliminated, leaving the vesicular connective tissue in peripheral region as mentioned in abnormality type 3'. The overripeness seems to reverse the tendency which causes the cortical component to develop even in the testis.

Summary

1. The sex differentiation of *Hynobius retardatus* begins just before metamorphosis and the sex ratio of 1:1 is temporarily established during metamorphosis. After the 120th day some abnormal gonads appear, and after the 270th day the females become more numerous than males in the sex ratio.

2. In many ovaries the growing oocytes degenerated, and the eosinophile cells and mesonephric blastemata immigrated through the mesovarium.

3. In both the testes and ovaries of the animals developed from overripe eggs, the cortical germ layers were suppressed in their development, especially in multiplication of germ cells. The rete cells actively immigrated into the testes but not always into the ovaries. The masculinization of ovaries was not confirmed sufficiently.

4. The affected ovaries probably gradually recover from the suppressed condition of cortex, and, though being delayed, in the normal course of development.

5. The peripheral region of many testes shows a vesicular connective tissue from which the cortical component might be degenerated or eliminated.

Literature cited

- Bruner, J. A., Failer, G., Wenk, P. and E. Witschi. 1951. The respiratory metabolism of overripe eggs and embryos of the frog *Rana temporaria*. *Anat. Rec.*, 111: 452.
- Bruner, J. A. and E. Witschi. 1954. Pluripotentiality of the mesonephric blastema and the mechanism of feminization of male salamander by androgenic hormones. *Anat. Rec.*, 120: 99-118.
- Detwiler, S. R. and W. M. Copenhaver. 1941. Further experiments upon the production of developmental abnormalities in *Amblystoma*. *Jour. Exp. Zool.*, 88: 399-411.
- Hamburger, V. 1950. A manual of experimental embryology. The Univ. of Chicago Press. 3rd Impression.
- Hanaoka, K. I. 1934. A semidifferentiated race of urodelans with regard to its gonadic development. *Jour. Fac. Sci. Hokkaido Univ., Ser. VI, Zool.*, 3: 247-261.

- Hertwig, R. 1912. Ueber den Einfluss der Ueberreife der Eier auf das Geschlechtsverhältniss von Fröschen und Schmetterlingen. Sitz.-ber. mathem.-physik. Klasse Bayer. Akad. Wiss. München, Jg., 1921, 269-294.
- Mintz, B. and L. Gallien. 1954. Androgen-induced feminization of urodele larvae in the absence of the hypophysis. Anat. Rec., 119: 493-518.
- Uchida, T. 1937. Studies on the sexuality of Amphibia. II. Sexual induction in a sexually semidifferentiated salamander. Jour. Fac. Sci. Hokkaido Univ., Ser. VI. Zool., 6: 35-63.
- . 1937. Studies on the sexuality of Amphibia. III. Sex transformation in *Hynobius retardatus* by the function of high temperature. Jour. Fac. Sci. Hokkaido Univ., Ser. VI, Zool., 6: 57-71.
- Witschi, E. 1914. Experimentelle Untersuchungen über die Entwicklungsgeschichte der Keimdrüsen der *Rana temporaria*. Arch. mikr. Anat., 85: 9.
- . 1924. Die Beweise für die Umwandlung weiblicher Jungfrösche in männliche nach uteriner Ueberreife der Eier. Arch. mik. Anat., 102: 163.
- . 1929. Studies on sex differentiation and sex determination in amphibians. II. Sex reversal in female tadpoles of *Rana sylvatica* following the application of high temperature. Jour. Exp. Zool., 51: 267-291.
- . 1930. Experimentally produced neoplasm in the frog. Proc. Soc. Exp. Biol. and Med., 27: 475.
- . 1934. Appearance of accessory "organizers" in overripe eggs of the frog. Proc. Soc. Exp. Biol. and Med., 31: 419.
- . 1952. Overripeness of the eggs as a cause of twinning and teratogenesis: A Review. Cancer Res., 12: 763-786.
- Witschi, E., Bruner, J. A. and S. J. Segal. 1953. The pluripotentiality of the mesonephric blastema. Anat. Rec., 115: 381.
- Zimmerman, L. and R. Rugh. 1941. The effect of age on the development of the egg of the leopard frog, *Rana pipiens*. Jour. Morph., 68: 329-346.

Explanation of Plate IV

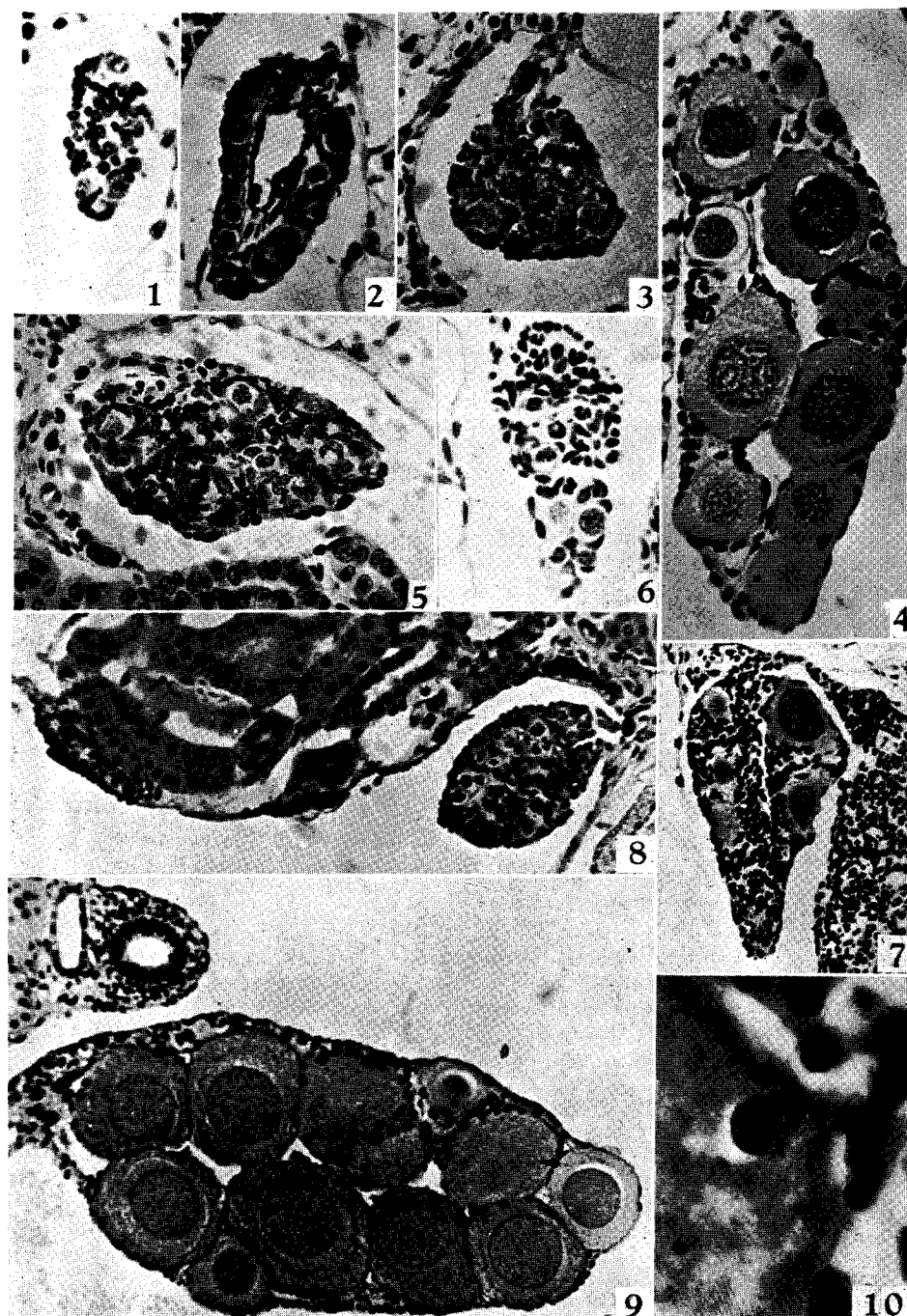
- Fig. 1. A normal neutral germ gland of larva, 70 days old. $\times 200$
- Fig. 2. A normal ovary of larva, 70 days old. $\times 200$.
- Fig. 3. A normal testis of larva, 70 days old. $\times 200$.
- Fig. 4. A normal ovary of animal, 120 days old. $\times 200$.
- Fig. 5. A normal testis of animal, 120 days old. $\times 200$.
- Fig. 6. A testis of untreated animal, 120 days old, showing elimination of oocytes at the terminal. $\times 200$.
- Fig. 7. An ovary of untreated female, 150 days old, showing degeneration of oocytes and vigorous immigration of eosinophile cells and mesonephric blastemata through the mesovarium from mesonephros. $\times 90$.
- Fig. 8. A normal testis of untreated male, 150 days old. $\times 90$.
- Fig. 9. A normal ovary of untreated female, 190 days old. $\times 90$.
- Fig. 10. Showing an eosinophile cell penetrating into the cytoplasm of degenerating oocyte. $\times 600$.

Explanation of Plate V

- Fig. 11. Section through the middle gonadal region of an hermaphroditic male, 190 days old. A testis showing normal testicular form in the upper portion, but possessing in the lower part several oviform cells in peripheral region. $\times 90$.
- Fig. 12. A degenerating ovary of untreated female, 300 days old. Showing degeneration of oocytes and penetration of eosinophile cells and mesonephric blastemata into these oocytes, an oocyte being completely occupied by eosinophile cells and mesonephric blastemata. $\times 90$.
- Fig. 13. Microcephalic larva, 32 days old. $\times 5$.
- Fig. 14. Twin larvae, 32 days old. $\times 5$.
- Fig. 15. An affected ovary of larva, 70 days old, having a distinct ovarian cavity and only two germ cells at the terminal end of suppressed thin cortex. $\times 200$.
- Fig. 16. An affected ovary of larva, 70 days old, with a distinct ovarian cavity but no germ cell in vesicular thick cortex. $\times 200$.
- Fig. 17. An affected ovary of larva, 80 days old, showing multiplied interstitial cells in basal part. $\times 200$.
- Fig. 18. An affected testicular gonad of larva, 70 days old, with immigrated rete cells but no germ cells. $\times 200$.

Explanation of Plate VI

- Fig. 19. Section through the anterior portion of an affected ovary of animal, 100 days old, showing suppressed cortex with only a few germ cells and the ovarian cavity occupied by some rete cells. $\times 200$.
- Fig. 20. A deformed ovary of treated female, 130 days old, having a compact tissue with several oocytes and interstitial cells, but the ovarian cavity obliterated. $\times 200$.
- Fig. 21. Section through the middle region of suppressed ovaries of an affected female, 130 days old. The upper gonad without ovarian cavity. $\times 90$.
- Fig. 22. A testis of affected male, 130 days old, having a vesicular and sparse connective tissue in peripheral region. $\times 200$.
- Fig. 23. A testis of treated male, 140 days old, showing several germ cells in synizesis stage of the peripheral region. $\times 200$.
- Fig. 24. A sterile gonad of affected animal, 150 days old. $\times 200$.
- Fig. 25. An affected ovary of treated female, 190 days old, containing several oocytes protruded into ovarian cavity from suppressed thin cortex. $\times 90$.
- Fig. 26. Section through the middle region of ovaries of affected female, 190 days old, showing features similar to the ovary of female, 90 days old $\times 90$.
- Fig. 27. Deformed ovaries of female, 190 days old, having some degenerating oocytes and immigrating eosinophile cells and mesonephric blastemata. $\times 90$.



K. Mikamo: Sex Differentiation in a Salamander

