



Title	Effects of X-Irradiation upon Rainbow Trouts (<i>Salmo irideus</i>) : II. Stimulative Effects of X-rays on Spermatogenesis in Fry (With 6 Text-figures)
Author(s)	NIIYAMA, Hidejiro
Citation	北海道大學理學部紀要, 13(1-4), 281-288
Issue Date	1957-08
Doc URL	http://hdl.handle.net/2115/27243
Type	bulletin (article)
File Information	13(1_4)_P281-288.pdf



[Instructions for use](#)

Effects of X-Irradiation upon Rainbow Trout (*Salmo irideus*) II. Stimulative Effects of X-rays on Spermatogenesis in Fry¹⁾

By
Hidejiro Niityama

(Faculty of Fisheries, Hokkaido University, Hakodate)

(With 6 Text-figures)

A considerable number of investigations have been carried out on the effect of X-rays on the testicular tissue. The general conclusion is that the spermatogonia are most sensitive to X-irradiation which causes the necrosis or inhibition of mitosis with a subsequent gradual disappearance of germ-cells and final reduction in production of spermatozoa (Heller '48, Oakberg '55, Ellinger '40, Shaver '53). The present study deals with the effect of low doses of X-irradiation upon the testicular tissue of rainbow trout fry, with special regard to some stimulative effects on spermatogenesis.

Here the author wishes to express his sincere gratitude to Professors K. Kobayashi and K. Yamamoto, and to Messrs. R. Yuki, M. Mogami and H. Hirata for their co-operation in obtaining the material for this study. Many thanks are due also to Dr. Sajiro Makino for his keen interest in the subject.

Material and methods

The irradiated testes of young rainbow trout, *Salmo irideus* Gibbons, provided the material for this study. The fishes used were 2550 in number: they were artificially fertilized on January 23, 1956 and hatched on March 31, 1956. They were reared for about three months in a small well-water tank set in a greenhouse with sufficient bait. The exposure of fry to X-rays was made on August 10, 1956. The body length and weight of 12 fishes sampled at random at the time of irradiation were 4.2-7.2 cm. and 1.3-3.5 gr. on average. All the fishes were divided into three groups; the first and second groups were exposed to 100r and 500r, and the third was used as the non-irradiated control. Throughout irradiation the water temperature was maintained at about 12°C. by adding ice pieces. The water was gently bubbled by supplying oxygen.

The radiation was made as follows: 180KVP, 3 mA; 0.1 mm. Cu filter; target distance 40 cm.; diameter of the field size 25 cm.; dose rate measured in air 33r/min. In each procedure 100 fishes were irradiated in a glass dish of 22 cm. diameter with water of 2.5 cm. depth.

1) Supported by a grant-in-aid for Cooperative Scientific Research from the Ministry of Education.

Jour. Fac. Sci. Hokkaido Univ. Ser. VI, Zool. 13, 1957 (Prof. T. Uchida Jubilee Volume).

After irradiation the fry were transferred for rearing to an out-door concrete pond which was divided into three compartments with fine brass screens. The material was sampled on Aug. 11, 13, 16, 20, 25, 30; Sept. 10, 20; Oct. 1, 24; Nov. 28; Dec. 24, 1956 and Jan. 23, 1957. These dates are 1, 3, 6, 10, 15, 20, 31, 41, 52, 75, 110, 136 and 166 days after radiation, respectively. After removal testes were fixed immediately with weak Flemming's solution. For staining, iron-haematoxylin method after Heidenhain was exclusively employed.

Observations

Control: Several testes derived from the control fry were fixed in each sampling. The number of fry together with spermatogenetic stages in testis are listed in Table 1.

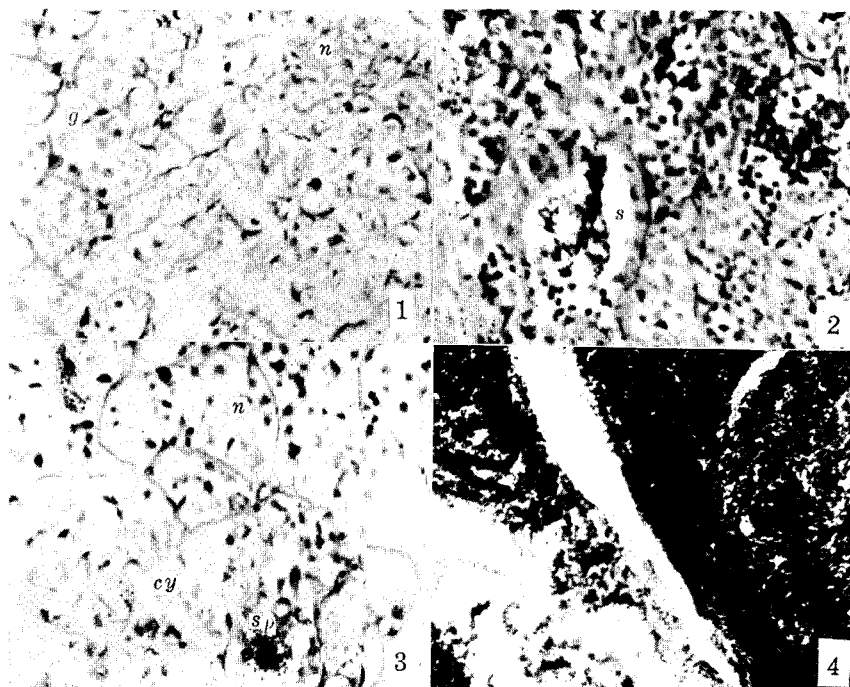
Table 1. Control data

Date	Days after irradiation	No. of fry sampled	No. of fry having only gonias	No. of fry having gonias and growing auxocytes	No. of fry having sperm	Body length (cm)
Aug. 11	1	3	3			5.4-6.0
Aug. 13	3	3	2		1	5.6-6.4
Aug. 16	6	3	2		1	5.8-5.8
Aug. 20	10	3	3			5.3-6.3
Aug. 30	20	2	0	2		6.5-6.5
Sept. 10	31	2	2			6.7-7.5
Sept. 20	41	3	3			6.7-9.5
Oct. 1	52	4	2	2		7.5-8.8
Oct. 24	75	3	3			10.8-12.7
Nov. 28	110	2	0	2		11.3-12.0
Dec. 24	136	6	1	5		11.0-14.1
Jan. 23	166	6	2	4		11.4-15.2
Total		40	23	15	2	

It is evident from Table 1 that the majority of control testes contain germ-cells in the spermatogonial stage being in active mitotic processes. Cells at the growing stages in the early maturation period were observed in testes derived from 15 comparatively older fry: they were found in certain inner cysts of the testis (Fig. 1). Remarkable is the fact that in two individuals, one from samplings on August 13, and the other on the 16th, both primary and secondary spermatocytes were observable in their testes. They were in rather advanced stages of maturation and a considerable number of mature spermatozoa was produced (Fig. 2). These fry were 5.6 cm. and 5.8 cm. in body length, respectively. It is surprising to know that the fish more than 15 mm. in body length killed in January showed the germ-cells at advanced growth stages. It is therefore most likely that these two fry are not of the normal type. It is noticed that there are some specimens which showed about 1% necrotic spermatogonia in the testes sampled on August 30, 1956 and some other dates later on.

Table 2. Data from 100r irradiation experiments

Date	Days after irradiation	No. of fry sampled	No. of fry having only gonia	No. of fry having gonia and growing auxocytes	No. of fry having sperm	Body length (cm)
Aug. 11	1	2	2			5.5- 6.5
Aug. 13	3	3	1	2		5.4- 5.7
Aug. 16	6	2	2			5.9- 6.0
Aug. 20	10	3	1	2		5.9- 6.3
Aug. 25	15	3	2	1		5.2- 5.7
Aug. 30	20	4	2	2		6.3- 6.7
Sept. 10	31	4		1	3	7.2- 7.7
Sept. 20	41	3			3	7.3- 8.5
Oct. 1	52	3	1	1	1	8.3- 9.7
Oct. 24	75	1		1		15.6
Nov. 28	110	2		1	1 completely mature	12.0-11.4
Dec. 24	136	3		2	1	10.4-12.3
Jan. 23	166	5		2	3; 1 completely mature	16.1-11.0
Total		38	11	15	12	



Figs. 1-4.

100 r experiment: Testes of the fry which were irradiated on August 10, 1956 were used for observation. The experimental data are given in Table 2. Testes of two individuals taken one day after irradiation contained no necrotic cells, being quite normal in appearance: some spermatogonial cells were found in process of division. At three days after irradiation, some necrotic cells made their appearance in the spermatogonial cysts. Then the spermatogonial cells become necrotic in more or less degree with time. The ratio between the number of necrotic cells and normal spermatogonia varies from 3% to 30% in different individuals. Even in the same sampling, ratio is not similar: in the four testes observed 20 days after irradiation one showed about 33%, while the other three were found to be about 3%. Particularly the testes with many necrotic cells showed frequent mitotic divisions. Spermatogonial divisions were observed in every testis so far observed. In the testes 20 days later on after exposure, mitosis was occurring actively.

All cells contained in a spermatogonial cyst did not show necrosis simultaneously; a few cells were found necrotic, having deep black nuclei. No distinction of cells in spermatogonia was observed though Oakberg 1955 and Shaver 1953 reported it. In the testis with advanced meiotic cells in the central portion, necrosis took place in cells lying near the border line between the spermatogonial and spermatocyte groupings. This fact may indicate that some cells lying near the testis surface were influenced at irradiation but the cells lying in central portions were not affected by the present dose of X-rays. Then the regeneration of spermatogonia followed with the development of non-affected cells near the testis surface.

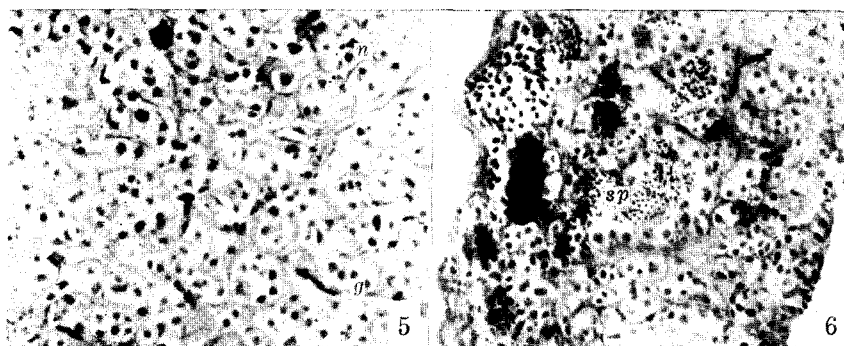
As shown in Table 2, the testes derived on September 10 and later on showed the cells at advanced meiotic stages in 12 out of 21 specimens. Two individuals among them, one on the 110th day and one on the 166th day, showed apparently mature testes, although their body length was small (Fig. 4). The former was 11.4 cm. in body length, having mature testes, weighing 1.15 gr. and 0.85 gr. The latter was 16.1 cm. in body length, having testes 1.25 gr. and 1.20 gr. in weight. The remaining 19 fry carried testes which were filled with advanced meiotic cells or spermatozoa (Fig. 3). In comparison with the control testes it is apparent that the testes from 100r-irradiation animals show earlier maturation than those of the control. This seems to be the effect, direct or indirect, of irradiation.

500r experiment: As in the former experiment, several testes were fixed in each sampling. The data are shown in Table 3. Testes of the first sampling appeared quite normal: dividing figures of spermatogonia were frequent. The dividing figures were scarcely observed in the samplings from the second to the 5th. In the 6th sampling, they appeared again in small numbers. In the 7th sampling and later, the spermatogonial divisions took place actively in almost all testes. The feature seems to be due to the difference in dose.

Table 3. Data from 500r irradiation experiments

Date	Days after irradiation	No. of fry sampled	No. of fry having only gonia	No. of fry having gonia and growing auxocytes	No. of fry having sperm	Body length (cm)
Aug. 11	1	2	2			5.7- 5.8
Aug. 13	3	3	3			5.8- 6.2
Aug. 16	6	3	1	2		6.4- 7.1
Aug. 20	10	2	2			6.1- 6.8
Aug. 30	20	3	3			4.9- 6.5
Sept. 10	31	3	3			5.3- 6.6
Sept. 20	41	4	3	1		7.7- 7.3
Oct. 1	52	3	1	2		7.0- 8.4
Oct. 24	75	3	0	1	2	10.6-10.7
Nov. 28	110	6	2	1	3	9.6-12.0
Dec. 24	136	5	1	3	1	10.2-12.3
Jan. 23	166	5	1	3	1	10.9-15.2
Total		42	22	13	7	

Necrotic spermatogonial cells were visible in the second sampling (Fig. 5) and continued to occur in the subsequent samples. Percentages of necrotic cells varied from 3% to 50% by testis. It was found that the cells showed tendency to increase with time after irradiation. Three testes, for instance, sampled on January 23, 1957 indicated about 50% necrotic cells. The central portion of the testes was filled with necrotic cells surrounded by spermatogonial cells. It seems probable that almost all cells in these testes were affected and the following



Figs. 5-6.

regeneration occurred as a result of the development of unaffected cells lying under the epidermis. The cells lying in the central portions of some testes would not be affected by irradiation; they continued active division and entered into the spermatogenetic cycle. Delay in the formation of spermatozoa in this experiment may be due to the irradiation dosage.

Discussion

A voluminous literature on radiation damage to the mammalian testes has been accumulated. Concerning fishes, however, only three reports have been issued so far as the author is aware. Ellinger (1940) reported in the goldfish that 1500r of X-rays represented the minimum lethal dose which killed all fish within 19 days. It is questionable whether 500r dosage is lethal. There are a few papers pertaining to the effect upon the testis of fish: Foster (1948) dealt with the effect on young rainbow trout and Welander et al. (1948) with that on Chinook salmon. According to them (cited from *Ann. Rev. Physiol.* 9, 1949), the gonads of these fishes are very sensitive to ionizing radiation. In his irradiation experiments with rabbits, mice, rats and guinea pigs Heller (1948) learned that the spermatogonia were the first to be affected. In the experiments with mice Oakberg (1955) divided the spermatogonia into A, and B types with a third type intermediate between them. The latter two types were very sensitive to X-rays, all cells being damaged after 2 days by exposure to 600r; the A type was more stable than the B. Shaver (1953) classified the dust-like cells in the spermatogonia and indicated that dust-like spermatogonia are the most radio-sensitive germinal cells, with respect to inhibition of mitosis, but they are the most radio-resistant with the exception of sperm, in their ability to withstand irreparable destruction by X-irradiation. It is believed that regeneration occurs from these cells which are not destroyed.

The exposure of rainbow trout fry to 100r and 500r X-rays made in the present experiments resulted in the appearance of necrotic cells in the testes on the third day and later on following the X-irradiation. Shaver (1953) and Oakberg (1955) distinguished the spermatogonial cells into different types with regard to sensitivity to X-rays, but the present material showed no such distinction. The injurious effect of X-rays was found to be non-simultaneous. It seems apparent that affected spermatogonia will degenerate later though they are normal in appearance just after irradiation, and that the necrotic cells increase with lapse of time after irradiation.

In the testes of rabbits and rats treated with 800r X-rays, germ-cell regeneration took place 30 and 35 days after irradiation. In the mouse testes which received 350r the regeneration occurred after 2 days (Heller '48). In the rainbow trout after 100r exposure, spermatogonial cells increased in number in the peripheral region of the testis and the spermatocytes in the central portions. Necrotic cells were found lying in the border area between them. The testes 10 days after irradiation showed a spermatogenetic activity and those 31 days after irradiation showed the production of spermatozoa. Two specimens, one from 100 days and the other from 166 days after irradiation, carried mature testes. Following the 500r exposure the spermatogenetic activity was suppressed on the 3rd to 20th day after treatment but recovered by 31 days after irradiation. In the testis 52 days after treatment spermatogenesis took place very actively. Sperm-production was found in the testis 75 days after irradiation.

In conclusion it can be stated that in the experiments with 100r and 500r irradiation, the rainbow trout fry produce mature spermatozoa in their testis earlier than the control fry, and that the stimulative effect seems to influence the regeneration of the injured parts of testes and to accelerate the maturation division of germ-cells.

Summary

This paper deals with the effects of irradiation with 100r and 500r X-rays on spermatogenesis of rainbow trout fry. The testicular tissue was studied 1 to 166 days after exposure.

Affected necrotic cells were found in the testes taken 3 days and later after treatment.

Mitosis was suppressed for about 20 days through the exposure to 500r.

At 41 days after 500r exposure and 10 days after 100r exposure, mitotic division was taking place actively. At 75 days after 500r exposure and 31 days after 100r exposure, mature spermatozoa were found produced in the testes of some fry.

The conclusion was reached that the production of spermatozoa seems to take place earlier in irradiated fry than in the non-treated ones.

Literature cited

- Ellinger, F. 1940. *Radiology* 35.
Foster, R. F. 1948. Atomic Energy Commission Declassified Document. No. AECD-2079.
Heller, M. 1948. The testis. In Bloom, W., "Histopathology of irradiation from external and internal sources." McGraw-Hill Book Co., Inc., N. Y.
Kobayashi, S. & H. Hirata 1957. *Bull. Fac. Fish. Hokkaido Univ.* 8 (1).
Oakberg, E. F. 1955. *Journ. Morph.* 97.
Shaver, S. L. 1953. *Amer. Journ. Anat.* 92.
Welander, A. D., Donaldson, L. R., Foster, R. F., Bonham, K. and A. H. Seymaur 1948. *Growth* 12.

Explanation of figures 1-6

All figures are photomicrographs of sections of testes, using Olympus P 7 ocular and Zeiss 40 × object, under 280 times.

- Fig. 1. Control testis, Dec. 24, '56 : 14.1 cm. in body length. Showing spermatogonia at periphery and spermatocytes in the central portion. No necrotic cells.
Fig. 2. Control testis, Aug. 18, '56 : 5.8 cm. in body length. Abnormal fry having mature spermatozoa in some testicular cysts.
Fig. 3. 100r irradiation testis, Oct. 1, '56 : 9.7 cm. in body length. Showing some necrotic cells and cysts involving mature spermatozoa.
Fig. 4. 100r irradiation testis, Jan. 23, '57 : 16.1 cm. in body length. Showing mature spermatozoa in testis.
Fig. 5. 500r irradiation testis, Aug. 13, '56 : 6.2 cm. in body length. Showing many necrotic cells among spermatogonia.

Fig. 6. 500r irradiation testis, Nov. 28, '56 : 9.6 mm. in body length. Showing many necrotic cells and cysts involving mature spermatozoa.

g : Spermatogonia. cy : Spermatocytes. sp : Spermatozoa. n : Necrotic cells.