HOKKAIDO UNIVERSITY

Title	The Homoplastic Pituitary Implantation into Larvae of a Salamander, Hynobius retardatus (With 1 Text-figure)
Author(s)	MIKAMO, Kazuya
Citation	北海道大學理學部紀要, 13(1-4), 399-403
Issue Date	1957-08
Doc URL	http://hdl.handle.net/2115/27264
Type	bulletin (article)
File Information	13(1_4)_P399-403.pdf

Instructions for use

Hokkaido University Collection of Scholarly and Academic Papers : HUSCAP

The Homoplastic Pituitary Implantation into Larvae of a Salamander, *Hynobius retardatus*[1)]

By
Kazuya Mikamo

(Zoological Institute, Hokkaido University)

(*With 1 Text-figure*)

In the previous experiments on the relation of the pituitary to metamorphosis in amphibian larvae, it has been repeatedly published that the additional pituitary stimulation usually accelerates the start of metamorphosis, through its effect on the thyroid. However, Herre ('35) reported that a massive dose of adult pituitaries postponed completion of metamorphosis in *Triturus marmoratus* for about 6 weeks. Moreover, Herre and Rawiel ('39) gained similar results in the same experiments using larvae of various salamander species. Fankhauser and Watson ('49) employing Herre's method, found that the metamorphosis of all treated larvae of *Triturus viridescens* was delayed largely or partially. The present study was undertaken to determine whether the additional pituitary stimulation results in precocious or in delayed metamorphosis in larvae of *Hynobius retardatus.*

It is the writer's great pleasure to be permitted to dedicate this article to Professor Tohru Uchida, under whose direction this study has been carried out, in memory of his 60th birthday.

Method : At the time of the first implantation, the age of both the experimental and control larvae was 70 days; their body length was 26-28 mm not including the tail. One or two whole pituitaries from adult salamanders were inserted into the abdominal muscle of each larva through a slit made laterally. Ten days after the first implantation, the second operation was done with the same procedure on the opposite side of the body. Under the continuous observation of external characters, twenty-seven animals operated were fixed respectively at the 5th, 25th, 140th and 300th day after the operation and used for histological examinations.

Observations

A. Metamorphic changes in normal larvae : The metamorphic changes were noted firstly in the pigmentation of larvae, about 80 days old. Following the disappearance of large black spots of dermal melanophores which characterize the larval coloration, dorsal and lateral regions are uniformly tited with blackish color. The color change is caused by the disparity in the rate of distribution of both

1) Contribution No. 392 from the Zoological Institute, Faculty of Science, Hokkaido University, Sapporo, Japan.

Jour. Fac. Sci. Hokkaido Univ. Ser. VI, Zool. 13, 1957 (*Prof. T. Uchida Jubilee Volume*).

dermal and epidermal melanophores. The dermal melanophores, a chief element in larval coloration, gradually decline in number, and the epidermal ones gradually increase to a sufficient number to form an almost continuous meshwork of melanophores from dorsal to lateral parts. At the same time, guanophores, the most conspicuous element of the adult coloration, become gradually distributed over the whole body with the advancement of the metamorphosis. Until the end of metamorphosis, the dorsal and lateral sides are colored bright blackish brown because of the uniform distribution of melanophores, guanophores and lipophores. This color gradually fades and almost completely disappears toward the ventral side. On the underside, glistening yellowish dots of guanophores are scattered over the semi-transparent skin (Fig. 1. a).

Shortly after the commencement of color change, resorption of the fin begins firstly in the dorsal neck region and is completed within a week. In the position at which the fin has been absorbed, the median dorsal groove is gradually formed

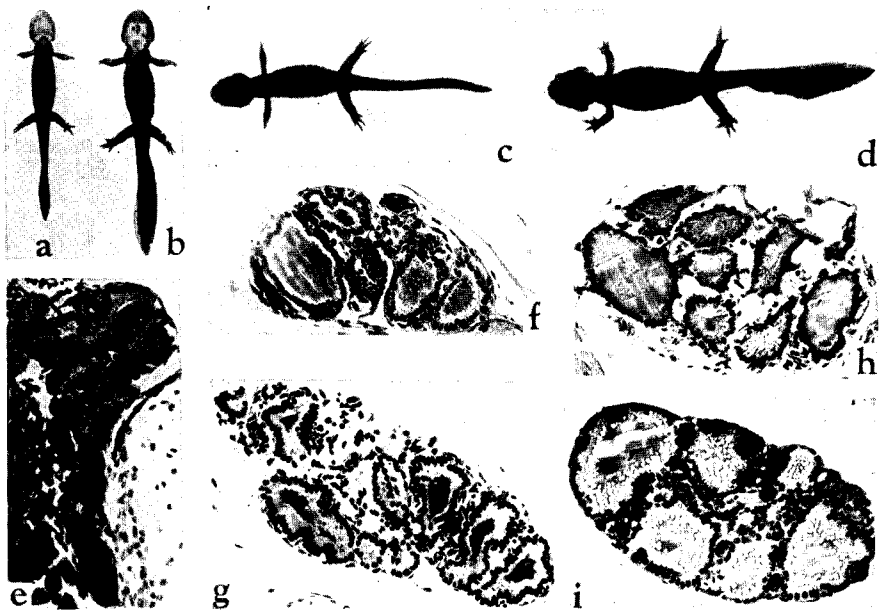

Fig. 1. a-d. Animals, treated and non-treated. ×1/2.
a. *Normal animal*, ten days after completion of metamorphosis, 100 days old. b. *Implanted animal*, 30 days after operation, 100 days old. c. *Normal animal*, one year old. d. *Implanted animal*, 300 days after operation, one year old.
e-i. *Thyroid glands*. ×50. e. From an animal 5 days after implantation. f. From a normal animal, one year old. g. From a implanted animal, one year old. h. From a male adult in terrestrial life. i. From a male adult in breeding season.

cephalo-caudally to the lumbar region. Three or four days after the first sign of metamorphosis, the reduction of gills begins and is finished within about a week, when the gill slits are perfectly closed.

The larval skin is composed of both dermal and sensory layers. The former is made up of a single thin row of flat cells and lined by the latter which contains large secretory cells. The beginning of metamorphic changes in the skin is marked by an accumulation of cells which may have originated from the sensory layer. These cells translocate into the surface, are gradually cornified there and differentiate to form multicellular epithelial glands. During these changes, the dermal layer is stripped in small flakes. After the completion of metamorphic changes in the skin, molting occurs after the manner of adult, and the animal enters the terrestrial life.

One of the most remarkable changes lies in the transformation of body from the bulky larval shape to the slender form of the adult living on land, caused by ossification of cartilage and decrease in volume of subcutaneous connective tissues or other structures, such as muscles and viscera. Above all, the head shows notable changes in shape. The head of the larva is triangular in outline and the snout is blunt, but the head of the metamorphosed animal is oval and fairly smaller in size than that of the larva. The transformation of the head brings about also a gradual projection of the eyeballs which is followed by a notable development of the upper eyelids.

B. Metamorphic changes in implanted larvae: The first visible change was blackening of the skin within the small area implanted, 3–4 mm in diameter, about 24 hours after the operation. Within a week after the first implantation, the larvae began to turn darker until the whole body, except some parts of the ventral side, finally became uniformly greenish black (Fig. 1. b). Neither the guanophores nor the lipophores were observed in any place. Such a coloration continued until the time of sacrifice, even in the oldest animals which lived for over one year.

About five days after the first implantation, the effects of thyrotropic hormone of the grafts were certified by the resorption of fin and gills several days prior to its commencement in control larvae. At the second implantation, metamorphic changes proceeded actively in control larvae but inactively in experimentals. Their fin was reduced only in the parts anterior to the posterior legs. Even a week after the second implantation, the tail fin continued to keep nearly larval appearance, though the fin of anterior part had been completely absorbed. Afterwards the tail of the animal gradually reached the form of the male adult in the breeding season retaining the larval features only in the upper and lower ridges which are thin and transparent. The width of the tail in proportion to the body size remained about two times larger as compared with that of the control animals. Such a condition of the tail was completed about three weeks after the first implantation and was retained constantly during the period of the

observations (Figs. 1. b and d).

The gills were gradually atrophied to a small rudimentary process at two weeks after the first implantation. The process had not been absorbed and the gill slit remained rudimentarily open, even in animals, one year old.

Their bodies did not attain the slender form as in the control animals, throughout the observation, but developed directly into a bulky shape similar to that in the male during the breeding season. A median dorsal groove was remarkably extended to the base of the tail. The body sides presented clearly a wrinkled appearance due to the lateral grooves. A pair of parotid glands developed fully (Figs. 1. b and d). These outer appearances seem to agree with the well developed subcutaneous tissues of the males in the breeding season (Aoto, '50). Molting was irregular in all implanted animals and did not occur in the normal way as in the adult of terrestrial life. This seemed to be caused by an incomplete cornification in their skin. The outer layer of the skin was stripped in small flakes. This fact was observed also in adults during the breeding season.

Growth rate constantly rose above that of the control. In the group of animals fixed on the 300th day after the first operation, the implanted animals were, on the average, about 12 mm longer than the controls in total length.

Their thyroid glands were seemingly activated through the thyrotropic hormone from the grafts. The colloidal substance in the follicles was almost completely discharged on the 5th day after the first implantation (Fig. 1. e). In all the animals fixed after that, the follicles were found to contain some colloidal substance and to be lined with thickened follicular epithelium of high columnar cells (Fig. 1. g; showing quite different figures from those of the normal adults, Figs. 1. f, h and i).

Discussion

Herre ('35) reported that the metamorphosis of the newt was completed, though delayed in his experiment, and suggested that the overdose of hypophyseal hormone does not act to accelerate thyroid glands which are still incompetent, but raises the threshold of the reacting tissues to the thyroid hormone. Fankhauser and Watson ('49), on the other hand, observed that the metamorphosis of the larvae was much delayed and remained partial. As an explanation of this retardation of the metamorphic reaction, they stated three possible ways as follows : "(1) through a depressing effect on the host's own pituitary, (2) through failure of the thyroid to respond to excessive amounts of thyrotropic hormone, or (3) conversely, through a too rapid and complete release of hormone from the thyroid so that insufficient amounts were available for the later phases of metamorphosis."

The results in the present investigation are similar to those of Fankhauser and Watson in respect of the tail fin, gills and gill slits. But the temporary rapid acceleration of metamorphic changes just after implantation has not been reported by them. During the time when the metamorphosis is accelerated, the thyroid glands of experimentals almost completely lost their colloidal substance in the

follicles. The fact observed in the present experiment seemed to support the possibility of their third explanation. However, at least in the writer's experiment, it seems to be doubtful whether it was caused by "a too complete release of hormone from the thyroid so that insufficient amounts were available for the later phases of metamorphosis". As far as the present experiment concerns, the exhaustion of the thyroid hormone probably did not continue very long, but it seems rather that a gradual intensifying response of thyroid to a massive pituitary hormone is produced. Actually, the pictures of the thyroid glands show active condition. According to Gasche ('40), the injected thyrotropic hormone activates both the thyroid and the reacting tissues of larvae of *Salamandra salamandra* in the premetamorphic period.

Fankhauser and Watson ('49) using *T. viridescens* described a similarity in the coloration and tail of their experimental newts to those of the aquatic adults. Also in the present study, some similarities were observed between implanted animals and male adult salamanders during aquatic life of breeding season with regard to several characters such as coloration, skin, tail, body shape and condition of thyroid. These characters of adults are secondarily acquired after hey have experienced their terrestrial life. The implanted animals seem precociously to gain these characters without terrestrial life of the adult, in consequence of intensification of hormonal relations which is caused and continued by the overdose of pituitary substance.

Summary

Two or three whole adult pituitaries of the salamander were implanted to the abdominal muscle of the larvae just before metamorphosis. The metamorphosis was accelerated, but gills and gill slits remained rudimentary and the tail fin was not lost even in the oldest animals which lived for 300 days after the operation. They showed certain similarities to the male adult in the breeding season in some characters, such as coloration, skin, tail and body shape. These results seem to be partially due to the continuous activation of the thyroid glands.

References

Aoto, T. 1950. Jour. Fac. Sci. Hokkaido Univ. Ser. VI, Zool. 10 : 45-53.
Fankhauser, G. and R.C. Watson 1949. Jour. Exp. Zool. 111 : 349-392.
Gasche, P. 1940. Rev. Suisse Zool. 47 : 183-192.
Herre, W. 1935. Verh. Dtsch. Zool. Ges., Jahresvers., Stuttgart : 65-75.
Herre, W. and F. Rawiel 1939. Arch. Entw.-Mech. 139 : 86-109.