



Title	Effects of Sex-Hormones on the Kidneys of the Three-Spined Stickleback, <i>Gasterosteus aculeatus aculeatus</i> (L.) (With 8 Text-figures and 1 Table)
Author(s)	OGURO, Chitaru
Citation	北海道大學理學部紀要, 14(1), 45-50
Issue Date	1958-12
Doc URL	http://hdl.handle.net/2115/27285
Type	bulletin (article)
File Information	14(1)_P45-50.pdf



[Instructions for use](#)

**Effects of Sex-Hormones on the Kidneys of the
Three-Spined Stickleback, *Gasterosteus
aculeatus aculeatus*(L.)¹⁾**

By
Chitaru Oguro

(Akkeshi Marine Biological Station)
(With 8 Text-figures and 1 Table)

Since Möbius (1885) reported that the kidneys of the male stickleback become hypertrophied during the breeding season, the fact attracted the attention of some workers (Courrier, '22; van Oordt, '23, '24; Craig-Bennett, '31; Ikeda, '33). From observations that the castration of the male in the breeding season brought about atrophy of the kidneys (Craig-Bennett, '31; Ikeda, '33), it was surmised that the hypertrophy of the kidneys depends on the testes as it does with the other breeding sexual characters, i.e. nuptial color and pearl organs. However, no considerations have been called forth on the nature of the female kidneys and on whether the kidneys of the female respond to sex-hormones. To clarify these subjects, the present study was designed. The results obtained lead to the conclusion that the kidneys of both sexes are physiologically similar.

Before going further, the writer wishes to express his cordial thanks to Professor Tohru Uchida for his kind guidance and correction of the manuscript. His gratitude is also due to Professor Kiichiro Yamamoto, Faculty of Fisheries, for his encouragement given to the present writer.

Material and methods

The material used in the present study was adult fish (*Gasterosteus aculeatus aculeatus*) caught in early winter of 1955 and spring of 1956, 1957 at Akkeshi. The fish secured in 1956 and 1957 were migrating. During the experimental period the fish were reared in running water under conditions of light and temperature similar to those in nature. They were fed with fish meat and liver once a day.

Castration took place according to Ikeda's technique (Ikeda, '33). Use of sulfas and penicillin solutions for rearing during several days after the operation was effective in preventing infection by bacteria and water molds. Methyl testosterone and ethinyl estradiol were used in this experiment, as androgenic and estrogenic substances respectively. Implantation was achieved by inserting a small piece of hormone pellet (ca. 1 mg for methyl testosterone, ca. 0.004 mg

1) Contributions from the Akkeshi Marine Biological Station, No. 97.

Jour. Fac. Sci. Hokkaido Univ. Ser. VI, Zool., 14, 1958.

for ethinyl estradiol; Teikoku Hormone Mfg. Co.) into the abdominal cavity. At autopsy, the fish were fixed in Bouin's solution after the macroscopical observations on the fresh kidneys. For histological examinations, the kidneys were removed and cut in paraffin at 8μ thickness. The sections were stained with Delafield's hematoxylin and eosin.

The height of the epithelial walls of the renal tubules was measured after being drawn with camera lucida with a magnification of 1000 times. The average value calculated from ca. 40 sections of the renal tubules was recorded in each individual. The mathematical mean in each experimental lot comprised of 5-7 fish served as average height of the renal tubule in this lot.

Observations

(1) *Observations on the normal fish*

As noted before, the kidneys of the normal male fish become hypertrophied during the breeding season (from late May to July in Akkeshi), and the epithelial cells of the renal tubules reach about 3 times of the height they have during the sexually quiescent period. On the other hand, the kidneys of the female show no changes all the year round. The kidneys of the male fish in the sexually quiescent season are indistinguishable from those of the females. The average height of the epithelial cells in the renal tubules is 15.5μ in both the female and the sexually quiescent male. At the late stages of breeding, the epithelial cells of the renal tubules attain to maximum height, ca. 40μ . The other modifications of the epithelial cells of the renal tubules coincide pretty well with the increase of the cell height (Ikeda, '33; Oguro, '57). The swelling of the kidneys owes chiefly to the hyperplasia of the epithelial cells of the renal tubules, so that the height of the epithelial cells in the renal tubules can be deemed an indicator showing a degree of hypertrophy or modifications of the kidneys. In the following, the height of the epithelial cells in the renal tubules is described mainly as an index of the modifications of the kidneys.

(2) *Experiments on the male fish*

Experiments on the male fish were accomplished in the following 4 lots.

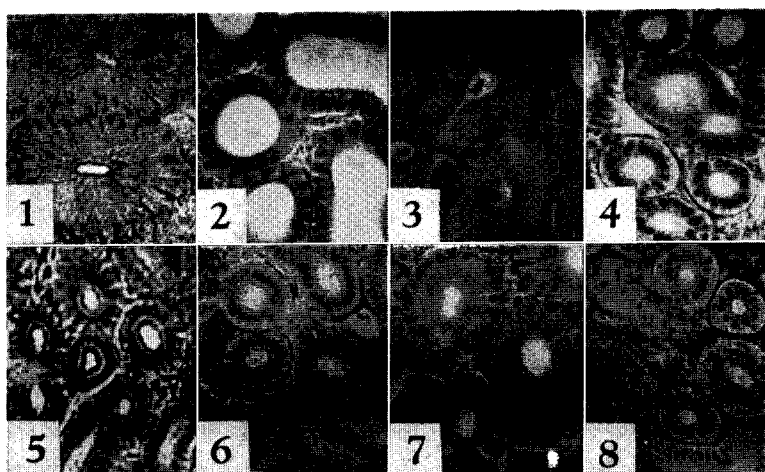
Lot 2: Testes were removed bilaterally. The swollen kidneys of the male began to atrophy; 10 days after, the height of the epithelial cells in the renal tubules had decreased to three-fifths of the original height. The 30th day after the operation, the kidneys appeared reddish brown like those of the non-breeding male or female, while those of the normal breeding male were pinkish white in appearance. The height of the epithelial cells in the renal tubules was reduced to 17.5μ on average, about one-half of the original size.

Lot 3: Implantation of the androgen pellet into the abdominal cavity was performed simultaneously with castration. 10 days after, the kidneys were slightly dwindled. This may have been brought about by the harmful effects of the operation on the physiological condition of the fish. However, 30 days after the procedure the organs recovered to the level of the normal breeding males both in appearance and in size.

Lot 4: The estrogen pellet was implanted immediately after the bilateral

castration. At autopsy, 30 days after the procedure, the height of the epithelial cells in the renal tubules was reduced to 18.5μ and the appearance of the kidneys was very similar to the female ones.

Lot 5: Twenty μg of estradiol benzoate suspended in balanced saline was intraperitoneally injected into each intact male. After 5 injections at intervals of 5 days, the kidneys were examined. Histological observations showed that the kidneys had been transformed into an organ very similar to that of the non-breeding male. The height of the epithelial cells in the renal tubules was 18.0μ on average.



Sections of the renal tubules of the kidneys. ca. $\times 150$

1: normal breeding male. 2: castrated male. 3: castrated male in which androgen was implanted. 4: castrated male in which estrogen was implanted. 5: normal female. 6: castrated female. 7: castrated female in which androgen was implanted. 8: castrated female in which estrogen was implanted.

(3) Experiments on the female fish

The following 5 lots of experiments were carried out in the female fish.

Lot 7: Removal of ovaries took place. The gonadectomy seemed more hurtful to the female than to the male because about 20% of the spayed fish died resulting from the castration, though the mortality in the male fish was 0. On the 10th day after the gonadectomy, it was revealed that the kidneys were somewhat atrophied due perhaps to the same reason described for lot 3. The height of the epithelial cells in the renal tubules was reduced, being 11.9μ on average. On the 30th day after the procedure, however, the condition of the kidneys recovered to the original form, the height of the epithelial cells in the renal tubules being 15.0μ on

average.

Lot 8: In this lot the spayed fish received androgen implantation. They were sacrificed 30 days after the treatment. Their kidneys resembled those of the breeding male in appearance. The height of the epithelial cells was 31.5μ .

Lot 9: The fish of this lot were castrated and implanted with the estrogen pellet. They were sacrificed 30 days after the procedure. The external appearance of the kidneys seemed to be undistinguishable from that of the intact female. Microscopical observations also showed no histological change and the height of the epithelial cells in the renal tubules was 15.0μ on average.

Lot 10: The females without surgical procedure were implanted with the androgen pellet. The results indicated that the implantation of the androgen pellet brought about a marked hypertrophy of the kidneys. The height of the epithelial cells in the renal tubules was 28.8μ on the 30th day after the implantation.

Lot 11: Each fish of this lot was implanted with two testes in the abdominal cavity. The ovaries of the host received no procedure. They were sacrificed 10 days after the implantation. At autopsy, all of the implanted testes were at the site of the implantation. No changes were observed in outer appearance of the kidneys. However, microscopical observations revealed that the height of the epithelial cells in the renal tubules had slightly increased in 2 individuals out of 4 treated fish, it being 18.8μ on average. The kidneys of the remainders were apparently of female type and the average height of the epithelial cells was 15.4μ .

Discussion

The alterations in the male kidneys of the stickleback occur parallel to the activity of the testes, and castration calls forth a retrogressive change in the kidneys (van Oordt, '23, '24; Craig-Bennett, '31; Ikeda, '33). These facts suggest that the peculiar hypertrophy of the kidneys of the breeding male is brought about by a substance from the testes. Up to the present, however, no consideration has been given to the sex difference in the kidneys of the stickleback.

In the females, the castration failed to cause any change in the kidneys (lot 7). Double treatment with ovariectomy and estrogen implantation brought about also no changes on the kidneys of the female (lot 9). In the breeding males, the repeated injections of estrogen induced a retrogressive change (lot 5). As observed in lot 2 and 4, estrogen exerts no promotive effects on the kidney-regression which was brought about by castration. From the above findings it seems to reasonable to conclude that estrogen affects only swollen kidneys.

Administration of androgen to the female changed its kidneys into the breeding male type (lots 8, 10). Androgen implantation on the castrated males also recalled the hypertrophy of the kidneys (lot 3), while castration without androgen implantation resulted in the regression of the kidneys (lot 2). These results lead that androgen acts directly on the kidneys to alter the organ into the breeding

Table 1. Summary of the experimental results

Sex	Lot	Surgical procedure	Dosage	Height of epithelial cells of renal tubules in μ	
				10 days after	30 days after
♂	1				37.5
	2	Castration		22.2	17.5
	3	Castration	Androgen implantation		
	4	Castration	Estrogen implantation	30.0	35.0
	5		Estrogen injection	21.9	18.5
♀					18.0
	6	Castration			15.5
	7	Castration	Androgen implantation	11.9	15.0
	8	Castration	Estrogen implantation		31.5
	9	Castration	Androgen implantation	14.4	15.0
	10		Androgen implantation		28.8
	11	Testes implantation		17.1	

male type, the fact being surmised from the previous works (Craig-Bennett, '31; Ikeda, '33).

In the three-spined stickleback, the gonads of both sexes have resistance to hormone treatment. The gonads of this species showed no observable changes in the histological pictures when the opposite sex hormone was administered at the dosage level of this experiment. This forms a contrast with the report of Egami ('55) in *Oryzias latipes* that the ovaries of androgen-treated fish become atrophied, even if there are differences of treatment and dosage. Androgen was able to cause a hypertrophy in the female kidneys as well as in the shrunken organs of the castrated males (lots 3,8), whereas estrogen prevents the kidneys from swelling (lot 5). Moreover, the results of lot 8 and 10 revealed that the presence of ovaries slightly interfered with the effects of androgen to hypertrophy the kidneys. In 2 individuals out of 4 females implanted with testes, the kidneys were slightly swollen, while those of the remaining 2 were not affected by the implantation (lot 11). The result may be explained by the difference of maturity in the implanted testes and the ovaries of the hosts, in which case, if the activity of the ovaries were predominant to that of the implanted testes, the kidneys would not be affected in appearance; and in the reverse situation the hypertrophy of the kidneys would be brought about. In consideration of the results above noted, the retrogressive alteration found in the kidneys treated with estrogen is not the result of the depression of the testes.

From the present experiments, it is concluded that the kidneys of both sexes behave similarly in response to sex-hormones. Androgen and estrogen seem to

act in opposite ways each other on the kidneys of the three-spined stickleback.

Summary

1. In the three-spined stickleback, (*Gasterosteus aculeatus aculeatus*), effects of sex-hormones and of castration on the kidneys were studied in either sex.

2. Castration caused a retrogressive change in the kidneys of the breeding males, while it failed to cause any change in the female ones.

3. The implantation of the androgen pellet brought about a hypertrophy in the kidneys of the females and those of the castrated males. On the other hand, estrogen exerted no effects on the kidneys of the females and castrated males.

4. The present experiments indicate that the kidneys of both sexes behave similarly in response to sex-hormones. Upon the kidneys, hormone of one sex acts in opposite way to that of the other one.

Literature

- Courrier, R. 1922. Sur l'indépendance de la glande séminale et des caractères sexuels secondaires chez les poissons. Compt. rend. Acad. sci., 174 : 70-72.
- Craig-Bennett, A. 1931. The reproductive cycle of the three-spined stickleback, *Gasterosteus aculeatus*, Linn. Philosoph. Transact. Roy. Soc. London, 219 (ser. B) : 197-279.
- Egami, N. 1955. Effects of estrogen and androgen on the weight and structure of the liver of the fish, *Oryzias latipes*. Annot. Zool. Japon., 28 : 79-85.
- Ikeda, K. 1933. Effect of castration on the secondary sexual characters of anadromous three-spined stickleback, *Gasterosteus aculeatus aculeatus* (L.). Jap. J. Zool., 5 : 135-157.
- Möbius, K. 1885. Ueber die Eigenschaften und den Ursprung der Schleimfäden des Seestichlingnestes. Arch. f. mikrosk. Anat., 25 : 554-563.
- Oguro, C. 1957. Notes on the change in the kidney of *Gasterosteus aculeatus aculeatus* (L.) caused by the estrogen administration. J. Fac. Sci., Hokkaido Univ., (Zool.) 13 : 404-407.
- van Oordt, G.J. 1923. Secondary sex-characters and testis of the ten-spined stickleback (*Gasterosteus pungitius* L.). Proc. Sec. Sci., Kon. Akad. Wet. Amsterdam, 26 : 309-314.
- van Oordt, G.J. 1924. Die Veränderungen des Hodens während des Auftretens der sekundären Geschlechtsmerkmale bei Fischen. I. *Gasterosteus pungitius* L. Arch. f. mikrosk. Anat. u. Entwicklungsmech., 102 : 379-405.