



|                  |   |
|------------------|---|
| Title            | A Cytological Study on the Preoptic Neurosecretory Cells in Thyroidectomized Xenopus (With 1 Plate and 1 Table) |
| Author(s)        | NOMURA, Eunice W.; WATANABE, Yûichi G.  |
| Citation         | 北海道大學理學部紀要, 17(4), 539-544  |
| Issue Date       | 1971-04   |
| Doc URL          | <a href="http://hdl.handle.net/2115/27504">http://hdl.handle.net/2115/27504</a>                                 |
| Type             | bulletin (article)  |
| File Information | 17(4)_P539-544.pdf  |



[Instructions for use](#)

# A Cytological Study on the Preoptic Neurosecretory Cells in Thyroidectomized *Xenopus*<sup>1)</sup>

By

Eunice W. Nomura<sup>2)</sup> and Yūichi G. Watanabe<sup>3)</sup>

Zoological Institute, Hokkaido University

(With 1 Plate and 1 Table)

A great deal of works have been made in an attempt to establish the relationship between thyroid function and the hypothalamo-hypophysial pathway (for reviews, see D'Angelo, 1963; Reichlin, 1966). One experimental approach to this problem is an alteration of thyroxin level which, in turn, has been known to alter the amount of TSH output. If the discharge of TSH is under the control of the hypothalamus, any changes in the hypothalamic region should be recognizable. Along this direction, a series of experiments has been carried out in the rat (Shiozaki, 1956; Shibusawa *et al.*, 1956a, b; Yamada, 1957; Shimizu, 1959; Akada, 1959). However, in amphibians, only limited data are available for this subject (Goos, 1968; Goos *et al.*, 1968).

The present work was undertaken to find whether thyroid deficiency leads to morphological changes in the preoptic neurosecretory cells of adult *Xenopus*.

## Material and Methods

Fifteen adult *Xenopus* were anesthetized with MS 222 and their thyroid gland was surgically removed under a dissecting microscope. In spite of considerable bleeding, mortality was low. The animals were killed 1, 3, 7, 15, 40 and 65 days after the operation and their brain was fixed in Helly's solution for 3 hours. Both intact animals and those 1, 3 and 7 days after being sham-operated were employed as controls. Serial paraffin sections of the whole brain were cut sagittally at 7  $\mu$ . They were stained mainly with Gabe's aldehyde fuchsin (AF) followed by Halmi's counter stain technique (Halmi, 1952). A few sections containing *pars distalis* were picked out for Heidenhain's Azan stain.

---

1) Contribution No. 889 from the Zoological Institute, Faculty of Science, Hokkaido University, Sapporo, Japan, 060.

2) Present Address: Dep. de Fisiologia, Fac. de Ciências Medicas, Curitiba (Parana), Brasil.

3) Present Address: Department of Anatomy, Tokushima University School of Medicine, Tokushima, Japan.

*Jour. Fac. Sci. Hokkaido Univ. Ser. VI, Zool. 17, 1971.*

The relative number of the preoptic neurosecretory cells was counted on every fifth section by counting the cells possessing nucleoli, and then each value was summed up. Also the nuclear size of the neurosecretory cells was measured on every tenth section under magnification of  $1,200\times$  using an ocular micrometer. Only cells with clear-contoured nucleus and distinct nucleolus were employed for measurement.

## Results

*Hypophysis.* The identification and cytology of the thyrotropes of *Xenopus* have previously been made elsewhere (Cordier, 1953; Guardabassi and Bianchi, 1962; Kerr, 1965). Both intact and sham-operated animals had the thyrotropes showing strong basophilia and those weakly basophilic ones were very few in number (Fig. 1). One or 3 days after thyroidectomy, large vacuoles were seen in their cytoplasm (Fig. 2). Similar vacuoles were occasionally found in the sham-operated animals of the same post-operative periods. On the third day after thyroidectomy some of the thyrotropes came to lose their affinity to basic dyes and by the 7th day after operation such cells appeared like chromophobes. However, these "degranulated" cells differed from the chromophobes in that a distinct nucleolus and abundant pale cytoplasm were present in the former (Fig. 3). These empty cells were frequently seen in the hypophysis of 7 or 15 post-operative days where the densely stained thyrotropes such as seen in the hypophysis of intact or in sham-operated controls were hardly observed. In the animals 40 or 65 days after thyroidectomy, on the other hand, histological pictures of the hypophysis were variable among different individuals. In some animals, densely stained thyrotropes were rare, while in others moderately to strongly stained cells were seen frequently.

*Hypothalamus.* In contrast to the notable changes of the hypophysis, tinctorial affinity of the hypothalamic neurosecretory cells showed little changes after thyroidectomy (Figs. 4-8). In Table 1 the number and the nuclear size of the neurosecretory cells are given. The number of these cells was considerably variable among different animals. During experiment it seemed to remain unaltered. On the other hand, the nucleus of the neurosecretory cells in thyroidectomized animals were slightly larger in size than that in intact or sham-operated controls. Such nuclear enlargement was most conspicuous 40 days after thyroidectomy. The nucleoli of these cells were large and stained distinctly. Moreover, their cytoplasm was voluminous (Fig. 7). In the animals of 65 post-operative days, the nucleus of neurosecretory cells was not so large as that in 40 day-animals, and their large nucleoli stained rather weakly (Fig. 8).

## Discussion

The fact that thyroxin deficiency results in "degranulation" of the thyrotropes has been well accepted (Purves and Griesbach, 1951; D'Angelo, 1953; Kerr, 1965). In *Xenopus* Kerr (1965) describes such cytological response that takes place within the first few weeks after thyroidectomy. In accordance with

Table 1. The number and nuclear size of the hypothalamic neurosecretory cells in intact, sham-operated and thyroidectomized *Xenopus*

|         |               | Days after Operation | Body Weight (gm) | No. of Neurosecretory Cells | Size of Nucleus ( $\mu$ ) |     |     |
|---------|---------------|----------------------|------------------|-----------------------------|---------------------------|-----|-----|
| control | intact        |                      | 7.0              | 382                         | 7.3                       |     |     |
|         |               |                      | 7.4              | 521                         | 7.1                       |     |     |
|         |               |                      | 10.7             | 451                         | 7.2                       |     |     |
|         | sham-operated | 1                    |                  | 7.5                         | 485                       | 7.3 |     |
|         |               |                      |                  | 7.2                         | 606                       | 6.9 |     |
|         |               |                      |                  | 6.7                         | 398                       | 7.1 |     |
|         |               | 3                    |                  | 16.8                        | 606                       | 6.8 |     |
|         |               |                      |                  | 14.5                        | 453                       | 7.0 |     |
|         |               | 7                    |                  | 8.9                         | 466                       | 7.5 |     |
|         |               |                      |                  | 8.5                         | 542                       | 7.1 |     |
|         |               | thyroidectomized     | 1                |                             | 6.7                       | 611 | 7.6 |
|         |               |                      |                  |                             | 8.1                       | 551 | 7.6 |
|         | 8.2           |                      |                  | 504                         | 7.7                       |     |     |
| 3       |               |                      | 7.6              | 620                         | 7.2                       |     |     |
|         |               |                      | 7.4              | 636                         | 7.6                       |     |     |
|         |               |                      | 8.0              | 554                         | 7.2                       |     |     |
| 7       |               |                      | 9.1              | 520                         | 7.7                       |     |     |
|         |               |                      | 8.4              | 407                         | 7.4                       |     |     |
| 15      |               |                      | 9.7              | 605                         | 7.1                       |     |     |
|         |               |                      | 7.4              | 582                         | 7.0                       |     |     |
| 40      |               |                      | 9.8              | 525                         | 8.3                       |     |     |
|         |               |                      | 11.0             | 476                         | 8.0                       |     |     |
|         |               |                      | 10.6             | 602                         | 8.3                       |     |     |
| 65      |               |                      | 14.2             | 669                         | 7.7                       |     |     |
|         |               |                      | 9.6              | 593                         | 7.2                       |     |     |

his observation, the present results show that most of the thyrotropes degranulate within 15 days after operation.

In addition to the degranulation, occurrence of characteristic large cytoplasmic vacuoles was noticed in the thyrotropes following thyroidectomy. In the present experiment these vacuoles were seen not only in the operated animals but also in the sham-operated ones. In the latter, however, subsequent degranulation such as seen in athyroid state was not observed. This fact seems to indicate that blood thyroxin level temporarily drops after the sham-operation. In the sham-operated controls this may be attributable to the severance of blood

vessels around the thyroid gland. Probably, the severed blood vessels regenerate soon and the recovery of thyroxin level in blood restores the temporarily altered thyrotropes to the normal cytological appearance.

During the earlier post-operative period when the thyrotropes underwent degranulation, a slight nuclear enlargement was recognized in the hypothalamic neurosecretory cells. In the rat, histological difference between the hypothalamus of normal rats and that of experimental ones is reported (Shiozaki, 1956; Shibusawa *et al.*, 1956a, b; Yamada, 1957; Shimizu, 1959). These authors relate the tinctorial affinity of the neurosecretory cells to their secretory activity, but there has been no general agreement yet in regard to the relation of the two parameters. In order to know functional alterations of the hypothalamic neurosecretion, if any, techniques other than ordinary staining methods are needed. Autoradiographic investigation such as the one made on the hypothalamo-hypophysial system in dehydrated frogs would be much more promising (Vullings, 1969).

In developing *Xenopus*, it has been reported that hyperactivity of thyrotropes is accompanied by a depletion of the dorsal pseudoisocyanine (PIC)-positive neurosecretory cells (Goos, 1968; Goos *et al.*, 1968). They conclude from these experiments and a more advanced one (Goos, 1969) that TRF-producing cells do exist in the hypothalamus of this animal. The preoptic neurosecretory cells in metamorphosed *Xenopus*, on the other hand, appear to be less affected even by a sudden discharge of hypophysial TSH through thyroidectomy. These data bring us to the question whether the hypothalamo-hypophysial relationship differs between metamorphosing larva and metamorphosed one. The answer to this question awaits further study.

### Summary

The hypothalamus and the hypophysis of thyroidectomized *Xenopus* were examined histologically. It was shown that during earlier post-operative days, the thyrotropes underwent a pronounced degranulation, whereas morphological changes were rather slight in the hypothalamic neurosecretory cells. In animals 40 days after thyroidectomy a notable nuclear enlargement of the neurosecretory cells was seen, but in animals in thyroid deficiency for longer periods histological pictures of the hypophysis were inconsistent and the nuclear enlargement in their hypothalamus was less conspicuous. These results are compared with the data hitherto obtained by other investigators.

### Acknowledgement

We wish to express our sincere appreciation to Professor Tomoji Aoto for his kind advice given to us throughout the course of this work and for careful revision of the manuscript.

## References

- Akada, J. 1959. Effect of the administration of thyroid stimulating hormone on the hypothalamo-hypophyseal thyroidal system. *Endocrinol. Japon.* **6**: 233-245.
- Cordier, R. 1953. L'hypophyse de *Xenopus*. Interprétation histophysiologique. *Ann. Soc. roy. zool. Belg.* **84**: 5-16.
- D'Angelo, S.A. 1953. Cyto-physiologic aspects of thyrotrophic hormone secretion in the goitrous guinea pig. *Endocrinology* **52**: 331-337.
- 1963. Central nervous regulation of the secretion and release of thyroid stimulating hormone. *In*: A.V. Nalbandov (ed.), *Advances in Neuroendocrinology*, University of Illinois Press, Urbana, pp. 159-210.
- Goos, H.J. Th. 1968. Hypothalamic neurosecretion and metamorphosis in *Xenopus laevis*. III. The effect of an interruption of thyroid hormone synthesis. *Z. Zellforsch.* **92**: 583-587.
- 1969. Hypothalamic neurosecretion and metamorphosis in *Xenopus laevis*. IV. The effect of extirpation of the presumed TRF cells and of a subsequent PTU treatment. *Ibid.* **97**: 449-458.
- , Anne-Marie de Knecht and J. de Vries 1968. Hypothalamic neurosecretion and metamorphosis in *Xenopus laevis*. I. The effect of propylthiouracil. *Ibid.* **86**: 384-392.
- Guardabassi, A. and D. Bianchi 1962. La cytologie hypophysaire chez *Xenopus laevis* Daud. *Ibid.* **56**: 540-551.
- Halmi, N.S. 1952. Differentiation of two types of basophils in the adenohypophysis of the rat and the mouse. *Stain Technol.* **27**: 61-64.
- Kerr, T. 1965. Histology of the distal lobe of the pituitary of *Xenopus laevis* Daudin. *Gen. Comp. Endocrinol.* **6**: 232-240.
- Purves, H.D. and W.E. Griesbach 1951. The site of thyrotrophin and gonadotrophin production in the rat pituitary studied by McManus-Hotchkiss staining for glycoprotein. *Endocrinology* **49**: 244-264.
- Reichlin, S. 1966. Control of thyrotropic hormone secretion. *In*: L. Martini, and W.F. Ganong (eds.), *Neuroendocrinology*, vol. I, Academic Press, New York, pp. 445-536.
- Shibusawa, K., S. Saito, K. Nishi, T. Yamamoto, K. Tomizawa and C. Abé 1956a. The hypothalamic control of the thyrotroph-thyroidal function. *Endocrinol. Japon.* **3**: 116-124.
- , ——, ——, C. Abé and K. Tomizawa 1956b. The effect of goitrogens on the hypothalamic neurosecretion in experimental animals. *Ibid.* **3**: 138-143.
- Shimizu, T. 1959. The hypothalamic neurosecretory phenomena and the activity of thyroid gland in partially thyroidectomized rats. *Ibid.* **6**: 75-85.
- Shiozaki, N. 1956. Changes in rat's hypothalamic neurosecretion following thyroidectomy. *Ibid.* **3**: 242-249.
- Vullings, H.G.B. 1969. Effects of dehydration on the hypothalamo-hypophysial system of *Rana temporaria*. An autoradiographic investigation with <sup>35</sup>S-cysteine. *Gen. Comp. Endocrinol.* **13**: 539.
- Yamada, T. 1957. Hyperactivity of hypothalamic neurosecretion and coincidental occurrence of thyroid enlargement following administration of methylthiouracil. *Endocrinol. Japon.* **4**: 110-119.

### Explanation of Plate IX

Fig. 1. Section through the pars distalis of an intact toad showing densely stained thyrotropes (arrows). In the lower half of the picture, another type of basophils of small size (presumably "gonadotropes") is also seen. AF+counter stain.  $\times 480$ .

Fig. 2. Vacuolated thyrotropes found in toads 3 days after thyroidectomy. Heidenhain's Azan stain.  $\times 480$ .

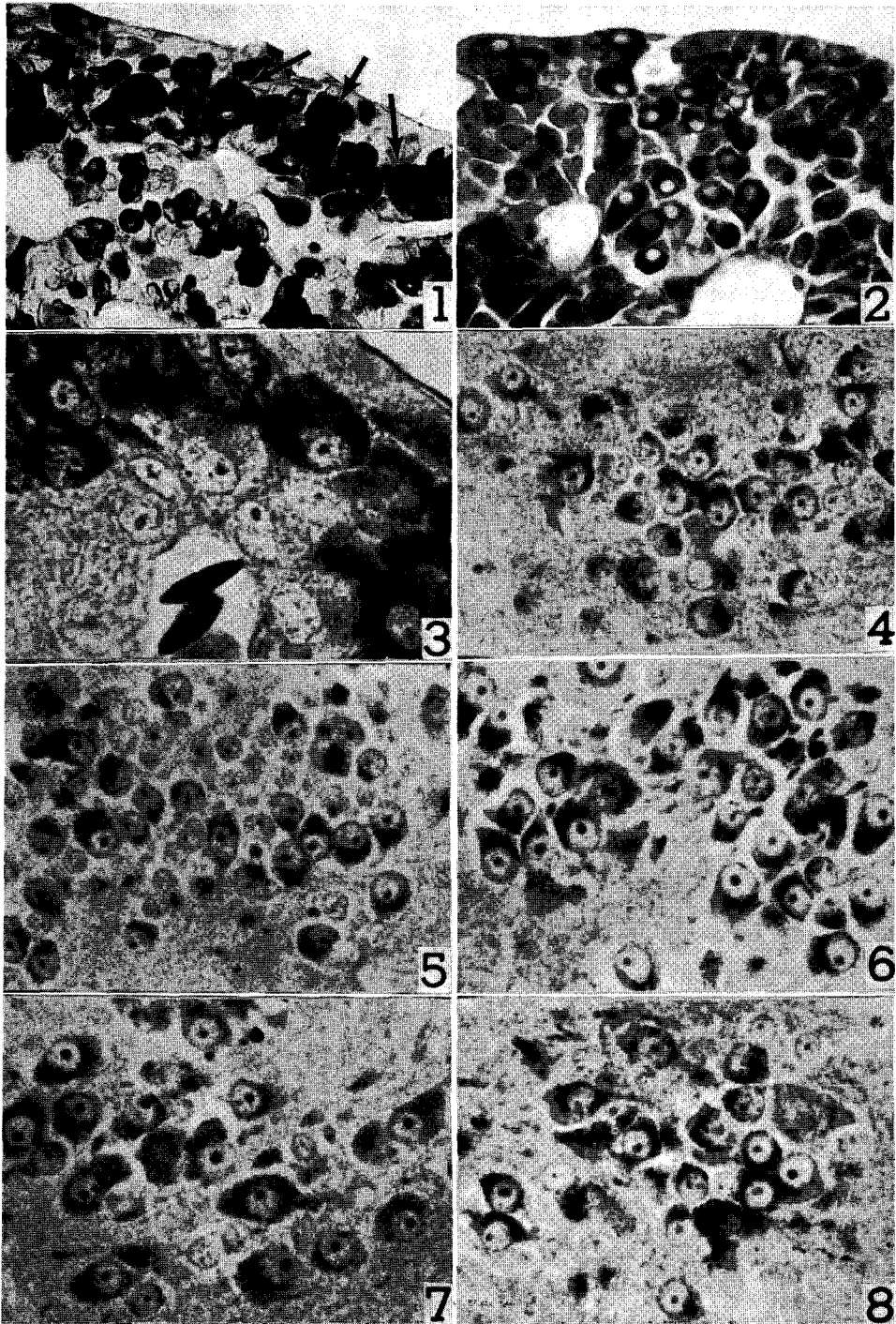
Fig. 3. Seven days after thyroidectomy. Completely degranulated thyrotropes lying against the blood capillary. Note large-sized nucleoli and rich cytoplasm. AF+counter stain.  $\times 1,200$ .

Figs. 4 and 5. The neurosecretory cells in the hypothalamus of an intact toad (Fig 4) and of a toad 7 days after sham-operation (Fig. 5). Not much difference was seen between the two specimens. AF+counter stain.  $\times 480$ .

Fig. 6. The neurosecretory cells 7 days after thyroidectomy. Note a large, distinct nucleolus in each nucleus. AF+counter stain.  $\times 480$ .

Fig. 7. Forty days after thyroidectomy. Both the nucleus and the nucleolus became larger in size. AF+counter stain.  $\times 480$ .

Fig. 8. Sixty-five days after thyroidectomy. Nucleus is rather small in size, with a weakly stained nucleolus. AF-counter stain.  $\times 480$ .



*E. W. Nomura and Y. G. Watanabe: Preoptic Nucleus and Thyroidectomy*