Jpn. J. Vet. Res., **34**, 251–267 (1986)

ECHOCARDIOGRAPHIC DETECTION OF BOVINE CARDIAC DISEASES

Yoshinori YAMAGA and Kimehiko TOO

(Received for publication August 11, 1986)

Cows with dilated (congestive) cardiomyopathy, chronic large abscesses of the pericardium and bovine leukemia were examined using echocardiography to determine its diagnostic capacities. M-mode echocardiographic data from 15 normal Holstein cows were collected to evaluate abnormalities associated with three cases. Case 1 with dilated cardiomyopathy was grossly characterized by dilatation of all four cardiac cavities and poor ventricular function. Case 2 showed large pericardial abscesses accompanied by cardial atrophy echocardiographically. For the purpose of the differential diagnosis, drainage from both thoracic cavities and biopsy of the lump within the abscess were performed and securely done under ultrasound guidance. Case 2 could be differentiated from dilated cardiomyopathy and traumatic pericarditis by echocardiography. The echocardiographic features of case 3 were strikingly symmetrical thickened ventricular walls due to leukemic infiltration of the myocardium. Cases 1 and 2 were characterized by an abnormal mitral closure on the M-mode echocardiogram indicative of an elevated left ventricular end-diastolic pressure. Echocardiographic findings reflected grossly pathological findings. By echocardiographic measurement, the left ventricular wall thickness at the end-systole of each case did not differ from that by necropsy measurement. Echocardiography was found to be an accurate technique for obtaining pathophysiological information on bovine cardiac diseases.

Key words: M-mode and two-dimensional echocardiography, bovine dilated cardiomyopathy, chronic large abscesses of the pericardium, bovine leukemia.

INTRODUCTION

Echocardiography has recently been introduced into veterinary medicine and been found to be useful in documenting cardiac abnormalities in many species.[1–5,7–10,13,15–17,20,22–24] In the bovine, it was reported that M-mode echocardiography is a useful method for detecting vegetative endocarditis,[8,15,24] traumatic pericarditis[7,24] and congenital cardiac malformation.[2,9,17] Real time, two-dimensional echocardiography has more recently been used to visualize cardiac structures and their

Veterinary Hospital Faculty of Veterinary Medicine Hokkaido University, Sapporo 060, Japan

motions and has been highly appraised.[5,16,22,25] But two-dimensional echocardiographic observations have been limited to a few case reports, as compared to the many cases reported using the M-mode method. The insufficient number of reports on M-mode echocardiographic measurements in normal cows[5,14] makes it difficult to evaluate the usefulness of echocardiography in cardiovascular diseases.

The purpose of the present report is to describe the echocardiographic features in three cows and to compare the M-mode measurements between normal Holstein cows and the present cases. In addition, we attempted to correlate these findings with the clinical and postmortem findings.

MATERIALS AND METHODS

Echocardiographic examination of all cows was performed using the same technique and instrument as described in the previous report.[25] A M-mode echocardiographic instrument (Echocardiograph SSD–11OS, Aloka Co. Ltd., Tokyo, with a 2.25 MHz probe) was used to produce one-dimensional cardiac images, which were viewed on an oscilloscope and recorded permanently with a line scan recorder for continuous recording (UCG recorder SSZ-91, Aloka) on heat sensitive paper. Two-dimensional echocardiograms were obtained using an electronic linear-array scanner equipped with a 3.5 MHz transducer (EUB 25–M, Hitachi Medical Corp., Tokyo), which can also display M-mode echograms. The frozen images on the CRT screen were photographed with a Polaroid camera. Real time, two-dimensional echocardiograms were recorded on a 3/4-inch videotape.

Each transducer for M-mode and two-dimensional echocardiography was oriented to several planes at the standard examination position[25] and was applied to the skin with coupling gel.

Echocardiographic data from 15 normal Holstein cows (approximately 600 kg) were collected to complement those from previous reports[5,14] and to evaluate abnormalities associated with the three cases. Moreover, additional structural information on the normal bovine heart was provided by a left atrial/aortic root ratio, a left ventricular wall excursion, a left ventricular wall velocity and a left ventricular wall thickness at the end-systole as well as at the end-diastole. A leading edge method of measurement, wherein the most anterior echo boundaries are used, was employed for all echocardiograms.[4,19]

Three cows suspected of having dilated (congestive) cardiomyopathy or bovine leukemia were admitted to the Veterinary Teaching Hospital of Hokkaido University. Each animal was examined echocardiographically and standard diagnostic techniques were performed. Echocardiographic findings were contrasted with the results of standard examinations. Echocardiographic measurements were compared with the cardiac postmortem findings, and the left ventricular wall thickness at necropsy was measured at the level of the tip of the mitral leaflet. The diagnosis was

confirmed by pathological findings.

RESULTS

Normal cows: Data from complete M-mode echocardiographic evaluations of 15 normal Holstein cows are shown in the Table. These data were compared with the values of the three cases.

Case cows: Case 1: A 4-year-old Holstein cow which had calved three times was admitted as a suspected case of dilated (congestive) cardiomyopathy. The cow showed depression and decreased milk production. Severe brisket edema, prominent jugular venous pulsations, weakness of the heart sound, sinus tachycardia and hyperpnea were evident. Hematological and serological examinations showed an elevated serum gamma glutamyl transferase. An electrocardiogram with the A-B lead showed prolonged and tall P waves, and the QRS complexes and T waves were of low voltage. Phonocardiography revealed an accentuated third heart sound.

Long-axis, intercostal two-dimensional echocardiography revealed dilatation of the left ventricle and atrium (fig. 1) and reduced overall mobility of the ventricular walls in real time display. The right atrium and ventricle also were remarkably enlarged. Pericardial and pleural effusions were noted (fig. 1).

M-mode echocardiographic measurements are shown in the Table. In this case, dilated ventricular dimensions, an increased left atrial dimension, an elevated left atrial/aortic root ratio and a decreased left ventricular wall thickness at the end-systole were recognized. The left ventricular wall excursion, left ventricular wall velocity, fractional shortening and mean velocity of circumferential fiber shortening were all reduced. In addition to the reduced mobility of the right ventricular wall, the right ventricular wall thickness at the end-diastole was increased (tab., fig. 2). The configuration of the mitral valve echoes was very abnormal. A rounding of the descent of the mitral leaflets (B-B'step or B-shoulder) was present (fig. 3). The early diastolic closing slope (E-F slope) was steeper in this case. Both septal and lateral mitral leaflets were easily recorded and displaced posteriorly in relation to the interventricular septum echocardiographically.

The patient was treated with digitalis glycosides, diuretics and other supportive therapy, but the condition was not improved. On the basis of these findings, a clinical diagnosis of dilated cardiomyopathy was made and the cow was euthanatized.

Necropsy was performed for comparison with the echocardiographic findings and to confirm the clinical diagnosis. The heart was dilated with a globoid appearance (fig. 4). The measurement of the left ventricular wall thickness was 34 mm. The right ventricular wall was thickened (23mm). Pericardial and pleural effusions were present. Microscopically, there were edematous and fibrous swelling in the interstitium, multiple atrophy of myocardial fibers and vacuolar degeneration of the myocardium. The liver was severely enlarged and congested with an exaggerated

lobular pattern, and a large amount of ascites was present. Pathological findings supported the clinical diagnosis of dilated cardiomyopathy[18].

Case 2: A 4-year-old Holstein cow which had calved two times was referred after delivery as a suspected case of dilated cardiomyopathy. Anorexia, watery stools and decreased milk production were apparent. The cow had pectoral and ventral edema, marked jugular venous pulsations, sinus tachycardia and hyperpnea. Auscultation revealed a systolic murmur on the left thoracic wall, but on the right area, the heart sound itself could not be auscultated. Electrocardiographically, the QRS complexes were of low voltage and no S-T segment deviations were recognized. In the phonocardiograms, friction sounds were recorded in various cardiac phases, mainly in the systole. The left ventricular end-diastolic pressure was elevated (peak systolic pressure/end-diastolic pressure, 134 mmHg/44 mmHg).

Two-dimensional echocardiography demonstrated abnormal echoes of the surrounding heart, which consisted of echo-free space, big lumps and echogenic walls (figs. 5,6). The masses were glued partially to the heart and the movement corresponded to cardiac pulsations in the real time observation. The left ventricle was diminished and a pleural effusion was also noted (fig. 6). The heart travelled markedly to the left side because of the presence of a large mass on its right side (fig. 7). The thickened echogenic wall was not distinguishable from the pericardium.

M-mode echocardiographic values in this case are presented in the Table. Left ventricular dimensions, left ventricular wall thicknesses, an interventricular septal thickness, an aortic root dimension and a left ventricular wall excursion were all decreased. The right ventricular dimension was extremely increased, and fractional shortening was reduced. M-mode echocardiograms demonstrating the septal mitral leaflet illustrated the B-B' step pattern (fig. 8).

Drainage from both thoracic cavities was performed and suppurative fluids amounting to about 10 liters from each side were removed. There were no connections among the echo-free spaces. The cow was preliminarily diagnosed as having abscesses of the surrounding heart. After the drainage, two-dimensional echocardiography demonstrated that the heart had returned approximately to its original position, and that there was a large abscess in the right side compressing the right atrium and ventricle (fig. 9). Moreover, a biopsy of the big lump within the echo-free space was performed under ultrasound guidance, and histological examination of the specimen revealed a clot of leukocytes and fibrins. The phonocargiogram taken at this time showed a split of the second heart sound. M-mode echocardiography revealed that the time of pulmonary valvular closure was delayed when compared with that of aortic valvular closure. Because of no improvement in the clinical condition, the cow was euthanatized on the 28th day after the drainage.

Necropsy showed chronic large abscesses of the pericardium accompanied by cardiac atrophy (fig. 10) and the pleural effusion. The abscesses consisted of four

sections and were filled with suppurative fluids and big lumps composed of fibrins and leukocytes. The pericardium was adhered partially to the pyogenic membrane. The heart was small in size and the left ventricle was diminished. Cardiac walls remarkably thinned (left ventricular wall thickness ; 28 mm). The right ventricular wall had a large impression caused by the abscess. The liver was enlarged with congestion and slight increase of consistency, and it contained a large amount of ascites. The pathological findings coincided with the echocardiographic observation.

Case 3 : A 5-year-old Holstein cow was admitted with a suspected case of bovine leukemia. Left subiliac and mandibular lymph nodes were enlarged on palpation and exophthalmos was noted bilaterally. Markedly enlarged iliac lymph nodes were palpable on rectal examination. Moderate jugular venous pulsations and slight sinus tachycardia were evident. An electrocardiogram with the A-B lead showed prolonged P waves and elevated r waves, and the fourth heart sound was remarkably accentuated on phonocardiography. Hematological examination showed a striking leukocytosis (WBC ; 373,000/mm^3) with a great number of atypical lymphocytes. Serological examination revealed an elevated serum LDH level and an abnormality of LDH isoenzyme fractions. The case had bovine leukemia virus antibodies.

Two-dimensional echocardiography revealed notable thickening of the ventricular walls (fig. 11) and a dilated right ventricle.

M-mode echocardiographic measurements showed marked thickening of the left ventricular wall, the interventricular septum and the right ventricular wall (fig. 12), dilatation of the left atrium and the right venticle and an elevated left atrial /aortic root ratio (tab.). The mean velocity of circumferential fiber shortening and the left ventricular wall velocity were elevated (tab.). The cow was diagnosed as having bovine leukemia and euthanatized.

On pathological examination, the heart revealed remarkable thickening of the walls due to leukemic infiltration of the myocardium (fig. 13). There were marked splenomegaly, hepatomegaly and enlarged lymph nodes. The pathological diagnosis was a lymphosarcoma. Moreover, the left ventricular wall thickness at necropsy (45 mm) was similar to the echocardiographic left ventricular end-systolic wall thickness (49 mm).

Discussion

Real time, two-dimensional echocardiography uses pulsed, reflected ultrasound to obtain thin tomographic images of the heart. In addition to producing anatomically correct and recognizable two-dimensional images, intercostal, electronic, linear-array, two-dimensional echocardiography provides real time images of the beating heart in large animals.[25] On the other hand, the M–mode technique excels in echocardiographic measurements and the evaluation of various cardiac structural motions throughout the cardiac cycle.[4]

Dilated cardiomyopathy is grossly characterized by the dilated left ventricle and atrium with poor myocardial contractility in man.[1,4,13,18] The echocardiogram reflects the gross changes of the diseased heart.[4] In case 1, M-mode echocardiographic abnormalities were characterized by dilatation of both ventricles and the left atrium and poor left ventricular function (tab.). These were similar to the features described in other reports in dogs,[10,23] cats[20] and cows.[5] B-B' step or B-shoulder on the down slope on the mitral valve has been found with elevated left ventricular end-diastolic pressures.[4] This abnormality was present in case 1 (fig. 3), and was also reported in canine dilated cardiomyopathy.[10] The elevation of both ventricular[21] and right ventricular[12] end-diastolic pressures was described in this disease in cattle. Since no cardiac catheterization was performed in case 1, we could only speculate that case 1 had elevated left ventricular end-diastolic pressures as judged from the sign of congestive heart failure. Owing to the dilatation of both ventricles, the mitral valve was easily recorded when contrasted with normal recordings.[25] On the other hand, intercostal, real time two-dimensional echocardiography could also detect diffuse hypokinesis of both ventricles in addition to the dilated left and right ventricles and atriums, as reported in cows.[5] It seemed that linear-array, long-axis two-dimensional echocardiography in cows could recognize readily the diseased changes of the right-side heart inclusive of the left-side due to the large size of the heart as contrasted with the heart size in man and small animals.

From various routine examinations, the differential diagnosis between cases 1 and 2 was not easy. Echocardiographic findings in case 2 did not show the characteristic findings of dilated cardiomyopathy (case 1).[1,4,5,10,13,20] Although traumatic pericarditis was suspected from clinical examinations, ultrasonic examination did not show typical echocardiographic patterns in traumatic pericarditis.[5,7,24] Especially, there were big lumps within the echo-free spaces (figs. 5, 6, 7), and the thickened pericardium as seen in pericarditis was not recognized clearly from observing the real time motion. The clinical diagnosis was regarded as chronic large abscesses of the pericardium after drainage of the echo-free spaces and biopsy of the big lump under ultrasound guidance. Pathological findings supported the clinical diagnosis based on the ultrasound imaging. Moreover, echocardiography explained realistically and accurately the sources of various changes in the clinical examinations after drainage. The B-B' step pattern on the mitral valve in case 2 was the same as that in case 1 (figs. 3, 8), and elevation of left ventricular end-diastolic pressures was suspected.[4] Cardiac catheterization subsequently proved this diagnosis. It was demonstrated that B-B' step formation was produced by the elevated pressures also in bovines. In case 2, echocardiography was very useful both in grasping the pathophysiological changes and in diagnosing.

In case 3, the echocardiographic features were the strikingly symmetrical thickened ventricular walls and the left atrial enlargement (figs. 11, 12,

tab.). Echocardiograms on specific heart muscle disease (infiltrative cardiomyopathy)[18] in man are characterized by thickened cardiac walls, decreased wall motion and normal to small ventricular cavities.[3,4,13] Echocardiographic findings in this case were similar to those in man. It is well known that neoplastic cells infiltrate among the myocardial bundles in bovine lymphosarcoma.[6] Pathological examination also showed the same findings and supported the echocardiographic changes (tab.). Although this case was diagnosed from other clinical examinations, echocardiography was very helpful in detecting and explaining cardiovascular abnormalities.

Echocardiography was useful in illustrating cardiac dilatations and diminutions, thickened and thinned cardiac walls, changes of cardiac contractility and abnormalities of the surrounding heart. The data on the M–mode echocardiographic measurements of normal adult Holstein cow[5,14] were deficient in the past, and abnormal cases[5] were scarcely examined. In the present observation, it was useful to evaluate the echocardiographic measurements in each case on the basis of those recorded in normal cows (tab.). The anomalous echocardiographic findings in the cases were similar to the necropsy findings. The left ventricular wall thickness measured at necropsy in the present three cases correlated closely with the measurements obtained echocardiographically in the end-systole. In man, it is thought that hearts examined at necropsy are in the systolic phase of the cardiac cycle, and that echocardiographic measurement of the left ventricular wall thickness at the end-systole does not differ from the necropsy measurement of the left ventricular wall thickness.[11]

Two-dimensional echocardiography in this study was sufficient to detect cardiac abnormalities, although M-mode echocardiography appeared to be superior for evaluating accurately the echocardiographic measurements and cardiac cycles. In addition, two-dimensional echocardiography surpassed the M-mode technique in revealing abnormalities of the surrounding heart and providing a general view of the morbid condition.

In the present three cases, echocardiography revealed cardiac lesions and abnormalities of the surrounding heart. In conclusion, it seems that echocardiography could offer important information with respect to the clinical course and the prognosis of heart abnormalities.

Acknowledgments

The authors are grateful to the veterinarians of the Iburi-higashi and Shiribeshi Agricultural Mutural Aid Association for submitting the case materials. We also thank Dr. H. Satoh, Hokkaido University, for his advice and performance of the pathological diagnosis.

References

1) Abbasi, A. S., Chahine, R. A., Mac Alpin, R. N. & Kattus, A. A. (1973): Ultrasound in the diagnosis of primary congestive cardiomyopathy *Chest*, **63**, 937–942

2) BONAGURA, I. D. & Pipers, F. S. (1983): Diagnosis of cardiac lesions by contrast echocardiography *J. Am. Vet. Med. Assoc.*, **182**, 396–402

3) BORER, J. S., HENRY, W. L. & EPSTEIN, S. E. (1977): Echocardiographic observations in patients with systemic infiltrative disease involving the heart *Am. J. Cardiol.*, **39**, 184–188

4) FEIGENBAUM, H. (1981): Echocardiography 3rd ed., philadelphia: Lea & Febiger

5) HAGIO, M., OHTSUKA, H., MURAKAMI, T. & TATEYAMA, S. (1984): M-mode and two-dimensional echocardiographic diagnosis of bovine heart diseases *J. Jpn. Vet. Med. Assoc.*, **37**, 560–568 (in Japanese with English summary)

6) JONES, T. C. & HUNT, R. D. (1983): Veterinary Pathology 5th ed. 1250–1293, Philadelphia: Lea & Febiger

7) JOUGLAR, J.-Y., ALZIEU, J.-P. & NAVARRE, P. (1984): Cas cliniques: les pericardites traumatiques des bovins, elements de diagnostic, apport de l'échocardiographie *TM Point Vet.*, 16, 165–175

8) LACUATA, A. Q., YAMADA, H., NAKAMURA, Y. & HIROSE, T. (1980): Electrocardiographic and echocardiographic findings in four cases of bovine endocarditis *J. Am. Vet, Med. Assoc.*, **176**, 1355–1365

9) LACUATA, A. Q., YAMADA, H., HIROSE, T. & YANAGIYA, G. (1981): Tetralogy of Fallot in a heifer *J. Am. Vet Med. Assoc.*, **178**, 830–836

10) LOMBARD, C. W. (1984): Echocardiographic and clinical signs of canine dilated cardiomyopathy *J. Small Anim. Pract.*, **25**, 59–70

11) MARON, B. J., HENRY, W. L., ROBERTS, W. C. & EPSTEIN, S. E. (1977): Comparison of echocardiographic and necropsy measurements of ventricular wall thicknesses in patients with and without disproportionate septal thickening *Circulation*, **55**, 341–346

12) MARTIG, J., TSCHUDI, P., PERRITAZ, C., TONTIS, A. & LUGINBÜHL, H. (1982): Gehäufte Fälle von Herzinsuffizienz beim Rind, Vorläufige Mitteilung *Schweiz. Arch. Tierheilk.*, **124**, 69–82

13) MINTZ, G. S., KOTLER, M. N., SEGAL B. L. & PARRYW. R. (1978): Echocardiographic features of cardiomyopathy *Cardiovasc. Clin.*, **9**, 123–137

14) PIPERS, F. S., REEF, V. & HAMLIN, R. L. (1978): Echocardiography in the bovine animal *Bovine Practioner*, **13**, 114–118

15) PIPERS, F. S. RINGS, D. M., HULL, B. L., HOFFSIS, G. F., REEF, V. & HAMLIN, R. L. (1978): Echocardiographic diagnosis of endocarditis in a bull *J. Am. Vet. Med. Assoc.*, **172**, 1313–1316

16) PIPERS, F. S., REEF, V. & WILSON, J. (1985): Echocardiographic detection of ventricular septal defects in large animals *J. Am. Vet. Med. Assoc.*, **187**, 810–816

17) REEF, V. B. & HATTEL, A. L. (1984): Echocardiographic detection of tetralogy of Fallot and myocardial abscesses in a calf *Cornell Vet.*, **74**, 81–95

18) Report of the WHO/ISFC task force on the definition and classification of cardiomyopathies (1980): *Br. Heart J.*, **44**, 672–673

19) SAHN, D. J., DEMARIA, A., KISSIO, J. & WEYMAN, A. (1978): Recommendations regarding quantitation in M-mode echocardiography: results of a survey of echocardiographic measurements *Circulation*, **58**, 1072–1083

20) SODERBERG, S. F., BOON, J. A., WINGFIELD, W. E. & MILLER, C. W. (1983): M-mode echocardiography as a diagnostic aid for feline cardiomyopathy *Vet. Radiol.*, **24**, 66–73

21) SONODA, M., TAKAHASHI, K., KUROSAWA, T., SUZUKI, T., NAKADE, T., MATSUKAWA, K. & CHIHAYA, Y. (1984): (translated title) Studies on idiopathic congestive cardiomyopathy in cattle *J. Vet. Clinic*, (247), 3–11 (in Japanese)

22) WARE, W. A., BONAGURA, J. D. & RINGS, D. M. (1986): Echocardiographic diagnosis of pulmonic valve vegetative endocarditis in a cow *J. Am. Vet. Med. Assoc.*, **188**, 185–187

23) YAMADA, E. (1980): A canine case of congestive myocardosis *J. Jpn. Vet. Med. Assoc.*, **33**, 471–476 (in Japanese with English summary)

24) YAMADA, H. & YONEDA, Y. (1975): Studies on ultrasonic diagnosis in veterinary practice I. Traumatic pericarditis and endocarditis in cows *J. Jpn. Vet. Med. Assoc.*, **28**, 6–12
(in Japanese with English summary)

25) YAMAGA, Y. & TOO, K. (1984): Diagnostic ultrasound imaging in domestic animals: Two-dimensional and M-mode echocardiography *Jpn. J. Vet. Sci.*, **46**, 493–503

TABLE *Echocardiographic measurements in normal and case cows*

PARAMETERS		NORMAL (n=15) MEAN	SD	CASE (No.) 1	2	3
HR	(beats/min)	58	6.9	94	88	81
BW	(kg)	589	62.9	590	480	640
LVDd	(mm)	97	7.1	110	74	91
LVDs	(mm)	57	5.8	88	49	57
LVWTd	(mm)	21	1.5	23	17	37
LVWTs	(mm)	37	2.3	32	28	49
LVWE	(mm)	27	2.6	13	20	23
LVWV	(mm/sec)	68	7.5	56	61	83
IVST	(mm)	21	1.6	17	17	32
RVD	(mm)	32	6.2	62	54	55
RVWT	(mm)	9	0.9	15	12	17
AoD	(mm)	70	3.3	72	61	72
LAD	(mm)	56	5.0	76	51	84
LA/Ao		0.81	0.054	1.06	0.84	1.18
ET	(msec)	396	26.4	236	330	278
FS		0.41	0.035	0.20	0.34	0.37
mVcf	(circ/sec)	1.05	0.075	0.85	1.03	1.34
E-F slope	(mm/sec)	112	20.9	230	84	115

HR = heart rate; BW = body weight; LVDd(s) = left ventricular dimension at end-diastole(systole); LVWTd(s) = left ventricular wall thickness at end-diastole(systole); LVWE = left ventricular wall excursion; LVWV = left ventricular wall velocity; IVST = interventricular septal thickness at end-diastole; RVD = right ventricular dimension; RVWT = right ventricular wall thickness at end-diastole; AoD = aortic root dimension; LAD = left atrial dimension; LA/Ao = left atrial/aortic root rotio; ET = ejection time; FS = fractional shortening; mVcf = mean velocity of circumferential fiber shortening; E-F slope = velocity of mitral valve closure; SD = standard deviation.

EXPLANATION OF PLATE

PLATE I

Figs. 1–4 Case 1

Fig. 1 Left intercostal long-axis two-dimensional echocardiogram of case 1 with dilated cardiomyopathy. The left ventricle (LV) is dilated and the pericardial effusion (PE) is visible. Pe : pericardium, TW : thoracic wall, D : dorsal, V : ventral.

Fig. 2 Ventricular M-mode echocardiograms of case 1 with dilated cardiomyopathy recorded from the right 4th intercostal space.
a) The left ventricle(LV) is dilated. The motion of the left ventricular wall (LVW) and the interventricular septum(IVS) is markedly reduced.
b) The right ventricle (RV) is dilated and the wall with reduced mobility is thickened. One-centimeter-deep calibration dots are recorded every 0.5 seconds. RVW : right ventricular wall, Lu : lung, ECG : electrocardiogram. Other abbreviations as above figures.

Fig. 3 M-mode echocardiogram of the mitral valve(MV) of case 1 demonstrating abnormal mitral closure (B-B' step or B-shoulder, Arrow) TV : tricuspid valve. Other abbreviations as in the above figures.

Fig. 4 Necropsy specimen of case 1. a) left-side heart, b) right-side heart. The heart is dilated with a globoid appearance. The right ventricular wall(RVW) is thickened. Ao : aorta, LA : left atrium. Other abbreviations as in the above figures.

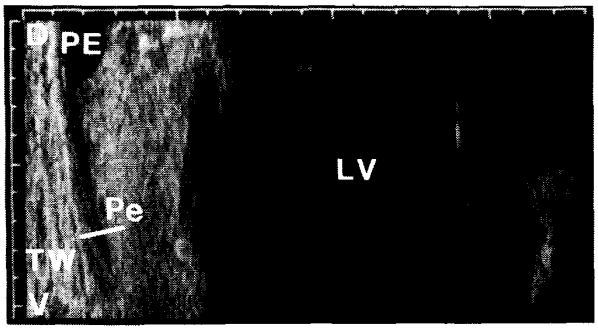

Fig. 1

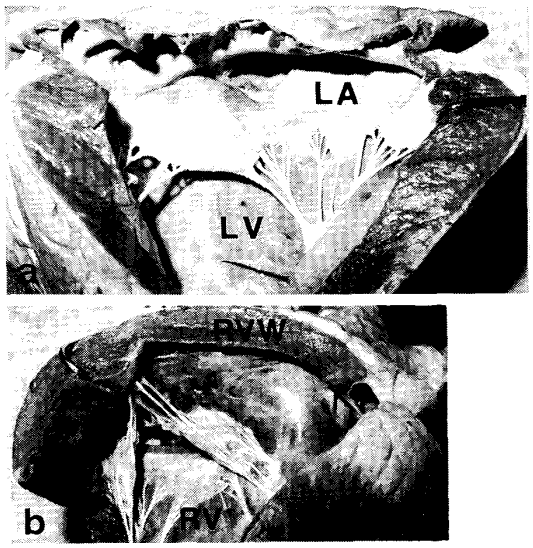

Fig. 4

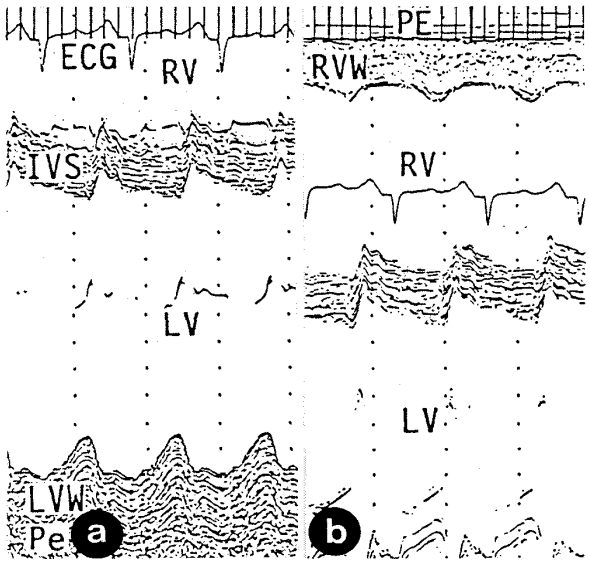

Fig. 2

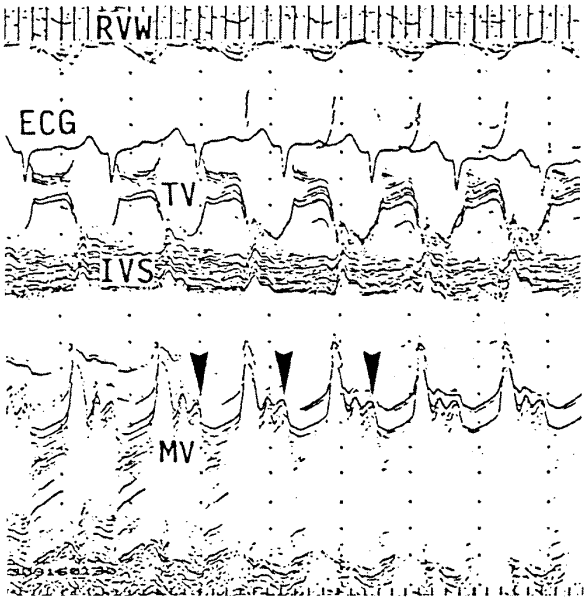

Fig. 3

PLATE II

Figs. 5–10 Case 2

Fig. 5 Two-dimensional echocardiogram of case 2 with chronic large abscesses of the pericardium obtained from the right 4th intercostal space. The right atrium and ventricle are not displayed with the normal transducer orientation due to severe compression by the large abscess(Ab). AbM : abscess membrane, L : lump. Other abbreviations as in the above figures.

Fig. 6 Left intercostal long-axis two-dimensional echocardiogram of case 2 demonstrating the diminished left ventricle(LV), thinned left ventricular wall(LVW) and pericardial abscess(Ab). The pleural effusion(Pl) is present. Other abbreviations as in the above figures.

Fig. 7 Echocardiograms obtained from the right 4th intercostal space in case 2. The right ventricle(RV) is compressed by the large abscess(Ab). The right half side of this figure represents the two-dimensional echocardiogram, and that of the left side displays the M-mode echocardiogram scanned at the level of the white line on the two-dimensional echocardiogram. The next Figures also follow Figure 7. Other abbreviations as in the above figures.

Fig. 8 M-mode echocardiogram of the mitral valve of case 2. Note the rounding of the descent of the mitral valve(MV) (B-B' step or B-shoulder, Arrow). The same labeling as for man is done in the mitral valve M-mode echocardiogram. Other abbreviations as in the above figures.

fig. 9 Echocardiograms after thoracocenteses in case 2 obtained from the same scanning position and orientation as those of Figure 7. The heart returns approximately to its position. The large abscess(Ab) compresses the right atrium and ventricle(RA, RV). Other abbreviations as in the above figures.

fig. 10 Necropsy specimen of case 2 with chronic large abscesses of the pericardium accompanied by cardial atrophy and its schema. L : left, R : right, Ao : aorta, portion within broken lines : abscess, shadowed portion : heart, meshed portion : lump. Bar is 10 cm.

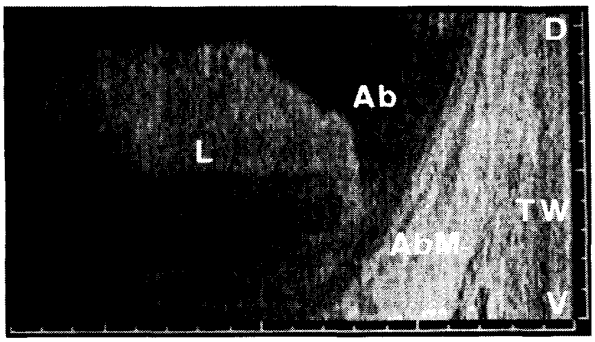

Fig. 5

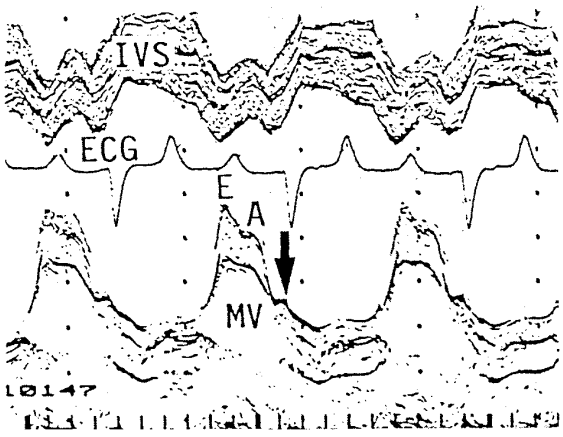

Fig. 8

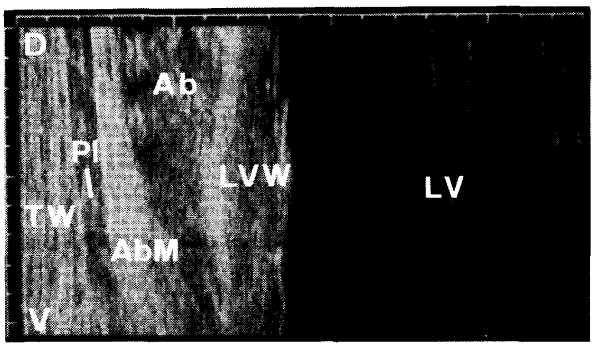

Fig. 6

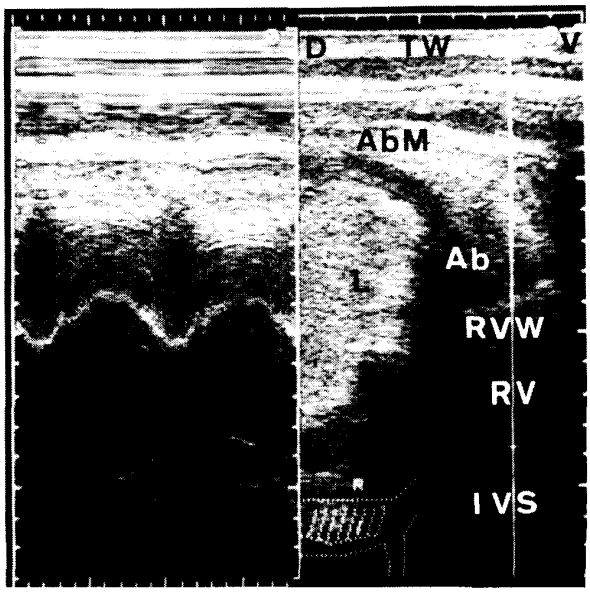

fig. 9

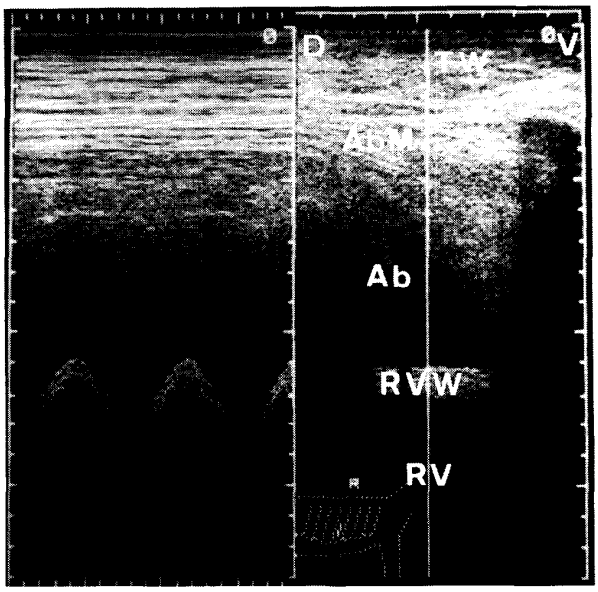

Fig. 7

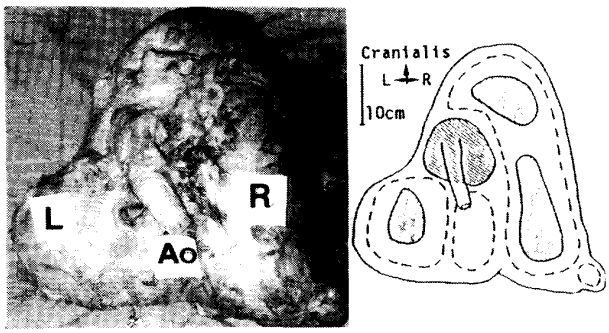

fig. 10

PLATE III

Figs. 11–13 Case 3

Fig. 11 Echocardiograms of case 3 with bovine leukemia obtained from left 4th intercostal space. The left ventricular wall(LVW) is markedly thickened. Other abbreviations as in the above figures.

Fig. 12 Ventricular M-mode echocardiogram of case 3. Each ventricular wall is notably thickened. One-centimeter-deep calibration dots are recorded every 0.5 seconds. Other abbreviations as in the above figures.

Fig. 13 Necropsy specimen of case 3. The left venticular wall(LVW) is remarkably thickened due to leukemic infiltration of the myocardium (arrow). Other abbreviations as in the above figures.

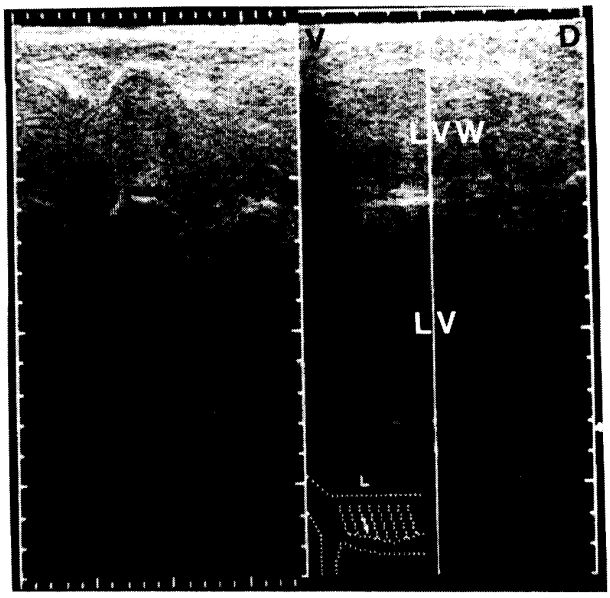

Fig. 11

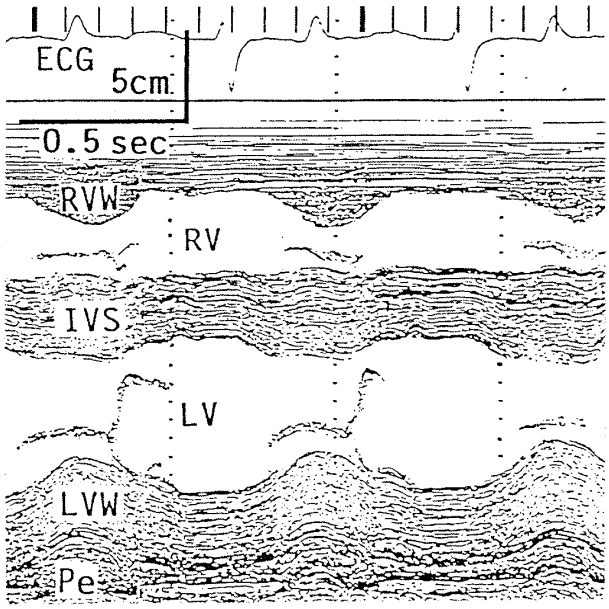

Fig. 12

Fig. 13