HISTOLOGICAL STUDIES ON THE OVARIES OF SOWS

V. HISTOLOGICAL OBSERVATIONS OF THE VARIOUS CORPORA LUTEA IN THE OVARIES OF SOWS WHICH HAVE DEFINITE HISTORIES OF PARTURITION

Tadayuki YAMASHITA

Department of Veterinary Anatomy,
Faculty of Veterinary Medicine,
Hokkaido University, Sapporo, Japan

(Received for publication, Dec. 15, 1961)

INTRODUCTION

Hitherto so far as the writer knows, there has been presented almost no description which attached importance to the subsequent fate of pregnant corpora lutea of sows. Obsolete pictures of the corpora lutea of pregnancy have not been differentiated from those of corpora lutea of non-pregnancy, and according to CORNER both corpora lutea have been designated as "hyaline bodies". However the subsequent fate of pregnant corpora lutea is thought certainly to have considerable significance for the judgment of ovarian function and also to be closely related to reproductive-physiological investigations. The present writer, therefore, paying special attention to this point of view, has already found his so-called "vascular bodies", and advocated that they are obsolete corpora lutea of pregnancy of sows. Fortunately materials from 3 sows were obtained in which the records of breeding and the number of repetitions of parturitions were known exactly. In this research the various corpora lutea found in the ovaries of these 3 animals were observed in detail for the purpose of substantiating the conception of the present writer's so-called "vascular bodies."

MATERIALS AND METHODS

Three sows used for this research are as indicated in table 1; each of the sows had repeated parturition 4 or 5 times in the past as shown in table 2.

After detailed macroscopical observations on the surfaces of ovaries, fresh materials were left in 10% formalin solution for about one week. After fixation, serial fragments of about 5.0 mm thick were cut off in transverse section which made a right angle with the long axis of the ovaries. As a routine matter, the specimens were embedded in paraffin, sectioned 6 to 8 μ in thickness, and treated with hematoxylin-eosin stain, VAN GIESON's stain, WEIGERT's stain and by GÖMÖRI's silver impregnation method. In some other paraffin sections Prussian-blue reaction was used for the detection of iron-containing pigments.

TABLE 1. *Materials Used for Investigation*

CASE NO.	NAME	BREEDING FARM	BREED	BIRTH DATE	AGE	PLACE SLAUGHTERED	DATE SLAUGHTERED
1	Unknown	Hokkaido agricultural experiment station	Middle White	Sept. 1951	5 years and 8 months	Sapporo slaughter house	Jun. 6, 1957
2	38 Hirugao	Shintoku livestock breeding farm	Middle White	Mar. 27, 1952	5 years and 9 months	Shintoku livestock breeding farm	Dec. 20, 1957
3	29 B-16	Shintoku livestock breeding farm	* Hampshire Fl	Apr. 1, 1954	3 years and 8 months	Shintoku livestock breeding farm	Dec. 20, 1957

*) Hampshire Fl was produced by a Hampshire parent which crossbred with Berkshire.

TABLE 2. *Careers of Parturition*

CASE NO.	DATE OF PARTURITION OF				
	1st	2nd	3rd	4th	5th
1	Apr. 5, 1955 (11)	Nov. 1955 (8)	Jun. 1956 (11)	Oct. 1956 (11)	
2	Jul. 12, 1953 (7)	Feb. 25, 1954 (13)	Jan. 16, 1955 (15)	Jan. 26, 1956 (9)	Jan. 25, 1957 (6)
3	Jan. 11, 1955 (6)	Aug. 23, 1955 (10)	Nov. 2, 1956 (13)	Sept. 19, 1957 (4)	

Parenthesized figure shows numbers of a litter.

TABLE 3. *Results of Macroscopical Observation*

STRUCTURES	CASE 1				CASE 2				CASE 3			
	Colors	Range of sizes (mm)	Number		Colors	Range of sizes (mm)	Number		Colors	Range of sizes (mm)	Number	
			Left ovary	Right ovary			Left ovary	Right ovary			Left ovary	Right ovary
Vesicular follicles	Light red	8.0~14.0	6	6	Light red	10.0~13.0	3	0	Grayish white	8.0~18.0	13	5
Corpora lutea	Light yellow	5.0~8.0	7	8	Light red	6.5~11.0	7	11				
					Dark yellow	4.2~ 4.6	2	0				
					Light yellow	2.3~ 5.2	17	0				
Yellow spots	Light brown	3.0~5.0	5	6	Light brown	2.1~ 3.6	6	15	Light red	1.0~ 3.0	Numerous	Numerous
	Dark brown	1.0~2.0	11	12								

FINDINGS

I. Macroscopical Findings of the Various Structures Found on Ovarian Surfaces

Large vesicular follicles (larger than 8.0 mm in diameter), corpora lutea and yellow spots found on the ovarian surfaces of 3 sows were observed macroscopically, and the results are summarized in table 3.

II. Histological Findings

1) Findings on large vesicular follicles

Large vesicular follicles of each case were observed histologically. They were referred to the histological types into which the writer has already classified normal ovarian follicles and atretic follicles in his previous papers; their growing stages and regressive stages were decided.

Case 1: Out of the 12 large light-red follicles found in the pair of ovaries of this case, 2 follicles in the left ovary and 3 follicles in the right ovary corresponded to type F. V. in H.-E. preparations, while 4 in the left and 3 in the right to type F. VI. In silver preparations all of the follicles showed the same finding as that of type AEf. II. Namely, these follicles were mature ones or ones just before ovulation.

Case 2: All of the 3 light-red follicles found only in the left ovary in this case showed the findings of type F. VI in H.-E. preparations and of type AEf. II in silver preparations; they were mature follicles just before rupture.

Case 3: Of the 18 large grayish-white follicles in this case, only one follicle in the left ovary and 2 in the right were normal; they showed the findings of type F. V. A few other follicles showed the findings at early stages of cystic atretic follicles; viz., each one follicle in each ovary belonged to type AF. I, while one follicle in the left ovary and 2 in the right to type AF. III. The remaining follicles, 7 in the left and 3 in the right, were very large, being a little less than 18.0 mm in diameter. They showed very different findings from those of cystic atretic follicles; namely, in the exceedingly large follicle cavity there appeared a few large epithelioid cells, which have been found in cystic atretic follicles at the middle stages, in addition to a few degenerated cells of the granulosa layer. A single layer of cuboidal epithelioid cells enveloped the follicle cavity completely. In these follicles, two layers of theca folliculi could not be differentiated. The thin follicle wall was composed mainly of spindle-shaped connective tissue cells which ran parallel to the follicle wall, and not even one epithelioid cell of theca interna was found there. In such follicles dilatation and hyperemia of blood vessels were not observed in the wall. In both ovaries of this case, moreover, numerous small follicles and moderate-sized ones which showed the same finding as those of above mentioned, very large, abnormal follicles appeared and pressed the stroma of the cortex strongly.

2) Findings on corpora lutea

Case 1: All of the 15 light-yellow corpora lutea found macroscopically were corpora lutea of non-pregnancy at the middle stage of regression; viz., they showed histological features similar to those of non-pregnant corpora lutea of type CL. VI in H.-E., of type AL. VI in silver impregnation preparations and of type EL. III in WEIGERT's stain preparations.

Case 2: In this case the 18 light-red corpora lutea resembled closely the non-pregnant

corpora lutea of type CL. I; the striking features were the appearance of several, large plica-like folds of the outer layer, which corresponded with the theca interna of mature follicles. In the corpora lutea of this case, however, blood capillaries did not sprout into the inner layer, which corresponded with the granulosa layer of mature follicles, but many extravascular erythrocytes were seen near the demarcation between the inner and the outer layer.
All of the dark-yellow and the light-yellow corpora lutea found only in the left ovary fell into type CL. VIII which was corpora lutea of non-pregnancy at the last stage of regression.

Case 3: Although corpora lutea were not observed on the ovarian surfaces by macroscopical observation, the youngest corpora lutea with a freshly ruptured wound were found 6 in the left ovary and 2 in the right ovary in histological examinations. They were 3.1 to 8.0 mm in diameter. In these corpora the structure of the wall was almost like that of the corpora lutea of case 2. In these corpora, however, there were found neither the penetration of blood capillaries from the outer layer into the inner layer nor extravascular erythrocytes near the demarcation between the inner and the outer layer or in the inner layer.

3) Classification of arterioles and intercellular substances

As a result of the observations of old corpora lutea, two new types of arterioles with sclerotic changes were added to the 14 types, which have already been classified by the present writer.

Type 15: The arterioles of this type were about 20 to 50μ in diameter. There was found slight hyperplasia in the inner coat. The internal elastic membrane was very thin or inconspicuous. The intermediate coat was found as a band of pale blue, finely granulated substances.

Type 16: The arterioles were about 50 to 200 μ in diameter. The hyperplastic swelling of the inner coat was more conspicuous than that of type 14, and there were minute elastic fibers in the thickened subendothelial tissue. In the intermediate coat elastosis was very conspicuous, and masses of homogeneous substances which stained very deeply and dirtily fused with each other to show stratified structures.

In obsolete corpora lutea, moreover, intercellular substances which were stained deeply with WEIGERT's resorcin-fuchsin were found. They fell into 3 types as follows:

Type a: The intercellular substances of this type were lightly or deeply stained; waving fibroid structures were found in the hyaline substances of obsolete corpora lutea.

Type b: This type was ring-like structures formed of deeply stained, finely granulated substances.

Type c: This type was very irregularly shaped masses composed of dirtily stained, finely granulated substances.

4) Findings on obsolete corpora lutea

Yellow spots found on the ovarian surfaces macroscopically and old corpora lutea found in the deeper layers of the ovarian cortex in section preparations were divided into "hyaline bodies" (H) and the present writer's so-called "vascular bodies" (G).

Hyaline bodies and vascular bodies which contained no pigment cells or relatively a few, which contained brownish-yellow, various-sized, round pigment granules which gave strong reaction to Prussian-blue reaction, were considered to be normal and designated respectively as "normal hyaline bodies" (HN) and "normal vascular bodies" (GN). However hyaline bodies

and vascular bodies which contained extremely numerous pigment cells were designated respectively as "brown hyaline bodies" (HB) and "brown vascular bodies" (GB).

a) Findings on hyaline bodies

In case 1, the hyaline bodies were divided into two large groups, normal hyaline bodies and brown ones; further the two groups were subdivided respectively into 6 types. In case 2 and case 3, on the other hand, all of the hyaline bodies were included in the category of normal hyaline bodies, because there was no hyaline body with extremely numerous pigment cells in the central fibrous core. In case 2 the normal hyaline bodies also were divided into the same 6 types as in case 1. In case 3, however, the normal hyaline bodies were divided into 5 types, for in this case the hyaline bodies which corresponded to type HN. I of case 1 or case 2 were not observed at all.

The total number and the range of the size in each type of hyaline bodies found in the ovaries of 3 cases are indicated in table 4.

TABLE 4. *Total Number and Range of Sizes in Each Type of Hyaline Bodies Found in 3 Cases*

TYPE		CASE 1		CASE 2		CASE 3	
		Total Nos.	Range of sizes	Total Nos.	Range of sizes	Total Nos.	Range of sizes
HN	I	18	2.5 ~4.0 mm	31	2.0~3.5 mm	0	
	II	10	0.8 ~2.0 mm	35	0.8~2.0 mm	19	0.7~1.6 mm
	III	5	0.5 ~1.3 mm	43	0.5~1.0 mm	10	0.4~2.9 mm
	IV	4	380~570 μ	26		3	
	V	16		37		18	
	VI	8		54		40	
HB	I	8	3.5 ~5.0 mm				
	II	30	0.8 ~2.3 mm				
	III	19	0.5 ~1.5 mm				
	IV	10	400~600 μ				
	V	16					
	VI	3					

In the normal hyaline bodies the histological findings of 6 types which are common to 3 cases are as follows:

Type HN. I: The hyaline bodies of this type were almost round in shape. In H.-E. preparations they showed features similar to those of type CL. IX which represented corpora lutea of non-pregnancy at the last stage of regression. In silver preparations they coincided well with type AL. VIII and in WEIGERT preparations with type EL. V. Moreover in VAN GIESON preparations homogeneous structures of interstitial tissues stained a rose color with fuchsin. In this stage of regression the central fibrous core had already shown hyaline degeneration, and no pigment cell or only a few were contained there. To sum up, this type showed typical characteristics of so-called "hyaline bodies."

Type HN. II: Most instances of this type which were situated among follicles and corpora lutea were rhombic in shape. In this type the hyaline substances, which were stained red in H.-E. preparations and reddish-yellow in VAN GIESON preparations, showed very thick, uniformly homogeneous, fibrous structures, among or with which a few intercellular substances of type "a" mingled. Moreover in case 2 and case 3 numerous pigment cells with yellow, brilliant, fine granules which were negative to Prussian-blue reaction, and with various-sized, rounded vacuoles, were found throughout the hyaline substances. Although the arterioles of types 9, 11 and 12 in the whole wall of the hyaline bodies decreased to become less than those of type HN. I, the arterioles of type 15 appeared newly. In the peripheral parts of the hyaline bodies the arterioles of type 14 appeared in addition to instances of types 6 and 9.

Type HN. III: These hyaline bodies were slightly smaller than those of type HN. II and were long triangular or semilunar in shape. The boundary between the hyaline bodies and the surrounding tissues was yet clear-cut like the preceding two types. Findings of the hyaline degeneration in the interstitial tissues were similar to those of type HN. II. But in this type a few collagenous fibers penetrated from the surrounding tissues into the deeper layers of the hyaline bodies. Moreover throughout the entire wall of the hyaline bodies the intercellular substances of type "a" were much greater than in the case of type HN. II. In this type of case 2 and case 3, numerous pigment cells with yellow granules were found throughout the hyaline substances.

Type HN. IV: This type was found in small, triangular-shaped, scar-like tissues which were surrounded by a few arterioles of types 8, 14 and 16. The inner part surrounded with these sclerotic arterioles was composed of the same fibrous connective tissue as that of the surrounding ovarian stroma, without any hyaline substance being contained. Moreover the peripheral parts of this tissue were enveloped by many intercellular substances of type "c" and a few of type "b". In this type in case 2 and case 3 pigment cells with yellow granules were entirely lacking.

Type HN. V. This type was represented by small, irregular-formed scar-like tissues which were very difficult to find in H.-E. preparations. In WEIGERT preparations, however, there appeared a few, heavily sclerotic arterioles of types 14 and 16 in the peripheral parts, while between and around these arterioles a few intercellular substance of types "b" and "c" were observed.

Type HN. VI: This type could be found only in WEIGERT preparations; some heavily sclerotic arterioles and a few intercellular substances of types "b" and "c" appeared scattered in the connective tissues of ovarian stroma.

The main histological features of "brown hyaline bodies" (HB), which were observed only in case corresponded to those of normal hyaline bodies as follows: HB. I to HN. I; HB. II to HN. II; HB. III to HN. III; HB. IV to HN. IV; HB. V to HN. V and HB. VI to HN. VI. However, within the central fibrous core which was found in types HB. I and II, extremely numerous brownish-yellow pigment cells were contained. Among the hyaline substances in type HB. III and among the connective tissue cells in types HB. IV to VI which had already shown the scar-like tissues, a few brownish-yellow pigment cells were always scattered. Moreover, in every type of the brown hyaline bodies, heavily sclerotic arterioles and intercellular substances were more numerous in comparison with what is found in normal hyaline bodies.

b) Findings on vascular bodies

In case 1, vascular bodies were also classified into two large groups; "normal vascular bodies" (GN) which contained no or a few brownish-yellow pigment cells and "brown ones" (GB) which contained numerous pigment cells. In case 2 and case 3, on the other hand, there was only one group, "normal vascular bodies."

The total number and the range of the size in each type of vascular bodies found in the present 3 cases are indicated in table 5.

TABLE 5. *Total Number and Range of Sizes in Each Type of Vascular Bodies Found in 3 Cases*

TYPE		CASE 1		CASE 2		CASE 3	
		Total Nos.	Range of sizes	Total Nos.	Range of sizes	Total Nos.	Range of sizes
GN	I	3	0.8 ~1.9 mm	8	1.2~2.1 mm	16	1.4 ~2.3 mm
	II	4	0.5 ~1.2 mm	12	0.6~1.2 mm	8	0.9 ~1.5 mm
	III	9	300~600 μ	17		4	0.6 ~1.1 mm
	IV	8				5	430~500 μ
GB	I	15	1.0 ~2.0 mm				
	II	11	0.7 ~1.5 mm				
	III	8	350~700 μ				
	IV	10					

In case 1 normal vascular bodies which are classified into 4 types are as follows:

Type GN. I: The vascular bodies of this type were situated in slightly deep portions from ovarian surfaces, and corresponded to those of type g. III in H.-E., of type Ag. III in GÖMÖRI, and of type Eg. III in WEIGERT preparations, which had already been reported by the present writer. These vascular bodies were a large, almost spherical mass composed mainly of heavily sclerotic arterioles, above all those of type 8.

Type GN. II: This type was found in the deep portions of ovarians of ovarian cortex as a mass of heavily sclerotic arterioles and intercellular substances. However various sclerotic arterioles, especially of type 8 decreased in comparison with the picture in type GN. I. On the contrary, many intercellular substances of types "b" and "c" appeared among these sclerotic arterioles. Hyaline substances which were found in the next preceding type were completely lacking in this type.

Type GN. III: Comprising this type there were found a few, large, heavily sclerotic arterioles, especially of type 14 at the peripheral parts of the vascular bodies. At the same time, in the deeper parts, where the tissue had already been organized completely, there were found a few, small arterioles of type 14. Extremely numerous intercellular substances of types "b" and "c" appeared at the peripheral parts of the bodies.

Type GN. IV: This type was found in the deepst parts of the ovarian cortex as a small mass which was composed only of several arterioles of types 14 and and 16, of a few intercellular substances of type "c". Moreover, among these sclerotic arterioles a few normal, small

arterioles were observed.

In case 2, findings with respect to normal vascular bodies of 3 types are as follows:

Type GN. I: This type was similar to type GN. I of case 1, and was found as a mass of sclerotic arterioles which were mainly ones of type 8. In this type, however, relatively numerous pigment cells with fine yellow granules, which were negative to Prussian-blue reaction, were found among the arterioles.

Type GN. II: The vascular bodies were like those of type GN. II of case 1. In this type, however, intercellular substances of types "b" and "c" were more numerous than those of type GN. II of case 1. Moreover, even arterioles of type 16 appeared at the peripheral parts of such vascular bodies, while those of type 14 appeared at the deeper parts.

Type GN. III: This type was found as a mass of arterioles of types 14 and 16. Arterioles of type 8 were rarely found. Moreover, among such arterioles many intercellular substances, especially of type "b", were observed.

In case 3, the findings of normal vascualr bodies classified into 4 types are as follows:

Type GN. I: In this type there was found a large quantity of hyaline substances, which stained reddish-yellow with VAN GIESON staining, among numerous arterioles of type 8. Arterioles found in the hyaline substances were those of types 12 and 13 with hypertrophied inner coat and hyalinized intermediate coat. That is to say, the vascular bodies of this type exhibited characters which were situated between type g. II and type g. III, which had already reported by the present writer.

Type GN. II: The vascular bodies of this type were similar to those of type GN. I found in case 1. However intercellular substances of type "c" were more numerous in comparison with instances of type GN. I of case 1.

Type GN. III: This type was found as a mass of arterioles of type 8, among which hyaline substances were not found. In this type extremely numerous intercellular substances of type "c" were observed among these arterioles.

Type GN. IV: The vascular bodies of this type were a mass composed mainly of arterioles of types 14 and 16. Extremely numerous intercellular substances of types "b" and "c" were found among these arterioles.

Brown vascular bodies were differentiated from normal ones only in case 1. The main pictures of brown vascular bodies, which were subdivided into the same 4 types as in normal vascular bodies, corresponded to those of the normal vascular bodies as follows: GB. I to GN. I; GB. II to GN. II; GB. III to GN. III and GB. IV to GN. IV. In hyaline substances of type GB. I or among the heavily sclerotic arterioles of types GB. II to IV, however, the yellowish-brown pigment cells, which were positive to Prussian-blue reaction, were always more numerous than those in every type of normal vascular bodies.

DISCUSSION

For the purpose of confirming the conception of the present writer's so-called "vascular bodies" which have been considered to be old corpora lutea of pregnancy of sows, investigation was conducted of 3 pairs of ovaries obtained from 3 sows which kept records of breeding and of history of parturitions. Use was made of various histological methods.

One should be able to decide a certain phase of ovarian cycles by means of histological observations of a group of the largest ovarian follicles or of corpora lutea derived from the latest ovulation.

In the ovaries of case 1, all of light-red follicles were mature follicles or ones just before rupture. CORNER reported that corpora lutea of non-pregnancy at the next ovulation in sows shrank up to about 6.0 mm in size and showed yellow tone. The macroscopical findings of light-yellow corpora lutea of this case resemble well those of corpora lutea observed by CORNER. Moreover, such corpora lutea were found to be ones of non-pregnancy at the middle stage of regression in this histological observation. Accordingly, the light-yellow corpora lutea of this case are recognized to be ones derived from the latest ovulation. That is to say, both ovaries of case 1 show the features of the last stage of follicle phase.

In case 2, light-red corpora lutea corresponded well with the "freshly ruptured follicles" described by CORNER in sows and with corpora lutea at the "proliferation stage" of MEYER in women. The wall of these corpora lutea maintained almost the same structures as those of mature follicles just before ovulation, although the outer layers, which originated in the theca interna of mature follicles, protruded conspicuously as several, large plica-like folds owing to the contraction of the whole wall concomitant with the ovulation. Blood capillapies still did not penetrate from the outer layers into the inner layers which are derived from the granulosa layer of mature follicles. Therefore it is obvious that light-red mature follicles found in this case have not long been in rupture. Namely, the ovaries of this case are recognized to be at the stage of proliferation in cropus luteum phase. On the other hand, all of dark-yellow corpora lutea and light-yellow ones showed the same histological findings; they were thought to have originated from corpora lutea in the next previous ovulation. They showed a more advanced stage of regression than those of light-yellow corpora lutea in case 1; i.e., the last stage of regression.

Among 18 large grayish-white follicles found in case 3, only three of them were mature follicles, whilst seven were cystic atretic follicles at the early stage. However, ten remnant follicles corresponded completely to "ovarian follicle cysts" reported by many investigators in various animals. In this case, in addition to such follicle cysts, numerous small and middle-sized follicle cysts were found; they occupied the greater part of ovarian cortex. Therefore the ovaries of this case by histological examinations are recognized to be "cystic ovaries." In case 3, on the other hand, there were found eight young corpora lutea by histological examinations, which were overlooked in the macroscopical observations. Although these corpora lutea were similar to those of case 2, in these corpora even extravascular erythrocytes were not found near the boundary between the inner and outer layers. Therefore these corpora are considered to be younger than those of case 2.

In case 3, it is especially noteworthy that mature follicles and the very young corpora lutea just after ovulation are found in spite of existence of an ovarian cyst.

Of the arterioles of two types which were newly distinguished in old corpora lutea in course of this observation, the writer's arterioles of type 15 were found scattered among the hyaline substances only in the hyaline bodies of types HN. II, HB. II, HN. III and HB. III. On the other hand, in the hyaline bodies of types HN. I and HB. I, which were considered to be hyaline bodies at a slightly earlier stage of regression than those of types HN. II or HB. II, only arterioles of types 9, 10, 12 and 13 appeared throughout the whole wall, while arterioles of type 15 did not appear. Therefore it is thought that arterioles of type 15 are formed by the accumulation of elastoid in arterioles of types 12 or 13 with the hypertrophic swelling in the inner coat and with the slightly or heavily hyaline swelling on the intermediate and outer coats.

The arterioles of type 16, which appeared especially in the vascular bodies, are considered to show more advanced sclerotic changes than do those of type 14. The reason is that in the arterioles of type 16 the hypertrophic swelling of the inner coat and the accumlation of the elastoid in the intermediate and outer coats are more remarkable than those in arterioles of type 14.

Intercellular substances found in hyaline bodies and vascular bodies were classified into 3 types: "a", "b" and "c". These substances, especially types "b" and "c", are closely similar to "elastoid tissues" already well known and to substances of "elastolipoidosis" which recently was discovered in corpora albicantia of women by ONO. Therefore it is thought that each type of these substances is produced by the degeneration of elastic fibers in blood vessels, especially in arterioles.

Among the yellow spots found on the ovarian surfaces by macroscopical observations and among the old corpora lutea found in the deeper layers of the ovarian cortex by histological examinations, the structures which showed considerable hyaline degeneration of the interstitial tissues and the structures which were considered to have originated from them were placed in one group and designated as "normal hyaline bodies." Moreover, normal hyaline bodies were classified into 6 types in case 1 and case 2, and into 5 types in case 3. However, hyaline bodies with extremely numerous pigment cells in the central fibrous core were found only in case 1, designated as "brown hyaline bodies", and classified into 6 types.

These pigment cells contained fine, yellowish-brown granules which gave a strong positive reaction for iron. Accordingly, it is obvious that these pigments are hemosiderin formed by the breaking down of hemoglobin in erythrocytes.

The brown hyaline bodies should be considered to be produced through the following process; freshly ruptured corpora lutea, whose central cavity was filled with effused blood at the same time with ovulation, become hematocyst-like. In

such corpora, lutein cell layers develop only in the peripheral parts of the corpora lutea. With the regression of the corpora, numerous histiocytes wander into the central cavity on account of the taking in of blood cells. Such histiocytes remain in corpora for a long time until the last stage of regression.

In the brown hyaline bodies, moreover, there were always found more arterioles with various sclerotic changes in comparison with those of normal hyaline bodies. Such findings also are considered to be sclerotic features of the arterioles which penetrated conspicuously into the walls of corpora lutea on account of the organization of the large, previously non-organized central cavity.

Pigment cells, which were found only in types HN. II and III of cases 2 and 3 with, fine, yellow, brilliant granules and various-sized, round vacuoles, are closely like the remant "theca lutein cells" described by CORNER, who found them in regressing corpora lutea. However the present writer cannot support the finding of CORNER on the basis of the findings in the present research.

Brown hyaline bodies resemble well the normal ones macroscopically and histologically, except for a large amount of bleeding which has occurred in the central cavity and existence of more arterioles than those of normal hyaline bodies. Accordingly in case 1 the same type of normal hyaline bodies and brown ones are thought to be derived from corpora lutea of the same generation.

Correlations of hyaline bodies with period of non-pregnancy will be discussed in the following paragraphs.

In both ovaries of case 1 there were found 12 normal mature follicles or 15 light-yellow corpora lutea corresponding to one ovulation in the past; this case was delivered of 8 to 11 young pigs in each of 4 parturitions in the past. In this case, therefore, it is presumed that about 15 ova were released from both ovaries at one heat. Accordingly, it is considered that the hyaline bodies of six types contain respectively obsolete corpora lutea which correspond to continual sexual cycles as follows: to about 2 sexual cycles in type I whose total numbered 26; about 3 in type II whose total numbered 40; about 2 in type III whose total numbered 24; about 1 in type IV whose total numbered 14; about 2 to 3 in type V whose total numbered 32, and about 1 in type VI whose total numbered 11. In this case it should be considered that the total of types I to II includes old corpora lutea of non-pregnancy which correspond with about 7 sexual cycles repeated during the fourth period of non-pregnancy, because in this case the fourth period of non-pregnancy, which extended from date of fourth delivery until date slaughtered, was for about 6 months, even if a month of lactation was considered. If ovarian functions were normal during this period, 8 to 9 sexual cycles should have been repeated. On the other hand, types IV to VI were respectively scar-like tissues organized clearly, and there was much difference in the findings between type III and type IV. Therefore it is

concluded that these three types are composed of old corpora lutea of non-pregnancy which correspond with about 4 sexual cycles repeated during the third period of non-pregnancy.

In case 2, supposing about 15 ova were released from both ovaries at one heat, it is thought that types I to III contain respectively old corpora lutea of non-pregnancy which correspond to 2 to 3 sexual cycles. In this case it is supposed that the sixth period of non-pregnancy after the latest weaning until slaughter continued about 10 months. Accordingly, during this period about 14 sexual cycles must have been repeated. However, the whole number of hyaline bodies from type I to type III contain only old corpora lutea of non-pregnancy which correspond with about 8 sexual cycles repeated during the sixth period of non-pregnancy, whilst types IV, V and VI were the same scar-like tissues as those of case 1. Therefore the present writer wishes it considered that these three types contain old corpora lutea of non-pregnancy for the fifth period of non-pregnancy. Accordingly, in the sixth period of non-pregnancy old corpora lutea which correspond to several sexual cycles are lacking. This finding may due to the fact that many other old corpora lutea which correspond with types I to III have been overlooked, because the present research was carried out in single section preparations.

It is not considered that in case 3 normal sexual cycles have been repeated during the fifth period of non-pregnancy, because both ovaries of this case had ovarian follicle cysts. Namely, it is a good evidence that hyaline bodies which correspond to type I were absolutely not found. Therefore it is considered that types II and III belong to old corpora lutea for the fourth period of non-pregnancy, and that types IV to VI belong to old corpora lutea for the third period of non-pregnancy.

Among the yellow spots found on the ovarian surfaces in macroscopical observation and among the old corpora lutea found in the deeper layers of ovarian cortex by histological examination, the structures which were found as a mass of heavily sclerotic blood vessels, especially of arterioles, and the scar-tissues which were considered to have originated from them, were all placed in one group and designated as "normal vascular bodies". These normal vascular bodies, moreover, were classified into four types in cases 1 and 3, and into three types in case 2. In case 1 vascular bodies with extremely numerous, brownish-yellow pigment cells were ovserved; they were designated as "brown vascular bodies" and further classified into 4 types.

It is considered that brown vascular bodies also were formed through the same processes as those in the case of brown hyaline bodies. From this point of view, it is thought that both normal vascular bodies and brown ones of case 1 originated from corpora lutea of the same generation in every type.

Correlation of vascular bodies with history of parturitions will be discussed in

the follows:

In case 1, total numbers of normal vascular bodies and brown ones in each type are 18 in type I, 15 in type II, 17 in type III and 18 in type IV. In case 2, vascular bodies are 8 in type I, 12 in type II and 17 in type III. In case 3, vascular bodies are 16 in type I, 8 in type II, 4 in type III and 5 in type IV. Namely, the numbers of vascular bodies in each type of these 3 cases are almost equal to the numbers of ova released in one ovulation, except for type I of case 2 and types II, III and IV of case 3.

Supposing in case 1 that the vascular bodies of types I, II, III and IV originate from corpora lutea of pregnancy which correspond respectively to the fourth, third, second and first deliveries, and supposing in cases 2 and 3 also that correlations of vascular bodies with history of parturitions are as case 1, the number per litter is less than the numbers of vascular bodies in each type of the three cases, except for types II and III of case 3. Such relations correspond well with KUDO's description, in which numbers of ova released from ovaries do not always correspond to the number of a litter, and the latter tends to be less than the former. At the same time in case 3, numbers of a litter in the second and third deliveries were larger than numbers of vascular bodies of types III and II, respectively. It must be considered that other vascular bodies corresponding to types II and III were overlooked, because the present research was done in single section preparations.

Regarding correlations of vascular bodies with history of deliveries, in case 1 the vascular bodies of type II yielded histoligical findings similar relatively to those of type I. Therefore, it is thought that both types derived from corpora lutea of pregnancy formed one after the other. In fact, this case underwent the fourth pregnancy shortly after the third delivery. Accordingly the vascular bodies of type I are considered to be related to the fourth delivery and those of type II to the third delivery. In vascular bodies of type III, sclerotic changes of arterioles were more conspicuous in comparison with those of type II. Therefore, these vascular bodies are thought to be related to a pregnancy of a long time previously. Namely, it is probable that these bodies originated from corpora lutea of pregnancy corresponding to the second pregnancy. The vascular bodies of type IV were well organized scar-like tissues. Therefore these bodies are considered to be derived from the oldest corpora lutea of pregnancy in this case, namely, from ones corresponding to the first pregnancy.

If in case 2 also the correlations of vascular bodies with history of deliveries are considered to be similar to the correlation of case 1, the vascular bodies of each type in this case are thought to be derived respectively from corpora lutea of pregnancy corresponding to the following: type I to the fifth pregnancy, type II to the fourth, and type III to the third pregnancy. Moreover the oldest corpora

lutea of pregnancy corresponding to the first and the second pregnancy should be considered to have already been organized completely and to have disappeared.

Thus, the vascular bodies of each type in case 3 also are thought to be derived respectively from pregnant corpora lutea corresponding to the following: type I to the fourth pregnancy, type II to the third, type III to the second and type IV to the first pregnancy.

The term during which pregnant corpora lutea are organized completely and disappear, viz., the surviving term of vascular bodies, is presumed to vary according to ovarian functions in each individual or influences of cystic follicles as found in case 3. In this research the present writer recognized in case 1 that the vascular bodies remained for about two years, and in case 2 and case 3 for about three years.

SUMMARY

The results may be summarized as follows:

1. Light-red corpora lutea which were found in case 2 in macroscopical observations and young corpora lutea which were observed in case 3 by histological examinations corresponded well to the "freshly ruptured follicles" of CORNER and were definitely stated to be corpora lutea at a earliest proliferation stage.

2. In this observation of obsolete corpora lutea of three sows, arterioles of two types were newly added to ones of 14 types, which had already been classified by the present writer.

3. In obsolete corpora lutea the intercellular substances which stained deeply to resorsin-fuchsin were divided into three types.

4. Brown hyaline bodies and brown vascular bodies were considered to have originated from corpora lutea, into the central cavity of which conspicuous hemorrhage had occurred directly after ovulation.

5. In the present research it could be definitely stated for the first time on the basis of the collations with the history of parturitions that the present writer's so-called "vascular bodies" were obsolete corpora lutea of pregnancy in sows.

6. It was presumed that pregnant corpora lutea of sows were organized completely and disappeared within 3 years at least.

The writer wishes to express his gratitude to Prof. K. TAKAHATA of the Department of Veterinary Anatomy for his kind direction and reviews. Further he would like to express cordial thanks to the members of the staff of the Department who assisted in this study.

REFERENCES

1) CORNER, G. W. (1919): *Amer. J. Anat.*, **26**, 117
2) KUDO, N. (1949): *Jap. J. vet. Sic.*, **11**, 90 (in Japanese)
3) MEYER, R. (1911): *Arch. Gynaek.*, **93**, 354
4) ONO, Y. (1955): *Nichidai Igk. Z.*, **14**, 1343 (in Japanese)
5) YAMASHITA, T. (1959): *Jap. J. vet. Res.*, **7**, 117
6) YAMASHITA, T. (1960): *Ibid.*, **8**, 107
7) YAMASHITA, T. (1960): *Ibid.*, **8**, 221
8) YAMASHITA, T. (1960): *Res. Bull. Obihiro Zootech. Univ.*, Series I, **3**, 125 (in Japanese)
9) YAMASHITA, T. (1961): *Jap. J. vet. Res.*, **9**, 31

EXPLANATION OF PLATES

PLATE I.

Fig. 1. Mature follicle just before rupture found in case 1, H.-E. stain, × 300
Fig. 2. Same material as fig. 1, GÖMÖRI's stain, × 300
Fig. 3. Mature follicle found in case 3, H.-E. stain, × 300
Fig. 4. Various-sized cystic follicles found in case 3, H.-E. stain, × 70
Fig. 5. Corpus luteum of non-pregnancy at the middle stage of regression, which was found in case 1, H.-E. stain, × 70
Fig. 6. Very young corpus luteum of non-pregnancy which was found in case 2, H.-E. stain, × 70
Fig. 7. Corpus luteum of non-pregnancy at the last stage of regression, which was found in case 2, H.-E. stain, × 70
Fig. 8. Very young corpus luteum of non-pregnancy which was found in case 3, H.-E. stain, × 70

PLATE II.

Fig. 9. Arteriole of type 15, WEIGERT's stain, × 370
Fig. 10. Arteriole of type 16, WEIGERT's stain, × 370
Fig. 11. Intercellular substances of type "a", WEIGERT's stain, × 370
Fig. 12. Intercellular substances of type "b", WEIGERT's stain, × 370
Fig. 13. Intercellular substances of type "c", WEIGERT's stain, × 370
Fig. 14. Hyaline body of type HN. I found in case 1, H.-E. stain, X 70
Fig. 15. Hyaline body of type HN. II found in case 1, H.-E. stain, × 70
Fig. 16. Same material as fig. 15, WEIGERT's stain, × 70

PLATE III. Various Types of Normal Hyaline Bodies

Fig. 17. Type HN. III found in case 1, H.-E. stain, × 70
Fig. 18. Same material as fig. 17, WEIGERT's stain, × 70
Fig. 19. Type HN. IV found in case 1, WEIGERT's stain, × 70
Fig. 20. Type HN. V found in case 1, WEIGERT's stain, × 70
Fig. 21. Type HN. VI found in case 1, WEIGERT's stain, × 70
Fig. 22. Type HN. I found in case 2, H.-E. stain, × 70
Fig. 23. Type HN. II found in case 2, WEIGERT's stain, × 70
Fig. 24. Type HN. III found in case 2, WEIGERT's stain, × 70

PLATE IV. Various Types of Normal Hyaline Bodies, WEIGERT's stain, × 70

Fig. 25. Type HN. IV found in case 2
Fig. 26. Type HN. V found in case 2
Fig. 27. Type HN. VI found in case 2
Fig. 28. Type HN. II found in case 3
Fig. 29. Type HN. III found in case 3
Fig. 30. Type HN. IV found in case 3
Fig. 31. Type HN. V found in case 3

Fig. 32. Type HN. VI found in case 3

PLATE V. Various Types of Brown Hyaline Bodies and of Normal Vascular Bodies

Fig. 33. Type HB. I found in case 1, H.-E. stain, × 70
Fig. 34. Type HB. VI found in case 1, WEIGERT's stain, × 70
Fig. 35. Type GN. I found in case 1, WEIGERT's stain, × 60
Fig. 36. Type GN. II found in case 1, WEIGERT's stain, × 70
Fig. 37. Type GN. III found in case 1, WEIGERT's stain, × 70
Fig. 38. Type GN. IV found in case 1, WEIGERT's stain, × 70

PLATE VI. Various Types of Vascular Bodies, WEIGERT's stain

Fig. 39. Type GN. I found in case 2, × 60
Fig. 40. Type GN. II found in case 2, × 70
Fig. 41. Type GN. III found in case 2, × 70
Fig. 42. Type GN. I found in case 3, × 70
Fig. 43. Type GN. II found in case 3, × 70
Fig. 44. Type GN. III found in case 3, × 70
Fig. 45. Type GN. IV found in case 3, × 70
Fig. 46. Type GB. I found in case 1, × 70

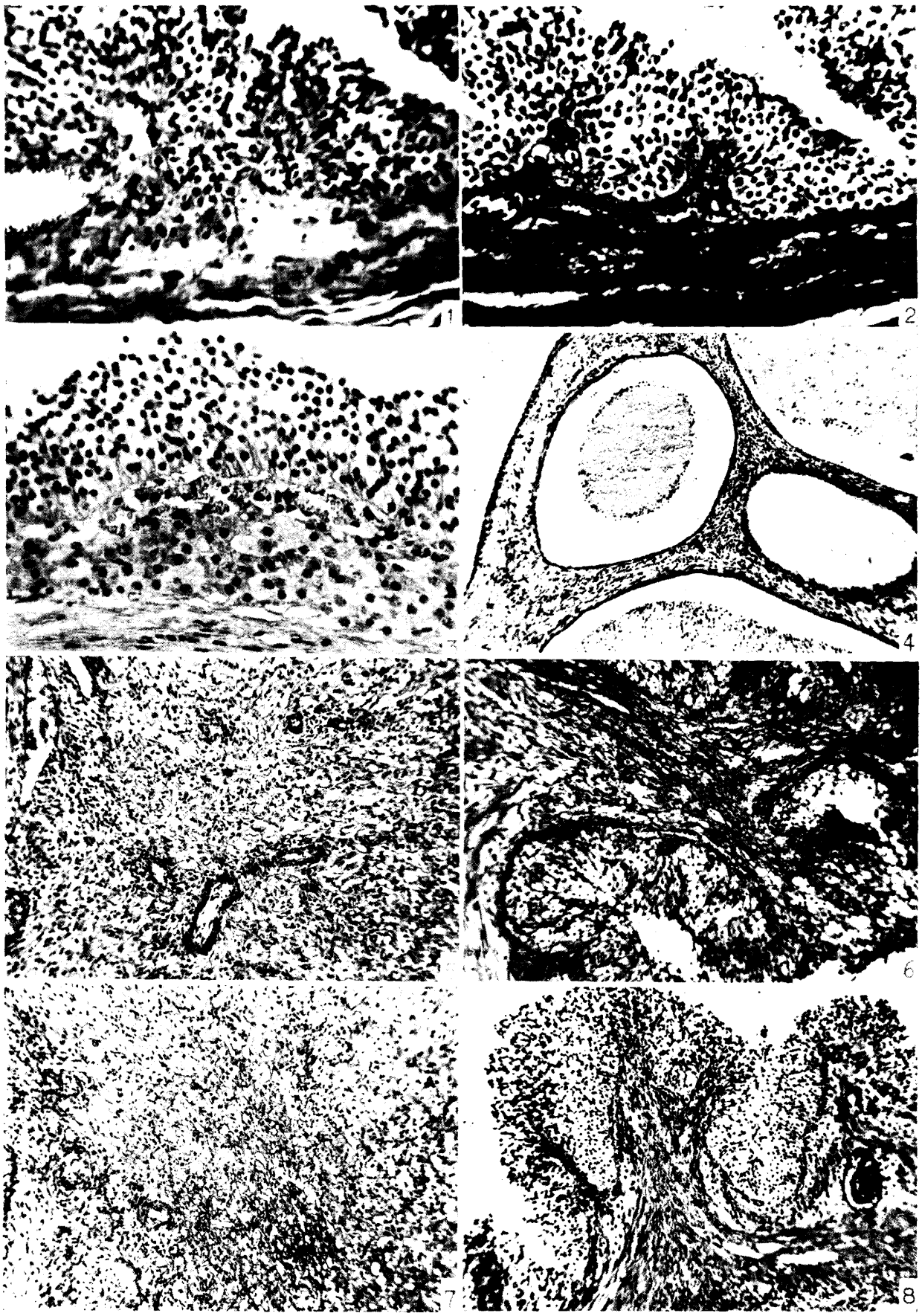
1
2
4
6
7
8

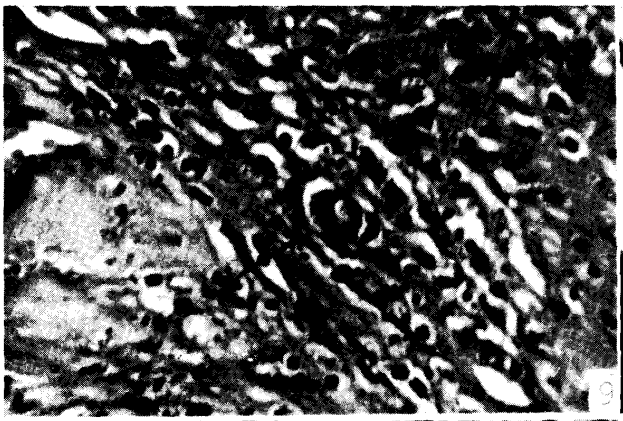
9

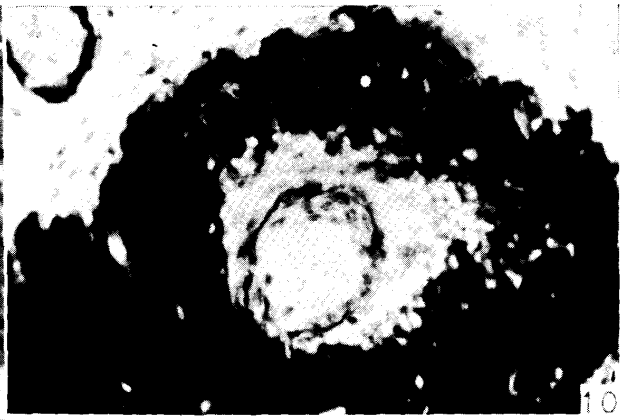
10

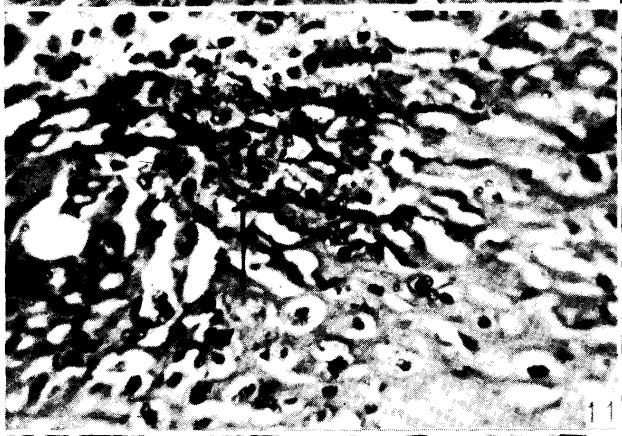
11

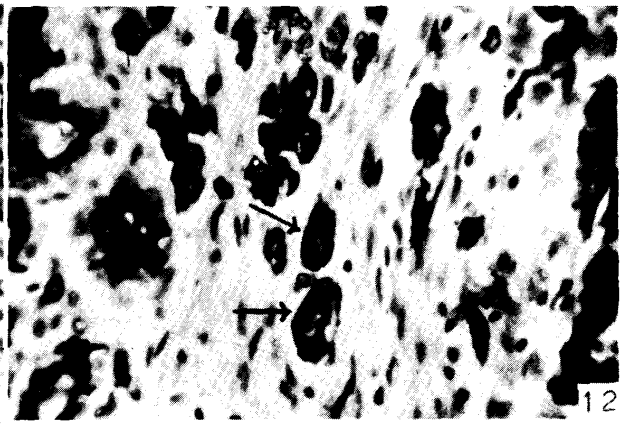
12


13

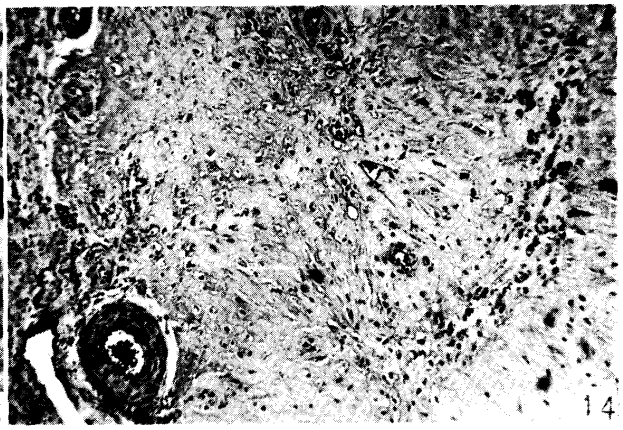
14


15

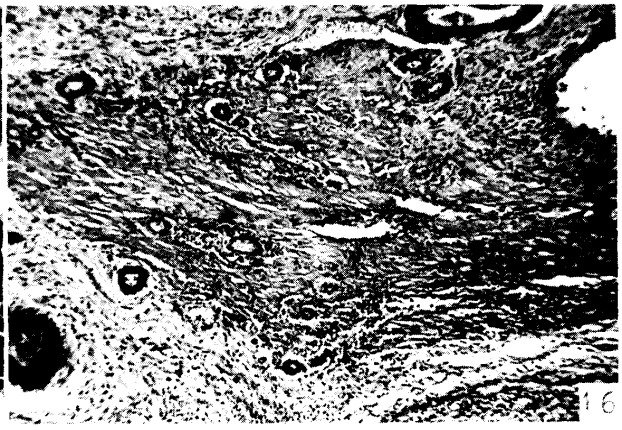
16

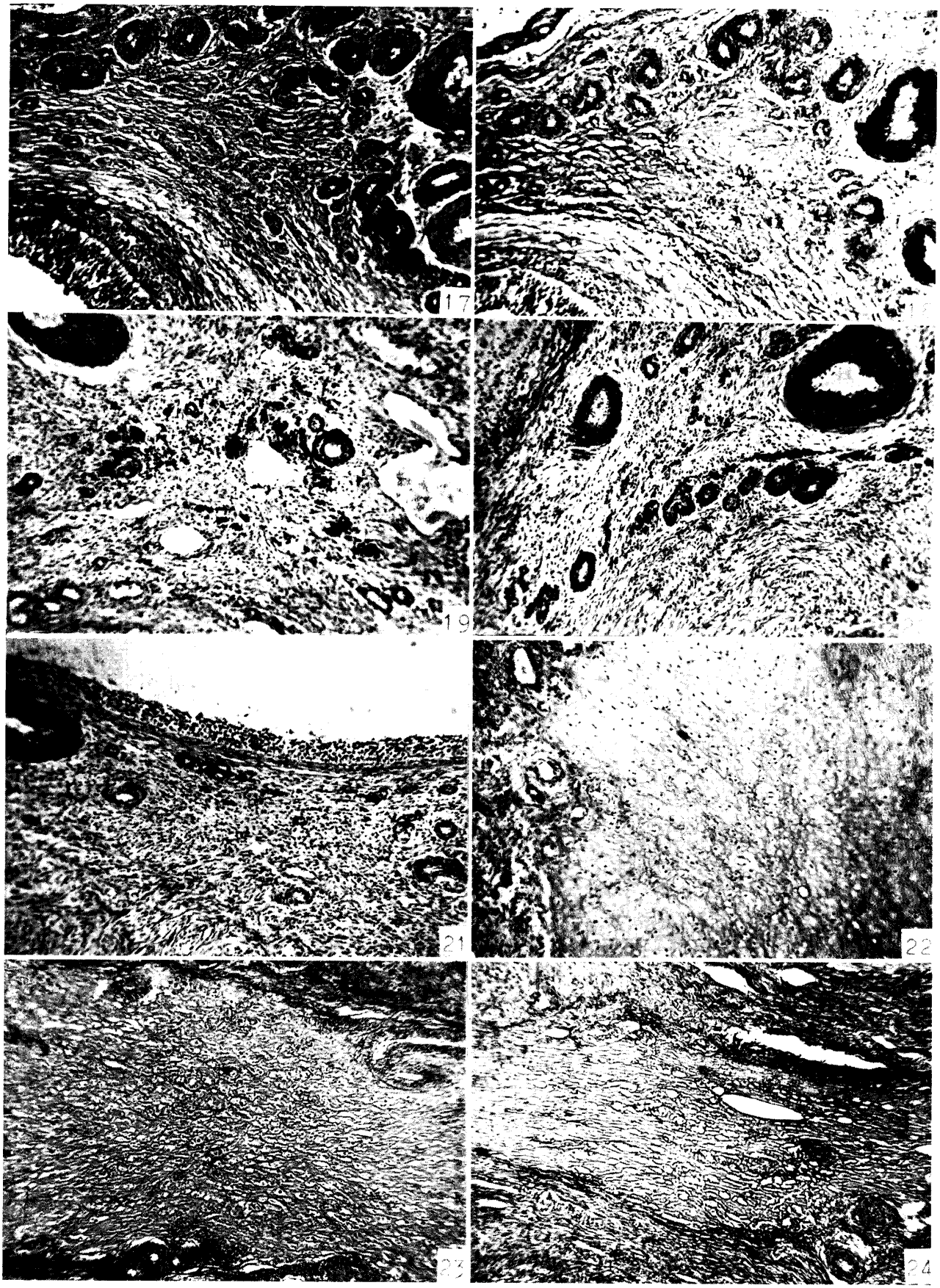
17
19
21
22
23
24

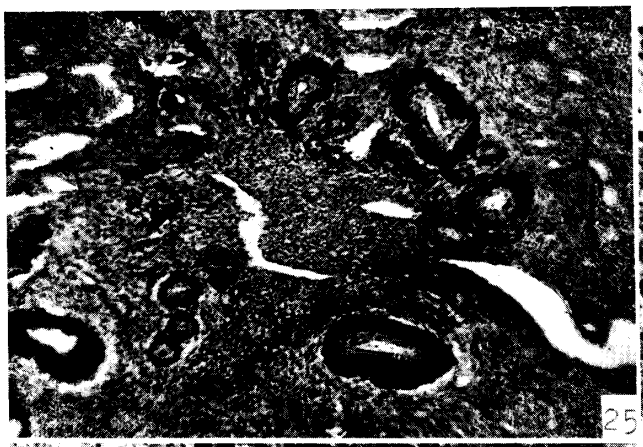
25


26


27


28


29


30


31

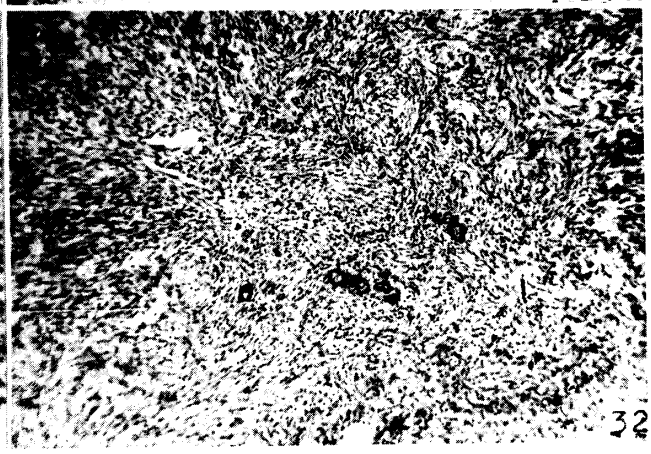
32

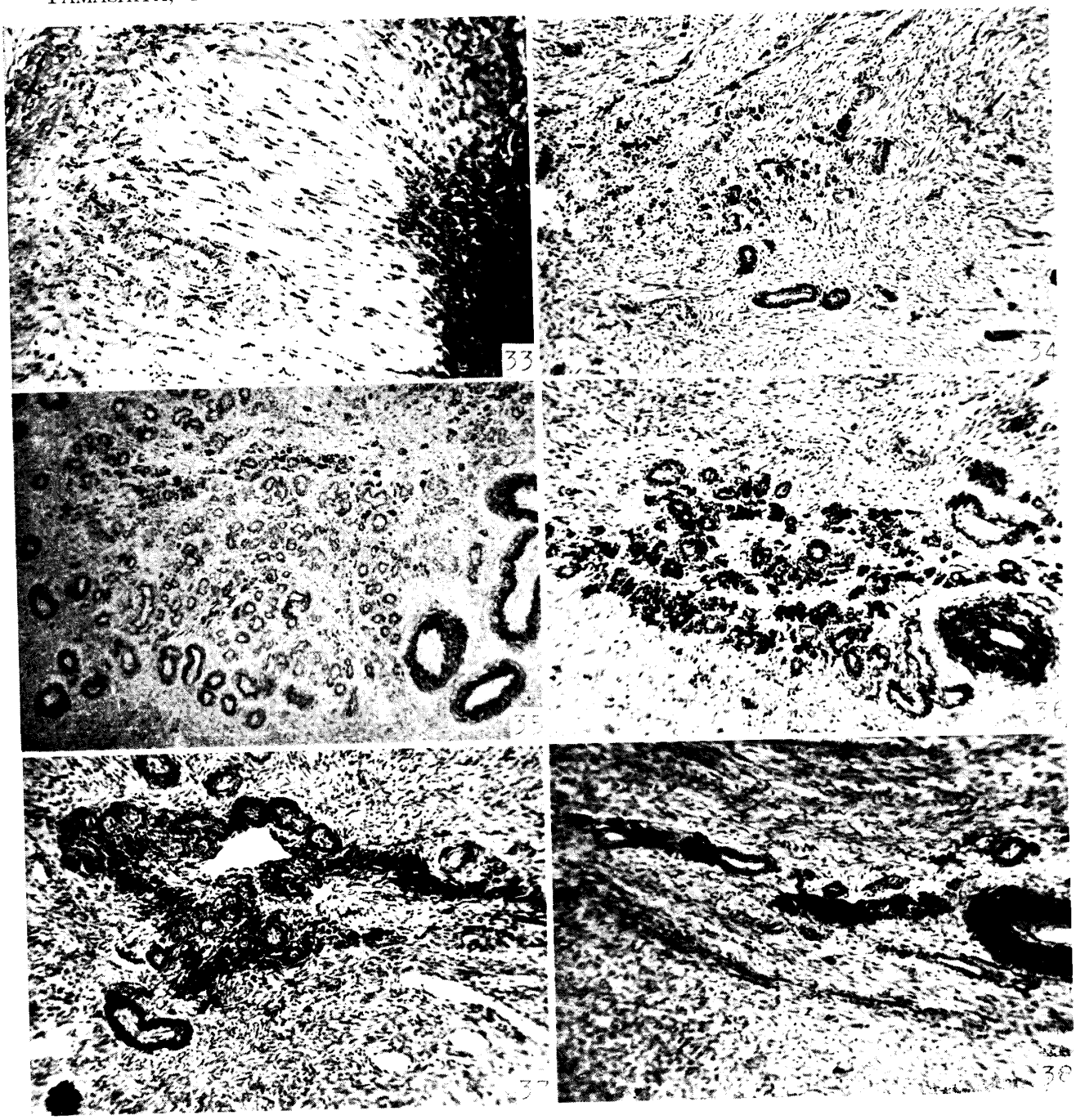
33
34
37
38

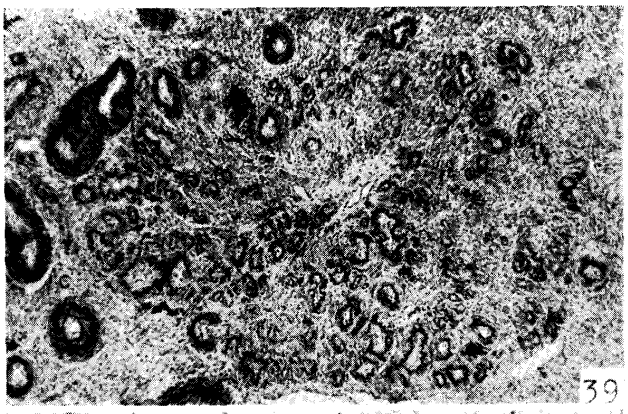
39

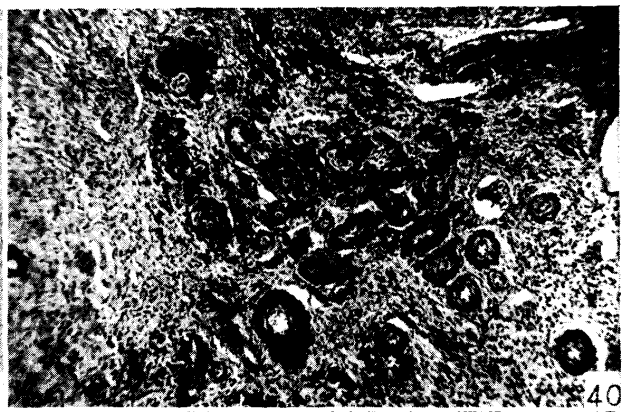
40


41

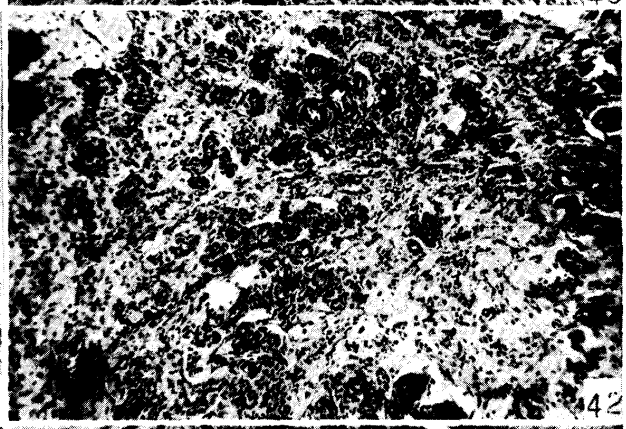
42

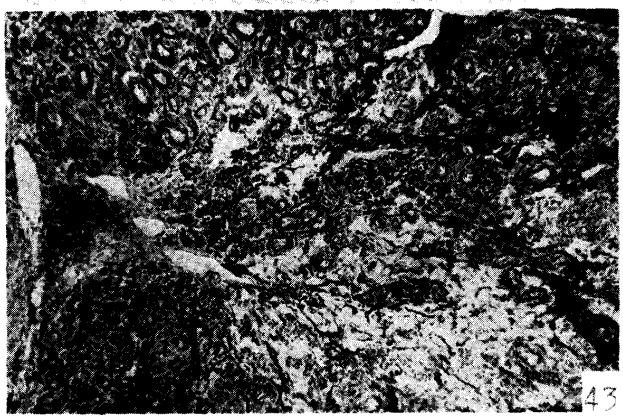
43

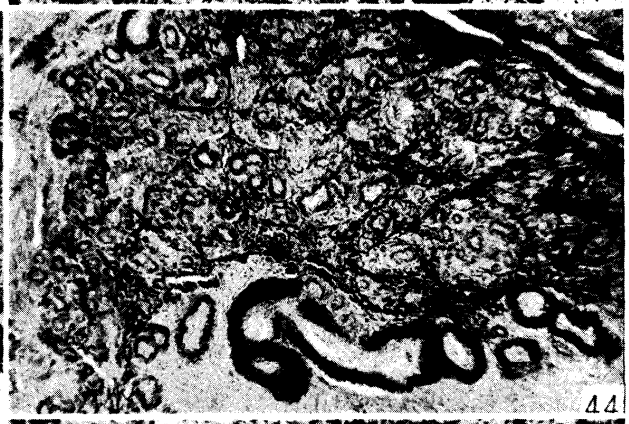
44


45

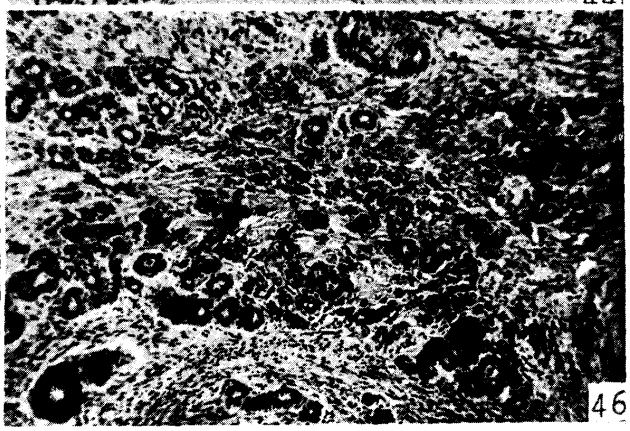
46