Arthroscopically Assited Reattachment of Avulsed Triangular Fibrocartilage Complex to the Fovea of the Ulnar Head

Surgical Technique

K2008-102R1, 2nd revision

Norimasa Iwasaki, MD, PhD; Akio Minami, MD, PhD

Department of Orthopaedic Surgery, Hokkaido University School of Medicine,

Sapporo, Japan

Running Title: Reattachment of Avulsed TFCC to the Fovea

Key words: Arthroscopic reattachment, Fovea, TFCC, Wrist arthroscopy

No benefits in any form have been received or will be received from a commercial party related directly or indirectly to the subject of this article.

Acknowledgment: The authors thank Dr. Yuichiro Abe for figure preparation and Dr. Tamotsu Kamishima for radiological evaluation.

Correspondence to: Norimasa Iwasaki, MD, PhD

Department of Orthopaedic Surgery, Hokkaido University School of Medicine, Kita 15, Nishi 7, Kita-Ku, Sapporo 060-8638, Japan.

Phone: 81-11-706-5937; Fax: 81-11-706-6054; E-mail: niwasaki@med.hokudai.ac.jp

Arthroscopically Assisted Reattachment of Avulsed Triangular Fibrocartilage Complex to the Fovea of the Ulnar Head

Abstract

Triangular fibrocartilage complex (TFCC) insertion into the fovea of the distal ulna plays a crucial role in stabilizing the distal radioulnar joint. Consequently, surgical reattachment against avulsion of the foveal TFCC insertion is required to stabilize the distal radioulnar joint. However, because of technical difficulties, no arthroscopic procedure for such a lesion has currently been established. We present a new technique for arthroscopic reattachment of the avulsed TFCC into the fovea. An osseous tunnel 2.9 mm in diameter is created from the ulnar neck to the foveal surface. Under arthroscopic guidance, a nonabsorbable suture passed into a 21 gauge needle is placed into the TFCC through the osseous tunnel. The avulsed portion of the TFCC is anchored to the fovea by means of a repair suture passed through the TFCC. To achieve normal tension of the TFCC, the suture is tied onto the periosteum around the proximal entrance of the osseous tunnel. Our arthroscopic technique is relatively simple and has significant advantages for progressive healing at the attachment site between the TFCC and the fovea.

Introduction

The triangular fibrocartilage complex (TFCC) is a complex structure consisting of fibrocartilaginous and ligamentous tissues on the ulnar side of the wrist. This structure plays a crucial role in stabilizing the distal radioulnar joint (DRUJ) during forearm rotations. Traumatic or chronic disruption of the TFCC leads to pathologic conditions of the wrist due to DRUJ instability.

Recent biomechanical studies have clarified that the TFCC insertion into the fovea of the distal ulna has a greater effect on DRUJ stability than other insertion sites (1). Therefore, surgical reattachment against avulsion of the foveal TFCC insertion must be considered to provide stability for the DRUJ. Although open techniques of reattachment for avulsed TFCC to the fovea of the ulnar head have been introduced (2,3), no arthroscopic procedure has currently been developed due to technical difficulties.

Arthroscopic surgery has an advantage of accurately diagnosing and locating the lesions, which is often difficult to do in open procedures. Our aim was to suggest a novel technique of arthroscopic reattachment of the avulsed TFCC into the foveal region of the distal ulna.

Surgical Technique

All patients had a positive ulnar fovea sign, positive provocative manners described by Kleinman (4), and DRUJ instability. We defined the DRUJ instability as an asymmetry of the constraint of the radius translation relative to the distal ulna in forearm pronation and supination (5). Preoperative water-excited 3D double-echo steady state (DESS) magnetic resonance coronal T2-weighted images showed an area of high-signal-intensity at just distal to the fovea in all patients. Arthroscopic procedures are performed under general anesthesia with a tourniquet. A traction tower (CONMED, Lorgo, FL) maintains 3.2 to 4.5 kg of distraction throughout the procedure via finger traps placed on all the fingers except for the thumb. An arthroscope is introduced into the 3-4 portal using the standard technique. Outflow is established through the 6-U portal. An accessory portal includes the 6-R or 4-5 portal. The lunotriquetral interosseous ligaments and the TFCC are each inspected for wear or tear. The articular surface of the lunate and the triquetrum are also investigated. TFCC tension or resilience (trampoline effect) on ballottement with an arthroscopic probe is tested to make a diagnosis (3). The final diagnosis of avulsion of the foveal TFCC insertion is determined by a loss of the normal trampoline effect and a displacement of the TFCC in multiple directions by pulling on the TFCC using a probe (5).

Once the diagnosis has been confirmed, a 1.5-mm Kirschner wire is used as a guide pin and percutaneously inserted from the ulnar neck to the foveal region of the ulnar head under C-arm visualization (Fig. 1). Then, a 1.5 cm incision is made around the Kirschner wire and the ulna is exposed between the extensor carpai ulnaris and the flexor carpi ulnaris. A 2.9 mm cannulated drill (Depuy, Warsaw, IN) is driven into the just distal to the fovea over the inserted Kirschner wire. This procedure creates an osseous tunnel 2.9 mm in diameter from the ulnar neck to the foveal surface and debrides fibrous connective tissues at the foveal surface (Fig. 2A). Under arthroscopic guidance in the 3-4 portal, a 2-0 nonabsorbable suture (Prolene, ETHICON, Some Ville, NJ) passed into a 21 gauge needle is placed into the TFCC through the osseous tunnel. Then, a 2-0 nonabsorbable suture loop is advanced into the TFCC using the same manner. The suture end is captured by the loop and delivered out of the osseous tunnel by proximally withdrawing the loop (Fig. 2A, B). Then, the two free ends of the repair suture are pulled through the osseous tunnel to bring the suture onto the TFCC surface. The avulsed portion of the TFCC is anchored to the fovea by means of this manner. Near-normal tension of the TFCC is then reconstituted by tightening both ends of the suture. With the forearm in neutral rotation, the suture is tied onto the ulnar periosteum around the proximal entrance of the osseous tunnel (Fig. 2C).

Each patient is splinted with a long-arm cast in 45° of supination for 4 weeks postoperatively. Then, a removable wrist brace is applied for an additional 2 weeks. Vigorous rehabilitation of the wrist and forearm begins at 6 weeks postoperatively.

Discussion

The proximal portion of the TFCC consists of the ligamentous component, including the radioulnar ligament, which plays a crucial role in stabilizing the DRUJ during forearm rotations. Anatomical studies have emphasized that this ligament originates from the fovea as well as the base of the ulnar styloid process (6). In the wrist joint, the center of forearm rotation runs through the ulnar head close to the foveal region. Therefore, the foveal insertion has a greater effect on DRUJ stability during forearm rotations than the styloid insertion (1).

Sennwald et al (3) showed that an open surgical reattachment of the avulsed TFCC to its foveal insertion gave promising results after a mean follow-up of 3 years. Although arthroscopic suture techniques for ulnar-sided TFCC tear (Palmer class 1B) have been reported (7-9), no arthroscopic procedure for the reattachment of the TFCC to the fovea has been established yet. To biologically bond the avulsed TFCC to the ulnar insertion, fibrous connective tissue at the foveal surface is debrided and the

bleeding from bone marrow is enhanced by curettage to cancellous bone. Under the standard arthroscopic technique, these manners require direct visualization of the foveal surface by inserting an arthroscope beneath the avulsed TFCC. This makes it difficult to perform arthroscopic surgery for the avulsed TFCC from the fovea.

Our new technique has been developed to overcome the technical difficulties mentioned above. The creation of an osseous tunnel for an outside-in arthroscopic suture technique can enhance bleeding from cancellous bone. In previous experimental studies, anchoring of the meniscus into a bone tunnel resulted in progressive healing at the attachment site between the two tissues (10,11). These experimental data provide the rationale for our arthroscopic technique against avulsion of the foveal TFCC insertion.

From 4 to 8 weeks postoperatively, computed tomography images suggested the osseous tunnel had been filled with new bone formation (Fig. 3). Magnetic resonance images at 12 weeks postoperatively showed findings indicating attachment of the TFCC to the distal entry site of the tunnel. The technique we present allows an arthroscopic repair for avulsion of the TFCC at its foveal insertion. This technique is relatively simple for reattachment of avulsed TFCC to the fovea. We consider it a promising alternative to the procedures actually in use.

127 **References**

128 1. Haugstvedt JR, Berger RA, Nakamura T, Neale P, Berglund L, An KN. Relative
129 contributions of the ulnar attachments of the triangular fibrocartilage complex to the
130 dynamic stability of the distal radioulnar joint. J Hand Surg 2006;31A:445-451.
131 2. Hermansdorfer JD, Kleinman WB. Management of chronic peripheral tears of the
132 triangular fibrocartilage complex. J Hand Surg 1991;16A:340-346.
133 3. Sennwald GR, Lauterburg M, Zdravkovic V. A new technique of reattachment after
134 traumatic avulsion of the TFCC at its ulnar insertion. J Hand Surg
135 1995;20B:178-184.
136 4. Kleinman WB. Stability of the distal radioulna joint: biomechanics, pathophysiology,
137 physical diagnosis, and restoration of function what we have learned in 25 years. J
138 Hand Surg 2007;32A:1086-1106.
139 5. Tay SC, Tomita K, Berger RA. The "ulnar fovea sign" for defining ulnar wrist pain:
140 an analysis of sensitivity and specificity. J Hand Surg 2007;32A:438-444.
141 6. Nakamura T, Makita A. The proximal ligamentous component of the triangular
142 fibrocartilage complex. J Hand Surg 2000;25B:479-486.
143 7. Böhringer G, Schädel-Höpfner M, Petermann J, Gotzen L. A method for all-inside
144 arthroscopic repair of Palmer 1B triangular fibrocartilage complex tears.

Arthroscopy 2002;18:211-213.

8. Pederzini LA, Tosi M, Prandini M, Botticella C. All-inside suture technique for Palmer class 1B triangular fibrocartilage repair. Arthroscopy 2007;23:1130.e1-4

9. Yao J, Dantuluri P, Osterman AL. A novel technique of all-inside arthroscopic triangular fibrocartilage complex repair. Arthroscopy 2007;23:1357.e1-4.

10. Gao J, Wei X, Messner K. Healing of the anterior attachment of the rabbit meniscus to bone. Clin Orthop Relat Res 1998;348:246-258.

11. Vail TP, Koukoubis TD, Schenkman D, Feagin JA. Graft-bone healing of a meniscus autograft anchored in bone tunnels. Knee Surg, Sports Traumatol, Arthroscopy 1995;3:105-110.

Figure Legends

Figure 1. Under C-arm visualization, a guide pin is inserted from the ulnar neck to the foveal region of the ulnar head to create an osseous tunnel.

Figure 2. (A) An osseous tunnel 2.9 mm in diameter from the ulnar neck to the foveal surface. Using a suture loop, the end of repair suture is delivered out of the osseous tunnel. **(B)** The two free ends of the repair suture are pulled through the osseous tunnel to bring the suture onto the TFCC surface. **(C)** The avulsed portion of the TFCC is anchored to the fovea with near normal tension. The suture is tied onto the ulnar periosteum around the proximal entrance of the osseous tunnel.

Figure 3. Computed tomography images suggest that the osseous tunnel is filled with new bone formation at 8 weeks postoperatively.

Reference Citation from the Pub/Med/Medline Web Site

1. Haugstvedt JR, Berger RA, Nakamura T, Neale P, Berglund L, An KN. Relative contributions of the ulnar attachments of the triangular fibrocartilage complex to the dynamic stability of the distal radioulnar joint. J Hand Surg [Am]. 2006 Mar;31(3):445-51. PMID: 16516740 [PubMed - indexed for MEDLINE]
2. Hermansdorfer JD, Kleinman WB. Management of chronic peripheral tears of the triangular fibrocartilage complex. J Hand Surg [Am]. 1991 Mar;16(2):340-6. PMID: 2022850 [PubMed - indexed for MEDLINE]
3. Sennwald GR, Lauterburg M, Zdravkovic V. A new technique of reattachment after traumatic avulsion of the TFCC at its ulnar insertion. J Hand Surg [Br]. 1995 Apr;20(2):178-84. PMID: 7797966 [PubMed - indexed for MEDLINE]
4. Kleinman WB. Stability of the distal radioulna joint: biomechanics, pathophysiology, physical diagnosis, and restoration of function what we have learned in 25 years. J Hand Surg [Am]. 2007 Sep;32(7):1086-106. Review. No abstract available.PMID: 17826566 [PubMed - indexed for MEDLINE]
5. Tay SC, Tomita K, Berger RA. The "ulnar fovea sign" for defining ulnar wrist pain: an analysis of sensitivity and specificity. J Hand Surg [Am]. 2007 Apr;32(4):438-44. PMID: 17398352 [PubMed - indexed for MEDLINE]

6. Nakamura T, Makita A. The proximal ligamentous component of the triangular fibrocartilage complex. J Hand Surg [Br]. 2000 Oct;25(5):479-86. PMID: 10991819 [PubMed - indexed for MEDLINE]
7. Böhringer G, Schädel-Höpfner M, Petermann J, Gotzen L. A method for all-inside arthroscopic repair of Palmer 1B triangular fibrocartilage complex tears. Arthroscopy. 2002 Feb;18(2):211-3. PMID: 11830818 [PubMed - indexed for MEDLINE]
8. Pederzini LA, Tosi M, Prandini M, Botticella C. All-inside suture technique for Palmer class 1B triangular fibrocartilage repair. Arthroscopy. 2007 Oct;23(10):1130.e1-4. Epub 2007 Mar 13. PMID: 17916483 [PubMed - indexed for MEDLINE]
9. Yao J, Dantuluri P, Osterman AL.A novel technique of all-inside arthroscopic triangular fibrocartilage complex repair. Arthroscopy. 2007 Dec;23(12):1357.e1-4. Epub 2007 May 7. PMID: 18063183 [PubMed - indexed for MEDLINE]
10. Gao J, Wei X, Messner K. Healing of the anterior attachment of the rabbit meniscus to bone. Clin Orthop Relat Res. 1998 Mar;(348):246-58. PMID: 9553559 [PubMed - indexed for MEDLINE]

11. Vail TP, Koukoubis TD, Schenkman D, Feagin JA. Graft-bone healing of a meniscus autograft anchored in bone tunnels. Knee Surg Sports Traumatol Arthrosc. 1995;3(2):105-10. PMID: 7553004 [PubMed - indexed for MEDLINE]

Figure 1
Click here to download high resolution image

Figure 2A

Click here to download high resolution image

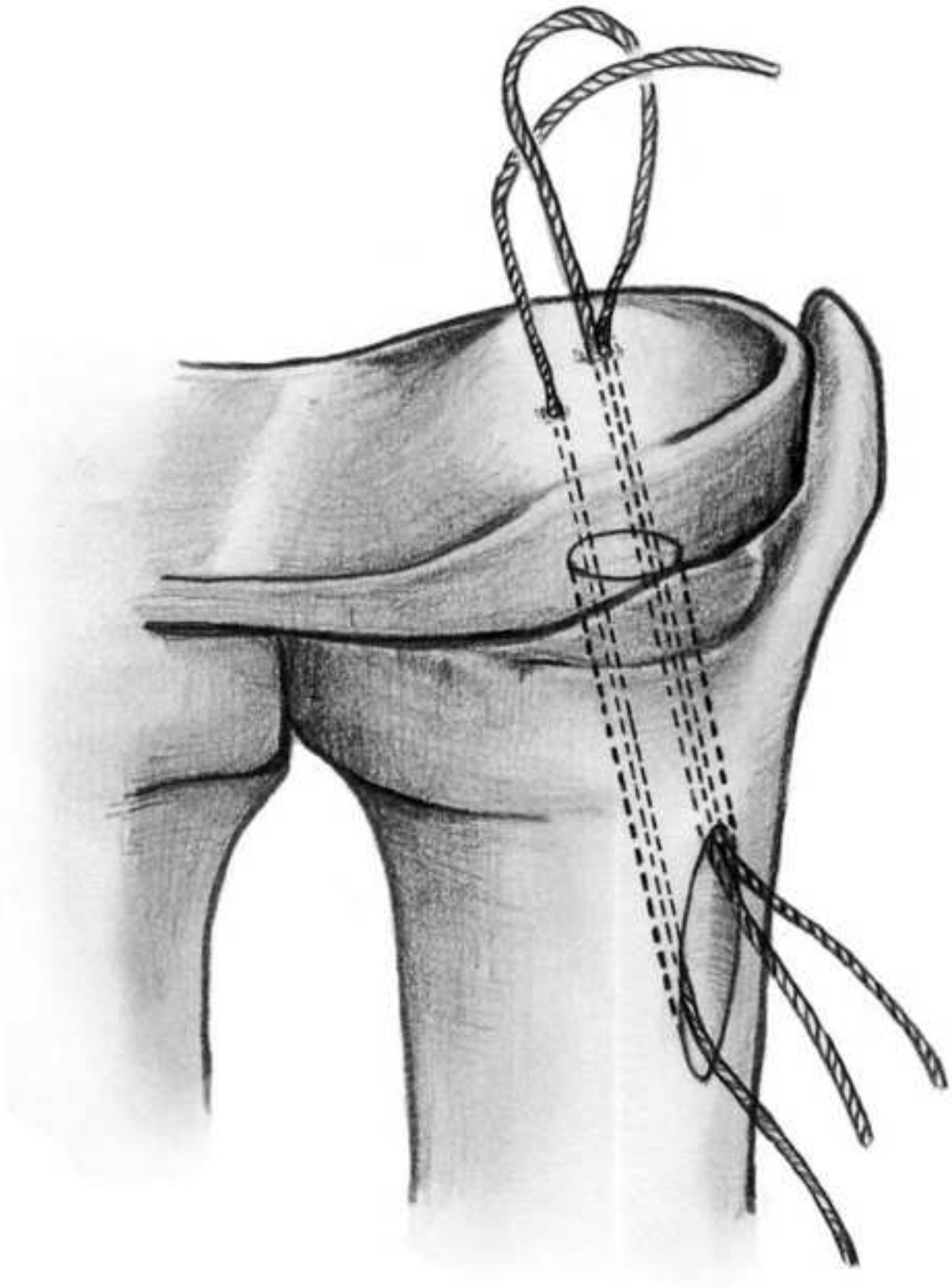

Figure 2B

Click here to download high resolution image

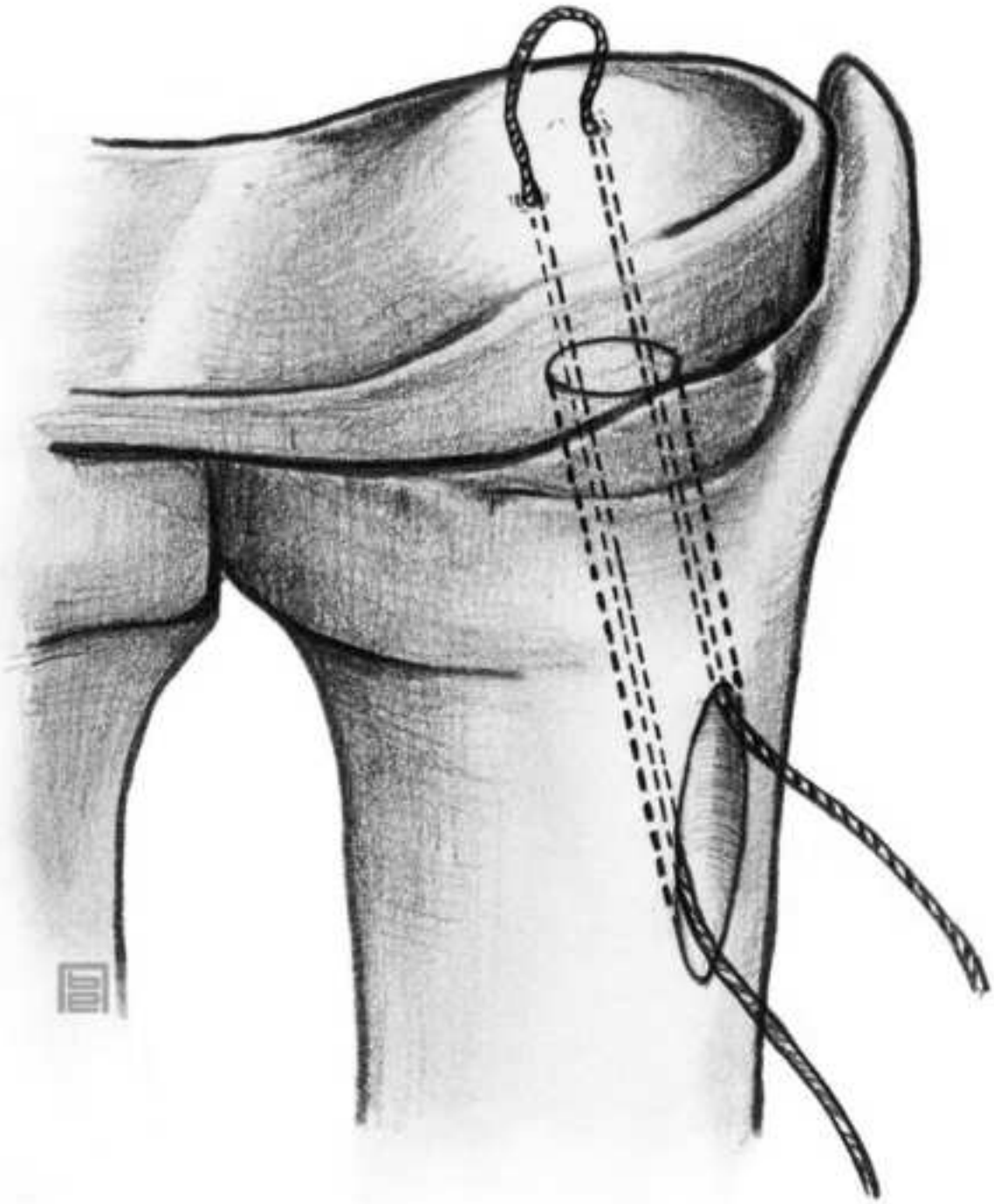

Figure 2C
Click here to download high resolution image

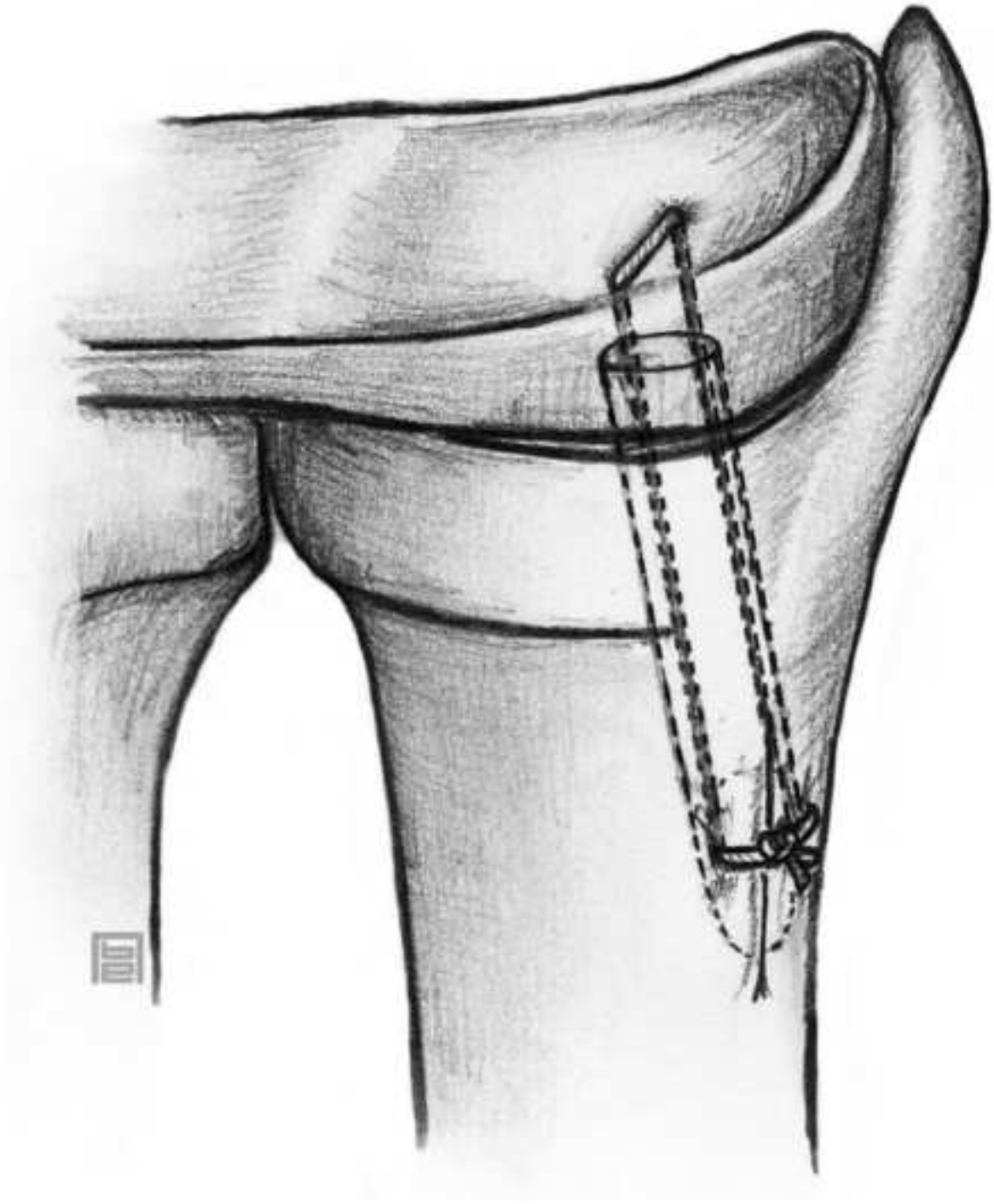

Figure 3
Click here to download high resolution image