Radial Overgrowth after Radial Shortening Osteotomies for Skeletally Immature Patients with Kienböck's Disease

Tomoya Matsuhashi, MD, Norimasa Iwasaki, MD, Naomi Oizumi, MD,

Hiroyuki Kato, M.D,* Michio Minami, MD,** Akio Minami, MD

Department of Orthopaedic Surgery, Hokkaido University Graduate School of Medicine,

Sapporo, JAPAN

*Department of Orthopaedic Syrgery, Shinsyu University Graduate School of Medicine,

Matsumoto, JAPAN

**Hokkaido Orthopaedic Memorial Hospital, Sapporo, JAPAN

Running title: Overgrowth after radial shortening osteotomy

Key words: Kienböck's disease, Overgrowth, Radial shortening, Teenagers

No benefits in any form have been received or will be received from a commercial party related directly or indirectly to the subject of this article.

Corresponding author: Norimasa Iwasaki, MD

Department of Orthopaedic Surgery, Hokkaido University Graduate School of Medicine, Kita 15 Nishi 7, Sapporo, 060-8638, JAPAN.

Phone: +81-11-716-5937, Fax +81-11-706-6054

E-mail: niwasaki@med.hokudai.ac.jp

ABSTRACT

Purpose: We hypothesized that radial shortening osteotomy (radial shortening) for skeletally immature patients with Kienböck's disease would induce the overgrowth of the radius. The purpose of this study was to determine the effect of radial shortening on radial growth in skeletally immature patients with Kienböck's disease and to clarify the relationship between the postoperative growth alterations and the clinical results.

Methods: Eight wrists of 8 skeletally immature patients with Kienböck's disease were treated with radial shortening. There were 3 males and 5 females, ranging in age from 11 to 18 (mean, 14) years old. All patients were presented with open physis and negative ulnar variance. The length of the radial shortening equaled the amount of negative ulnar variance. Clinical assessment was based on the modified Nakamura scoring system. Radiographic assessment, including Lichtman's stages, ulnar variance, carpal height ratio, radial inclination and volar tilt was performed preoperation, immediately after surgery, and at follow-up. A difference in ulnar variance of more than 2 mm between these time points was considered to be overgrowth. Statistical comparisons were performed using paired t-tests.

Results: At a mean follow-up period of 69 months, the mean clinical score was 19.7 of 21 maximum points, with all wrists rated as excellent. Radiographically, no progression of Lichtman stage was found in any patient. At follow-up, the X-ray and MRI findings indicated lunate revascularization in all patients. Four of the 8 were recognized to have had overgrowth in the operated radius. On the other hand, other radiographic parameters showed no significant

changes at follow-up. The occurrence of postoperative radial overgrowth did not significantly affect the clinical scores.

Conclusions: The current results suggest the probability of occurrence in the overgrowth of the radius in skeletally immature patients with Kienböck's disease treated with radial shortening. The postoperative radial overgrowth after this osteotomy had no effects on clinical and other radiographic outcomes.

Type of study/level of evidence: Therapeutic IV

INTRODUCTION

Kienböck's disease often affects male manual workers between the ages of 20 and 40.[1] The pathogenesis of this disease process is still controversial. Consequently, various operations, including excision arthroplasty,[2,3] radial wedge and shortening osteotomies, [4-8] limited intercarpal fusions[9-11] and lunate revascularization procedures[12-14] have been advocated as treatments.

Based on the theory that negative ulnar variance is a significant causative factor in Kienböck's disease,[15,16] radial shortening osteotomy (radial shortening) has been advocated for patients with negative ulnar variance. A radial shortening osteotomy has been reported to improve clinical results in adults.[4,5,7] However, little is known about the postoperative history of the disease in skeletally immature patients. In a recent study, Iwasaki et al.[6] reported that radial shortenings provided satisfactory clinical and radiographic outcomes in teenage patients even at advanced stages of the disease.

There are few reports concerning the outcome and risk of postoperative overgrowth of the radius following radius shortening for skeletally immature patients in Kienböck's disease.[17] We should consider the effect of radial shortening osteotomy on the postoperative radial growth.

In the present study, we have performed radial shortenings for skeletally immature patients with Kienböck's disease and evaluated clinical and radiographic results. The hypothesis of this study was that radial shortening for skeletally immature patients with

Kienböck's disease would induce alterations in radial growth. The aims of this study were to determine the effect of radial shortening on radial growth in skeletally immature patients with Kienböck's disease and to elucidate relationships between postoperative growth changes and clinical outcomes.

MATERIALS AND METHODS

We retrospectively identified and reviewed all skeletally immature patients with symptomatic Kienböck's disease from 1990 to 2004 who were considered for radial shortening. Chart reviews identified 8 patients. Three surgeons carried out radial shortening for the 8 patients with negative ulnar variance. Hospital medical records and preoperative and postoperative radiographs obtained at regular follow-ups were collected to evaluate the clinical and radiographic findings. There were 3 males and 5 females between 11 and 18 (mean 14) years old. They were presented with open physis. All patients had an occupational or recreational background of repeated minor stress to the wrist. Six patients had a history of acute trauma to the affected wrist. In all patients, occupational or recreational activities were interrupted by severe wrist pain. Preoperative Lichtman's stages[18] were determined according to the radiographic findings (Table 1). In identifying preoperative Lichtman's stages in this study, 2 cases were at stage II, 2 cases at stage IIIA, and 4 cases at stage IIIB. All patients had preoperative magnetic resonance imaging (MRI), although 6 of the 8 patients had MRI scans at follow-up.

Surgical Technique.

All operations on the patients were performed under general anesthesia. An 8-cm longitudinal skin incision was made in the distal part of the anterior aspect of the forearm, parallel and lateral to the tendon of the flexor carpi radialis. The distal part of the radius was exposed between the brachioradialis and the flexor carpi radialis tendon. Radial shortening was carried out by making two parallel transverse cuts to remove an appropriate segment of the bone. The length of the removed segment equaled the amount of negative ulnar variance measured on the preoperative radiograph. The osteotomy site was fixed by a 5-hole or 6-hole dynamic compression plate. Using fluorogram, we avoided a growth plate injury by plate application. Postoperatively, a below-elbow splint was applied for 2 weeks. All patients had an operation to remove the plate approximately 1 year postoperatively.

Outcome Assessment.

At follow-up, patients were evaluated clinically and radiographically. Clinical evaluation was based on a modification of the scoring system of Nakamura et al (Table 2).[19] Three observers examined clinical findings at follow-up. The original scoring system with a 30-point maximum was based on clinical and radiographic results with 21 points and 9 points, respectively. Although the radiographic assessment was deleted from the original scoring system, we assessed the radiographic findings in other parameters including ulnar

variance,[15,20,21] carpal height ratio,[3,22] radial inclination[23], and volar tilt[23].

Radiographic evaluation was based on the Lichtman's stage.[18] The progression of degenerative change through the entire wrist joint and revascularization of the diseased lunate was determined with anteroposterior (AP) and lateral radiographs of the wrist**.** The radiographic parameters, including ulnar variance,[15,20,21] carpal height ratio,[3,22] radial inclination[23], and volar tilt[23] were measured preoperation, immediately after the radial shortening, and at follow-up. The ulnar variance is defined as the difference between the transverse line at the level of the lunate fossa and the transverse line at the level of the ulnar head on the AP radiograph with the shoulder abducted, elbow flexed, and forearm in neutral rotation to quantify variance.[15,20,21] The carpal height ratio is defined as the carpal height divided by the length of the third metacarpal on the AP radiograph.[3,22] The radial inclination is the angle of the distal radial articular surface to the line perpendicular to the long axis of the radius on the AP radiograph.[23] The volar tilt is the angle created between the articular surface of the distal radius and the line perpendicular to the long axis of radius on the lateral radiograph.[23] Regarding overgrowth, a difference in length of more than 2 mm was considered a discrepancy.[24] According to the MRI grading system by Nakamura et al,[19] the preoperative and postoperative signal intensities of the lunate were evaluated.

<u>The radiographic measurements were all made by the senior author, an experienced hand surgeon.</u> Intra-observer variations in the measurements were assessed by calculating the coefficient variation, which equals the standard deviation divided by the mean value. The

observer took 5 measurements of each parameter in the same radiograph. The coefficient of variation of each parameter among the results of 5 sets was calculated. The value was 8.8% in the ulnar variance, 2.8% in the carpal height ratio, 4.0% in the radial inclination, and 9.3% in the volar tilt. These low values showed a high reliability of the radiographic measurements.

Statistical Analysis.

All data were represented as mean ± standard deviation. Statistical comparisons were performed using paired t-tests. The level of significance was set at a probability value of less than 0.05.

RESULTS

Clinical Assessments.

At a mean follow-up of 69 (range, 36-117) months, 6 of the 8 patients were free from pain, and the remaining patients had mild wrist pain on strenuous activity. No patient had pain at the DRUJ or at the osteotomy site. The mean postoperative range of extension and flexion of the wrist significantly increased from 90.7 ± 15.5° to 151.4 ± 20.5° ($p < 0.0001$). The grip strength of the affected side compared with the unaffected side improved from 42.5 ± 12.7% to 103.5 ± 10.2% ($p < 0.0001$). Based on the scoring system, the mean clinical score was 19.7 (range, 17–21) of 21 maximum points. All patients were classified as excellent. There were no postoperative complications.

Radiographic Assessments.

Bony union at the site of the osteotomy was achieved within 12 weeks in all patients. Radiographic findings suggested that radial shortening prevented disease progression and enhanced diseased lunate revascularization. At follow-up, no progression of Lichtman's stages was found in any patient. There were no degenerative changes in the DRUJ or the radio carpal joint in any patients. Lunate revascularization based on the radiographic findings was found in all patients. Magnetic resonance imaging scans of all patients showed grade V of the Nakamura's grading system, as defined by generalized low signal intensity of the lunate on T1-weighted and T2-weighted images, preoperatively. At follow-up, in 4 of the 6 patients, the MRI scans demonstrated a return of normal marrow signal intensity of the lunate, indicating grade I (Fig. 1). The grade II finding, including localized regions of slightly decreased signal intensity, was found in the remaining 2 patients.

Postoperative alterations in radiographic parameters showed a tendency towards radial overgrowth following radial shortening osteotomy for teenagers with Kienböck's disease. Table 3 summarizes the alterations in radiographic parameters. The mean postoperative ulnar variance significantly increased from -1.4 ± 1.3 mm (range, 0 to 4 mm) to -3.9 ± 2.2 mm (range, 1 to 8 mm) ($p < 0.03$). Based on the criteria for overgrowth, 4 of the 8 patients were recognized to have had radial overgrowth on the affected side of the radius (Fig. 2, Table 4). All 4 of these patients were under 13 years at the time of operation. On the other hand, the other parameters

showed no significant changes postoperatively.

Effect of Postoperative Radial Overgrowth on Clinical Outcomes.

The occurrence of postoperative radial overgrowth did not significantly affect the clinical scores. The mean score was 20.5 ± 0.9 in the patient group with radial overgrowth and 19.0 ± 1.6 in that without radial overgrowth.

DISCUSSION

The first aim of this study was to determine the effect of radial shortening on radial growth in skeletally immature patients with Kienböck's disease. At a mean follow-up of 69 months, in standard radiographs, we recognized that 4 of the 8 patients (50%) had radial overgrowth in the operated side. There were no other findings indicating radial deformities after this operation. To our knowledge, only one case report has demonstrated 8 mm overgrowth at 80 months after radial shortening for Kienböck's disease in a skeletally immature patient.[17] Therefore, this is the first study showing the probability of overgrowth after radial shortening in skeletally immature patients with Kienböck's disease.

Carsi et al.[24] showed that 67% of 119 pediatric patients with nonphyseal forearm fracture treated conservatively had radius overgrowth at 5 years after injury. In their study, only fractures in the proximal and middle 1/3 of the radius were associated with overgrowth; distal 1/3 fractures were associated with growth arrest. Our data obtained from the osteotomy cases

disagree with these results. One of the reasons for this discrepancy is considered to be the stimulation of growth by operative procedures. Bone overgrowth is thought to be caused by increased vascularity. Doria et al.[25] showed postoperative hypervascularity after femoral osteotomy in rabbits. This report did not deal with postoperative radius hypervascularity. However, this result may indicate that radial shortening osteotomy induces hypervascularity of the distal radius. Therefore, we assume that the effects of the radial shortening osteotomy are considered not only for mechanical decompression, but also for increases in distal radius and lunate vascularity. Therefore, stimulation of growth by the radial shortening is more likely the cause. Another reason seems to be the existence of microinjuries to the growth plate of the distal radius in distal 1/3 fractures. In performing radial shortening, the distal growth plate can be protected from injuries. This could arrest the growth of the radius even though the radius responds to stimulus caused by fracture.

In this study, radial overgrowth was observed in 4 of 5 patients who were under 13 years old. A previous case report presented that overgrowth after radial shortening occurred in a 15-year-boy.[17] Based on the radiographic distance between the distal radius and ulnar growth plates, Pritchett[26] suggested that the skeletal maturation of the forearm bones was at age 13 in girls and 15 in boys. On the other hand, Carsi, et al.[24] concluded that overgrowth after forearm fractures was not influenced by age. Although this contradicts the results mentioned above, the probability of radial overgrowth should be considered in doing radial shortening for Kienböck's disease in skeletally immature patients.

Another question was to clarify the relationships between the postoperative growth changes and the clinical outcomes after radial shortening. In our study, the existence of radial overgrowth did not significantly affect the postoperative clinical outcomes. All skeletally immature patients with postoperative radial overgrowth achieved excellent clinical results. Ulnar negative variance associated with postoperative radial overgrowth seems to cause compressive force to the lunate. This biomechanical effect may lead to the progression of Kienböck's disease. However, the MRI findings obtained here indicate that radial shortening produces lunate revascularization and healing in skeletally immature patients with this disease. Consequently, the excessive force produced by radial overgrowth may not progress the stage of Kienböck's disease in skeletally immature patients. Radial shortening provides a positive clinical outcome for skeletally immature patients with Kienbock's disease, even though the existence of postoperative radial overgrowth. Therefore, this operation is considered to be an effective procedure for Kienbock's disease in children. Regarding the operative technique, we recommend to perform a 1 or 2 mm overshortening for skeletally immature patients especially under 13 years old.

We caution readers regarding the considerable limitations of this study. First, the current analysis was based on data from a relatively small number of patients. Therefore, the statistical power might not be enough to clearly derive the conclusions from the current analysis. Second, we had no definite data of control group in non-operation healthy patients of the same age. However, we consider that there may be no difference in the laterality of ulnar

variance in skeletally immature patients. Therefore, regarding overgrowth, a difference in length of more than 2 mm was considered to be a discrepancy. Third, at a mean of 69 months postoperatively, the radial overgrowth would not produce any radiographic changes, such as osteoarthritis of the DRUJ, and related symptoms. This might not influence the clinical results the same way in the future. A longer follow-up in a large cohort population is needed to overcome these limitations.

In conclusion, overgrowth after radial shortening for Kienböck's disease in skeletally immature patients occurs but has little effect on clinical outcomes. The obtained results also provide precious information on the probability of growth changes after forearm osteotomies for other disorders, such as congenital anomalies or traumatic deformities, in skeletally immature patients.

REFERENCES

1. Allan CH, Joshi A, Lichtman DM. Kienböck's disease: diagnosis and treatment. J Am Acad Orthop Surg 2001;9:128–136.
2. Eaton RG. Excision and fascial interposition arthroplasty in the treatment of Kienböck's disease. Hand Clin 1993;9:513–516.
3. Kato H, Usui M, Minami A. Long-term results of Kienböck's disease treated by excisional arthroplasty with a silicone implant or coiled palmaris longus tendon. J Hand Surg

1986;11A:645–653.

4. Almquist EE, Burns JF Jr. Radial shortening for the treatment of Kienböck's disease: a 5- to 10-year follow-up. J Hand Surg 1982;7A:348–352.

5. Iwasaki N, Minami A, Oizumi N, Suenaga N, Kato H, and Minami M. Radial osteotomy for late stage Kienböck's disease: Wedge osteotomy versus radial shortening. J Bone Joint Surg 2002;84B:673–677.

6. Iwasaki N, Minami A, Ishikawa J, Kato H, Minami M. Radial osteotomies for teenage patients with Kienböck disease. Clin Orthop 2005;439:116–122.

7. Rock MG, Roth JH, Martin L. Radial shortening osteotomy for treatment of Kienböck's disease. J Hand Surg 1991;16A:454–460.

8. Weiss AP, Weiland AJ, Moore JR, Wilgis EF. Radial shortening for Kienböck disease. J Bone Joint Surg 1991;73A:384–391.

9. Pisano SM, Peimer CA, Wheeler DR, Sherwin F. Scaphocapitate intercarpal arthrodesis. J Hand Surg 1991;16A:328–333.

10. Sennwald GR, Ufenast H. Scaphocapitate arthrodesis for the treatment of Kienböck's disease. J Hand Surg 1995;20A:506–510.

11. Watson HK, Monacelli DM, Milford RS, Ashmead IV D. Treatment of Kienböck's disease with scaphotrapezio-trapezoid arthrodesis. J Hand Surg 1996;21A:9–15.

12. Hori Y, Tamai S, Okuda H, Sakamoto H, Takita T, Masuhara K. Blood vessel transplantation to bone. J Hand Surg 1979;4A:23–33.

13. Hermans S, Degreef I, De Smet L. Vascularised bone graft for Kienböck disease: preliminary results. Scand J Plast Reconstr Surg Hand Surg 2007;41:77-81.

14. Lu LJ, Gong X, Wang KL. Vascularized capitate transposition for advanced Kienböck disease: application of 40 cases and their anatomy. Ann Plast Surg. 2006;57:637-641.

15. Hulten O.Über anatomische Variationen der Handgelenkknochen: Ein Beitrag zur Kenntnis der genese zwei verschiedener Mondbeinveranderungen. Acta Radiol 1928;9:155–168.

16. Bonzar M, Firrell JC, Hainer M, Mah ET, McCabe SJ. Kienböck Disease and Negative Ulnar Variance. J. Bone Joint Surg 1998;80A:1154-1157.

17. Herdem M, Ozkan C, Bayram H. Overgrowth after Radial Shortening for Kienböck's Disease in a Teenager: Case Report. J Hand Surg 2006;31A:1322–1325.

18. Alexander AH, Lichtman DM. Kienböck's Disease. In Lichtman DM (ed). The Wrist and Its Disorders. Philadelphia, WB Saunders 1998;329–343.

19. Nakamura R, Watanabe K, Tsunoda K, Miura T. Radial osteotomy for Kienböck's disease evaluated by magnetic resonance imaging: 24 cases followed for 1–3 years. Acta Orthop Scand 1993;64:207–211.

20. Gelberman RH, Salamon PB, Jurist JM, Posch JL. Ulnar variance in Kienbock's disease. J. Bone Joint Surg 1975;57A:674-676.

21. Chan KP, Huang P. Anatomic variations in radial and ulnar lengths in the wrists of Chinese. Clin Orthop Relat Res 1971;80:17-20.

22. Youm Y, McMurtry RY, Flatt AE, Gillespie TE. Kinematics of the wrist. I. An experimental study of radial-ulnar deviation and flexion- extension. J Bone Joint Surg 1978;60A:423–431.

23. Gartland JJ Jr, Werley CW. Evaluation of Healed Colles' Fractures. J. Bone Joint Surg 1951;33A:895-907.

24. Carsi B, Abril JC, Epeldegui T. Longitudinal growth after nonphyseal forearm fractures. J Pediatr Orthop 2003;23:203-207.

25. Doria AS, Cunha FG, Modena M, Rodrigues CJ, Garcez AT, Godoy Junior R et al. Effect of intertrochanteric osteotomy on the proximal femur of rabbits: assessment with power Doppler sonography and scintigraphy. Clinics 2007;62:741-748.

26. Pritchett JW. Growth and Development of the Distal Radius and Ulna. J Pediatr Orthop 1996;16:575-577.

FIGURE LEGENDS

Figure 1. A preoperative AP radiograph of an 11-year-old boy with Stage IIIA Kienböck's disease in the right wrist (A). The AP radiograph shows ulna-zero variance immediately after radial shortening (B). The AP radiograph obtained 48 months after radial shortening indicates lunate revascularization with improved appearance of the lunate in density and height (C).

Preoperative coronal T1 and T2-weighted MRI images show diffuse decreased signal intensity of the lunate (D, E). At follow-up, T1 and T2 –weighted images demonstrate return of normal signal intensity of the involved lunate (F, G).

Figure 2. A preoperative AP radiograph of a 13-year-old boy shows Stage IIIB Kienböck's disease in the right wrist (A). The AP radiograph immediately after radial shortening reveals 1 mm ulna-negative variance (B). Radial overgrowth at the operated side is found in the AP radiograph at 65 months after radial shortening (C). Transverse line is set on the tip of ulnar head through (A) – (C).

Citation Details

1. Kienböck's disease: diagnosis and treatment. Journal of the American Academy of Orthopaedic Surgeons Vol 9, No 2, March/April 2001, 128-136. Allan CH, Joshi A, Lichtman DM. PMID: 11281636
2. Excision and fascial interposition arthroplasty in the treatment of Kienböck's disease. Hand Clin. 1993 Aug;9(3):513-6. Review Eaton RG. PMID: 8408262
3. Long-term results of Kienböck's disease treated by excisional arthroplasty with a silicone implant or coiled palmaris longus tendon. J Hand Surg [Am]. 1986 Sep;11(5):645-53 Kato H, Usui M, Minami A. PMID: 3760487
4. Radial shortening for the treatment of Kienböck's disease--a 5- to 10-year follow-up.J Hand Surg [Am]. 1982 Jul;7(4):348-52. Almquist EE, Burns JF Jr. PMID: 7119393
5. Radial osteotomy for late stage Kienböck's disease: Wedge osteotomy versus radial shortening J Bone Joint Surg 2002 Jul;84(5):673-677. Iwasaki N, Minami A, Oizumi N, Suenaga N, Kato H, Minami M. PMID: 12188482
6. Radial osteotomies for teenage patients with Kienböck disease. Clin Orthop Relat Res. 2005 Oct;439:116-122.. Iwasaki N, Minami A, Ishikawa J, Kato H, Minami M. PMID: 16205149
7. Radial shortening osteotomy for treatment of Kienböck's disease. J Hand Surg [Am]. 1991

May;16(3):454-460. Radial shortening osteotomy for treatment of Kienböck's disease. Rock MG, Roth JH, Martin L. PMID: 1861026

8. Radial shortening for Kienböck disease. J Bone Joint Surg Am. 1991 Mar;73(3):384-391. Weiss AP, Weiland AJ, Moore JR, Wilgis EF. PMID: 2002076

9. Scaphocapitate intercarpal arthrodesis. J Hand Surg [Am]. 1991 Mar;16(2):328-333. Pisano SM, Peimer CA, Wheeler DR, Sherwin F. PMID: 2022848

10. Scaphocapitate arthrodesis for the treatment of Kienböck's disease. J Hand Surg [Am]. 1995 May;20(3):506-510. Sennwald GR, Ufenast H. PMID: 7642939

11. Treatment of Kienböck's disease with scaphotrapezio-trapezoid arthrodesis. J Hand Surg [Am]. 1996 Jan;21(1):9-15.Watson HK, Monacelli DM, Milford RS, Ashmead D IV. PMID: 8775190

12. Blood vessel transplantation to bone. J Hand Surg [Am]. 1979 Jan;4(1):23-33. Hori Y, Tamai S, Okuda H, Sakamoto H, Takita T, Masuhara K. PMID: 759500

13. Vascularised bone graft for Kienböck disease: preliminary results. Scand J Plast Reconstr Surg Hand Surg. 2007;41(2):77-81. Hermans S, Degreef I, De Smet L. PMID: 17605440

14. Vascularized capitate transposition for advanced Kienböck disease: application of 40 cases and their anatomy. Ann Plast Surg. 2006 Dec;57(6):637-641. Lu LJ, Gong X, Wang KL. PMID: 17122549

15. Über anatomische Variationen der Handgelenkknochen: Ein Beitrag zur Kenntnis der genese zwei verschiedener Mondbeinveranderungen. Acta Radiol 1928;9:155–168. Hulten O.

16. Kienböck Disease and Negative Ulnar Variance J Bone Joint Surg Am. 1998 Aug;80(8):1154-1157. Bonzar M, Firrell JC, Hainer M, Mah ET, McCabe SJ. PMID: 9730124

17. Overgrowth after Radial Shortening for Kienböck's Disease in a Teenager: Case Report. J Hand Surg [Am]. 2006 Oct;31(8):1322-1325. Herdem M, Ozkan C, Bayram H. PMID: 17027794

18. Kienböck's Disease. In Lichtman DM (ed). The Wrist and Its Disorders. Philadelphia, WB Saunders 1998;329–343. Alexander AH, Lichtman DM.

19. Radial osteotomy for Kienböck's disease evaluated by magnetic resonance imaging: 24 cases followed for 1–3 years. Acta Orthop Scand. 1993 Apr;64(2):207-211. Nakamura R, Watanabe K, Tsunoda K, Miura T. PMID: 8498188

20. Ulnar variance in Kienbock's disease. J Bone Joint Surg Am. 1975 Jul;57(5):674-676. Gelberman RH, Salamon PB, Jurist JM, Posch JL. PMID: 1150712

21. Anatomic variations in radial and ulnar lengths in the wrists of Chinese. Clin Orthop Relat Res. 1971 Oct;80:17-20. Chan KP, Huang P. PMID: 5133324

22. Youm Y, McMurtry RY, Flatt AE, Gillespie TE: Kinematics of the wrist. I. An experimental study of radial-ulnar deviation and flexion-extension. J Bone Joint Surg Am. 1978 Jun;60(4):423-431. Youm Y, McMurthy RY, Flatt AE, Gillespie TE. PMID: 670263

23. Evaluation of Healed Colles' Fractures. J Bone Joint Surg Am. 1951 Oct;33-A(4):895-907. GARTLAND JJ Jr, WERLEY CW. PMID: 14880544

24. Longitudinal growth after nonphyseal forearm fractures. J Pediatr Orthop. 2003 Mar-Apr;23(2):203-207. Carsi B, Abril JC, Epeldegui T. PMID: 12604952

25. Effect of intertrochanteric osteotomy on the proximal femur of rabbits: assessment with power Doppler sonography and scintigraphy. Clinics. 2007 Dec;62(6):741-748. Doria AS, Cunha FG, Modena M, Rodrigues CJ, Garcez AT, Godoy Junior R, Bolliger Neto R, Melo IB, Buchpiguel C, Molnar LJ, Guarniero R. PMID: 18209917

26. Growth and Development of the Distal Radius and Ulna. J Pediatr Orthop. 1996 Sep-Oct;16(5):575-577. Pritchett JW. PMID: 8865039

Figure 1

Click here to download high resolution image

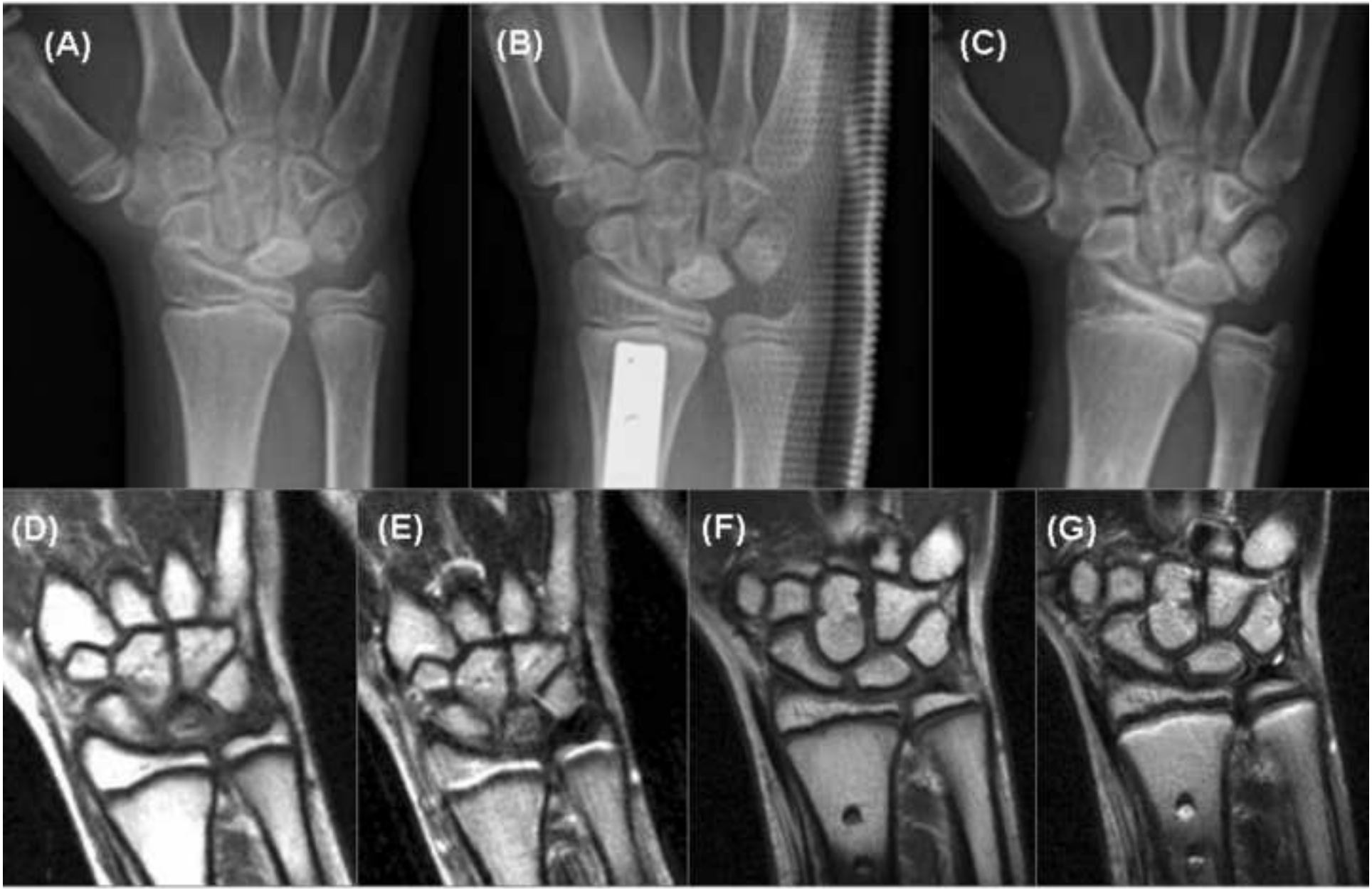

Figure 2
Click here to download high resolution image

Table 1

Table1: Lichtman's stage

Staging	Radiographic assessment
Stage I	Normal except for the possibility of a linear or compression fracture.
Stage II	Definite changes in the apparent density of the lunate.
Stage IIIA	Collapse of the entire lunate at a normal scapholunate angle.
Stage IIIB	Collapse of the entire lunate at a scapholunate angle greater than 60°.
Stage IV	Generalized degenerative changes in the carpus.

Table 2

Table2: Modified Nakamura et al. Scoring System

Clinical Assessment	Points
Pain in the wrist	
None	10
Mild with strenuous activity	7
Mild with light work	4
Grip strength (percentage of unaffected side)	
90%	5
80%	4
70%	3
60%	2
50%	1
Increase in range of flexion and extension	
> 20°	6
10–19°	5
5 –9°	3
Overall grade	**Total points**
Excellent	15-21
Good	9–14
Fair	3–8
Poor	0-2

Table 3

Table3: Radiographic Parameters

Radiographic Assessment	Preoperation	Immediately after operation	Follow-up	
Ulnar variance (mm)	-3.1 ± 1.6	-1.4 ± 1.3	-3.9 ± 2.2	*
Carpal height ratio	0.47 ± 0.04	0.48 ± 0.04	0.48 ± 0.03	
Radial inclination (degree)	23.8 ± 3.9	23.6 ± 3.9	21.5 ± 4.9	
Volar tilt (degree)	10.0 ± 3.1	8.8 ± 2.6	9.9 ± 3.9	

(mean ± standard deviation)

*denotes statistical significance between Immediately after operation's data and Follow-up's data ($P<0.05$)

Table 4

Table4: Changes in Ulnar Variance after Radial Shortening Osteotomy

Case	Preoperative Lichtman's Stage	Age (y)	Follow-up periods (months)	Ulnal negative variance (mm)		
				Immediately after operation	Follow-up	
1	II	12	40	3	6	*
2	II	18	90	1	2	
3	IIIA	11	48	0	4	*
4	IIIA	13	48	4	8	*
5	IIIB	12	113	0	2	
6	IIIB	13	65	1	5	*
7	IIIB	17	38	1	3	
8	IIIB	18	117	0	2	

*denotes overgrowth at follow-up