Chin augmentation by thin cortical bone concomitant with advancement genioplasty

Authors

Kazuhiro Matsushita, Nobuo Inoue*, Hiro-o Yamaguchi, Kazuhiro Ooi, Yasunori Totsuka.

Department of Oral and Maxillofacial Surgery, Division of Oral Pathobiological Science, Graduate School of Dental Medicine, Hokkaido University.

*Department of Gerodontology, Division of Oral Health Science, Graduate School of Dental Medicine, Hokkaido University.

Corresponding author: Kazuhiro Matsushita

Department of Oral and Maxillofacial Surgery, Division of Oral Pathobiological Science, Graduate School of Dental Medicine, Hokkaido University

N13 W7, Kita-ku, Sapporo, Hokkaido 060-8586, Japan

E-mail: matsushi@den.hokudai.ac.jp

Abstract

Genioplasty is a commonly performed procedure and various modifications of the technique have been described. One postoperative complication after advancement genioplasty is resorption of the genial segment, occasionally leading to so-called witch's chin appearance when combined with a deep labiomental fold. To prevent this condition, bone grafting onto the advanced genial segment is commonly performed. This method, however, should necessitate grafting of a certain volume of block bone or autologous bone marrow. The donor site should be set up, occasionally even far from the recipient site such as iliac bone. We present two cases in which a novel augmentation technique was taken. Thin cortical bone was harvested from the upper frontal sharp edge of the genial segment, where the sharp edge was sometimes reduced with a bur to avoid irritating surrounding tissues. This harvested bone was placed onto the advanced genial segment obliquely in the sagittal plane, just like covering the gap. Vacant space was made under the thin cortical bone. Neither particulate bone nor any substances were packed into the vacant space, instead keeping the space open. At least 8 months after augmentation, the space was filled with newly formed bone. This phenomenon

indicated that voluminous bone is not always required, but preparing adequate environmental circumstances for bone formation is crucial and integral. This method may bring about a new concept of the bone grafting and augmentation.

Introduction

The chin plays a prominent role in establishing not only esthetics, but also function. Incompetent lip seal and tension of the mentalis muscle in swallowing can be annoying symptoms. Genioplasty is one of the options for addressing chin deformity and dysfunction caused by shape[1]. As for postoperative complications, resorption of grafted bone and a deep labiomental fold are sometimes seen. Lateral wings of the genial segment are apt to be resorbed, occasionally leading to so-called witch's chin appearance[2] if combined with a deep labiomental fold. To overcome this problem, various strategies have been reported[3]. We describe herein a novel method to build up the chin structure with a desirable labiomental fold using thin cortical bone alone. We generally do not expose the surgical site postoperatively simply for the sake of confirming bony union, so we usually depend on radiography or computed tomography (CT). However, we had the opportunity to see firsthand the actual state of bony union in these cases when subsequent anterior subapical alveolar osteotomy was performed several months later. We report two cases in which substantial bone augmentation was achieved.

Case 1

A 34-year-old woman visited our department with a chief complaint of masticatory dysfunction and incompetent lip seal. Marked micrognathia was seen with labial inclination of the mandibular incisor (Fig. 1). The genial site was exposed by gingival sulcus incision in an ordinary mannar[1] and the osteotomy was performed approximately 5 mm below the mental nerve. We advanced the genial segment 10 mm forward into the desired position and stabilized with three poly-L-lactic acid (PLLA) bone screws (Fixsorb-MX; Takiron, Osaka, Japan). We then chamfered the upper frontal edge of the genial segment on both sides using a reciprocal saw, where the edges stuck out, by sliding the genial segment anteriorly. These thin cortical bones were individually smoothly and symmetrically positioned onto the osseous gap created at the osteotomy line, and ligated to the genial segment with thread (Figs. 2-4). The cavity bounded by thin cortical bone graft, osteotomy stump of the genial segment and labial surface of the mandible was kept open with no filling at all. Finally, the elevated periosteum and soft tissues were closed in layers.

About 8 months after genioplasty, chin projection was marked with a proper labiomental fold. Volume and texture were seen to be completely satisfactory when subsequent mandibular subapical alveolar osteotomy was performed (Fig. 5). Lateral cephalography demonstrated bone formation in the former vacant space (Fig. 6). CT confirmed these observations (Fig. 7). After finishing pre-surgical orthodontic treatment, bimaxillary surgery was performed to establish desirable occlusion. About 2 years later, bone formation was also completed at the horizontal osteotomy line of the alveolar segment (Fig. 8).

Case 2

A 17-year-old girl was referred to our department with a chief complaint of masticatory dysfunction. She showed a marked micrognathia with anterior crowding of the mandibular dental arch (Fig. 9). Total arch discrepancy of the lower teeth was -22 mm. We planned to make space to accommodate the crowded teeth by distraction osteogenesis of the anterior alveolar segment. To ameliorate the reduced chin and construct the infrastructure for anterior movement of the alveolar segment, we advanced

the genial segment 8 mm by genioplasty in the early stage of presurgical orthodontic treatment. The genial segment was fixed with three PLLA screws using a lag screw technique. A titanium plate was added to strengthen the fixation. Thin cortical bone was harvested and grafted using the same method described in Case 1. Lateral cephalography performed about 4 months after genioplasty demonstrated only faint radio-opacity in the former vacant space (Fig. 10). We performed subsequent mandibular subapical alveolar osteotomy for distraction osteogenesis of the anterior dentate segment. We directly observed the proper structure of the chin without gaps. The horizontal osteotomy line was 5 mm under the dental apices, slightly above the edge of the grafted bone, and the vertical osteotomy line was between the lateral incisor and canine, on both sides. Distraction length was about 5 mm anteriorly (Fig. 11). About 2 years later, the initially vacant space was completely filled with bone (Fig. 12). Finally, bimaxillary surgery was performed to establish desirable occlusion.

Discussion

Postoperative resorption of the augmented chin at the lateral wings of the genial

segment together with an inappropriate labiomental fold results in a chin structure relatively similar to hyperprojection of the mandible. This witch's chin deformity, first described by Gonzalez-Ulloa[2] in 1972, comprises ptosis of premental soft tissue with an accentuated submental crease. Witch's chin is initially a deformity of the soft tissue. However, the configuration of soft tissue is often influenced by the underlying bone structure. Thus, the relatively narrow anterior projection of the chin induced by the lateral resorption of the grafted bone at the genial segment, in combination with a deep labiomental fold, can result in the appearance of a witch's chin.

In order to augment and preserve a preferable configuration, insertion of an artificial object is occasionally performed. Non-absorbable silicone implants have been widely used for many years, but silicone display intrinsic problems such as bone erosion[4, 5] and extrusion[6]. The relatively high incidence of infection is also problematic. We have therefore utilized autologous osseous objects, but have sometimes been obliged to harvest excess bone out of fear of later resorption. Iliac crest[6], cranium and tibia[7] have been popular as donor sites for bone graft, and costal bone[8] and even nasal osteocartilage[9] are also suitable for chin graft. Harvesting from the oral cavity such as

retromolar[10] and ramus[11] bone is also frequently performed. The common denominator in all of these procedures is the use of a certain volume of block bone. Bell et al.[1] reported bone augmentation using a different method, placing an autogenous particulate marrow graft between the osseous gaps created between segments to stimulate osteogenesis and enhance the esthetic result. The present method, however, differs substantially from these previous reports. The essence of our method is to create a favorable environment for bone formation. Utilization of thin cortical bone is just one of the methods to achieve this outcome.

The concept of our method may have something in common with that of guided bone regeneration (GBR) from as far back as in 1959[12] and guided tissue regeneration (GTR) as described by Nyman[13] in 1982. GBR and GTR were originally based on the same principles of using barrier membranes for maintaining space over a defect, preventing significant amounts of connective soft tissue from entering the defect and at the same time allowing the passage of osteogenic cells. Although our method seems to use the same biologic rationale as the above two regeneration techniques from the perspective of using a barrier, the creation of a proper environment by using autologous material

facilitates bone augmentation after grafting, thus representing a methodological departure from previously conventional techniques. A more physiological reaction of bone formation is expected compared to use of a barrier membrane. We speculate that the mechanism of bone formation is as follows: the gap, namely the cancellous bone stump, enables mesenchymal progenitor cells to infiltrate into the vacant space formed by thin cortical bone and proliferate as active chondrocytes. Migrating mesenchymal progenitor cells from the covering periosteum, muscles and endothelial capillaries of newly formed blood vessels[14] and stem cells from the bone marrow, together with growth factors, may have contributed to endochondral ossification under the appropriate environmental circumstances. This method offers great potential not only from the perspective of using autologous material, but also in effective use of the laterally protruded portion of the genial segment, which is sometimes reduced using a bur or resorbed spontaneously over time.

We have described two representative cases with different periods of cancellous bone formation. Such differences appear to reflect factors such as size of the stump, vacancy volume, and vascularization, but also indicate that bone formation should naturally

occur soon or later if proper environmental circumstances are prepared for osteogenesis.

We again emphasize the benefit of thin cortical bone grafts when advancement genioplasty is performed. This method is, in fact, one of our inventions in staged operations for micrognathia, comprising advancement genioplasty, subapical alveolar osteotomy and bimaxillary surgery, in that order. We consider that this method is not only of great value to chin augmentation, but also can be applied to bone grafts at other sites in the oral cavity. Preparation should be made to secure favorable environmental circumstances for osteogenesis.

Figure 1: Preoperative lateral cephalogram showing skeletal class II malocclusion with labial inclination of the lower incisors and reduced chin.

Figure 2: Schematic representation of the osteotomy and bone graft. After stabilization of the genial segment with three bioresorbable screws, two thin cortical bone grafts were harvested from the right and left anterior edges of the lateral wing of the genial segment. These grafts were transferred onto the gap smoothly and symmetrically, and fixed to the genial segment using thread. T dotted line indicates the area of bone harvesting.

Figure 3: Intra-operative image demonstrating advancement of the genial segment and thin cortical bone graft. The donor site is not visible, lying just under the oral mucosa at the external border of the incision line. Each harvested thin cortical bone graft was sutured to the genial segment with threads for immobilization.

Figure 4: Lateral cephalogram showing thin grafted bone on the genial segment. The

cavity bounded by grafted thin cortical bone, the osteotomy stump of the genial segment and the labial surface of the mandible was kept open.

Figure 5: About 8 months postoperatively, bony union was completed and robust chin structure was observed. The patient underwent subapical alveolar osteotomy to correct labial inclination of the incisors.

Figure 6: Lateral cephlography showing bone formation.

Figure 7: CT confirming integration of robust bone and desirable anteroposterior diameter.

Figure 8: Final appearance of debond. Proper chin structure was achieved. Neither osteotomy line nor vacant space were observed.

Figure 9: Preoperative lateral cephalography showing marked micrognathia. Overjet

was 14.3 mm.

Figure 10: Lateral cephalography showing advancement genioplasty and thin cortical bone graft. Obvious bone formation was not observed in the former vacant space as of 4 months after advancement genioplasty.

Figure 11: Completion of alveolar osteotomy followed by distraction. Thin cortical bone graft was recognized just under the dentate segment.

Figure 12: Complete bone formation was observed in the former vacant space prior to bimaxillary surgery.

References

1. Bell WH: Surgical correction of dentofacial deformities. Vol 1(ed 1). Philadelphia, PA, Saunders, 1980, p60

2, Ward J, Podda S, Garri JI, Wolfe SA, Thaller SR: Chin deformities. J Craniofac Surg 18: 887, 2007

3. González-Ulloa M: Ptosis of the chin. The witches' chin. Plast Reconstr Surg 50: 54, 1972

4. Friedland JA, Coccaro PJ, Converse JM: Retrospective cephalometric analysis of mandibular bone absorption under silicone rubber chin implants. Plast Reconstr Surg 57: 144, 1976

5. Matarasso A, Elias AC, Elias RL: Labial incompetence: a marker for progressive bone resorption in silastic chin augmentation. Plast Reconstr Surg 98: 1007, 1996

6. McCarthy JG, Kawamoto H, Grayson BH, Colen SR, Coccaro PJ, Wood-Smith D: Plastic Surgery. Philadelphia, PA, Saunders, 1990, p1305

7. Tolman DE: Reconstructive procedures with endosseous implants in grafted bone: a review of the literature. Int J Oral Maxillofac Implants 10: 275, 1995.

8. Converse, JM: Restoration of the facial contour by bone grafts introduced through the oral cavity. Plast Reconstr Surg 6: 295, 1950

9. Mottura AA: Chin augmentation with nasal osteocartilaginous graft. Plast Reconstr Surg 109: 783, 2002

10. Nkenke E, Radespiel-Tröger M, Wiltfang J, Schultze-Mosgau S, Winkler G, Neukam FW: Morbidity of harvesting of retromolar bone grafts: a prospective study. Clin Oral Implants Res 13: 514, 2002

11. Misch CM: The harvest of ramus bone in conjunction with third molar removal for onlay grafting before placement of dental implants. J Oral Maxillofac Surg 57: 1376, 1999

12. Hurley LA, Stinchfield FE, Bassett AL, Lyon WH: The role of soft tissues in osteogenesis. An experimental study of canine spine fusions. J Bone Joint Surg Am 41-A: 1243, 1959

13, Nyman S, Lindhe J, Karring T, Rylander H: New attachment following surgical treatment of human periodontal disease. J Clin Periodontol 9: 290, 1982

14, Mardas N, Kostopoulos L, Stavropoulos A, Karring T: Evaluation of a

cell-permeable barrier for guided tissue regeneration combined with demineralized bone matrix. Clin Oral Implants Res 14: 812, 2003

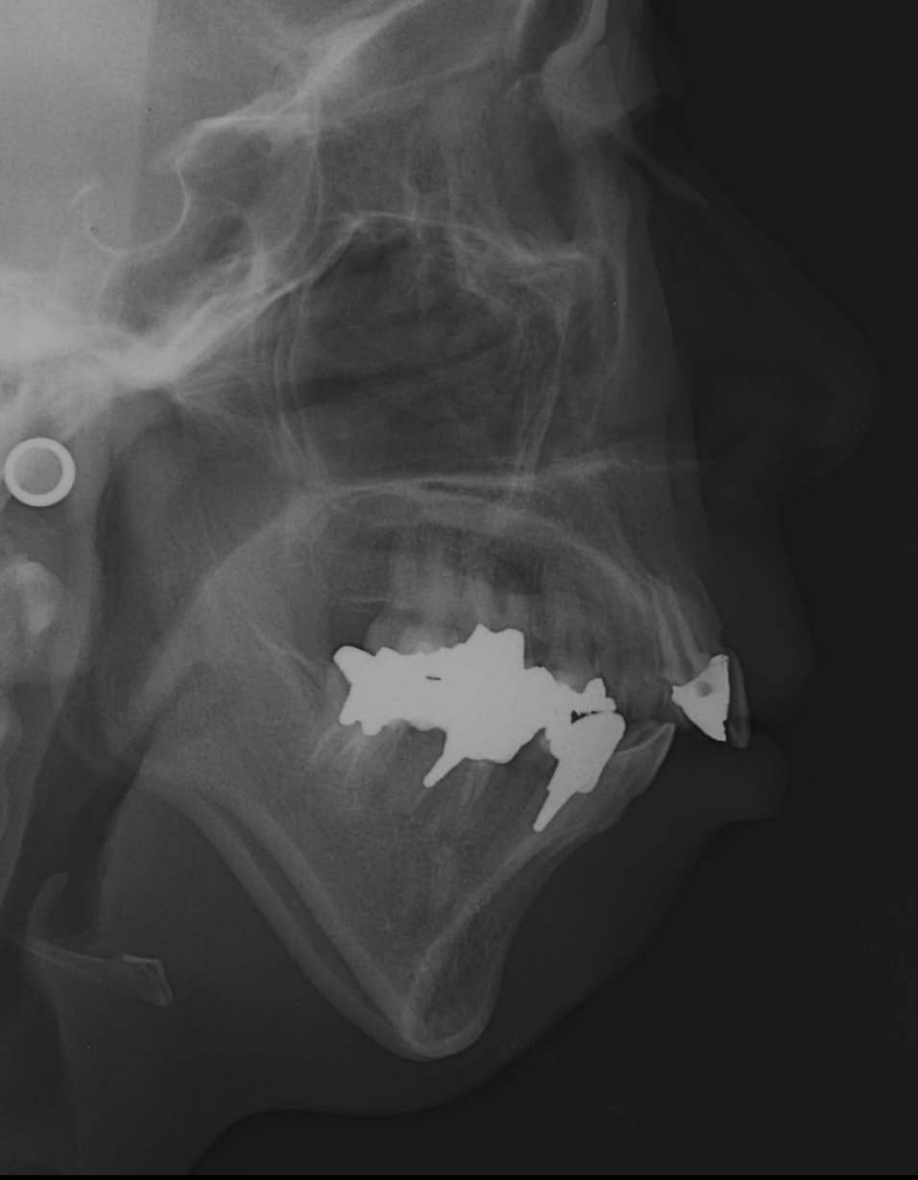

Fig. 1

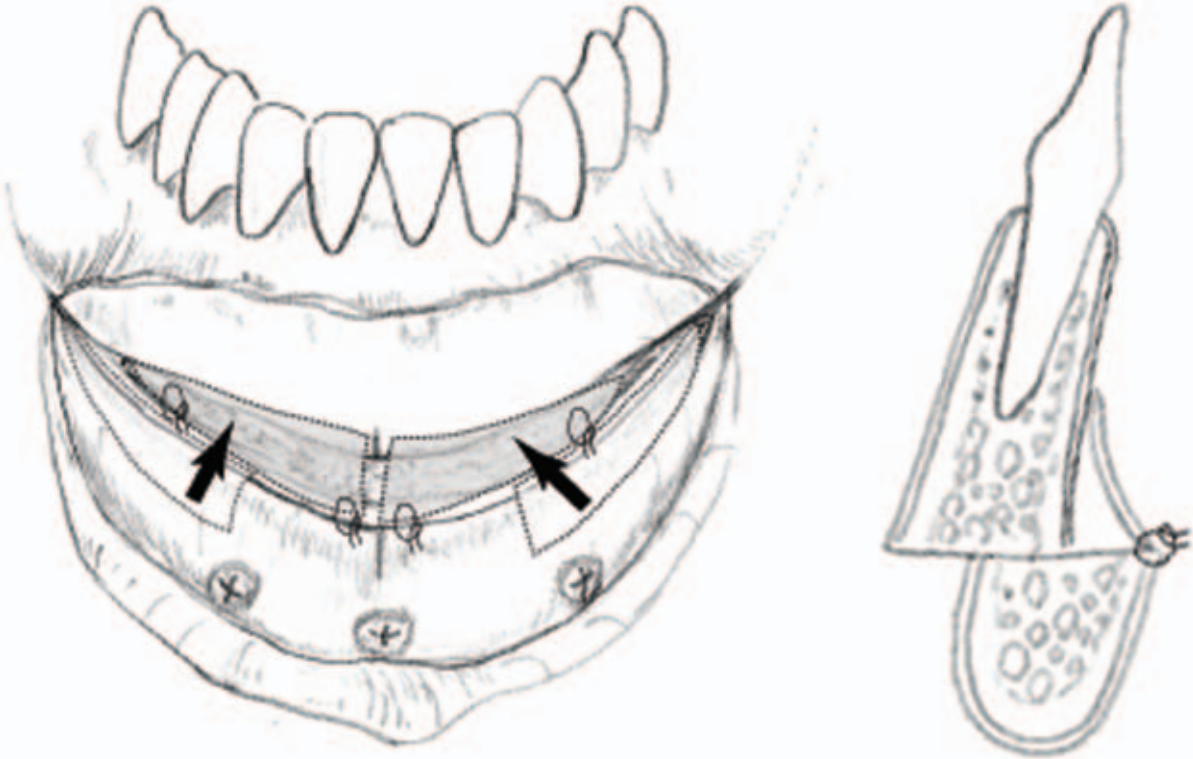

Fig. 2

Fig. 3

Fig. 4

Fig. 5

Fig. 6

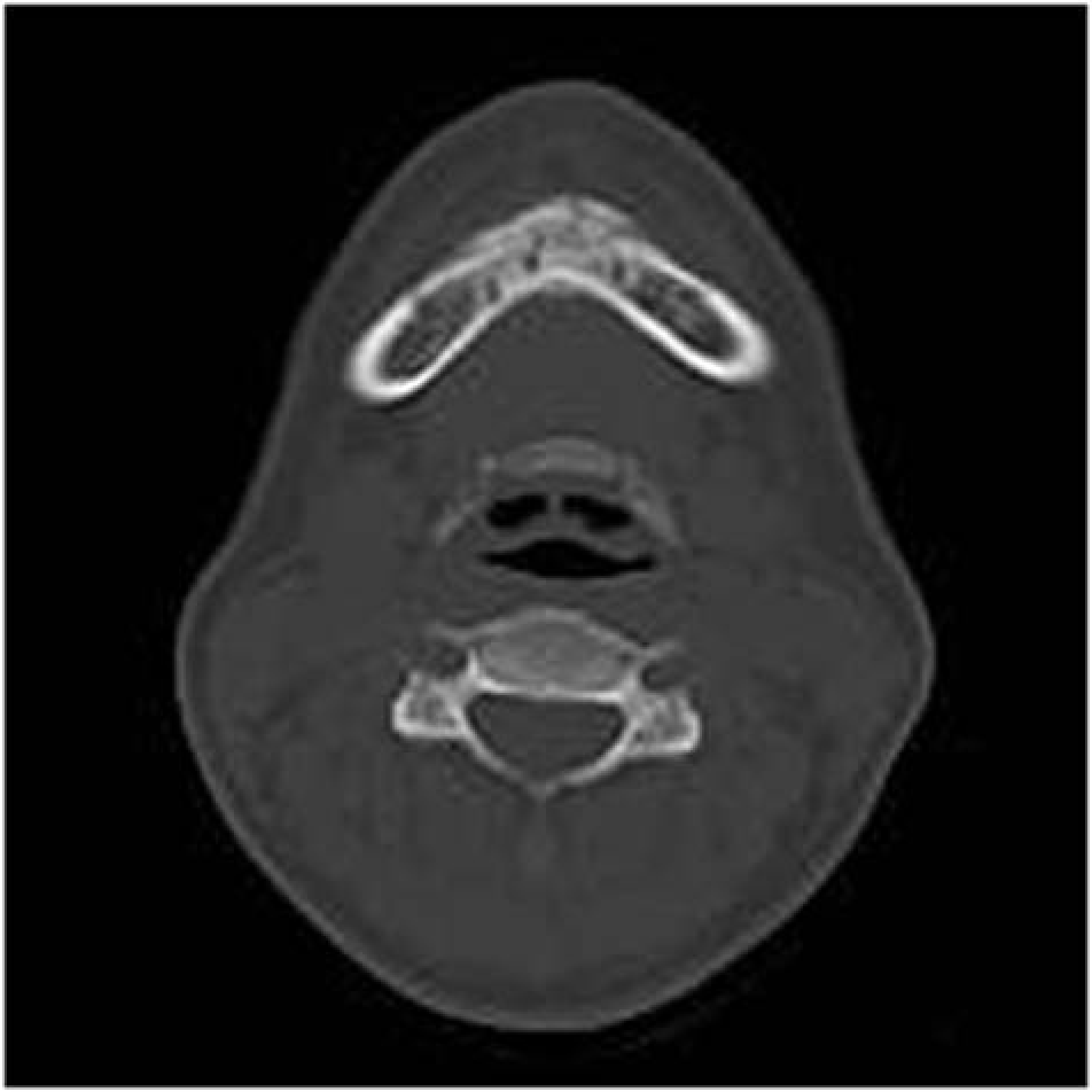

Fig. 7

Fig. 8

Fig. 9

Fig. 10

Fig. 11

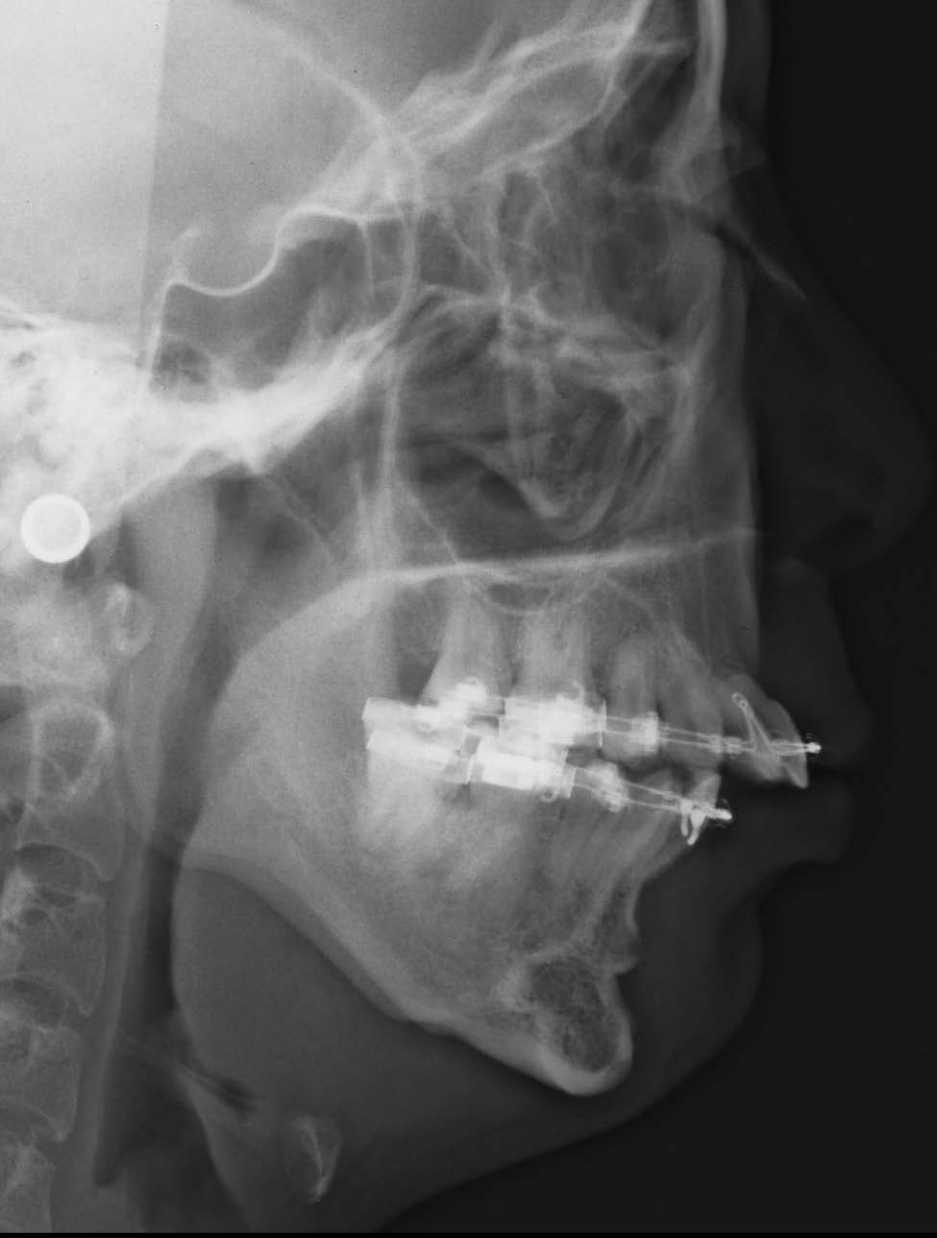

Fig. 12