GASTRIC EROSION IN HORSES AFFECTED WITH JAPANESE ENCEPHALITIS

Saburo YAMAGIWA*, Yutaka FUJIMOTO*,
Kan-ichi OHSHIMA*, Hiroshi SATOH*,
Shizuma SUGANO**
and Jun-ichi USHIJIMA***

(Received for publication, January 7, 1959)

INTRODUCTION

The senior author and coworker have, in a previous report[5], already described briefly how they had often encountered noteworthy lesion in *pars oesophagea* in stomach during the course of investigation on Japanese encephalitis in horses at Department of Veterinary Pathology of Hokkaido University. As this lesion is considered to be important not only respecting the pathology of Japanese encephalitis, but also in pathologico-anatomical diagnosis, the present authors, taking this opportunity, would like to describe its histopathological aspects. Except SHIMADA and TANAKA who laid emphasis on erosion and small ulcer in an infantile case of encephalitis (3 years and 3 months of age), there has been no report on the subject under reference according to the literature.

Of a total of 14 cases discussed in this report, 7 with the subject lesion were obtained during the course of investigation of viscera[3] on 56 "epidemic-year" cases which were used for the study of neuro-histopathology of Japanese encephalitis in horses by TAJIMA of our Department. The remaining 7 which manifested the lesion were obtained from among 19 cases affected with Japanese encephalitis in non-epidemic year. Of these 19 cases, histological findings on the central nervous system of 18 cases have already been reported[5]. Since the clinical findings of non-epidemic year cases have been described in the previous report they are omitted from this paper.

FINDINGS ON MATERIALS INVESTIGATED

Case No. 1: Pr. 3632 (Non-epidemic Year Case No. 6)

Ogifushi-mura, Urakawa-gun, Hokkaido; ♂; 4 years of age; 36 hours of course.

Stomach

* *Department of Veterinary Pathology, Faculty of Veterinary Medicine, Hokkaido University, Sapporo.*
** *Laboratory of Veterinary Pathology, Faculty of Agriculture, Gifu University, Gifu.*
*** *Laboratory of Veterinary Hygiene, College of Dairy Farming, Ebetsu.*

Macroscopical findings: Pale and smooth serous surface; dirty aqueous substance in medium quantity accompanied by bloody color; mucosa of *pars glandularis* shows no circumscribed focus; *pars oesophagea* shows irregularly rounded or belt-like mucosal defects in various sizes showing fresh lesions, some of which manifest red spots on the surface.

Microscopical findings: Preparation 1 (section manifests three depressions: 0.8 cm in diameter (a), 0.1 cm in diameter (b) at 0.5 cm from (a) and 0.2 cm in diameter (c) at 0.5 cm from (b)).

(a): The superficial mucosa and *lamina muscularis mucosae* are lacking for the most part; *lamina muscularis mucosae* is left only in marginal portions; coinciding with the focus, there exists a clearly-demarcated edematous area which reaches *tunica muscularis* at its deepest portion; large and small blood vessels dilated and are filled with fibrinous thrombi and coagulated blood; as the walls of blood vessels themselves become edematous, the distinction and the characteristics of artery and vein are not obviously observable; focal hemorrhages; mucosal epithelium attaching to the margin of the focus shows necrobiosis, where *tunica propria* shows severe edema and small blood vessels contain thrombi. Wandering cell reaction is stratiformly observed in the profound layer of mucosal epithelium (Fig. 1).

(b): This depression taking the shape of a bowl, and the bottom of which reaches *lamina muscularis mucosae*; mucosal epithelium loses keratinized layer and shows necrobiosis in all layers; in the lower half layer, karyo-pyknosis is still observed clearly; *tunica propria* become edematous and branches of small arteries contain fibrinous thrombi nearly at the center of depressed portion; even in superficial mucosa which changed into necrobiosis, small blood vessels contain 2 or 3 masses which are regarded as thrombi.

(c): Is a somewhat large type of (b)-lesion; the characteristics of central and marginal portions resemble those of (a) and (b) respectively; a good many white thrombi in various sizes are observed in depressed necrobiotic tissue with severe edema.

Preparation 2 (section manifests defected mucosal epithelium of 0.6 cm in diameter (a) adjacent to *margo plicatus*, and another of 0.3 cm in diameter at 0.7 cm from (a)).

(a): *Tunica propria* is exposed on the defected surface and changes into necrobiosis leaving the lower layer of *tunica propria* attached to the *lamina muscularis mucosae*; fragments of mucosal epithelium remain at 2 or 3 places; a good many separating thrombi are observed in small blood vessels; necrobiotic portion manifests edema, and many wandering cells are found.

Case No. 2: Pr. 2641 (Epidemic Year Case No. 7)

Shinoro-mura, Ishikari-gun; ♂; 1 year of age; 2 days of course.

Clinical symptoms: Was returned to stable at about 11 a. m., on 10/IX '48, but did not suck the milk; manifested lethargic state; was released to the field with mother horse in the afternoon but showed no appetite; a veterinarian was consulted at 8. 30 p.m., at which time the animal had no appetite, showed clockwise circling movement as well as severe perspiration and gnashing. 11/IX— showed abnormal posture with circling movement and raising head almost throughout the day; killed for the purpose of examination.

Neuro-histopathological diagnosis: Encephalitis in transitional stage.

Stomach

Macroscopical findings: Pale serous surface; contains watery mash-like substance of icterous color in small quantity; mucosa manifests areas of substance defects between the size of a rice grain and a cherry at the portion adjacent to cardia of which surrounding shows bank-like elevations some of which are stained in blood color; 3 *Gastrophilus* larvae; in contact with the boundary between *pars oesophagea* and *pars glandularis,* mucosa of *pars oesophagea* shows an egg-size superficial ulcer.

Microscopical findings: Preparation 1 (Base of large ulcer — 2 cm in diameter): Mucosal epithelium becomes necrobiotic and barely shows its proper structure; the layer of demarcating inflammation rich in wandering cells exists adjacent to *tunica propria*; the deeper portion of the ulcer reaches *tunica muscularis*; large and small blood vessels and lymph vessels near by such lesions distended and contain hyaline and fibrinous thrombi; the wall of artery of large diameter located at *tunica propria* manifests fibrinoid swelling; surrounding sound tissue shows clear boundary.

Preparation 2 (Continuation of preparation 1 — manifests substance defects (a) of 1.2 cm diameter and (b) 0.1 cm diameter, 0.3 cm from (a)).

(a): The characteristics resemble those of preparation 1; many wandering cells are found in necrobiotic area.

(b): Contacts mucosa of *pars glandularis* and shows fresh necrobiosis of mucosal epithelium of *pars oesophagea*; active leucocytic infiltration is observed adjacent to *tunica propria*; small blood vessels there contain separating thrombi; marginal portions of the focus are clearly demarcated from surrounding mucosal epithelium of *pars oesophagea* and *pars glandularis.*

Preparation 3 (Obtained from the area of ulcer in parallel with preparation 1 and 2 manifests substance defect areas (a) of 0.2 cm, (b) 0.1 cm and (c) 1.5 cm).

(a): Characteristics are the same as in preparation 1.

(b): Characteristics are the same as in preparation 2 (b).

(c): Mucosal epithelium becomes necrotic and leucocytic infiltration is observed equally in *tunica propria* and *lamina muscularis mucosae*; many small blood vessels in mucosal epithelial layer contain thrombi; *tela submucosa* is edematous and large, small focal areas rich in fibrinous threads are observed (fibrinoid swelling of connective tissue fibers).

Preparation 4 (Continuation of preparation 3 — manifests substance defect of 1 cm length, 0.5 cm from *margo plicatus*): Characteristics are the same as preparation 1.

Case No. 3: Pr. 3018 (Epidemic Year Case No. 13)

Ogifushi-mura, Urakawa-gun; ♀; 2 years of age; 3 days of course.

Clinical symptoms: 27/VIII'50 — the animal was reluctant to come out of stable against the rein in the morning; when dragged out to the pasture, it showed clockwise circling movement; lost thirstiness and appetite by noon and stood still; a veterinarian was consulted at 6.30 p. m.; T. 39.2°C; respiration and pulse normal; depression; dimness of vision; upper lip was twisted to left by facial paralysis; paralyzed tongue. 28/VIII — similar symptoms. 29/VIII — complete loss of thirstiness and appetite; stood still vacantly with head leaning against the wall; skin reflex and back sensibility became dull; eyelid and anal reflex became slightly dull; tail resistance could hardly be found; mydriasis and

loss of eyesight; salivation and halitosis; slight gnashing; T 36.9°C; reduction of intestinal peristalsis; no abnormality on heart sounds and alveolar murmur; killed; had not been inoculated with vaccine for encephalitis.

Neuro-histopathological diagnosis: Encephalitis in transitional stage.

Stomach

Macroscopical findings: Pale serous surface; nearly empty; two mucosal defects of thumb and little finger tip size at *curvatura major* of *pars cardiaca*; the defect area shows irregular surface and dirty yellowish red color.

Microscopical findings: Preparetion 1 (Ulcer of 0.7 cm diameter at 1.5 cm from *margo plicatus*): Mucosal epithelium which became necrobiotic is desquamated and defected except the marginal portion of ulcer; edematous from *tela submucosa* to *tunica muscularis* through *lamina muscularis mucosae*; marked swelling of connective tissue fibers and appearance of fibrins are also observed; in *tela submucosa* tissue is loosened and wandering cells increase in number; many fibrin thrombi are contained in large and small blood vessels of mucosal epithelial layer (Fig. 3) and *tunica propria* (Fig. 2); walls of some blood vessels of *tunica propria* and *tela submucosa* show fibrinoid swelling (Fig. 10); eosinophile cell infiltration in the proximity of blood vessels at *tela submucosa*.

Preparation 2 (One substance defect (a) smaller than pin head size, one lesion (b) of 1 cm diameter):

(a) Mucosal epithelium becomes focal necrobiotic and is ready to separate from *tunica propria*; *tunica propria* is loosened containing leucocytic infiltration; the portion of mucosal epithelial lesion contains a few small blood vessels with thrombi; the focus does not reach *lamina muscularis mucosae*.

(b): Mucosal epithelium becomes necrobiotic; shows clear border line with *tunica propria*, but the structure of epithelial layer is indistinguishable; wandering of infiltrating cells in profound layer of mucosal epithelium; *lamina muscularis mucosae* can hardly be identified being buried in edematous changes which extend from *tunica propria* to *tela submucosa*, except at a partial marginal portion; remarkable fibrinoid swelling of connective tissue fibers and fibrin separation; fibrinoid swelling is observed in the wall of large blood vessels of *tunica propria* and *tela submucosa* (Fig. 11); outstanding eosinophile cell infiltration around the blood vessels.

Case No. 4: Pr. 3636 (Non-epidemic Year Case No. 11)

Iwamizawa; ♂; 5 years of age; 3 days of course.

Stomach

Macroscopical findings: Pale serous surface; blood vessels dilated in a medium amount; contains a little quantity of ingesta; mucosa itself presents pale color; many irregularly-shaped ulcers in various sizes up to broad beans in *pars oesophagea* showing clear demarcation; no hyperemia, but every lesion manifests remarkable gelatinous edema on the wall.

Microscopical findings: Preparation 1 (A depression of 1.6 cm in diameter with fairly flat surface): Mucosal epithelium becomes necrobiotic; many pieces remain of non-necrotic tissue of profound epithelial layer sporadically; many small blood vessels

with thrombi exist in the area of necrotic tissue and are presented as vertical sections running nearly perpendicular to the surface; thin layer comprised of infiltrated cells between the epithelial layer and *tunica propria*; the walls of some large sized veins in *tunica propria* and *tela submucosa* show fibrinoid swelling (Figs 8 & 9), and these layers manifest severe edema change as thick as 0.5 cm; remarkable lymph thrombosis in *tela submucosa*.

Preparation 2 (1.5 cm in diameter, a depression with minute depressions; is located near *pars glandularis*): Characteristics resemble those of preparation 1; the focus is defective portion of mucosal epithelium, in which areas of mucosal epithelium remain sporadically.

Case No. 5: Pr. 2644 (Epidemic Year Case No. 15)

Eniwa-cho, Chitose-gun; ♀; 3 years of age; 4 days of course.

Clinical symptoms: 14/IX′48—no appetite; depression and abnormal gait gathering 4 legs; counterclockwise circling movement in the stable. 15/IX—alternative excitement and depression of every other 5~10 minutes; atrocious fit at or about 11.00 p. m. 16/IX—excitement appeared as the animal laid down with 4 legs bound; T. 40.0°C; P. 90; A. 52. 17/IX killed.

Neuro-histopathological diagnosis: Encephalitis in transitional stage.

Stomach

Macroscopical findings: A small quantity of contents; mucus contains sand grains; no remarkable changes on mucosal surface but *pars oesophagea* in its various portions manifests shallow mucosal desquamations.

Microscopical findings: A defect of mucosal superficial layer of 0.2 cm diameter adjacent to *pars glandularis*; some of deep portion of mucosal epithelium remain; to some portions of the defected surface is attached necrobiotic substance, in which 2 or 3 thrombi are contained in small blood vessels; no remarkable changes in *tunica propria* and *tela submucosa*.

Case No. 6: Pr. 3697 (Non-epidemic Year Case No. 12)

Fukagawa-cho, Uryu-gun; ♂; 13 years of age; 4 days of course.

Stomach

Macroscopical findings: Contains a medium quantity of aqueous contents which is mingled with a little ingesta; blood vessels of serous surface show slight congestion; pale mucosa; superficial substance defects, size from red beans to lentils, along the *curvatura major* of *pars oesophagea*; clearly demarcated and no proliferation of granulation tissue.

Microscopical findings: A shallow depression of 1.6 cm diameter at the distance of 0.7 cm from *pars glandularis*; necrotized and defected as if superficial mucosal layer were flatly scraped off; pieces of epithelial deep layer remain taking an island-like shape and are buried at the boundary within *tunica propria* (Fig. 6); *tunica propria* remarkably increases its thickness and many a wandering cell is observed diffusely; the fibers of connective tissue show fibrinoid swelling and also show portions deeply stained with eosin diffusely or focally; in large and small blood vessels (even in layer of mucosal epithelium fallen in necrobiosis) separating thrombi are observed at every portion; lymph thrombi

are also found; fibrinoid swelling with a fairly large diameter is observed on the walls of blood vessels; pathohistological changes of *tunica propria* distinctly appear even in *tela submucosa* beyond *lamina muscularis mucosae* and extend to sound *tela submucosa* which is adjacent to eroded portion.

Case No. 7: Pr. 2657 (Epidemic Year Case No. 26)

Kotoni-cho, Sapporo; ♀; age unknown; 5 days of course.

Clinical symptoms: 23/IX′48—anorexia. 24/IX—when delivering milk to the station, the animal kept on going to the right; showed a strong clockwise circling movement at night and stumbled easily; anorexia. 25/IX—the fore half of the body bent to the right; T. 39.0°C; P. 58. 26/IX—T. 39.2°C; excitement became severe; no urination and evacuation from the onset of the illness. 27/IX—began rushing about from midnight. 28/IX—died at 4.00 a. m.

Neuro-histopathological diagnosis: Encephalitis in transitional stage.

Stomach

Macroscopical findings: Contains a little quantity of aqueous substance.

Microscopical findings: Shows a shallow erosion of 2 cm in diameter; superficial mucosa seems to have been scraped off; pieces of deep layer of mucosal epithelium remain forming an island-like shape; *tunica propria* becomes thicker and is rich in fibrocytes; small blood vessels are clearly shown because of swollen endothelial cells; contains a few wandering cells; *tela submucosa* shows slight edema.

Case No. 8: Pr. 3021 (Epidemic Year Case No. 28)

Mukawa-mura, Yufutsu-gun; ♀; 2 years of age; 5 days of course.

Clinical symptoms: 30/VIII′50—showed anorexia and depression from the evening; stood still vacantly; T. 41.0°C. 1/IX—a veterinarian was first consulted; appetite completely lost; head was deeply dropped down while standing still vacantly and sometimes both ears showed tremor; intermittent convulsions appeared all over the body; amblyopia and gazing; restless countenance; mydriasis; T. 39.2°C; P. 48; A. 10~12. 2/IX—general conditions were almost the same as the previous day, but the animal was apt to lie down after bending fore knees as if it fell down; eyes were always open to the half and showed lethargic conditions; head and side of neck showed almost normal tangibility which was weakened in other parts of the body; reflex of eyelid was lost; it leaned against the wall while standing; T. 39.0°C; P. 70; A. 24. 3/IX—the animal rushed about and tried to come out over the stable bar at night, and later regained lethargic conditions; killed; no encephalitis vaccine had been given.

Neuro-histopathological diagnosis: Encephalitis in transitional stage.

Stomach

Macroscopical findings: Pale and smooth serous surface; no contents; dense mucus of whitish-grey color envelopes mucosa surface; a hand-sized defect of mucosa of *pars cardiaca* at *curvatura major* and *tela submucosa* is exposed; the portion affected remarkably increases its thickness and manifests yellowish gelatinous infiltration; mucosa of *pars pylorica* is generally swollen and congested.

Microscopical findings: Shows a flat and superficial depression of 3.5 cm diameter,

at 0.7 cm from the *pars glandulais*; whole mucosal epithelium falls in necrobiosis; which causes mucosa epithelium to come off leaving deep mucosa fragments in spots; a thin layer consisting of degenerated cells accompanied by wandering cells is observed at the boundary portion adjacent to *tunica propria*; *lamina muscularis mucosae* is buried in between *tunica propria* and *tela submucosa* which show severe edematous conditions; both layers jointly reach 0.5 cm in thickness, large and small blood vessels of which frequently contain separating thrombi (Fig. 4) while many a blood vessel shows fibrinoid swelling on the walls (Fig. 12); some of the walls of the blood vessels show hemorrhage; numerous wandering cells are observed diffusely in edematous tissue, and outstanding eosinophile accumulation is observed perivascularly.

Case No. 9: Pr. 3637 (Non-epidemic Year Case No. 14)

Iwamizawa; ♀; 13 years of age; 5 days of course.

Stomach

Macroscopical findings: Contains a great quantity of normal ingesta; pale and smooth serous surface; pale mucosa; 2 or 3 irregularly shaped and shallow depressions of size between soybean and the tip of forefinger are located in the area close by boundary between *pars oesophagea* and *pars glandularis*; hyperemia and others are hardly observed.

Microscopical findings: A flat depression of 1.2 cm diameter appears at 0.6 cm from the border line adjacent to *pars glandularis*; the superficial layer of mucosal epithelium comes off as if it were scraped off leaving a partial profound layer (Fig. 6); *tunica propria* remarkably increased in thickness and connective tissue fibers show fibrinoid swelling; many a wandering cell is observed; many blood vessels and lymph vessels contain fibrin thrombi; the walls of blood vessels manifest fibrinoid swelling; *tela submucosa* shows severe edema and focal fibrinoid swelling; perivascular areas show much eosinophilic cell emigration.

Case No. 10: Pr. 3025 (Epidemic Year Case No. 46)

Kurisawa-cho, Sorachi-gun; ♂; 2 years of age; 7 days of course.

Clinical symptoms: 4/IX'50—anorexia; depression; counterclockwise circling movement from time to time, and no tail resistance. 5/IX—same as above. 6/IX—would not come out of the stable showing hostility; staggered; gnashing sometime. 7/IX—first consultation; T. 40.3°C; facial paralysis; stood vacantly in the stable. 8/IX—T. 38.0°C; stood vacantly; depression; broke out the wall of the stable at night; later became quiet. 9/IX—was unable to stand from the evening; lay down to the right side of the body and often showed swimming-movement. 11/IX—lay down in the same shape as the previous day and often repeated weak swimming-movement; often expanded its fore legs as stiffened; no eyesight; conjunctivae ramiform hyperemia; halitosis; T. 39.4°C; killed; No encephalitis vaccine had been injected.

Neuro-histopathological diagnosis: Encephalitis in non-leucocytic stage.

Stomach

Macroscopical findings: Pale serous surface; completely vacant contents; the mucosa of both *pars cardiaca* and *pars pylorica* slightly swollen and the *pars cardiaca* in the proximity of the *margo plicatus* of *curvatura major* shows substance defect, beans

to hen's egg size, of which surface is black violet in color showing granular appearance and is not flat; clot-like substances are attached to the marginal portion of the defected areas.

Microscopical findings: A shallow depressed area of 1.3 cm diameter at 0.7 cm from other defective area of 0.2 cm diameter, the latter localizes at 0.3 cm from *margo plicatus*; mucosal epithelium becomes necrobiotic and comes off as if it were scraped off, and profound layer of mucosal epithelium is exposed; the mucosa is degenerative in character but tissue structure is clearly observable in some portions; the border line adjacent to *tunica propria* is clearly marked by the existence of a thin layer consisting of karyorrhectic cells and wandering cells; *tunica propria* slightly increased in thickness and wandering cells diffusely infiltrate; many a small blood vessel in these tissues contains the separating thrombi; *tela submucosa* is conspicuously thickened and becomes edematous; many lymph vessels contain thrombi; some part shows remarkable fibrin separation focally, where connective tissue fibers show fibrinoid swelling (Fig. 7).

Case No. 11: Pr. 3765 (Non-epidemic Year Non-reported Case)

Shinkotoni-cho, Sapporo; ♀; 15 years of age; 10 days of course.

Clinical symptoms: 15/IX' 57—circling movement in the morning. 17/IX—consultation; depressions; loss of appetite; abrasions on the face; severe hyperemia of the conjunctivae; muffled cardiac sounds; extremely weakened pupillary reflex; slightly paralyzed upper and lower lips; calm intestinal peristalsis; urinary protein—+; urinary sugar—++; blood cell count—R 7,980,000, W 9,000. 20/IX—appetite was regained as if recovery would occur. 24/IX—suddenly went wild in the afternoon for an hour and a half; later asthenia of the hind quarters made the animal unable to stand; unconsciousness at 3.20 p. m.; died at 4.30 p. m.; encephalitis vaccination had already been given (detailed clinical findings were obtained through the good offices of the Department of Veterinary Internal Medicine of Hokkaido University Veterinary Hospital).

Neuro-histopathological diagnosis: Japanese encephalitis which failed to demonstrate histological encephalitis changes; plexus-cholesteatosis.

Stomach

Macroscopical findings: Gastric contents are well masticated, but stomach was inflated with ingesta with acid smell; the mucosa of *pars oesophagea* contains irregularly shaped substance defect area, 2.5×1.5 cm, along the border line between the mucosae of *pars oesophagea* and *pars glandularis* in *curvatura minor*; in the vicinity of the latter one other substance defect of 1.0×0.5 cm size exists (Fig. 13); the degree of the lesions is slight and permits yellowish white fibrinous precipitations attached to the lesions; circumference is sharply demarcated; contains 2 other substance defect areas of match-split size and of 2 cm length by several millimeter width respectively; *pars glandularis* generally shows clear plications, and also shows the dilatation of small blood vessels at the portion of *curvatura major* which causes it to present purple-red color; the wall of the stomach shows edematous swelling regardless of the location.

Microscopical findings: A depressed portion of 1.4 cm diameter is observed along the *pars glandularis* and two other depressed areas, pin head size, exist in proximity to

the former; superficial layer of the mucosal epithelium changes to necrosed tissue stained deeply with eosin; profound layer loses proper tissue structure and is replaced by proliferated tissue composed of immature fibrocytes; *lamina muscularis mucosae* increased in thickness; tissues in between muscle fibers and *tela submucosa* contain focal connective tissue areas which show fibrinoid swelling (Fig. 5).

Case No. 12: Pr. 3023 (Epidemic Year Case No. 54)

Karifuto-cho, Abuta-gun; ♀; 2 years of age; 12 days of course.

Clinical symptoms: 26/VIII′50—depression in the morning; decreased appetite; was released from the stable but lay on the ground. 27/VIII—first consultation; the body temperature in the morning—39.0°C; depression with the head dropped down; was willing to lie down; appetite completely lost; was forced to stand but showed stagger; in the afternoon T. 38.9°C, P. 70. 29/VIII—showed frenzy fit at night; jumped out of the stable. 30/VIII—T. 38.5°C, P. 60; slight clockwise circling movement. 5/IX—T. 37.8°C, P. 40; was in lethargic conditions with head bent downward; clockwise circling movement and often gnashed; anorexia; dense nasal discharge in small quantity; conjunctivae become hyperemic. 7/IX—the animal was hanged by slings and travis and kept in the normal standing pose but bent the head down at every 5 or 10 minutes as if to take collective posture; often gnashed; normal tail resistance; the reflex of eyelid and anus was normal; the reflex of pupil and skin was slightly reluxed; halitosis; killed; encephalitis vaccination had been already given.

Neuro-histophathological diagnosis: Encephalitis in non-leucocytic stage.

Stomach

Macroscopical findings: Formation of gastric ulcer.

Microscopical findings: Showed a depressed area of 0.7 cm diameter; mucosal epithelium is completely lost, and *lamina muscularis mucosae* is enveloped by a thin layer of proliferated tissues which are rich in fibrocytes and small blood vessels; in some part, there was an invasion of the proliferated connective tissue rich in fibers, which originated in *tela submucosa* and penetrated *lamina muscularis mucosae*; in *tela submucosa*, some part shows focal fibrinoid swelling.

Case No. 13: Pr. 3694 (Non-epidemic Year Case No. 16)

Ashibetsu; ♂; 3 years of age; 18 days of course.

Stomach

Macroscopical findings: Contains a small quantity of well masticated ingesta and the wall is expanded; presents anemic serous surface; sporadically manifested superficial keratinization or ulcer existed atop the mucosal folds, pen point size, in *pars oesophagea*.

Microscopical findings: A substance defect area of 0.2 cm diameter, and at 0.7 cm from it another defect area of 1.0 cm diameter exists; the former loses a great part of mucosal epithelium and pieces of its profound tissue are left behind; the latter also loses the structure of mucosal epithelium and leaves its profound tissue in various places adjacent to *tunica propria*; on the surface of the masses, mesh structure which contains wandering cells is manifested; the superficial layer of mucosal epithelium allows fragments of necrosed tissue to adhere, where many small blood vessels contain thrombi; *tela*

submucosa shows lymph thrombosis.

Case No. 14: Pr. 3695 (Non-epidemic Year Case No. 17)

Ōno-mura, Kameda-gun; ♀; 8 years of age; 19 days of couse.

Stomach

Macroscopifal findings: Contains a great quantity of well masticated ingesta; mucosa is generally pale and *pars oesophagea* shows 2 substance defect areas covered by rice grain sized pseudomembranes of brown yellowish color.

Microscopical findings: Manifests a depression of 0.4 cm diameter which is exposed on the surface of *tunica propria* of fibrosed tissue, of which surface is as clean as if scraped off; the surface and the superficial layer of *tunica propria* present small cellective masses of mucosal epithelial cells (Fig. 14); *tela submucosa* shows areas of loose fibrous tissue.

DISCUSSION

The authors would like to try to summarize the findings on the foregoing described 14 cases. What is the most noteworthy structural change of mucosa of *pars oesophagea* would be the erosion of superficial mucosa caused by necrobiosis of mucosal epithelium. In addition mucosal epithelium which became necrobiotic is usually demarcated by *tunica propria* or deep epithelial layer having a distinctive line in parallel with mucosal epithelial surface. This is why the portion from which degenerative necrobiotic substance came off presents a surface which varies in size as if it had been scraped off. The length, of course, and the size of lesion play a decisive role in the extent of infiltration of reactive wandering cells. The proliferation of fibrous tissue has participated in the changes as observed in the advanced cases.

Changes that cannot be overlooked at the portion with substance defects are (a) thrombosis of large and small blood vessels, (b) the fibrinoid swelling of the walls of blood vessels and interstitial connective tissue fibers and (c) edema of mucosa tissue. The formation of thrombi takes place in any part of mucosal tissue. However, it is interesting to know that the formation in small blood vessels of superficial mucosa was observed in all cases regardless of the length of the course. When the changes are very severe, it is not hard to observe the formation of thrombi in blood vessels and lymph vessels of fairly large diameter as well as in each layer of mucosa. Thrombi are characterized by showing a clear fibrinous structure but many show hyalinous appearance. The fibrinoid swelling of the wall of the blood vessels is clearly observed principally in blood vessels of fairly large diameter in *tunica propria* and *tela submucosa*. As to the fibrinoid swelling of interstitial connective tissue, since the fibrin separation is simultaneously observed, changes of fibers cannot always be detected clearly in the event of the co-existence of edematous changes. However, fibrinoid swelling

is normally observed focally, and or clearly at perivascular areas. Cases which took a long course is also gave evidence of the existence of such fibrinoid swelling in the intermuscular tissue of *lamina muscularis mucosae*. The depth and width of edematous changes vary depending on the size of substance defects, and such changes, relatively speaking, appear only in the lower layer of the eroded surface.

Considering such histological changes pathogenetically, the authors are able to say without doubt that the erosion formation of mucosa has a close relation with thrombosis, for causal relation can be sought between the location and the size of thrombus observed by microscopy and the formation of erosion. What comes into question is to what extent one should attach significance to edematous changes which are accompanied by fibrinoid swelling and eosinophilic infiltration observed in interstitial fibrous tissue. In connection with this, what we can easily say is that thrombosis and edematous changes might be directly traced to the virus of Japanese encephalitis. According to what we have experienced, emphasis should be laid upon various changes of circulatory disturbances in general organs and tissues including central nervous system as they represent findings on infection pathology of Japanese encephalitis. In consequence, we could safely consider even *pars oesophagea* of the stomach to be included in such a category.

From the viewpoint of infection pathology of Japanese encephalitis, it may not be proper to deny the way of interpreting a series of changes which took place in blood vessel and connective tissue as allergic ones. In fact, KINAMI holds an opinion about the fibrinoid swelling observed on the wall of the small artery of brain and visceral organs of a patient affected with Japanese encephalitis in the same way as the authors.

SUMMARY

The authors have attempted to describe gastric erosion and ulcer which were observed at each autopsy of 7 horses affected with Japanese encephalitis respectively in epidemic year and non-epidemic year.

The authors have placed emphasis on the thrombosis in affected tissue as a causal factor.

The authors are confident that they have added new knowledge on the pathological anatomy of Japanese encephalitis.

REFERENCES

1) KINAMI, M. (1949): *Tr. Soc. Path. Jap.*, **38**, 274 (in Japanese).
2) SHIMADA, N. & A. TANAKA (1949): *Tr. Soc. Path. Jap.*, **38**, 294.
3) SUGANO, S., S. KONNO & Y. FUJIMOTO (1949): *Jap. J. vet. Sci.*, **11**, 103 (in Japanese).
4) TAJIMA, M. (1953): *Jap. J. vet. Res.* (formerly *Vet. Res.*), **1**, Extra No. 1 (in Japanese with English summary).
5) YAMAGIWA, S. & H. SATOH (1957): *Acta path. jap.*, **7**, Suppl., 613.

EXPLANATION OF FIGURES

Preparations for microscopical examination are all sections embedded in paraffin and stained with hematoxylin-eosin.

PLATE I.

Fig. 1—Case No. 1: ×90: Necrobiosis took place in the mucosal epithelium except in the upper one-third; the lower one-third was desquamated. *Tunica propria* became edematous and was thickened to a great extent. Fibrinoid swelling of connective tissue fibers and fibrin separation was observed in the focus. Many thrombi of various sizes.

Fig. 2—Case No. 3: ×90: The left half of the picture indicates necrosed mucosal epithelium. *Tunica propria* presents sections of thrombi.

Fig. 3—Case No. 3: ×90: Portion adjacent to that shown in Fig. 2. Mucosal epithelium has partly come off, partly manifests necrobiosis and contains many thrombi in small vessels. Proliferation of small blood vessels in *tunica propria.*

Fig. 4—Case No. 8: ×45: Mucosal epithelium has become necrobiotic and shows small blood vessels containing thrombi. The central portion deeply stained on the picture indicates the deep layer of mucosal epithelium which became necrobiotic.

Fig. 5—Case No. 11: ×45: The left upper part of the picture is necrotic mucosal epithelium deeply stained with eosin. Proliferation of freshly granulated tissue in *tunica propria.* The portion of *lamina muscularis mucosae* deeply stained is the fibrinoid swelling of connective tissue fibers.

PLATE II.

Fig. 6—Case No. 9: ×90: A piece of mucosal epithelium taking island-like shape remains in the left central portion of the picture. Other epithelial layer has become necrobiotic. *Tunica propria* became edematous and increased its thickness. The formation of thrombi and the infiltration of wandering cells are observed. Connective tissue fibers show fibrinoid swelling.

Fig. 7—Case No. 10: ×45: Mucosal epithelium became necrobiotic. *Tela submucosa* is edematous and lymph thrombosis is observed. Deeply stained focal portion indicates the outstanding fibrinoid swelling of connective tissue fibers.

Fig. 8—Case No. 4: ×45: Deeply stained portion on the left of the picture is mucosal epithelium which became necrobiotic, and contains thrombi. *Tunica propria* and *tela submucosa* have become severely edematous. The wall of arteries manifests fibrinoid swelling in *tunica propria* (Cf. Fig. 9).

Fig. 9—Case No. 4: ×150: Fibrinoid swelling of the wall of artery in *tunica propria.* Outstanding eosinophilic cell infiltration in perivascular area.

Fig. 10—Case No. 3: ×90: Portion adjacent to that shown in Fig. 2: Indicates fibrinoid swelling of wall of veins in *tunica propria.* Eosinophilic cell infiltration in perivascular areas.

PLATE III.

Fig. 11—Case No. 3: ×150: Boundary portion between erosive and intact portions. Nearly central portion of the picture shows 2 cut sections of blood vessels with fibrinoid swelling. Mucosal epithelium which has become necrobiotic contains thrombi.

Fig. 12—Case No. 8: ×300: Portion adjacent to that shown in Fig. 4. The upper half of the picture is mucosal epithelium which exhibits necrobiosis and the lower is *tunica propria*. In the center of the picture is a small artery showing fibrinoid swelling.

Fig. 13—Case No. 11: Cleaned erosion.

Fig. 14—Case No. 14: Cleaned erosion. There remains a part of deep layer tissue of mucosal epithelium.


①
②
③
④
⑤


⑥
⑦
⑧
⑩

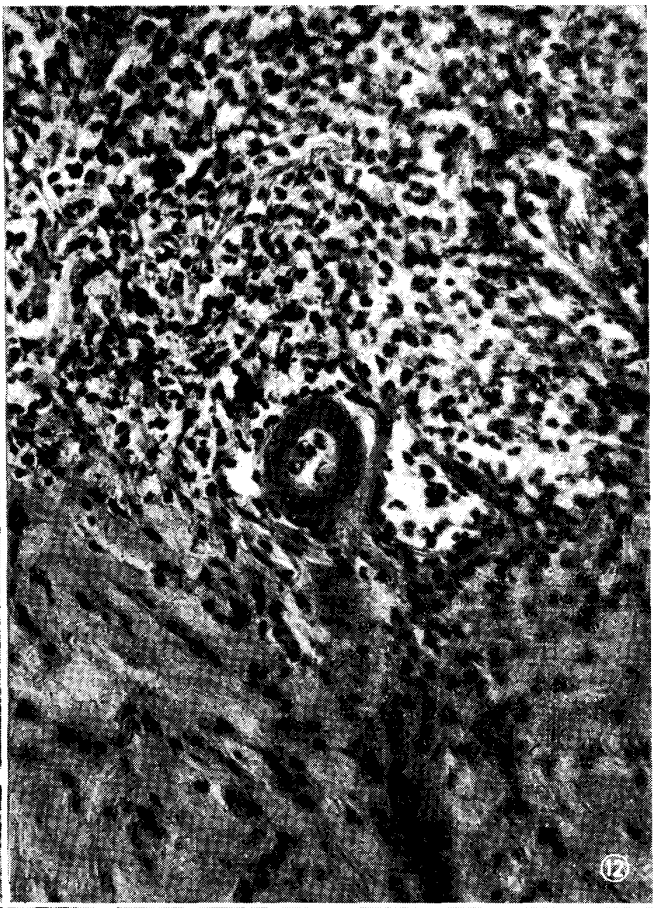

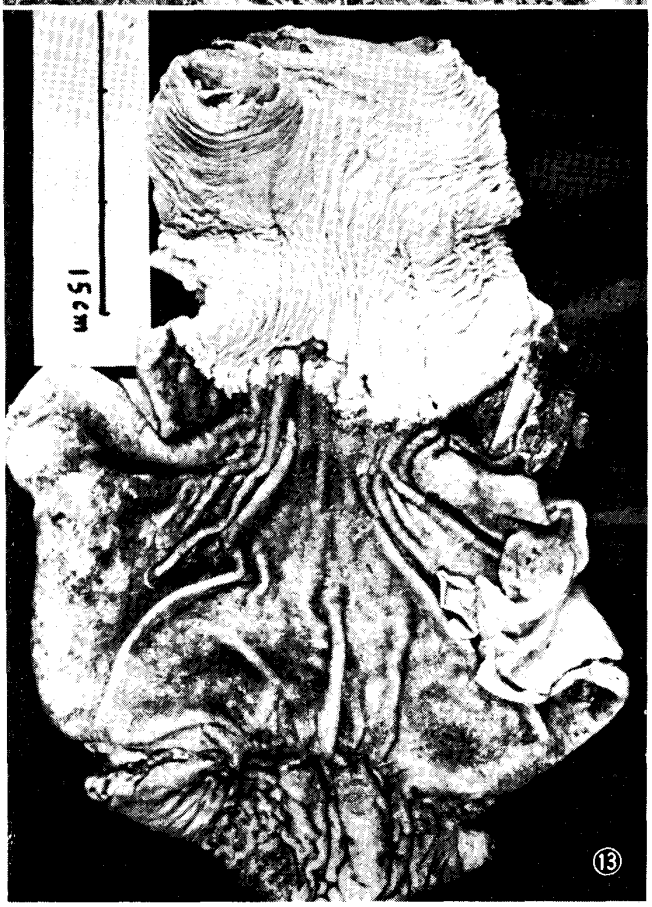
15cm