CYTOLOGICAL STUDIES ON SIDEROCYTES IN EQUINE INFECTIOUS ANEMIA*

I. MORPHOLOGICAL STUDIES ON SIDEROCYTES

Tsukasa SAKAMOTO

*Department of Veterinary Pathology,***
Faculty of Veterinary Medicine,
Hokkaido University, Sapporo, Japan

(Received for publication, December 28, 1959)

PREFACE

Equine infectious anemia (EIA), centering around the pathogenesis of anemia, has been studied by many investigators. DOBBERSTEIN[2] published his critical views concerning the pathogenesis, in 1934, on the basis of histo-pathological findings. He stated that the virus of EIA acts on undifferentiated and differentiated mesenchymes of the wall of blood vessels in the whole body. About that time, many other investigations supporting his opinions were reported by himself and his co-workers.[3,27] ISHII et al. (1935, 1937)[8,9] studied the monocytosis, especially so-called histiocytosis in EIA. They considered that some hematological changes should occur in parallel with such successive histological changes as histiocytic, lymphoid cellular and fibrillar reactions in response to virulence and action of the virus, if DOBBERSTEIN's opinion was correct. Since tissue hemosiderosis is severe in EIA, ISHII investigated the relationship between blood and tissue siderocytes, and in 1939[6], he classified the siderocytes into two types, large and small. The latter was considered to have some relation with so-called lymphoid cell. In the next year, ISHII et al. (1940)[11] reported that the detection of siderocytes in the blood of the jugular vein is useful for clinical diagnosis of EIA, and thenceforth the detection of siderocyte has played an important role for the diagnosis of EIA. ISHII (1940)[7] also reported that the appearance of siderocytes begins at the stage of proliferation of histiocytes, and the demonstration of blood-siderocytes is difficult or impossible at the stages of lymphoid cellular and fibrillar reactions, because siderocytes originate from histiocytes. That is to say, these reports deny any relation between small

* This work was communicated at the 47 th Meeting of the Japanese Society of Veterinary Science on April 3, 1959 in Tokyo.
The investigation was conducted in preparation of a thesis for the doctor course in the Faculty of Veterinary Medicine, Hokkaido University on September 30, 1959.

** Present post: *Department of Parasitology, Faculty of Veterinary Medicine, Hokkaido University.*

siderocytes and so-called lymphoid cells.

Although, in 1954, YAMAGIWA et al.[39] conducted extensive clinico-pathological studies on natural and experimental cases of EIA. They recognized that the lesions existed mainly in the lympho-reticular tissue and reticulo-endothelial system; they also classified EIA into four types as acute, subacute, chronic and relapsed from the patho-morphological point of view. They emphasized that the acute and subacute types terminate usually in death, but that the chronic type EIA takes a chronic course showing chronic type lesions mainly such as small lymphoid cellular reaction in the lympho-reticular tissue from the initial stage. In view of their reports and the fact that the detection of siderocytes is done widely in order to discover natural cases of chronic type EIA which provide most cases in Japan, the present author feels there is considerable disagreement with ISHII's opinion.

On the other hand, many reports were made on the clinical diagnostic value of siderocytes by SUGANO et al. (1950)[32,33], SCHÜTZLER (1955)[30] etc., and for its prosperity and decay by SUGANO et al. (1950)[32,33], NAKAMURA and OGURA (1951)[19], MORITA (1955)[15], MORITA and ICHIOKA (1957)[16] and many other investigators. No report has been published, however, based upon a systematic study of the essential characters of siderocytes and also based upon recent advances in hematology.

The author supposes that these investigations may have been influenced by an important characteristic of siderocytes which can be identified by finding of the masked iron which appears only by artificial fixation.

Here the present author describes his attempts to make an accurate and careful cytological investigation in order to confirm the characteristics of siderocytes and advance a step further in the study of the pathogenesis of EIA.

MATERIALS AND METHODS

Materials examined were from 100 cases, of which in 93 natural cases the appearance of siderocytes was recognized in the blood of jugular vein whilst 7 experimental cases were infected artificially with the disease. Eighty-eight natural cases (80 chronic, 1 acute, 3 relapsed type and 4 non EIA cases) were obtained from the Sapporo, Tsukisappu and Ebetsu slaughter houses. Their livers, spleens, lymph nodes and other organs were subjected to histio-pathological examination. The experimental cases (3 chronic, 3 subacute and 1 acute type cases) were dissected, and their organs were also subjected to examination. For the cytological studies of siderocytes, the blood of jugular vein was used; it was subjected to MAY-GIEMSA staining and ARMITAG's peroxydase reaction. Hemograms of the blood samples were counted in the film of MAY-GIEMSA staining.

For the cytological studies of siderocytes in the blood, 3 ml of 10% sodium citrate solution was placed in a test tube, and 27 ml blood was added. After being mixed, the

tube was allowed to stand in the incubator for 15 to 30 minutes, and then each 5 ml of the plasma was removed in three centrifugal tubes (A, B and C). Some drops of saline solution containing 0.2% neutral red were added into tube B for the supravital staining. A few drops of saline solution containing carbon were added into tube C for the examination of phagocytic affinity. Those tubes were allowed to stand in the incubator for 10 minutes, then they were centrifuged for 5 minutes at 600~800 rpm. The sediment suitably diluted with saline solution was filmed on the slide, and dried in a moment using the drier. A part of the films obtained from tube A was fixed in formalin vapour, treated with Berlin blue reaction, and then counterstained with alum-carmine (abbreviated hereafter as BK-treatment). To another of the film samples were applied ARMITAG's peroxydase and Berlin blue reactions (PB-treatment); to some of the samples was further applied the counterstaining of alum-carmine (PBK-treatment).

The films obtained from tube B to which was added saline solution with neutral red were treated by the fixer which was prepared as follows: The supernatant fluid of mixture of 100 ml of 5% $HgCl_2$ and 60 ml of 15% KI was mixed with the equivalent MAYER's solution. For the identification of masked iron, materials were allowed to stand in formalin vapour for 5 minutes. Berlin blue reaction was applied to the films, and the findings of siderocytes stained supravitally with neutral red were observed by above method (NB-treatment). The films obtained from tube C to which had been added saline solution containing carbon were subjected to the KB-treatment (CKB-treatment), and the phagocytic affinity of siderocytes to carbon particles was examined. For the histopathological studies, the organs were fixed with CARNOY's and formalin solution, and were stained with hematoxylin-eosin and Berlin blue-alum-carmine.

RESULTS

(A) Morphology of siderocytes in the blood of jugular vein

The various treatments described above were applied to the films of the leucocytes collected from the blood of the jugular vein of 100 horses in which blood was recognized the appearance of siderocytes. They were classified hematologically according to a synthesis of the morphological findings, peroxydase reaction, supravital staining, phagocytic affinity to carbon particles and MAY-GIEMSA staining. As the result, it was manifested that siderocytes consist of neutrophilic leucocytes and monocytes which were the native blood cells and large phagocytes, small phagocytes and small lymphoid cells which originated in tissue. The conditions of hemosiderin staining of siderocytes were classified into three types as follows. The first is a diffuse type in which hemosiderin is stained diffusely over the entire cytoplasm, the second is a granular type with hemosiderin stained granularly in cytoplasm, and the third is a mixed type which manifests the above two types. A detailed explanation of each variety of siderocytes will be described below.

1. *Siderophagous neutrophilic leucocytes*

Siderophagous neutrophilic leucocyte is clearly identified at a glance. It is round in shape. The contour is distinct and smooth. No vacuole can be found in the cytoplasm. The size of these cells is 11 to 17 μ in diameter. The nucleus consists of 2 to 5 segments.

The chromatin network is coarse and distinct. The peroxydase reaction is strong positive. In materials prepared by PKB-treatment, it is clear that the peroxydase-positive granules have relation to the segmentary nucleus. The phagocytosis of a few carbon particles is seen in these cells. In supravital staining, the neutral red granules are hardly recognized. Hemosiderin granules are seen in the cytoplasm of most cells, but diffusely staining hemosiderin and hemosiderin of the mixed type are seen rarely.

2. *Siderophagous monocytes*

The cells, excepting a few having irregular forms, are commonly round in shape. The contour is distinct and smooth. The size of these cells is 12 to 20 μ in diameter. A vacuole can seldom be seen in the cytoplasm. When it was found, it is very fine. The nucleus is round, kidney-like, horse-shoe-like and segmentary in shape. But the segmentary nucleus has a central point of radial or glove-like form. The chromatin network is very fine. The peroxydase reaction is negative. Phagocytosis of a few carbon particles is recognized at the indentation of the nucleus. Fine neutral red granules gathered by one side of the nucleus are remarkable in the cytoplasm and form the rosette generally. The cytoplasm is stained diffusely in general, but a small number of cells possess hemosiderin granules in the cytoplasm. These granules are clustered at the indentation of the nucleus and have a close relationship to the Golgi apparatus which is characterized by an aggregation of the neutral red vacuoles.

3. *Large siderophagocytes*

This structure generally shows an irregular shape with projections. The contour is faint and irregular. The sizes are various, but a majority of the cells are large in size (15 to 50 μ in diameter) as compared with the other sorts of cells. Large and small vacuoles of various size are generally recognizable in the cytoplasm. Phagocytosis for erythrocytes and waste substance are seen frequently in the cytoplasm. The nucleus is nearly oval and kidney-like in shape. A few segmentary nuclei are found in these cells. In the decrepit cells which contain many vacuoles and large hemosiderin granules, the shapes of the nuclei are faint and irregular. The chromatin network is very fine and feebly stained. The peroxydase reaction is almost negative, but peroxydase-positive large feeble drops and faint granules are seen rarely in some cells. The remarkable phagocytosis of carbon particles is recognized but the above decrepit cells do not show phagocytosis. In supravital staining, large neutral red granules of brownish color are seen in clusters, and large brownish neutral red vacuoles are seen scattered about in the cytoplasm. Hemosiderin in the cells is granularly stained for the most part. These granules are extremely many and large as compared with those of the other cells. On the other hand, there are considerably many cells which showed the mixed type and the diffuse type. By MAY-GIEMSA staining, the cells manifest characters similar to those shown in BK-treatment. From the above noted findings, it can be said that the cells showed the characters of reticulo-endothelial cells in a narrow sense.

4. *Small siderophagocytes*

They are round in shape. The contour is distinct and smooth. The sizes are 8 to 17 μ in diameter. The cytoplasm has no vacuoles. The nuclei are various in shape, but most

of them show kidney-like form with a sharp rift in the concave portion. Round nuclei with various and sharp rifts are also recognized in considerable numbers. The nucleus is deeply stained, and its chromatin network is coarse. The peroxydase reaction is negative. The phagocytosis of one to several carbon particles can be observed. Some or many dark purply red granules of neutral red gathered by one side of the nucleus are seen in the cytoplasm and an arrangement resembling a rosette is recognized rarely. By Berlin blue reaction, most cells are stained diffusely. A few cells have one to several hemosiderin granules by one side of the nucleus in the cytoplasm staining diffusely with hemosiderin. The cells with granular hemosiderin are rare. Under MAY-GIEMSA staining, the cells manifest shape and size similar as those KB-treated. From the above noted findings, it is obvious that the cell resembles type II of phagocytes reported by AKAZAKI and his co-workers[1,13,14,17,18].

5. *Small siderophagous lymphoid cells*

They are round in shape. The contour is distinct and smooth. The diameters are 7 to 9 μ. The cytoplasm is substantial without any vacuole. The nucleus is round in shape, and it has generally a sharp rift, but it occasionally shows a kidney-like form accompanied by a sharp rift on its concave portion. The nucleus is deeply stained, and the chromatin network is coarse. The peroxydase reaction is negative. Phagocytosis of a few carbon particles is often recogenized. A few fine neutral red granules are seen scattered about in the cytoplasm. By Berlin blue reaction, hemosiderin of most cells is stained diffusely. A few cells, however, have a few hemosiderin granules in the cytoplasm staining diffusely with hemosiderin. Cells which have only hemosiderin of the granular type are rarely seen. By MAY-GIEMSA staining, cells show characters similar to those KB-treated. This sort of cell identifies morphologically the "small lymphoid cell (r-cell)" described by YAMAGIWA and OHSHIMA[25,26,36,37].

(B) The relations between the variety of siderocytes in the blood of the jugular vein and certain factors

The morphological characters of siderocytes in the blood of the jugular vein were clarified in the previous chapter. The manifestations of appearance of siderocytes are considerably varied by cases. It is indubitable that such variations are owing to many factors. The author would like to offer descriptions separately, in this chapter, for each pathological type since he attaches importance to the relation between the kinds of siderocytes and the histological findings.

1. *Chronic type EIA*

The increase of small lymphoid cells in the lympho-reticular tissue was recognized without exception in the cases of chronic type as YAMAGIWA et al.[39] reported. The cases with the cells remarkably increased in the lymph nodes manifested a higher ratio of appearance of blood-siderocytes of which the larger part is small lymphoid cells. In the cases which increased small lymphoid cells in the spleen, the findings mentioned above are manifested. The increase of small phagocytes (monocytoid cells) in the tissue as splenic pulp is recognized in parallel with the increase of small lymphoid cells and reticular cells. There

is no denying the fact that the increase of these cells has close relation to the small siderophagocytes which appear in the blood of the jugular vein. The increase of reticulo-endothelial cells in the liver, spleen and lymph nodes attached to these organs are not always in parallel with the appearance of large siderophagocytes in the blood of the jugular vein. But the increase of reticulo-endothelial cells in tissue is recognized without exception in the cases where large siderophagocytes were found in the blood of the jugular vein. About siderophagous neutrophilic leucocyte and siderophagous monocytes, the author has had no data yet to throw light on relationship to the histological findings.

Hemosiderosis in tissue:

In mild hemosiderosis of the spleen, the hemosiderin granules lie in the reticular cells of the splenic pulp and the endothelium of the venous sinus (+). In medium hemosiderosis, free hemosiderin is recognized in the interstices of reticular cells, and also it is contained in the cells of splenic pulp, the phagocytes etc., but hemosiderin is not recognized in an area which shows gregarious hyperplasia of lymphoid cells (++). In severe hemosiderosis, hemosiderin is diffusely stained blue all over the splenic pulp. In the detailed observation of these cases, the cell interstices are diffusely stained, and these cells contain both granular and diffuse hemosiderin. Also the reticular cells of the follicle and the lymphoid cells of the splenic pulp contain hemosiderin (+++).

In mild hemosiderosis of the liver, the endothelium and the KUPFFER's cells contain fine granular hemosiderin. According to the progress of the hemosiderosis, the hemosiderin

TABLE 1. *Relations between Ratio of Appearance of Siderocytes* and Tissue Hemosiderosis*

TYPE OF EIA	NOS. OF CASES	RATIO OF APPEARANCE OF SIDEROCYTES PER 100,000 LEUCOCYTES	NUMBER OF CASES WITH HEMOSIDEROSIS															
			In spleen						In liver					In lymph node				
			**++++	+++	++	+	±	−	+++	++	+	±	−	+++	++	+	±	−
Chronic	28	2~9		11	11	5	1		1	4	17	6			5	18	5	
	15	10~19	1	2	6	3	1	2		6	5	1	3		2	8	2	3
	20	20~99		6	12	2			1	8	10		1	1	9	4	5	1
	5	100~299			1	4					5					4	1	
	12	300~1820		4	4	4				2	9	1			1	8	2	1
Total	80***	2~1820	1	23	34	18	2	2	2	20	46	8	4	1	17	42	15	5
Acute	2	10~350				2					2					1	1	
Subacute	3	10~34		1		2			1		2					2	1	
Relapsed	3	10~16				3				3					3			
Non EIA	4	1~7			1	3					4					4		

*: Siderocytes in the blood of jugular vein

**: −~++++ indicate the degree of hemosiderosis

***: In the chronic type, 3 experimental cases are excepted from the table.

granules increase in number and size, and they are liberated in the capillaries (+). In the medium hemosiderosis, hemosiderin comes to be recognized in the GLISSON's capsule, portal vein, *A. hepatica propria*, the proliferated cells of the adventitia of the intralobular capillaries and the hepatic cells (++). In severe hemosiderosis, hemosiderin is recognizable diffusely in the capillaries (+++).

In mild hemosiderosis of the lymph nodes, granular hemosiderin is recognized in the endothelium of the lymph sinus (+). In medium hemosiderosis, hemosiderin granules are recognized in the cells of the reticulo-endothelial system (++). In severe hemosiderosis, the lymph sinus is diffusely stained blue with hemosiderin. Also hemosiderin is recognized in the endothelium and phagocytes of the lymph sinus and a few lymphoid cells (+++). The relation between the hemosiderosis of the tissue and siderocytes varies with each case and each organ as shown in table 1. It is possible that siderocytes in these tissue appear as siderocytes in the blood of jugular vein, however it was not possible to find a definite numerical relationship.

The relations between the ratio of appearance of siderocytes and the proportions of the various cell varieties determined by the cytological classification of siderocytes in the blood of jugular vein are as follows:

The proportions of siderocytes according to cytological variations change with the increase of the ratio of appearance of the siderocytes. In the cases which showed the

TABLE 2. *Ratio of Appearance and Proportion of Cell Varieties of Siderocytes in the Blood of Jugular Vein*

TYPE OF EIA	NOS. OF CASES	RATIO OF APPEARANCE OF SIDEROCYTES PER 100,000 LEUCOCYTES	PROPORTION OF CELL VARIETIES (%)				
			Siderophagous neutrophilic leucocyte	Siderophagous monocyte	Large siderophagocyte	Small siderophagocyte	Small siderophagous lymphoid cell
Chronic	28	2~9	32.5	26.9	5.6	0	35.0
	15	10~19	18.1	28.2	1.0	15.8	36.9
	20	20~99	16.0	18.9	6.0	25.8	33.3
	5	100~299	22.7	18.4	1.7	34.8	22.4
	12	300~1820	14.7	14.0	5.3	20.1	45.9
	Total 80	2~1820	15.7	15.0	5.1	21.1	43.1
Acute	2	10~350	23.0	8.2	2.7	(68.8)*	
Subacute	3	10~34	22.2	49.5	28.3	0	0
Relapsed	3	10~16	25.0	20.0	7.0	25.0	23.0
Non EIA	4	1~7	0	8.7	0	0	91.3

*: Degenerated cells

TABLE 3. *Proportion of Types of Hemosiderin Substance in Each Variety of Siderocytes**

TYPE OF EIA	NOS. OF CASES	RATIO OF APPEARANCE OF SIDEROCYTES PER 100,000 LEUCOCYTES	SIDEROPHAGOUS NEUTROPHILIC LEUCOCYTE			SIDEROPHAGOUS MONOCYTE			LARGE SIDEROPHAGOCYTE			SMALL SIDEROPHAGOCYTE			SMALL SIDEROPHAGOUS LYMPHOID CELL		
			Diffuse Type	Mixed Type	Granular Type	Diffuse Type	Mixed Type	Granular Type	Diffuse Type	Mixed Type	Granular Type	Diffuse Type	Mixed Type	Granular Type	Diffuse Type	Mixed Type	Granular Type
Chronic	28	2~9	31.2	11.6	57.1	38.0	20.1	41.9	11.6	18.7	69.7	0	0	0	50.3	21.7	28.0
	15	10~19	47.6	6.1	48.3	43.4	13.9	42.7	0	100.0	0	55.3	17.5	29.2	28.0	33.6	38.4
	20	20~99	56.1	6.1	37.8	59.4	22.0	18.6	36.3	16.6	47.1	61.6	25.1	13.3	55.6	27.2	17.2
	5	100~299	86.9	10.3	2.8	72.5	27.5	0	100.0	0	0	89.1	3.0	7.9	86.7	4.7	8.6
	12	300~1820	88.0	5.3	6.7	78.2	16.6	5.0	47.1	52.9	0	90.4	7.6	2.0	86.3	10.9	2.8
	Total 80	2~1820	83.8	6.0	10.2	74.3	17.9	7.8	47.0	49.0	4.0	87.9	8.4	3.7	83.9	11.8	4.3
Acute	2	10~350	1.7	0	98.30	0	0	100.0	0	0	100.0	0	0	0	0	0	0
Subacute	3	10~34	49.0	0	51.0	6.8	0	93.2	0	100.0	0	87.4	12.6	0	0	0	0
Relapsed	3	10~16	36.5	1.5	58.0	11.5	0	88.5	28.7	52.4	18.9	63.5	36.6	0	20.5	0	79.5
Non EIA	4	1~7	0	0	0	100.0	0	0	0	0	0	0	0	0	41.6	0	58.4

*: Siderocytes in the blood of jugular vein

lower appearance of siderocytes, siderophagous neutrophilic leucocytes occupied the great part, and they decreased with the increase of appearance of siderocytes. Siderophagous monocytes showed the same inclination as the siderophagous neutrophilic leucocytes. The relation between the ratio of appearance of siderocytes and large siderophagocytes is not clear. Few small siderophagocytes are recognized in a case where the ratio of appearance of siderocytes is lower than 1/10,000, and they are barely recognized in the cases having 1/5,000～10,000 ratio of appearance. In cases with higher ratio of appearance of siderocytes than in the above cases, small siderophagocytes increased in parallel with the increase of appearance of siderocytes. The proportion of small siderophagous lymphoid cells in siderocytes increased undoubtedly in parallel with the increase of appearance of siderocytes. That is to say, it seems that such lymphoid cells play important parts in the increase of siderocytes. No relation was recognized in respect to number among the hemogram and siderophagous neutrophilic leucocytes and siderophagous monocytes. In cases where the reticulo-endothelial cells were recognized in the hemogram, large siderophagocytes are almost always recognized. No close relation is recognized between small siderophagocytes in blood-siderocytes and small phagocytes (monocytoid cell) in the hemogram. In cases with remarkable increase of small lymphoid cells, the increase of small siderophagous lymphoid cells is recognized, but the cases with the predominant appearance of small siderophagous lymphoid cells do not always show increase of small lymphoid cells in the hemogram. Hemosiderin in siderocytes showed that diffuse type occupied generally the predominant proportion ; such inclination were remarkable in cases with higher ratio of appearance of siderocytes.

2. *Acute type*

Two cases of the histological acute type manifested a remarkable increase of the reticulo-endothelial cells in the liver, spleen and lymph nodes, and they further showed mild hemosiderosis in tissue. In one case (Z 138) with 1/10,000 ratio of appearance of siderocytes, siderophagous neutrophilic leucocytes occupied a great part of the siderocytes, and siderophagous monocytes the remaining part. In another case (E 2138) with 1/285 ratio of appearance of siderocytes, the degenerated form of large siderophagocytes occupied the greater part, while the rest was occupied in order by siderophagous neutrophilic leucocytes, siderophagous monocytes and large siderophagocytes. That is to say, such findings manifested close relation with histological findings. All hemosiderin in siderocytes showed a granular type. No special relation between the varieties of siderocytes and the hemogram were recognized.

3. *Subacute type*

Three cases of the histological subacute type manifested remarkable increase of reticulo-endothelial cells and large lymphoid cells (L-cells) and a few small lymphoid cells in the liver, spleen and lymph nodes attached to above organs. Hemosiderosis in tissue was strongly positive in the spleen of Z 223 and Z 231, and other case was all weakly positive. In case Z 223 with 1/10,000 ratio of appearance of siderocytes, siderophagous neutrophilic leucocytes and siderophagous monocytes occupied nearly a half each, and a few large siderophagocytes were recognized. In case Z 231 with 16/100,000 ratio of

appearance of siderocytes, siderophagous neutrophilic leucocytes, siderophagous monocytes and small siderophagocytes occupied the greater part. In the other case (Pr 3703) with lower ratio (1/7,430) of appearance of siderocytes, only siderophagous monocytes were recognized. In cases Z 223 and Pr 3703 with lower ratio of appearance of siderocytes, all hemosiderin of siderocytes showed a granular type. But hemosiderin of the diffuse and mixed types were recognized considerably in case Z 231 with higher ratio of appearance of siderocytes. In the hemogram of the blood of jugular vein, reticulo-endothelial cells were recognized in Z 223, and small phagocytes in Z 231.

4. *Relapsed type*

Three cases of the histological relapsed type manifested an increase of small lymphoid cells, large lymphoid cells, small phagocytes and reticulo-endothelial cells in the liver, spleen and lymph nodes attached to those organs. In all cases, considerable hemosiderosis in the spleen and lymph nodes was recognized, but it was mild in the liver. The ratio of appearance of siderocytes in Z 222, Z 225 and E 2013 was 1/10,000, 1/750 and 12/10,000 respectively. The cytomorphological varieties of siderocytes in these cases were siderophagous neutrophilic leucocytes, siderophagous monocytes and small siderophagous lymphoid cells. Large siderophagocytes were recognized in Z 222 and Z 225, and small siderophagocytes in Z 222 and E 2013. Small lymphoid cells were recognized in the hemograms of all cases. Also reticulo-endothelial cells were recognized in Z 225, and small phagocytes in Z 222 and E 2013. In these cases, granular hemosiderin occupied a large part of siderocytes, however also a few siderocytes with diffuse and mixed types were recognized.

5. *Non EIA*

In four cases of the histological non EIA, no remarkable changes were recognized except that the nodules of small lymphoid cells seemed to be parasitic. Hemosiderosis was mild in the liver, spleen and lymph nodes. The ratio of appearance of siderocytes was lower than 1/15,000. The varieties of siderocytes were almost all small siderophagous lymphoid cells, but siderophagous monocytes occupied about a half of the siderocytes in Z 144 only. Hemosiderin in siderocytes was of the diffuse and granular types.

Discussion

Discussion about the siderocytes which occurred in the natural and experimental cases of EIA is offered as follows.

(A) Histogenesis of siderocytes

In his basic studies of siderocytes, Ishii (1939)[6] recognized two varieties: one was the so-called large phagocyte having many hemosiderin granules and rich cytoplasm, the other was the cell having a small nucleus and poor cytoplasm which was stained diffusely by Berlin blue reaction and was considered to have mutual relations with so-called lymphoid cells originated from the reticulo-endothelia and adventitia of blood vessels. In the next year, Ishii[7] reported that

siderocytes are histiocytes which originated from the differentiated and undifferentiated wall mesenchyma of blood vessels and took the blood cells or the destructive production of erythrocytes. Siderocytes are considered to originate from the cells of splenic pulp, reticulo-endothelial cells and endothelial cells of venous sinus of the spleen and KUPFFER's cells. Appearance of siderocytes begins at the stage of proliferation of histiocytes; however the demonstration of blood-siderocytes is very difficult at the stages of lymphoid cellular and fibrillar reactions, because siderocytes originate from histiocytes. ISHII and co-workers (1941)[10] expressed again the same opinion. Namely, their ultimate opinion amounted to a denial of the relation between small siderocytes and so-called lymphoid cells contrary to statements in his first report.

The present author believes that siderocytes in the blood of jugular vein can be classified into siderophagous neutrophilic leucocytes, siderophagous monocytes, large siderophagocytes, small siderophagocytes and small siderophagous lymphoid cells. It is well known that the neutrophilic leucocytes and monocytes are native blood cells having phagocytic ability. Both cells are distinguished by a certain few characters; the structure of the nucleus, the distinctively positive peroxydase granules in neutrophilic leucocytes and the typical rosette of neutral red in monocytes. However, no other paper has been published, up to the present, reporting the appearance of siderocytes originated from these two cells. The author was fortunately able to ascertain this fact with certainty by the application of new methods. A large siderophagocyte is a so-called "Makrophagen" containing reticular cells, reticulo-endothelial cells and histiocytes etc., which is considered to coincide with so-called "Histiozytäre Zellen" and large siderocyte reported by ISHII[6,7]. The cell is characterized from the size, shape and presence of carbon particles caused by phagocytosis, large granules of neutral red in the supravital staining and vacuoles in the cytoplasm etc.

Small siderophagocytes, in size, are common between small siderophagous lymphoid cells and monocytes in size, and the conditions of their cytoplasm, contour and neutral red granules in the cell resemble those of monocytes. However, the deeply staining nucleus with deep and sharp rifts and the coarse chromatin network resembles that of a small lymphoid cell. Nevertheless, the phagocytosis of the carbon particles of the cell is stronger than that of the other two cells. From these facts, such a cell should be differentiated from other both cells. AKAZAKI and his co-workers[1,17,18] carried out detailed cytological studies of the free cells native to the peritoneal fluid of mice, and classified them into four types morphologically. Also AKAZAKI and his co-worker[1] reported that monocytoid cells appearing in some inflammatory lesions resemble such cells. Small phagocytes classified by the author closely resemble the type II phagocytes

reported by AKAZAKI and his co-workers[1,13,14] from the cytological viewpoint. KANO (1953)[13], a collaborator of AKAZAKI thought that the rounded reticular cells are morphologically classifiable from monocytes in his studies of so-called "Splenozyten"; he classified the rounded reticular cells into four types similar to AKAZAKI's. AKAZAKI and his co-workers[1,14] reported that phagocytes are also recognized in the thoracic and pericardial fluid as in the peritoneal fluid. The presence of phagocytes in the bone-marrow had already been known from the reports of ROHR (1940)[29] etc. ISHII (1939)[6] reported that hemosiderosis was recognized in the spleen, bone-marrow and milky spots of the greater omentum of the EIA affected horses, and in the next year[7], he mentioned that the cells of splenic pulp are able to become siderocytes. So there is support for the statement that siderocytes which originated from the phagocytes in tissue, as mentioned above in the present paper, appear in the blood of jugular vein. In view of these points the author will understand that the matrices of small siderophagocytes are made not only in the spleen but also in the reticular tissue in a wide sense: in the lymph nodes, bone-marrow and peritoneal cavity etc. Small siderophagous lymphoid cells are a sort of proliferated cell in the lympho-reticular tissue in the chronic type EIA, as mentioned by YAMAGIWA et al.[36~39], and it was possible to identify them with small lymphoid cells (r-cell) which was recently reported in detail with their cytological characters by OHSHIMA[25,26]. Also, the cells should be included in the lymphoid cells which appear in the chronic reaction of undifferentiated and differentiated mesenchymes of blood vessel wall which was reported by DOBBERSTEIN[2]. As mentioned above, notwithstanding his first suggestion that there is a mutual relation between small siderophagocyte and so-called lymphoid cell, ISHII and his co-workers[7,11] rather reported a negative opinion against this relation in the next year. It is showing positively a large contradiction which seems to be caused by his consideration that the decrease of blood-siderocytes should occur in parallel with the disappearance of histiocytic reaction, under DOBBERSTEIN's standpoint which the histological findings change from histiocytic reaction to lymphoid cellular reaction.

YAMAGIWA et al.[39] emphasized that the clinically chronic cases show the chronic type lesion mainly, such as small lymphoid cellular reaction. Furthermore, blood-siderocytes are recognized in the most part of chronic type cases. It is difficult to explain these facts by ISHII's opinion[7]. OHSHIMA (1956)[25,26] reported that the r-cells are recognized in the blood of jugular vein by the help of the phase-contrast microscope; this fact endorses the present author's opinion. The author was able to make clear that a mutual relation is recognizable between siderocytes in the blood of jugular vein and histological findings as mentioned above. Therefore it was not only made clear that the blood-siderocytes

have a close relation with the lesions of EIA, but also light was thrown upon the original characters of blood-siderocytes which have been taken up hitherto as a manifestation of EIA.

The author will discuss the phenomena of siderophagia in the following. About the condition of hemosiderin in blood-siderocytes, ISHII (1939)[6] classified it into two types: large phagocytes having a number of various hemosiderin granules and small siderocytes stained diffusely all over the cytoplasm by Berlin blue reaction. The findings of large siderophagocytes and small siderophagous lymphoid cells which were classified by the author coincide with those of ISHII's report. According to RICHTER's recent study[28] of hemosiderosis by means of electron and light microscopy, the aggregation of hemosiderin granules is situated inside of a "siderosome" which may be a derivative of mitochondria; these hemosiderin granules are scattered diffusely in the cytoplasm by the disruption of the membranous borders of siderosomes, and the siderosomes and hemosiderin scattering diffusely coincide with each granular and diffuse hemosiderin which is recognized in the cells under the light microscope. It is obscure whether granular hemosiderin in blood-siderocytes turn into diffuse hemosiderin or not, but these changes are within the range of possibility, because many siderocytes of the granular types are recognized in the first stage of the infection. It is considered that the above phenomena are perhaps due to the difference among the characters of varieties of cells at present when the characters of siderocytes come to be clear. A number of hemosiderin granules in siderophagous monocytes are clustered at the indentation of the nucleus. This fact is interesting together with GOESSNER's report[5] that glycoproteid of hemosiderin is made within the Golgi apparatus being at the indentation of the nucleus.

(B) Appearance of siderocytes

The mutual relations were observed between the ratio of appearance and cytomorphological varieties of siderocytes. In the chronic type of EIA, cases with comparatively lower ratio of appearance of siderocytes showed the predominant appearance of siderophagous neutrophilic leucocytes and siderophagous monocytes. In accordance with the gradual increase of the ratio of appearance, however, small siderophagous lymphoid cells showed a tendency to increase, and small siderophagocytes increased subsequently. Cases with comparatively lower ratio of appearance of siderocytes showed the predominant appearance of siderophagous neutrophilic leucocytes and siderophagous monocytes which originated from the native cells of the blood, because the proliferation of the cells of reticulo-endothelial system was not remarkable. In cases with comparatively higher ratio of appearance of siderocytes, on the contrary, small

lymphoid cells and small phagocytes are considered to appear as siderocytes, because the conspicuous proliferation of the cells is recognized in tissue. In the acute and subacute types, cases with low ratio of appearance of siderocytes showed the predominant appearance of siderophagous neutrophilic leucocytes and siderophagous monocytes. That is important because no proliferation of small lymphoid cells is recognized in tissue and because large siderophagocytes clog in the lung and capillaries of tissue without occurring in the blood of jugular vein, notwithstanding that the proliferated reticulo-endothelial cells are able to become siderocytes. Degenerated siderocytes which are recognized in the case of acute type EIA show the figures of karyolysis, karyorrhexis and pyknosis, and it is perhaps that such degenerated structures are the degenerated large siderophagocytes morphologically. In the relapsed type, various varieties of siderocytes were recognized. This may be explained by the fact that the type of histological lesions in the case showed characters of both the chronic and acute types.

No distinct relations were recognized in number between the hemogram and cytomorphological varieties of siderocytes. About that, the author will explain as follows: The factors[20] which act upon the metabolism of iron and the factors[35,41] such as cortisone etc. which work upon the phagocytic action of reticulo-endothelial cells are to be concerned in the findings without a monistic appearance. In the case of non EIA histologically, most of the siderocytes were small siderophagous lymphoid cells, and a few nodules which consisted of some small lymphoid cells were recognized in the liver of two cases. It is of course true that such cells are never directly considered to have relation to the appearance of siderocytes, but also that some factors acting upon the increase of these cells do exist.

A discussion follows about the relation between siderocytes and hemosiderosis. ISHII (1939)[6] reported: "In the first stage of infection, hemosiderosis is mainly recognized in the bone-marrow and spleen. At the stage when the several fever paroxysms are recurrent, contrary to the gradual decrease of hemosiderosis in the spleen, hemosiderosis in the liver increases gradually, because siderocytes move from the spleen to the liver. But after a prolonged course of the disease, hemosiderosis of the spleen and liver decreases gradually, and on the contrary the proliferation of lymphoid cells becomes remarkable, and the hemosiderosis comes to be unable to be found ultimately. Namely, at this stage, iron metabolism is considered to be in the paralytic or insufficient condition from the point of view of destruction of erythrocytes." The same opinion was reported also by ICHIKAWA and SHIBATA (1958)[12] and YAMAMOTO et al. (1958)[40]. In the next year, by ISHII[7], it was also reported that in severe cases of liver hemosiderosis a large number of siderocytes were recognized and in mild cases a few siderocytes were

found. So he asserted that the detection of blood-siderocytes is quite useful for deciding the grade of liver hemosiderosis. In a word, it is indubitable that he held the opinion that siderocytes in tissue appear directly in the peripheral blood. In view of these facts, the author attempted an investigation of the relation between the ratio of appearance of siderocytes and hemosiderosis in tissue, but he was unable to discover any decisive tendency. In addition, many cases were recognized in which few blood-siderocytes were found notwithstanding the occurrence of sever hemosiderosis in tissue and in which no hemosiderosis was recognized notwithstanding that a number of siderocytes were found (Table 1). Therefore it is doubtful that the relation between hemosiderosis and siderocytes can be concluded simply. In the blood of the jugular vein of the 100 horses examined, siderophagous monocytes and siderophagous neutrophilic leucocytes comprise a principal part of the siderocytes. So it is clear that the participation of the other varieties of siderocytes should be recognized to be dependent on the histological lesions of EIA. Moreover, large siderophagocytes and small siderophagocytes comprise a principal part of the siderocytes in tissue, whilst small siderophagous lymphoid cells are contained in tissue in some cases.

From the facts mentioned above, the author would point out an important matter: that the phenomena of siderophagia of siderocytes occur not only in tissue but also in imperceptible places such as the blood-stream. He recognizes also the considerable hemosiderin granules in the blood films which were got from the blood-stream in the internal organs. The report of TABUCHI et al. (1954)[34] saying that hemosiderin granules were scattered into the blood-stream by the disintegration of siderocytes and the report of OHKI et al. (1958)[21,22] stating that ferritin which is the native stored iron protein in the spleen, liver, bone-marrow etc. is set free in the blood of jugular vein of the horse affected with EIA, are to be considered endorsements of the author's opinion.

SUMMARY

Cytological studies on siderocytes in the blood of the jugular vein of 100 horses were carried out based upon patho-morphological investigation. The mutual relations between siderocytes, hematological changes and histological findings were investigated in detail.

1) Siderocytes were classified into siderophagous neutrophilic leucocytes, siderophagous monocytes, large siderophagocytes, small siderophagocytes and small siderophagous lymphoid cells from the morphological point of view. Each of the siderocytes was considered to originate from neutrophilic leucocytes, monocytes, reticulo-endothelial cells, type II phagocytes (AKAZAKI) and small lymphoid cells respectively. Hemosiderin substances in the siderocytes were

classified morphologically into diffuse type, granular type and mixed type of the two types, and these types were considered to be characterized by cytological characteristics of siderocytes.

2) Mutual relations were recognized between the appearance of siderocytes and histological findings. In the chronic type, cases with increased small lymphoid cells in the spleen and lymph nodes manifested a comparatively higher ratio of appearance of blood-siderocytes of which the larger part was small siderophagous lymphoid cells. In all cases of the acute, subacute and relapsed types and some chronic type cases, the proliferation of reticulo-endothelial cells was recognized in tissues, while the detection of large siderophagocytes in the blood of jugular vein was rare.

3) Mutual relations were observed between the ratio of appearance and cytomorphological variety of siderocytes. In the chronic type EIA, cases with low ratio of appearance of siderocytes showed predominant appearance of siderophagous neutrophilic leucocytes and siderophagous monocytes. In accordance with the gradual increase of the ratio of appearance, however, small siderophagous lymphoid cells showed a tendency to increase and subsequently small siderophagocytes increased. In the acute and subacute types, siderophagous neutrophilic leucocytes and siderophagous monocytes provided the greater part of the siderocytes in cases with low ratio of appearance of siderocytes. A few large siderophagocytes and their degenerated forms in both types and, in addition, small siderophagocytes in the subacute type EIA participated in cases with comparatively higher ratio of appearance of siderocytes. The most of the hemosiderin in both types showed a granular form. In the relapsed type EIA, characteristics of siderocyte were various, those of the above three EIA types were observed. The ratio of appearance of siderocytes in the blood and the morphological variety of siderocytes have no mutual relations to the hemosiderosis in tissue. It can be said without doubt that blood-siderocytes are to be considered to originate not only from the tissue, but also from some sorts of cells having a special function in the blood-stream.

(References will appear in the next issue.)

EXPLANATION OF PLATES

PLATE I.

Fig. 1. Siderophagous neutrophilic leucocytes of the diffuse type. KB. × 1,300.

Fig. 2. Siderophagous neutrophilic leucocytes of the granular type. KB. × 1,400.

Fig. 3. Siderophagous neutrophilic leucocytes (N), siderophagous monocyte (M), small siderophagocytes (p) and small siderophagous lymphoid cell (L) of the diffuse type. KB. × 1,400.

Fig. 4. Siderophagous neutrophilic leucocytes of the diffuse type. PB. × 1,400.

Fig. 5. Siderophagous monocyte of the diffuse type. NB. × 1,400.

Fig. 6. Siderophagous monocyte and large siderophagocyte (Lp) of the diffuse type. NB. × 1,400.

PLATE II.

Fig. 7. Large siderophagocyte of the granular type. KB. × 1,400.

Fig. 8. Large siderophagocyte of the diffuse type. KB. × 1,400.

Fig. 9. Large siderophagocyte of the diffuse type. NB. × 1,400.

Fig. 10. Large siderophagocyte of the mixed type. NB. × 1,400.

Fig. 11. Small siderophagocyte of the diffuse type. KB. × 1,500.

Fig. 12. Small siderophagocytes of the granular type. KB. × 1,500.

PLATE III.

Fig. 13. Small siderophagocyte (p) and siderophagous neutrophilic leucocyte (N) of the granular type. PB. × 1,400.

Fig. 14. Small siderophagocyte of the diffuse type. CKB. × 1,400.

Fig. 15. Small siderophagocyte of the diffuse type. NB. × 1,400.

Fig. 16. Small siderophagous lymphoid cell of the diffuse type. KB. × 1,400.

Fig. 17. Small siderophagous lymphoid cells in the spleen of case No. Z 189. KB. × 1,400.

Fig. 18. Small siderophagous lymphoid cells in a lymph node of case No. Z 153. KB. × 1,400.

Remark: The films were made of the blood of jugular vein except the two sections of tissue (Figs. 17 and 18).

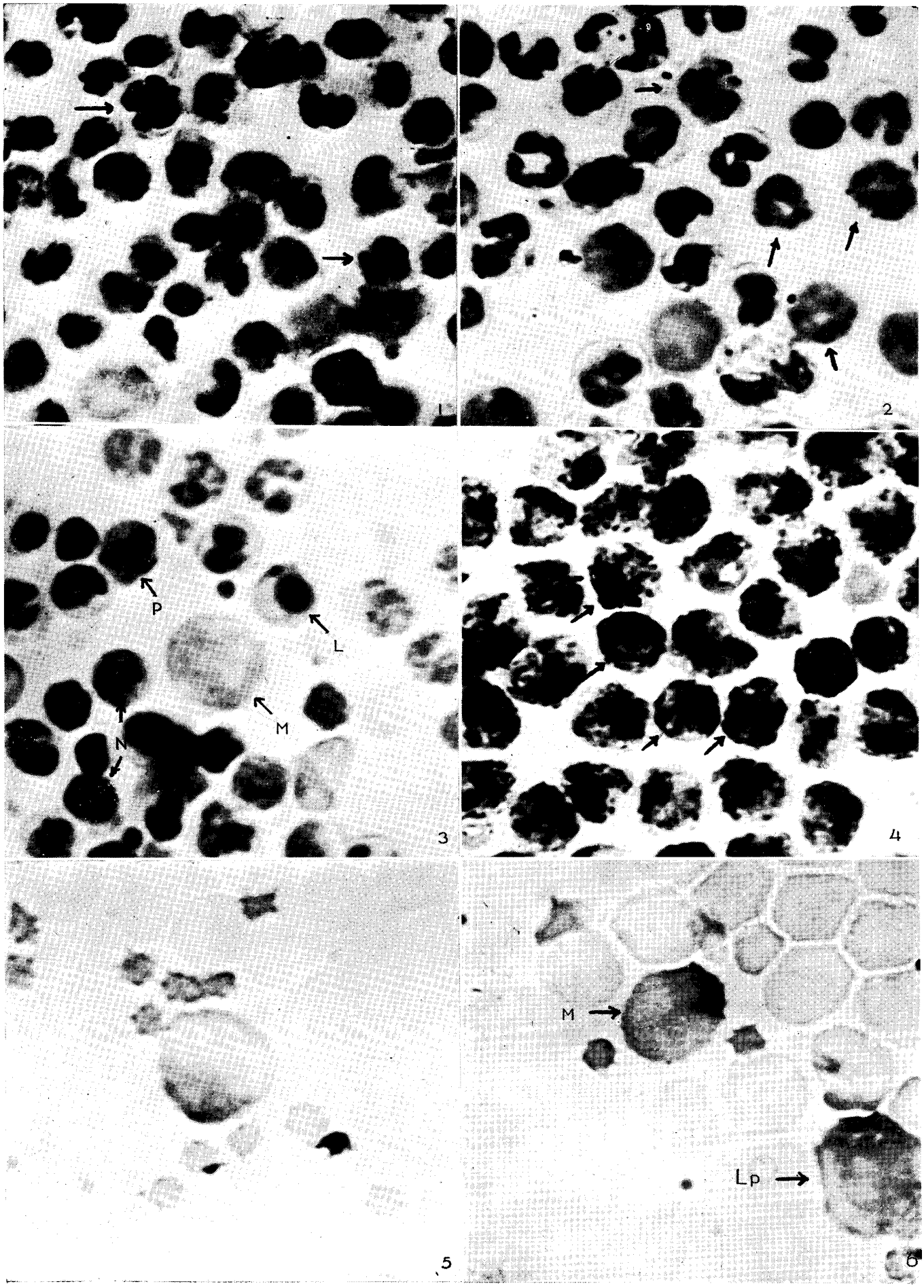
1
2
P
L
M
N
3
4
M
Lp
5
6

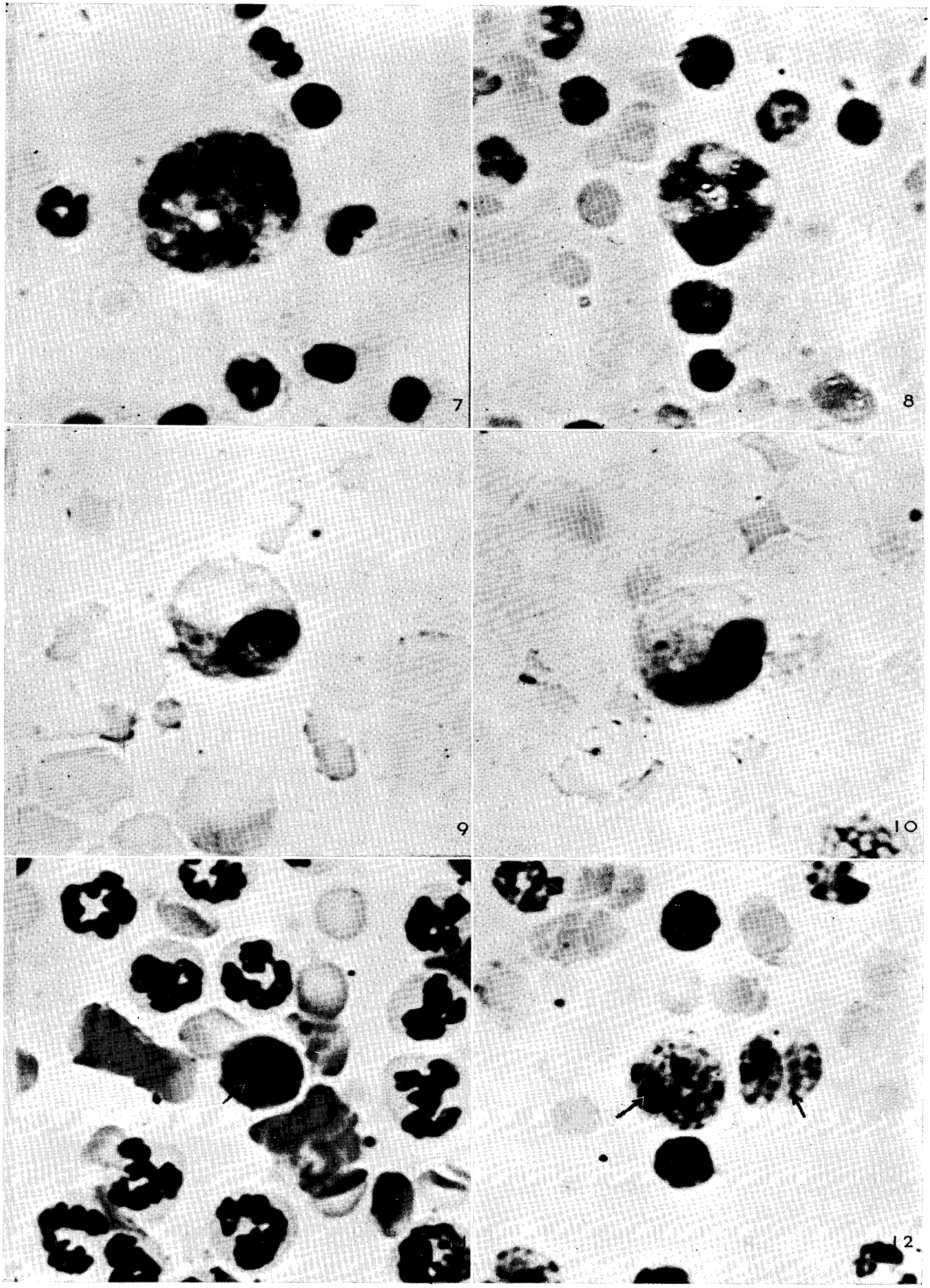
7
8
9
10
12

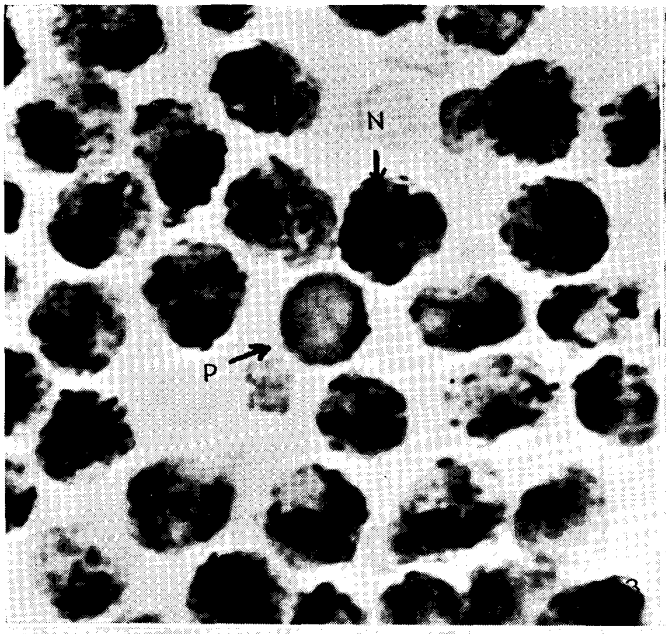
N
P

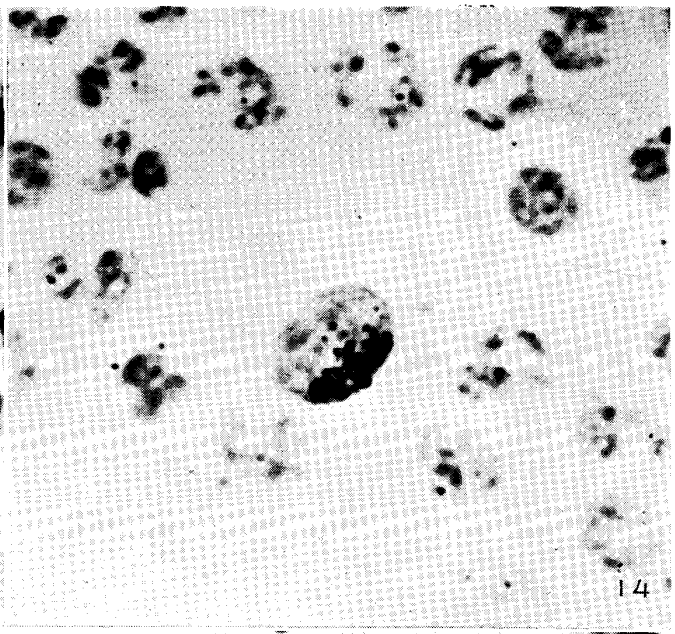
14


15

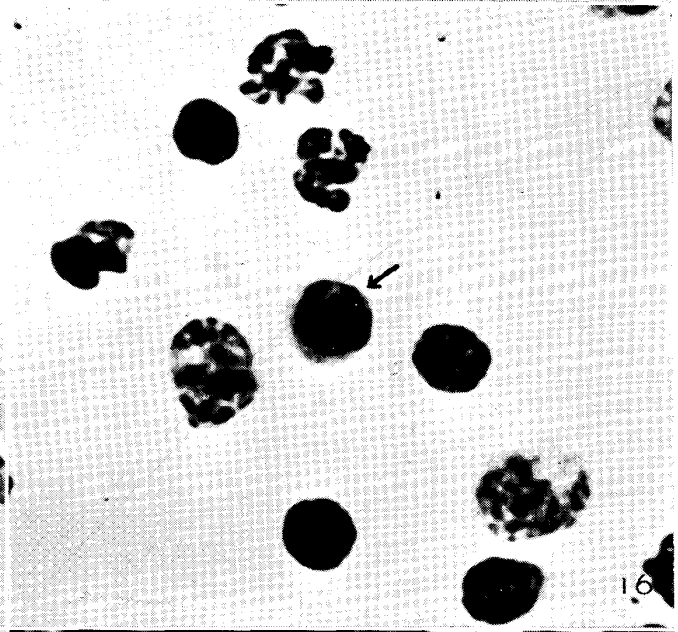
16

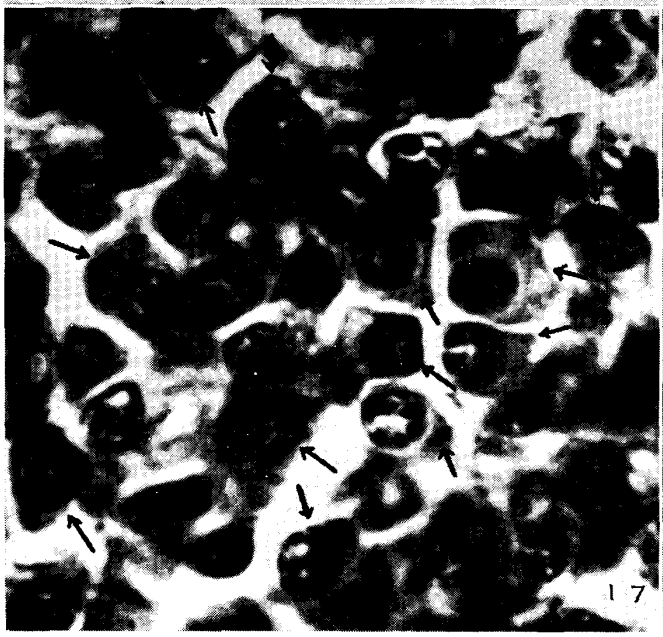
17

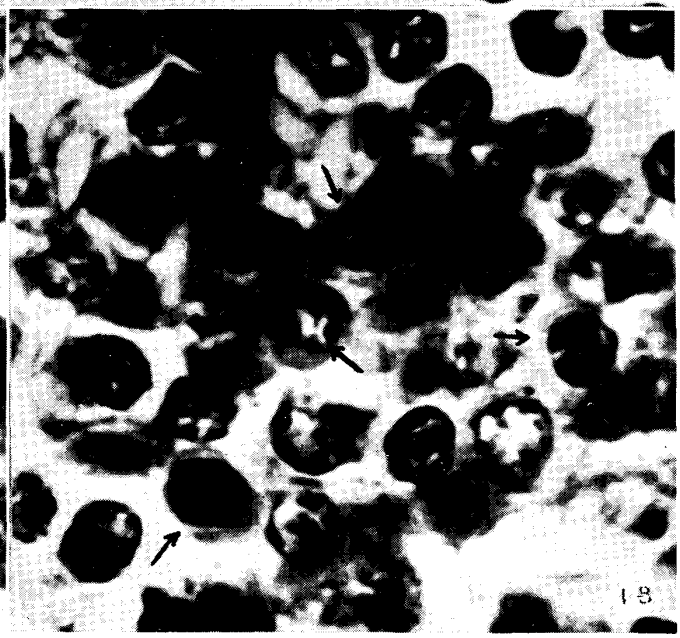
18