STUDIES ON FINE VASCULAR ARRANGEMENTS IN THE ADRENAL GLAND OF THE CAT*

Tatsudo TAMURA

Department of Veterinary Anatomy,
Faculty of Veterinary Medicine,
Hokkaido University, Sapporo, Japan

(Received for publication, October 12, 1960)

Since the advocation of the "stress theory" by SELYE ('50) the adrenal gland has come to the front again under the possibility of its having new significances.

The patterns of the fine vascular arrangements in the adrenal gland were studied by FLINT ('00), BENNETT and KILHAM ('40) etc., and it has been considered as a settled fact that the vascular patterns of the cortex and medulla are peculiar to each. But there are many unsolved problems on the relations between functions and morphological structures of this organ, especially one feels a severe contradiction between the conception of the so-called "X zone" and "cell migration theory" concerning the function and histological appearance of the zona reticularis.

For these reasons, the present author undertook to reinvestigate the fine vascular arrangements of the adrenal gland employing the newly improved neoprene injection method and making use of the easily obtainable materials of the cat.

MATERIALS AND METHODS

For this research 47 cats, 13 males and 34 females, weighing 430 g to 4200 g each, were used as indicated in table 1.

As the injection method, the neoprene latex method was mainly used. Neoprene latex 601 A, diluted 2 or 4 times with distilled water before application, was injected through the thoracic aorta near the diaphragma to caudad. In some cases it was retrogradely injected through the adrenolumbar vein.

After observation in situ, the injected glands were removed and fixed with 10% formalin solution. Then they were macerated in industrial hydrochloric acid, one to three days. By this method such incompletely macerated neoprene casts of the vessels as to be convenient for the orientation of detailed structures were obtained.

For the coloring of neoprene latex, the present writer used black ink (PILOT Co.) at the rate of 10 to 15% to diluted neoprene. The black neoprene injected glands were sliced and

* This paper was prepared in partial fulfillment of the requirements for the degree of Master of Veterinary Medicine in the Faculty of Veterinary Medicine, Hokkaido University. It was presented March 25, 1960. A summary of this paper was published in this Journal, **8**, 219, 1960.

TABLE 1. *Materials Used for Observations*

NO.	SEX	WEIGHT	NO.	SEX	WEIGHT
		g			g
1	♂	470	25	♀	1250
2	"	900	26	"	1300
3	"	1500	27	"	1400
4	"	1500	28	"	1650
5	"	1950	29	"	1700
6	"	2200	30	"	1750
7	"	2300	31	"	1800
8	"	2400	32	"	1850
9	"	2750	33	"	1900
10	"	3200	34	"	2100
11	"	3200	35	"	2150
12	"	3450	36	"	2250
13	"	4200	37	"	2300
14	♀	430	38	"	2400
15	"	430	39	"	2400
16	"	450	40	"	2400
17	"	450	41	"	2700
18	"	520	42	"	2800
19	"	600	43	"	3200
20	"	800	44	"	4000
21	"	800	45	"	4200
22	"	1000	46	"	—
23	"	1100	47	"	—
24	"	1200			

cleared with glycerine. In these transparent specimens the vessels filled with the black neoprene were distinctly visible. After the observation of these sliced transparent specimens, the author macerated them in concentrated hydrochloric acid to obtain an accurately orientated cast preparation.

Some of the glands were injected with India ink solely, embedded in paraffin and sectioned. The sections were stained with hematoxylin and eosin stain, modificated Azan stain, WEIGERT's elastic fiber stain and GÖMÖRI's silver impregnation.

RESULTS

1. Arteries to the adrenal gland

The sources and courses of the arteries supplying the adrenal glands in the cats have been described in detail by BENNETT and KILHAM ('40), ABE and KUDO ('58) and HAYASHI

('59). The present author's findings were largely in accord with those of the earlier workers. The adrenal glands in the cats were seen to have no main arterial trunks, but to have at least about 15 small arteries from the abdominal aorta, the renal and phrenicoabdominal arteries in all cases, and in some cases, besides these sorts of arteries, from the superior mesenteric and coeliac arteries. In only one case, in this investigation, was the ovarian artery seen to supply the adrenal gland partially.

These arteries came near to the capsule of the adrenal gland, and branched into bifurcated or trifurcated smaller branches of the so-called "penicillar type" or "comb type" after ABE and KUDO ('58). Frequently, near the glands, there were found snaking or tortuous features of the arteries which seemed to be more conspicuous in the adult specimens than in the juvenile specimens (Figs. 2, 3 & 5). Most of these small arteries penetrated the capsule of the gland, but only a few of them sent branches to the capsule as the capsular arteries. These small arteries supplying the adrenal gland were seen frequently on the dorsal, cranial, caudal, medial and lateral surfaces, but rarely on the ventral surface, where the adrenolumbar veins ran along.

In the capsule, the majority of the arteries, except the capsular arteries, ran obliquely to the subcapsular region. In the intracapsular course, these arteries were seen with snaking or tortuous features and scarce branching.

At the subcapsular region, the tortuous features of arteries were not seen, but the bi- or trifurcating of arteries were repeated to build some arterial and capillary plexus between the capsule and the zona glomerulosa (Figs. 3. 5 & 6).

2. Distribution of the fine blood vessels

For the denomination of the arteries in the adrenal gland the names used by FLINT ('00) in dogs were used for convenience.

a) Capsular arteries (*A. capsulae* after FLINT, '00)

A few capsular arteries branched off from the juxtacapsular arteries as described above. They were distributed in the connective tissue of the capsule without direct connection with the subcapsular plexus and were so inconspicuous that injection into them was very difficult. By this investigation only a few faint ones were proved to exists contrary to denial of their existence by many authors. It was noted that there were a few inconspicuous arboreal branches of the capsular arteries and formations of inconspicuous coarse capillary nets from them in the capsule proper, without the building of any arterial plexus.

b) Cortical arteries (*A. corticis* after FLINT, '00) and cortical veins

The greater portion of the arterial blood supply of the cortex were seen to come from the subcapsular arterial plexus and to diverge into the capillary plexus. There were 2 different types of patterns found in the cortical arteries. Those of the first type were relatively few in number. They originated from the subcapsular arterial plexus and protruded into the cortical parenchyma, in which at various levels their courses were turned toward the capsule to the subcapsular region, where they diverged into capillaries. The arteries of the second type did not take such recurrent courses, but directly after branching off from the subcapsular plexus diverged into capillaries. The arteries of the first type seemed to correspond to the

arteries described in cats as "recurrent arteries" by BENNETT and KILHAM ('40).

Though these recurrent arteries were relatively few in number, there were several different patterns of them proved to exist. The present author classified the recurrent arteries, in his materials, by their courses and branching features, into 4 types, R. I to R. IV, as follows (Schema 1).

SCHEMA 1. *Types of Recurrent Arteries*

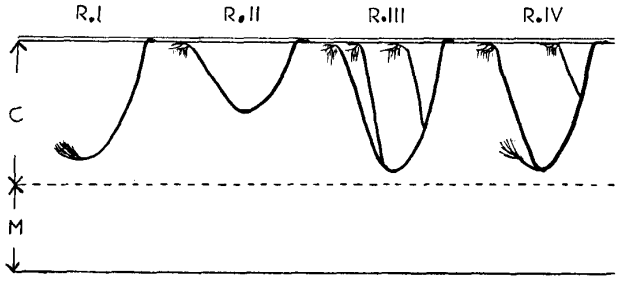

C: Cortex
M: Medulla

Type R. I: Incomplete recurrent type. Recurrent arm did not reach to the subcapsular plexus, but ended into the capillaries in the cortical parenchyma on their way. Of these, some arteries terminated in the capillaries in the inner part of the cortex (Nos. 33 & 39), and other one in the outer part of the cortex (No. 33).

Type R. II and R. III: Complete recurrent arteries.

Type R. II: Recurrent arm reached to the subcapsular plexus without branching in their courses, and their capillaries spread in the outer part of the cortex (Fig. 11). In this type the recurrences were generally occurred in the outer part of the cortex.

Type R. III: Recurrent arm divided into two or several smaller branches which extended up to the subcapsular plexus. In this type the recurrences were generally occurred in the deeper part of the cortex (Fig. 12).

Type R. IV: Mixed recurrent type. Combined form of the complete and incomplete types. In this type, out of several branches, some of the recurrent arms reached to the subcapsular plexus and others spread into the capillaries in the zona fasciculata or the zona reticularis (Fig. 13).

Table 2 presents the number of recurrent arteries observed in an entire gland on 10 side-specimens.

The number of reported recurrent arteries was variable, from 2 to 16 in a gland, owing to the difficulty of injection technique. More than half of them were the complete recurrent type of R. II and R. III, but the incomplete type of R. I and the mixed type of R. IV were found rarely. The diameter of the neoprene casts obtained in the recurrent arteries was variable from 20 μ to 260 μ.

During his observation, the writer found among the above mentioned recurrent arteries, some of which sent off capillaries or smaller arterial branches to the medulla, contrary to the uniformly held conception on the patterns of the adrenal vascularization. It might be wise to discuss these particular arteries later, because they seem to involve so important suggestions

TABLE 2. *Existence of Recurrent Arteries*

NO. AND SIDE	R. I	R. II	R. III	R. IV	TOTAL	STATE OF INJECTION
21R	•	•	•	•	•	no good
21L	•	•	•	•	•	"
42L	•	3 (1)	•	•	3 (1)	"
8R	•	•	•	•	•	good
8L	•	•	•	•	•	"
24L	•	•	•	•	•	"
5L	•	2	3 (2)	1	6 (2)	very good
29L	•	2	•	•	2	"
33R	2	•	2	1	5	"
39R	1	12	3 (1)	•	16 (1)	"
Total	3	19 (1)	8 (3)	2	32 (4)	

Notes ( ): Existence of corticomedullary arteries
R : Right side
L : Left side

concerned with the vascular patterns of the hypophysis cerebri, and concerned with the so-called "X zone" function.

The capillaries in the cortex were continuous to the subcapsular plexus and seemed to be arranged at a right angle to the capsule. By means of the transparent sliced specimens, arched features corresponding to the arrangements of the zona glomerulosa were well defined. In the zona glomerulosa, the surface of neoprene casts of the capillaries was smooth (Fig. 6). These glomerulosa capillary nets were continuous to the capillary nets in the zona fasciculata which were arranged parallel to cell columns of the zone. The neoprene casts in the zona fasciculata, in many specimens, were shown to give an irregular uneven surface like sinusoid features (Fig. 9). Such sinusoid features of the neoprene casts were variable by specimens, but their features were especially remarkable in the outer part of the zona fasciculata. The capillaries in this zone were continuous to the capillaries in the zona reticularis (Figs. 7, 8 & 9), where sinusoid features were seen.

The cortical capillaries converged into the medullary veins at the corticomedullary boundary (Figs. 7, 9, & 29). At the vicinity of the adrenolumbar vein, the capillaries of the adrenal cortex were continuous to the capillaries of the adrenal medulla without distinct demarcation. Such continuous capillaries between the cortex and the medulla were found frequently at the corticomedullary boundary in the juvenile specimens (Fig. 10).

Besides the above mentioned cortical arteries, the present writer observed a few arteries

which protruded into the cortical parenchyma, accompanying the trabecules. These trabecular arteries ran at a right angle to the capsule without recurring courses, and built up an inconspicuous plexus along the trabecules, from which they diverged into capillaries.

The writer did not succeed in obtaining injection casts of the cortical veins in most of the materials. In only 2 specimens, respectively, a vein originated in the capsule, passing through the cortex, and joined with the medullary vein (Nos. 11 & 24).

c) Arteries in the medulla

The arteries which came to the adrenal medulla branched from the intracapsular arteries, and penetrated down through the cortex, at a right angle to the capsule, protruding into the medullary parenchyma. They were defined as the "medullary arteries (*A. medullae*)" by FLINT ('00). Some investigators (FLINT, '00; OKANO et al., '56 & '60; NISHINA, '57 & HAYASHI, '59) called them "penetrating or perforating medullary arteries" owing to their branchless features in the cortex. Thus the medullary capillaries seemed to receive blood mainly through these medullary arteries.

These medullary arteries did not always take a similar patterns of arrangements; they were rather various in appearance. So the present writer needed to investigate them thoroughly by using his injected specimens. He was able to set up 4 pattern types, M.I to M.IV, according to their courses and branching forms, as follows (Schema 2).

SCHEMA 2. *Types of Medullary Arteries*

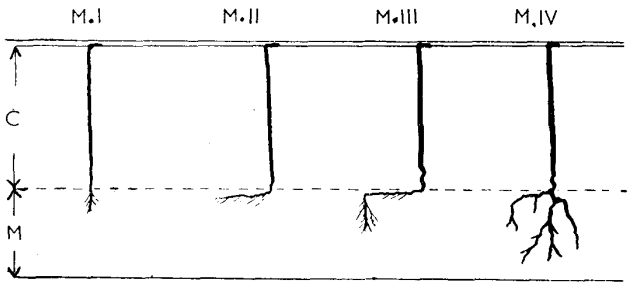

C: Cortex
M: Medulla

Type M. I.: The arteries of this type went down into the medulla, at a right angle to it, and at the entrances they broke down into medullary capillaries in the peripheral part of the medulla (Figs. 14 & 15). Their related areas were narrow and superficial to the medulla. The diameter of the arteries was about 30 μ in neoprene preparations.

Type M. II: The arteries of this type bent their courses ca. 90° at the corticomedullary boundary and tapered along the boundary (Fig. 15). In their courses, after bending they branched off several smaller arteries and many capillaries toward the medulla. Their related areas were wider than those of M. I. The diameter of the arteries was about 40 μ in neoprene preparations.

Type M. III: The arteries of this type were somewhat larger and bent their courses at the corticomedullary boundary like those of type M. II, but after a short way in the corticomedullary boundary, they bent again in their courses elongating toward the medullary parenchyma (Fig. 16). They had no branches, but diverged into capillaries in the deeper

medullary portion. Some of the arteries of this sort reached the medulla of the opposite side. The diameter was about 60 μ in neoprene casts.

Type M. IV: At the corticomedullary boundary, the arteries of this type sent off one or several branches, each of which took various courses as also in type M. I, M. II or M. III, so their related areas were wider and deeper than those of other types (Fig. 17). The diameter in neoprene casts was, from 60 to 190 μ, about 100 μ on the average.

The existence of each type of medullary arteries, on 10 side specimens of the writer's investigation are presented in table 3.

TABLE 3. *Existence of Medullary Arteries*

NO. AND SIDE	M. I	M. II	M. III	M. IV	TOTAL	STATE OF INJECTION
21R	6	4	•	2 (1)	12 (1)	no good
21L	15 (1)	5 (1)	•	2	22 (2)	"
42L	12	1 (1)	•	3 (1)	16 (2)	"
8R	12 (2)	8 (2)	•	2	22 (4)	good
8L	20 (3)	3 (1)	1	2	26 (4)	"
24L	8 (2)	4	2	7 (2)	21 (4)	"
5L	33 (1)	7 (3)	7 (2)	4 (1)	51 (7)	very good
29L	7 (3)	4	9 (5)	7 (5)	27 (13)	"
33R	24 (4)	2 (2)	2 (1)	1	29 (7)	"
39R	24 (10)	5	•	5 (1)	34 (11)	"
Total	161 (26)	43 (10)	21 (8)	35 (11)	260 (55)	

The states of injection of the neoprene were not always entirely constant with the results that the number of the medullary arteries found was variable by specimens. Out of 10 side specimens 4 ones, which were sufficiently injected, had medullary arteries 29 to 51 in number. Accordingly, it seems to be expected more than 30 of medullary arteries should be observed in each specimen, if the injection was sufficient.

There was also found another sort of arteries in addition to those penetrating the medulla. The arteries of this sort usually were few in number, ran along the wall of the adrenolumbar vein, and came into the medulla in company with some connective tissue through the hilus of the organ without directly penetrating the cortical parenchyma (Fig. 18).

It was especially noticed that, in many cases, the medullary arteries showed conspicuous constriction and dilation of their wall, and remarkable snaking or coiling features in their

courses in the deep portion of the cortex and the corticomedullary boundary portion. The arteries of types M.III and M.IV, frequently, presented such features even in the medulla (Figs. 14~17). These features seemed not to relate to the type differences, but to relate to individual characteristics such as age, etc. In general, they were rather inconspicuous in young individuals and more remarkable in the older specimens.

These features in the medullary arteries seemed to correlate with similar features of the extracapsular and intracapsular arteries. The present writer's interest for these features made him arrange his data about them. The adrenal glands could be classified into 3 groups with respect to these features. In the first group of glands no very conspicuous features were seen in any arteries; in the second group of glands these features were found in the extracapsular and medullary arteries, but not in the intracapsular arteries. In the third group, these features were conspicuous in any sort of arteries. In general, the first group seemed to correspond to young specimens, the second and third group to adult specimens, and the convolution of the intracapsular arteries seemed to appear most tardily.

d) Capillary pattern of the medulla and medullary veins

The medullary arteries diverged into capillaries between the medullary veins, making medullary capillary nets, from which the blood flowed into the medullary veins (Fig. 29).

The medullary capillaries, with smooth surface in neoprene casts, and with relatively large meshes, emptied into the medullary veins in small groups. The medullary veins gradually grew to larger veins, and at last 4 to 6 medium-sized medullary veins joined with the adrenolumbar vein on the venous groove (Figs. 26~29). Thus, in cat's adrenal gland, there was seen no single large medullary vein, but several medium-sized medullary veins which emptied into the adrenolumbar vein, respectively.

The present writer observed, besides these findings, the anastomoses between the medullary vein and the medullary artery (No. 39), and between the two medullary arteries in the medulla (Nos. 35 & 39).

Especially, some of the medullary arteries branched off smaller arteries or capillaries toward the cortex, and some of the arms of such arteries reached the level of the subcapsular plexus. This sort of arteries belonged not to any previously known category of adrenal gland arteries because by most investigators the cortex and the medulla of this gland were thought to be nourished respectively by independent arteries. So the writer was obliged to set up a new type of arteries under a special conception for these arteries such as a "corticomedullary artery".

e) The present writer's so-called corticomedullary arteries

Contrary to the opinion of previous investigators who thought the arterial system supplying the cortex and the medulla of the adrenal glands were independent, the present writer found many single arteries supplying both the cortex and the medulla.

Some of them corresponded to the variants of the recurrent or medullary arteries respectively, while others were regarded as the combined forms of both arteries. The writer provisionally named them "corticomedullary arteries (*A. corticomedullae*)" and classified them into 6 types according to their patterns, CM.I to CM.VI, as follows (Schema 3).

It was seen that types CM.I and CM.II could be regarded as variants of the recurrent

SCHEMA 3. *Types of Corticomedullary Arteries*

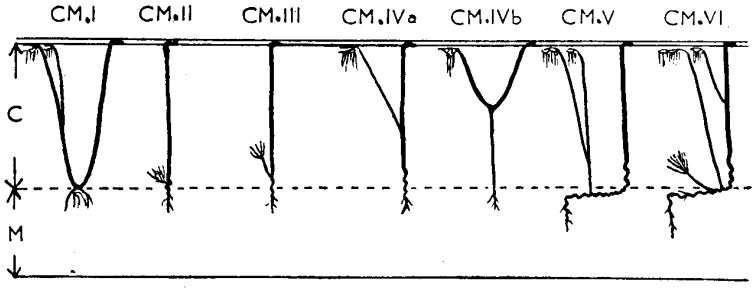

C : Cortex
M : Medulla

arteries and of the medullary arteries respectively, whilst types CM.III, CM.IV, CM.V and CM.VI could be regarded as combined forms of the two arteries. Amongst them, the last four types were classified by the features of their recurrent branches.

Type CM.I : (Nos. 5, 38 & 42) Arteries of the complete recurrent type which at the corticomedullary boundary had capillaries continuous to those of the medulla (Fig. 19).

Type CM.II : (Nos. 1, 4, 5, 6, 8, 21, 24, 25, 29, 33, 39, 41, 44, & 46) Some medullary arteries which branched off capillaries into the cortical parenchyma within the cortex (Fig. 20). Many of the capillaries from these arteries were found in the zona fasciculata or reticularis. A majority of this sort of arteries corresponded to type M.I above described.

Type CM.III : (Nos. 5, 7, 8, 21, 24, 25, 29, 33, 39 & 44) Some medullary arteries which branched off small arteries, which diverged to the cortical capillaries. These were regarded as belong to the combined form of the medullary arteries with the incomplete recurrent one (R.I). There were seen many recurrent branches continuous with the cortical capillaries in the inner cortex (Figs. 21 & 22).

Type CM.IV : Arteries which seemed to be combined forms of the medullary arteries with the complete recurrent one (R.II.). The arteries of this type were subclassified into 2 subtypes, CM.IVa (Nos. 1, 3, 5, 8, 12, 14, 25, 29, 33, 37, 39, 45 & 46), in which the medullary arteries were well defined, and CM.IVb (Nos. 5, 29, 33 & 39), in which the recurrent arteries were well defined. Arteries of type CM.IVa were found in many cases, and the recurrent branches occurred in every zone of the cortex or in the medulla (Fig. 23). Arteries of type CM.IVb were found in only a few cases with the medullary branches occurring adjacent to the recurrent point (Fig. 24).

Type CM.V : (Nos. 4, 25, 33 & 45) A combined form of the medullary artery with complete recurrent one (R.III). The recurrent branches were several; in many cases they were divided in the medulla (Fig. 25) and in a few cases in the mid-part of the cortex.

Type CM.VI : (No. 33) A combined form of the medullary arteries with the mixed recurrent one (R.IV). Arteries of this type were rare; in only one case 2 arteries were observed. Each of them branched two complete recurrent arteries and an incomplete recurrent artery spraying out in the zona reticularis.

On the 10 sides of glands, in which arteries were observed to be well injected in the whole organ exactly, the corticomedullary arteries were found as follows (Tables 2 & 3): out

of recurrent arteries, an artery of type CM.I and 3 of CM.IVb, total number 4, 12.5%, and out of 260 medullary arteries, 20 of CM.II, 4 of CM.III, 27 of CM.IVa, 2 of CM.V and 2 of CM.VI, total number 55, 21.5% were found in this investigation.

DISCUSSION

The vascular structures of the adrenal glands in various animals have been observed by many previous investigators. Many of their findings were obtained from transparent specimens injected with India ink or other pigments (FLINT, '00; BENNETT & KILHAM, '40; HAYASHI, '59) or with stereoscopic injected casts (LEVER '52; OKANO et al., '56 & '60; NISHINA, '57).. But there are many unsolved and uncertain problems in the vascular patterns of the adrenal glands, due to difficulties of the injection method and multiple sources of the adrenal arteries.

In this research the neoprene latex injection method was improved in coloring by the use of a sort of black ink ("PILOT ink for fountain pens made in Japan"). Such black latex can be recommended as a suitable injection material for stereoscopic observation of detailed arrangements of fine blood vessels in organs, because the very same transparent slice preparations are transformable into stereoscopic specimens.

In this research, the adrenal glands of cats were found to be supplied not by a main arterial trunk but by many small arteries from several sources such as the abdominal aorta, the renal, phrenico-abdominal, coeliac, superior mesenteric and ovarian arteries. This is as shown by BENNETT and KILHAM ('40), HARRISON ('51), ABE and KUDO ('58) and HAYASHI ('59) in cats, and in various other animals also: FLINT ('00) in dogs, TSUKAMOTO ('30), TOMIOKA ('36), PICK and ANSON ('40) in humans, HARRISON ('51) in rabbits and rats, LEVER ('52) in rats, HARRISON and ASLING ('55) in monkeys, NISHINA ('57) in dogs, cows and rabbits, EZAKI ('58) in mice and HAYASHI ('59) in dogs.

The arteries to the adrenal gland repeatedly divide two or three times before their entrance into the gland. These extracapsular arteries show conspicuous snaking features, and after entrance into the capsule the snaking features seem to be more conspicuous. The arteries which nourish the capsule proper are inconspicuous, and difficult to be seen. In this research, in only a small number of specimens, a few small arteries were found to form poor capillary nets in the capsule. This sort of artery was demonstrated as capsular arteries by FLINT ('00) in dogs, but BENNETT and KILHAM ('40) denied the existence of such arteries in the cat, whilst other investigators did not offer any description. As above mentioned, the existence of the so-called capsular arteries in cats is an actual fact, but in many cases they might have escaped the attention of investigators, because of the difficult injection for rendering them visible.

In the subcapsular region, arteries branch respectively several times to form a distinct arterial plexus there. This plexus corresponds to the subcapsular plexus described by BENNETT and KILHAM ('40) in cats, "Reticulum capillarium infracapsulare" by OKANO et al. ('60) in cats, and to the subcapsular plexus by HAYASHI ('59) in dogs and cats and by EZAKI ('58) in mice. The majority of the arteries to the adrenal parenchyma are considered to pass through the plexus; some of them from the plexus divide into the capillaries which enter into the cortex as cortical capillaries. Whilst other arteries from the plexus branch off smaller branches which enter the gland as cortical recurrent or the arteries which penetrate the medulla.

Besides these subcapsular plexus, FLINT ('00), NISHINA ('57) and OKANO et al. ('60) each described the plexus found in the capsule in dogs. The present writer did not find any arterial plexus developed in the capsule.

In the cortical arteries, there were found two different patterns according to the courses: the one is of ordinary arteries which immediately spread into the capillaries of the subcapsular plexus continuous to the capillary nets of the cortex, the other one is of those arteries which correspond to the recurrent arteries described by BENNETT and KILHAM ('40) and others.

In this investigation, the recurrent arteries were classified into 4 types (R.I to R.IV), on the basis of their courses and branching features. Type R.I shows incomplete recurrent form; its recurrent branch spreads into cortical capillaries, before the subcapsular plexus, in the relatively deeper portion of the cortex. Types R.II and R.III show the complete recurrent forms. In these types, arteries return to the subcapsular plexus without sending out cortical capillaries. In type R.II, there are no branches to the recurrent arms, but in type R.III, there are two or more comparatively smaller branches to the recurrent arms long enough to reach the plexus. Type R.IV shows mixed recurrent type, combined of the incomplete and the complete types.

Recurrent arteries similar to the writer's type R.I were reported by HAYASHI ('59) in cats; those of type R.II by BENNETT and KILHAM ('40) in cats, GERSH and GROLLMAN ('41) in mice, EZAKI ('58) in mice and HAYASHI ('59) in cats, those of type R.III by BENNETT and KILHAM ('40) in cats. But arteries of type R.IV have not been reported by previous investigators within the scope of the present writer's references at hand.

FLINT ('00) noted the arteries which entered the cortex at a right angle to the capsule, and spread out into the cortical capillaries. These arteries should be treated as ordinary cortical arteries, even though their straight courses in the cortical parenchyma are somewhat longer than the ordinary cortical arteries of the present writer.

About the meaning and mechanism of recurrence of these arteries, no explanations nor considerations have been published. Recently, YAMASHITA ('59) reported that, in the corpus luteum of the sow, by use of neoprene injection method, he observed similar recurrent arteries. This analogy of the arterial patterns in both hormonal organs seems not to be a fortuitous circumstance, because of the parenchymatous structures in both organs.

YAMASHITA ('59) has not given any explanation for this phenomenon, but the present author would like to explain it as that, by the development of the corpus luteum extension or protrusion of arteries should occur prior to the development of the parenchyma, accompanied by the plica-like elevation of the ruptured follicle wall, so that these arteries should show the recurrent features. In the adrenal gland, also, the cortical arteries should be expected to extend prior to the development of the parenchyma resulting as recurrent cortical arteries. But, in the adrenal gland, in which the process of the development of the parenchyma should be more speedy, the relation seems not so exact clear definite as that in the corpus luteum. If this explanation of the recurrent arteries should prove to be correct, the existence would be understood of various features (4 types) of pattern in the adrenal gland, and their grades of development would be easily understood.

From the results obtained by BENNETT and KILHAM ('40) and others, the capillaries from the subcapsular plexus are generally thought to extend into the cortex running along the cellular cords of the cortex down to the medulla. Moreover, in this research in cats, the present writer found that the neoprene casts of capillaries showed somewhat different features, especially the casts in the zona fasciculata, in many cases, irregular uneven surfaces were obscured, like sinusoid features, different to the smooth surface of capillaries in other zones. BENNETT and KILHAM ('40) noted that the capillary spaces in the outer fasciculata (the secretory zone) were narrow, whilst those in the inner fasciculata (the post-secretory zone) and the zona reticularis (the senescent zone) were wide. They considered that the secreting cells in the secretory zone might swell up sufficiently to compress the capillaries, so that injected India ink could not pass through them. The writer's sinusoid features of the neoprene casts in the zona fasciculata also seem to suggest the special functional activities of this region.

The present writer observed, as have many other investigators, that the cortical capillaries are collected into the medullary veins at the corticomedullary boundary.

Since MITSUKURI (1882) first noted that the adrenal gland in mammalia, histologically, consisted of the cortex and the medulla, it became accepted as a decided fact that the cortex comes from the mesodermal epithelium and the

medulla comes from the sympathetic ganglion (INABA, 1891; FLINT '00).

FLINT ('00) studied the arterial system in the gland, and distinguished them into two clear cut independent parts on the basis of supplied areas, treating them as cortical and medullary arteries respectively. After him, many investigators, BENNETT and KILHAM ('40), NAKAYA ('42), LEVER ('52), OKITA ('53), OMURA ('54), OKANO et al. ('56 & '60), NISHINA ('57), EZAKI ('58) and HAYASHI ('59), substantiated FLINT's findings in various mammalia; as a general conception, the medullary arteries are branches of the intracapsular arteries which, on their courses in the cortex, do not send off branches or capillaries for the cortical parenchyma. Because of this fact, some investigators (FLINT, '00; OKANO et al., '56 & '60; HAYASHI, '59) termed them as penetrating or perforating medullary arteries. But this conception of the medullary artery is not always correct; there are some exceptional cases which may prove to have important significance.

The writer's present investigation of the medullary arteries led him to classify them into 4 types (M.I to M.IV), according to these courses and the branching features of the trunk in the medulla.

The arteries of type M.I do not change their courses in the medulla; they divide into the medullary capillaries at the corticomedullary boundary or in the superficial region of the medulla. The arteries of type M.II, after change their courses, run along the corticomedullary boundary, sending capillaries into the medulla. The arteries of type M.III change their courses like those of M.II, protruding into the deeper part of the medulla, where they spread into the capillaries. These arteries of types M.I, M.II and M.III are the ones which send off capillaries into the medulla. The arteries of type M.IV are those with two or more well-developed branches, each of which follow pathway similar to those of type M.I, M.II, or M.III; some of the branches reach the opposite side of the medulla. Types M.I, M.II, M.III and M.IV are shown as grades of complex structures with deeper and wider supplying areas in turn. In the medullary arteries, which belong to the type M.I fall more than half of the total number of medullary arteries.

The alternate occurrence of conspicuous constriction and dilation, and the existence of snaking or coiling features of the medullary arteries at the corticomedullary boundary or in the medulla have been described by BENNETT and KILHAM ('40) in cats and NISHINA ('57) in cats, dogs, cows and rabbits. In this research, also, similar features observed in the medullary arteries. Moreover, it is noticed that they seem to correlate with similar features in the extracapsular arteries and the intracapsular arteries. The occurrence of such irregular changes of vascular spaces or tortuous features of the restricted part of every specific artery seems to relate to the individual condition of the animals such as their

age. In fact, those characters of the glands in young cats show themselves less conspicuous than in the adult ones.

Similar features are known in the uterine arteries which exhibit tortuous and coiling features according to aging and pregnancy. And as an analogy in wide sence, there are many arteries such as the "Rete mirable" of the cephalic basilar artery and the external ophthalmic artery in the ruminants, and the pampiniform plexus of the ovarian and testicular arteries.

In the adrenal glands, also, such features seem to become more remarkable with aging. It may be considered that, when the adrenal glands should be activated for the "systemic stress" by SELYE ('50), the blood stream supplied the glands should be increased, and there should be needed the appearance of the regulating characters of related arteries, resulting in formation of these structures especially discussed in this paper.

Each medullary artery spreads into medullary capillaries among the medullary veins. The medullary capillaries in groups empty into the larger medullary veins; these veins unite in turn into 4 or 6 veins which join with the extra-glandular adrenolumbar vein which run along the venous hilus of the ventral surface of the gland.

Among many investigators, only BENNETT and KILHAM ('40), OKANO et al. ('56 & '60) and HAYASHI ('59) described the arteries which supplied the cortex and the medulla simultaneously, as exceptional cases. Contrawise them, the present writer found so many arteries which supplied the cortex and the medulla simultaneously, that he could not treat them as exceptional ones. So he has provisionally named them "corticomedullary arteries." These so-called corticomedullary arteries could be classified into 6 types (CM. I to CM. VI).

The arteries of type CM. I are considered as variants of the recurrent artery; the arteries of CM. II are considered as variants of the medullary and those of types CM. III to CM. VI are as combined ones of the recurrent and medullary arteries.

The arteries of type CM. I turn upward to the capsule at the corticomedullary boundary and at the portion adjacent to it send capillaries to the medulla. In type CM. II, a sort of medullary arteries sends capillaries to the cortical parenchyma, so as to communicate with the cortical capillary nets. In type CM. III, a sort of medullary artery branches off smaller arteries which, after a short distance, spreads into the cortical capillaries in the cortex. The arteries of this type are seen as a combined form of the medullary with an incomplete recurrent artery (R. I). The arteries of type CM. IV are shown as a combined form of the medullary with the complete recurrent artery (R. II), and are differentiated into subtype CM. IVa, in which the character of the medullary artery is predominat,

and subtype CM. IV b, in which the recurrent artery is predominant. The arteries of type CM. V also show a combined form of the medullary with complete recurrent artery (R. III) and have two or several recurrent branches in the cortex or medulla. The arteries of type CM. VI show a combined form of the medullary with the mixed recurrent artery; some of the branches reach to the capsule and others spread out into cortical capillaries as incomplete recurrent arteries.

From amongst these corticomedullary arteries, the arteries of types CM. III, CM. IV b and CM. V have already been described by previous investigators. The arteries of type CM. III are similar to those of HAYASHI ('59) in cats as variants of the medullary arteries; the arteries of type CM. IV b are similar to those of BENNETT and KILHAM ('40) in cats as variants of the recurrent arteries; those of CM. V are similar to the arteries described by OKANO et al. ('60) in dogs and cats as variants of the medullary arteries.

The corticomedullary arteries were found to provide more than 20% of the total number of the recurrent and medullary arteries. The injection into the vessels of the adrenal glands is so difficult, that insufficiently injected specimens have been used often by investigators. Even the neoprene casts, which have been thought to be the most suitable specimens, were not completely injected ones, so if the injection are perfect, the so-called "corticomedullary arteries" would be found to exist in a still high percentage.

LOBAN ('52) noted that the zona reticularis of the cat varied with the sexual condition, and HOLMES ('55) stated that the zona reticularis of the cat corresponded to the "X zone" in the rodentia. Thus, the concept of the zona reticularis, explained as being inactive in the "cell migration theory", is in conflict with the "X zone" or the active zona reticularis. TAKAKUSU ('58) observed that each zone of the adrenal cortex in rabbits developed independently, and he noted that the functions of the cortex should be different in each zone. HARRISON ('51), HARRISON and ASLING ('55) made ligation-experiments on the single arteries of the adrenal arteries in the rabbit, rat, monkey and the cat, producing focal necrosis of the cortical tissue of the gland. They reported that, in their experiments, perfect necrosis of the gland was observed only in the zona fasciculata.

The just mentioned statements by TAKAKUSU, HARRISON and ASLING seem to explain the different functions in each zone of the adrenal cortex. In the present research, the small arterial branches or capillaries of the recurrent arteries (types R. I & R. IV) and the corticomedullary arteries (types CM. II, CM. III & CM. VI) were found to communicate with the capillaries in each zone of the cortex.

Morever, there was noticed the existence of communication between the cortical capillaries and the medullary capillaries. Thus, the blood supply of the adrenal cortex is not completely different from that of the medulla in cats, in

respect to which the "X zone" corresponding portion in the adrenal gland has been set up by some investigators.

SUMMARY

The fine vascular patterns of the adrenal gland of the cat were investigated use being made of 47 cats with the newly improved neoprene latex injection method, because reinvestigation of the vascular arrangements has been needed for the explanation of their functions, according to the recent improvement of conception for the adrenal gland such as the "stress theory" by SELYE and the "X zone" function of rodentia.

Results obtained and conclusions reached were as follows:

1) Approximately 15 different adrenal arteries were proved in this investigation to come from the several different sources previously known, and as an exceptional case even from the ovarian artery.

2) Besides the cortical and medullary arteries, capsular arteries were proved to exist in the cat's adrenal gland contrary to opinions of previous investigators who denied it in this gland.

3) From amongst the cortical arteries the recurrent arteries were differentiated, and after careful observation, the latter were classified 4 types (R. I to R. IV). From these, arteries of type R. IV were newly distinguished ones.

4) It was thought that there might be an analogy between the recurrent arteries of the adrenal gland and those of the corpus luteum.

5) The ordinary medullary arteries were investigated and differentiated into 4 types (M. I to M. IV). From amongst them, the arteries of type M. IV were newly differentiated ones by the present writer.

6) The number of medullary arteries in a single adrenal gland is expected to be 30 to 50 or a little more on the basis of this investigation.

7) There were 3 sorts of arteries proved to have snaking or tortuous or coiling features and restricted portions with remarkable constriction and dilation. These were extracapsular, intracapsular and medullary arteries.

8) These abnormal features in the vascular spaces seemed to occur simultaneously, and those of 3 different portions seemed to correlate with other.

9) The present writer would like to denominate a new sort of artery as a "corticomedullary artery" in the adrenal gland of the cat. Some of arteries of this sort were described in previous literature, but in such reports the occurrence of these arteries was treated as inconstant, and exceptional cases.

10) The corticomedullary artery was seen to account for 20% of the cortical and the medullary arteries, and a rather higher percentage of discovery is expected with the improvement of investigating methods.

11) The corticomedullary arteries were classified into 6 types (CM. I to CM. VI). From amongst them, the arteries of types CM. III, CM. IVb and CM. V are considered in previous report as exceptional cases of arterial patterns, whilst the arteries of other types, CM. I, CM. II, CM. IVa and CM. VI are newly differentiated ones.

12) The states of capillaries of the adrenal gland were investigated, and a distinct sinusoid structure was proved in the outer half of the zona fasciculata as a conglomerated capillary mass with uneven irregular surface.

13) Capillaries of other part in the cortex formed stretched network, and short narrow meshes in the medulla.

14) Between the capillary nets of the cortex and the medulla distinct communication was proved to exist.

15) These corticomedullary capillary communication and the constant occurrence of the corticomedullary arteries seemed to suggest an important significance in respect to the adrenal function such as the X zone activity, because recently the "X zone" of this organ was proved to be a sexual reactive part.

16) The "cell migration theory" of the adrenal cortex and the conception of the "X zone" activity seem to conflict with each other, but in the view of vascular arrangements and blood supply it seems to be possible to reconcile this conflict.

The author wishes to thank Prof. K. TAKAHATA for his constant guidance and Messrs. N. KUDO, M. SUGIMURA, K. FURUHATA and M. ABE for their kindness in helping in this investigaion.

REFERENCES

1) ABE, M. & N. KUDO (1958): *Jap. J. Zootech. Sci. Hokkaido Shibukaiho*, **1**, 7 (in Japanese).
2) BENNETT, H. S. (1940): *Amer. J. Anat.*, **67**, 151.
3) BENNETT, H. S. & L. KILHAM (1940): *Anat. Rec.*, **77**, 447,
4) BENNETT, H. S. (1941): *Amer. J. Anat.*, **69**, 333.
5) ELLENBERGER, W. & H. BAUM (1921): Handbuch der vergleichenden Anatomie der Haustiere. 16 Auf. 614, Berlin.
6) EZAKI, T. (1958): *J. Kur. M. A.*, **21**, 1332 (in Japanese).
7) FLINT, J. M. (1900): *Johns Hopk. Hosp. Rep.*, **9**, 153.
8) HARRISON, R. G. (1951): *J. Anat. Lond. Rep.*, **85**, 12.
9) HARRISON, R. G. & C. W. ASLING (1955): *Ibid.*, **89**, 106.
10) HAYASHI, T. (1959): *Fukuoka Acta med.*, **50**, 2861 (in Japanese).
11) HOLMES, W. N. (1955): *Anat. Rec.*, **122**, 271.
12) INABA (1891): *J. Coll. Sci., Imp. Univ., Tokyo, Japan*, (cited from FLINT).
13) LEVER, D. J. (1952): *J. Anat. Lond.*, **86**, 459.
14) LOBAN, C. M. (1952): *J. Physiol.*, **118**, 565.

15) MITSUKURI (1882): *Quart. J. micr. Sci.*, (cited from FLINT).
16) NAKAYA, T. (1942): *Jap. J. med. Sci., Anat.* **9**, 113.
17) NISHINA, N. (1957): *Folia endocrin. jap.*, **33**, 665 (in Japanese).
18) OKANO, H. & Y. OHTA (1956): *Kaibo Z.* **31**, 115 (in Japanese).
19) OKANO, H., Y. OHTA, H. SAWA & I. FUJIWARA (1960): *Okajimas Folia anat. jap.*, **34**, 553.
20) OKITA, M. (1955): *J. Hiroshima med. Ass.*, **3**, 235 (in Japanese).
21) OMURA, H. (1954): *Mitt. med. Ges. Chiba.*, **30**, 64 (in Japanese).
22) PICK, J. W. & B. J. ANSON (1940): *Anat. Rec.*, **78**, 1.
23) SELYE, H. (1950): The physiology and pathology of exposure to stress. 1st ed., Montreal: Acta Inc. Medical Publisher.
24) TAKAHATA, K. (1955): *Kobunshi*, **4**, 63 (in Japanese).
25) TAKAHATA, K., N. KUDO & K. FURUHATA (1956): *Japan Plastics*, **7**, 34 (in Japanese).
26) TAKAKUSU, A. (1958): *Med. J. Osaka Univ.*, **9**, 289.
27) TOMIOKA, T. (1936): *Mitt. med. Ges. Tokio*, **50**, 950 (in Japanese).
28) TSUKAMOTO, N. (1930): *Kaibo Z.*, **2**, 780 (in Japanese).
29) YAMASHITA, T. (1961): *Jap. J. vet. Res.*, (in press).

Explanation of Plates

C : Cortex
M : Medulla
zg : Zona glomerulosa
zf : Zona fasciculata
zr : Zona reticularis
Am : Medullary artery
Vm : Medullary vein
Va : Adrenolumbar vein

Plate I.

Fig. 1. Ventral aspect of the adrenal gland in a juvenile cat. Venous hilus distinct, and an artery (arrow) enters the capsule of the gland without branching. × 4.4

Fig. 2. Dorsal aspect of fig. 1. Many arteries are found on the dorsal surface. × 4.4

Fig. 3. Intracapsular arteries and subcapsular plexus (adult cat). Intracapsular arteries with conspicuous coiling and extracapsular artery (above) with comparatively coarse snaking. × 23

Fig. 4. Capsular arteries (arrow) from extracapsular artery. Intracapsular arteries with snaking. × 17.5

Plate II.

Fig. 5. Small subcapsular artery and accompanying capillary plexus. × 46

Fig. 6. Subcapsular plexus (below) and cortical capillaries (above). × 20

Fig. 7. Cortical capillaries and medullary veins. At the corticomedullary boundary capillaries are collected into medullary veins. Capillaries in the zona fasciculata with long out-stretched mesh works (retrogradely venous injection). × 50

Fig. 8. Cortical capillaries and medullary vein. Capillaries in the zona reticularis seem to join with medullary capillaries (arrow). × 100

Fig. 9. Cortical capillaries. In the zona fasciculata capillaries with uneven surface as sinusoid feature. In the zona reticularis are seen capillary nets but not sinusoid. × 46

Fig. 10. Specimen from a juvenile cat, cortical and medullary boundaries are indistinct, on account of communicating capillaries between them. × 50

Plate III.

Fig. 11. A recurrent artery of type R. II and a medullary artery of type M. I (with coiling feature). × 23

Fig. 12. A recurrent artery of type R. III. × 46

Fig. 13. A recurrent artery of type R. IV. A recurrent branch is seen to spread

into the capillaries in the zona fasciculata and other branches are seen to reach to the subcapsular plexus. × 23

Fig. 14. A medullary artery of type M. I. Coiling feature and dilation of the artery are seen in the deeper cortex. × 23

Fig. 15. Medullary arteries of types M. II (right) and M. III (left); coiling feature is seen. × 17.5

Fig. 16 Medullary arteries of types M. III (right) and M. IV (left). Conspicuous snaking features are seen in the medulla. × 23

PLATE IV.

Fig. 17. A medullary artery of type M. IV. × 23

Fig. 18. A medullary artery (arrow) in the portion of the venous groove. The artery enters the medulla without penetrating the cortex. × 23

Fig. 19. A corticomedullary artery of type CM. I. Medullary capillaries (arrow) are seen to be sent at the branching point. Recurrent artery is of type R. III. × 23

Fig. 20. A corticomedullary artery of type CM. II. A medullary artery of type M. II sends distinct cortical capillaries into the zona reticularis (arrow). × 46

Fig. 21. A corticomedullary artery of type CM. III. A medullary artery of type M. III gives off a recurrent branch to the subcapsular plexus (arrow). × 23

Fig. 22. The same corticomedullary artery of type CM. III as Fig 21. ×50

PLATE V.

Fig. 23. A corticomedullary artery of type CM. IVa. A medullary artery of type M. III sends out a recurrent branch to the subcapsular plexus (arrow). × 23

Fig. 24. A corticomedullary artery of type CM. IVb. A recurrent artery sends out a medullary artery (arrow) which breaks up into medullary capillaries in the medulla. × 23

Fig. 25. A corticomedullary artery of type CM. V. Two complete recurrent branches originate from the medullary artery at the corticomedullary boundary (arrow). × 23

Fig. 26. The cortex (above) and the medulla (below). A comparatively thicker medullary vein is found. × 17.5

Fig. 27. Medullary veins. × 23

Fig. 28. Medullary veins. × 23

PLATE VI.

Fig. 29. A medullary artery and veins. The medullary artery breaks up into the medullary capillaries between the medullary veins. × 100

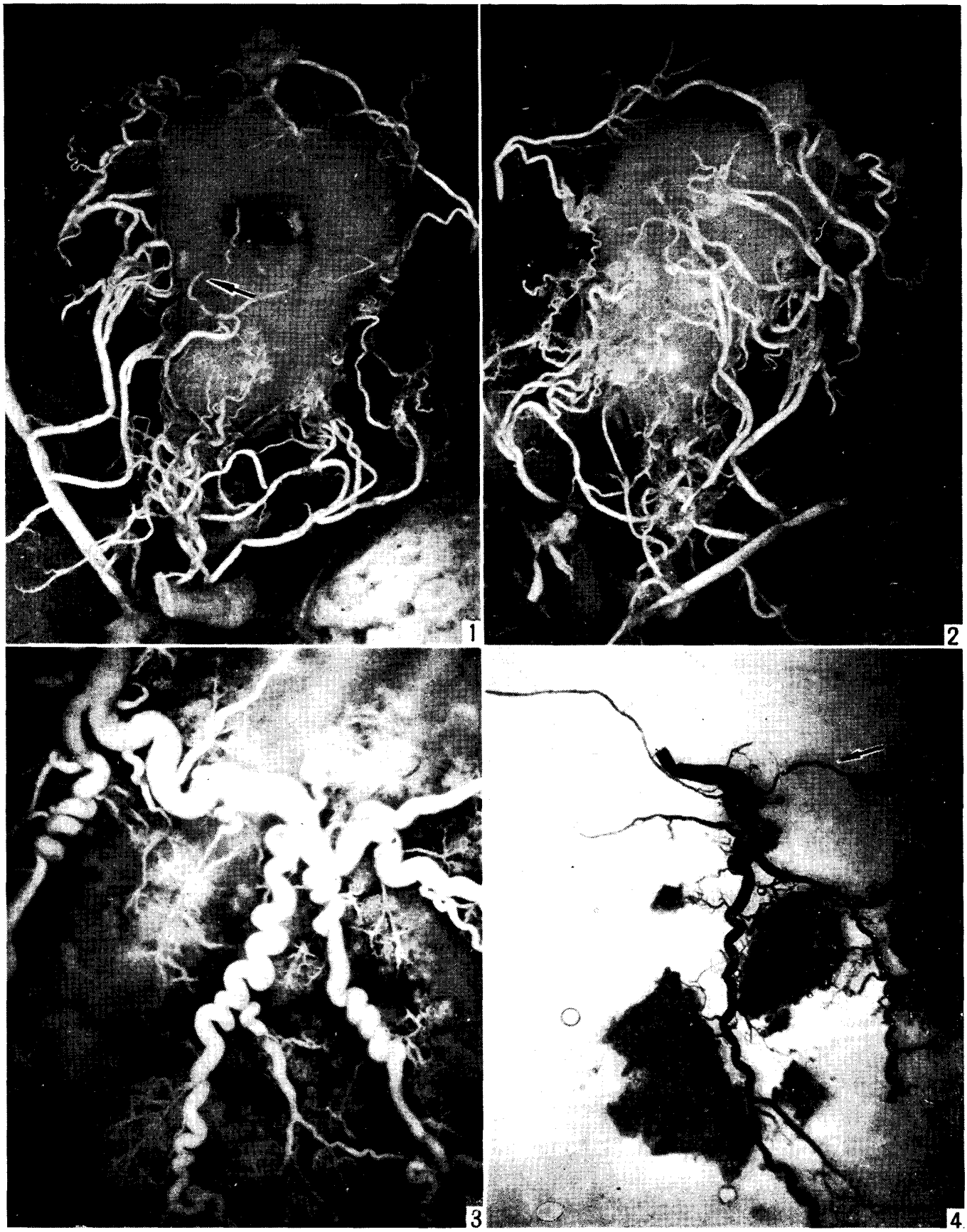
1
2
3
4


5

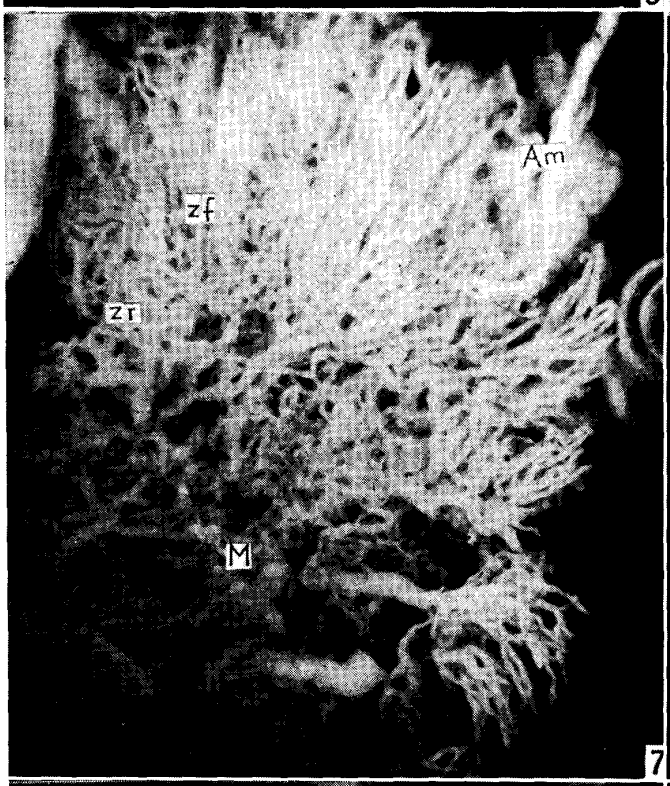
Am
zf
zr
M
7

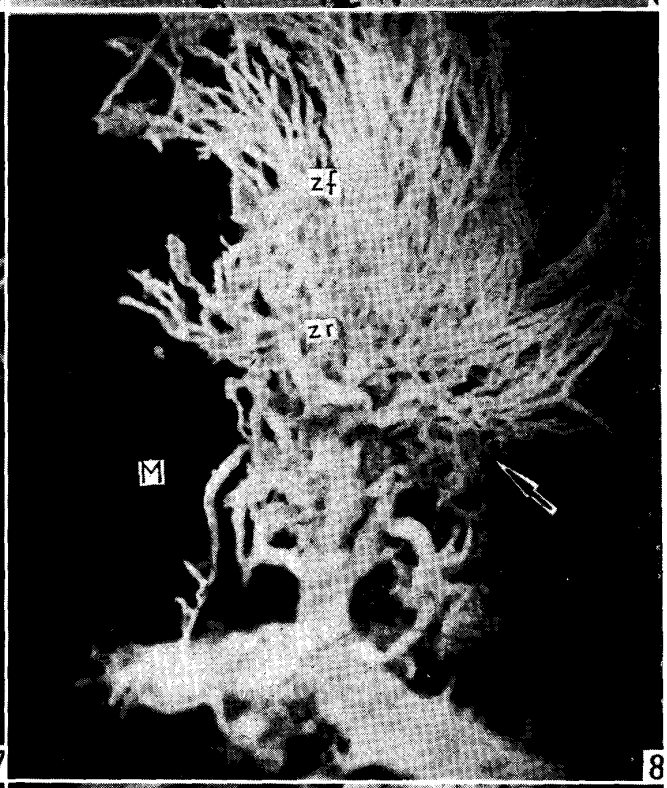
zf
zr
M
8

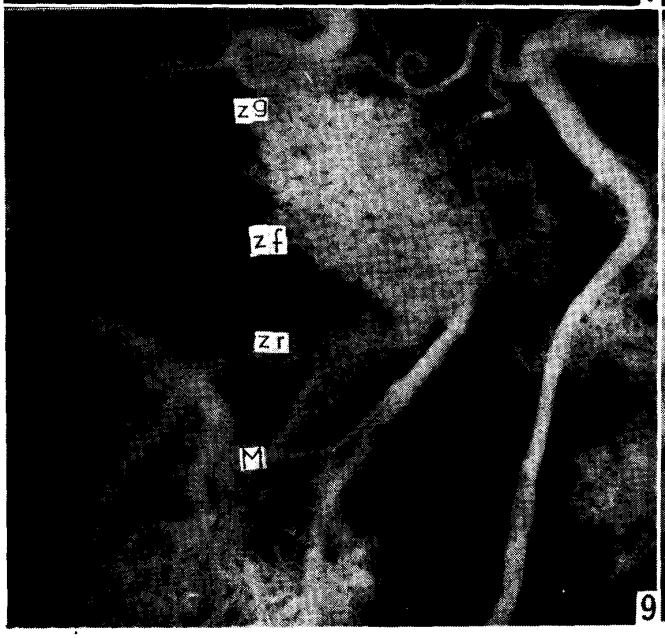
zg
zf
zr
M
9


Am
C
M
10

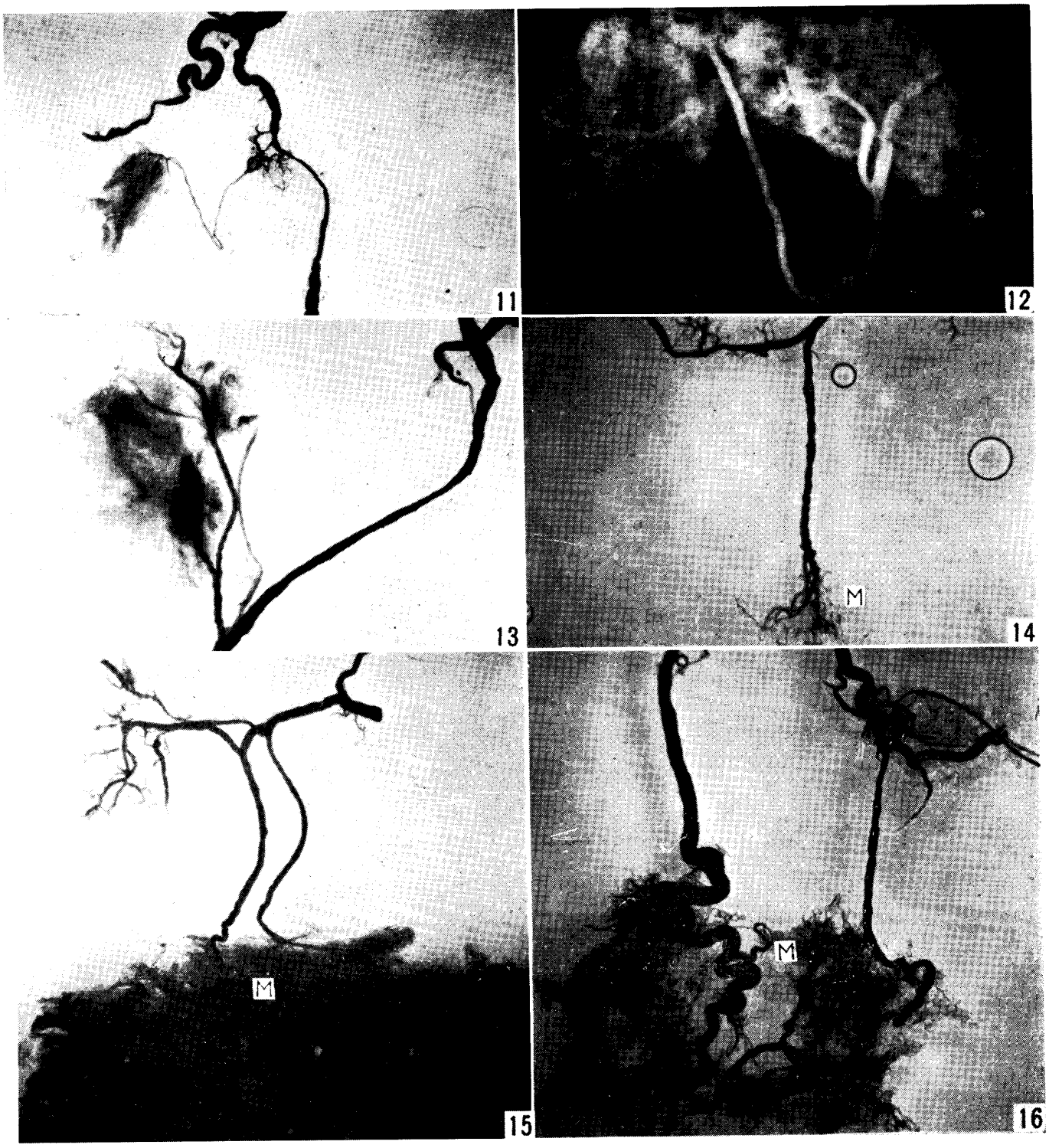
11
12
13
M
14
M
15
M
16

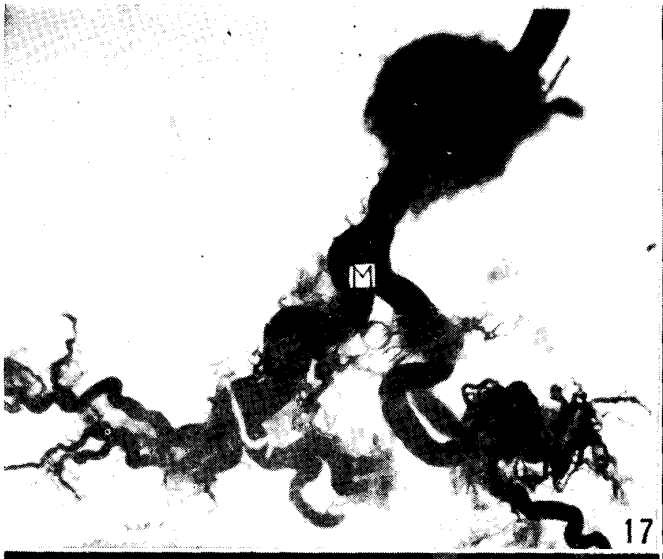

17

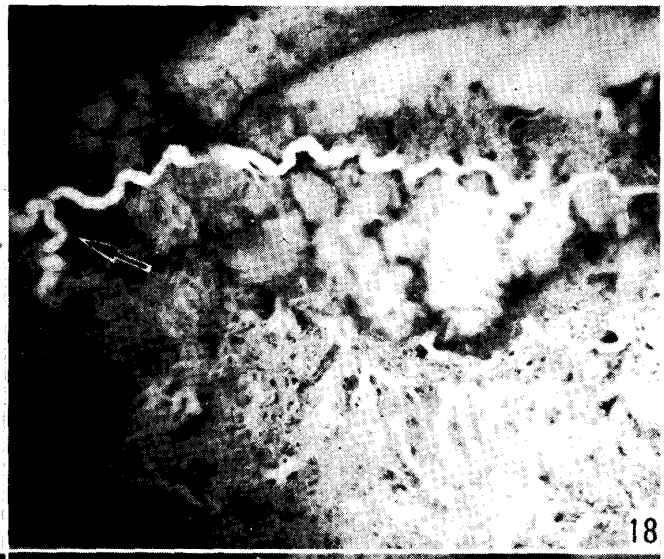

18

19

20

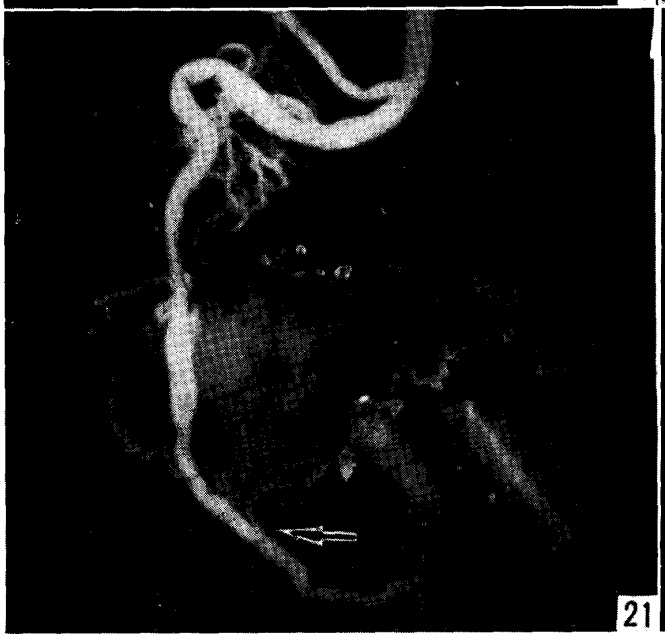

21

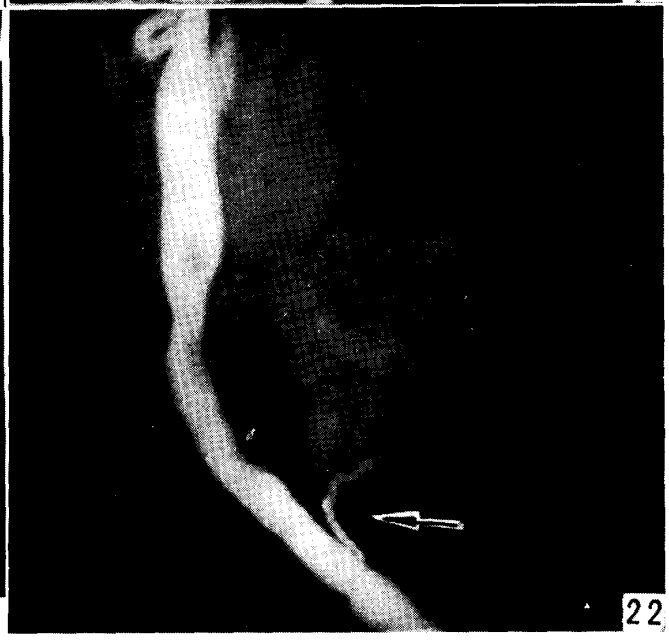

22

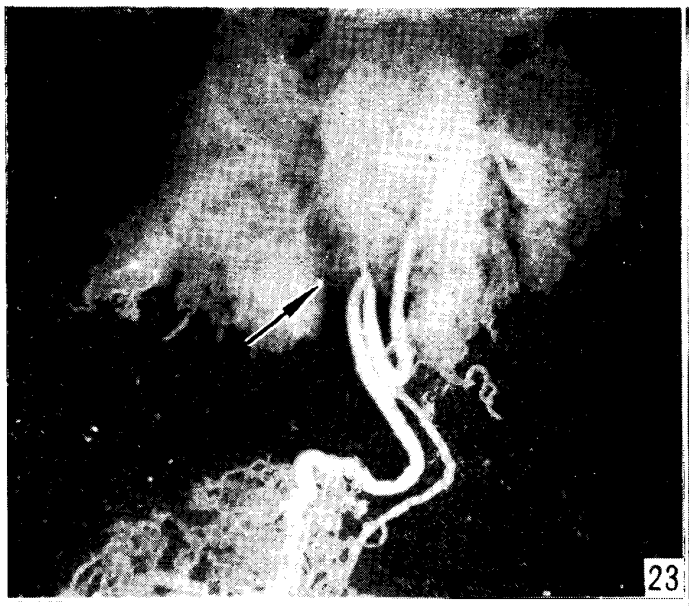
23


M
24


25

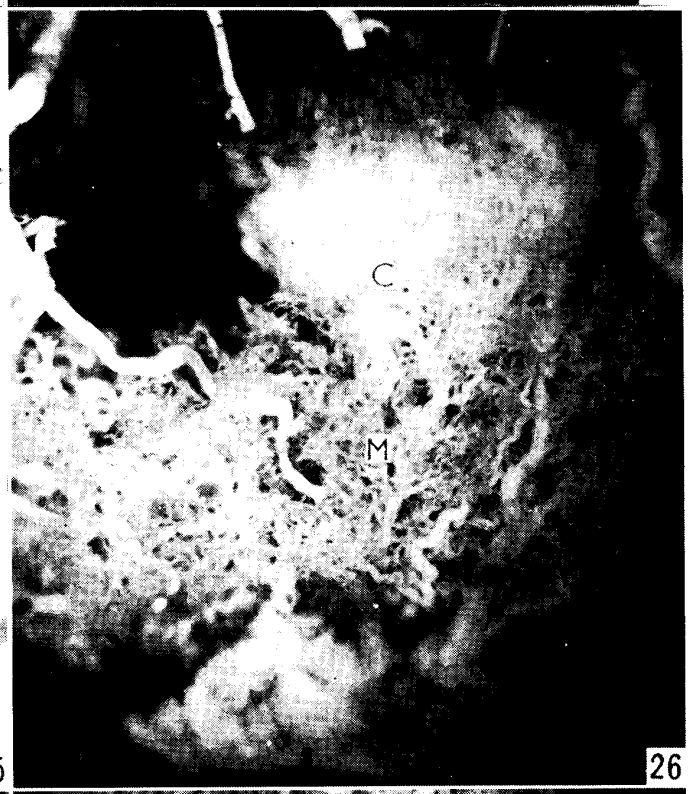
C
M
26

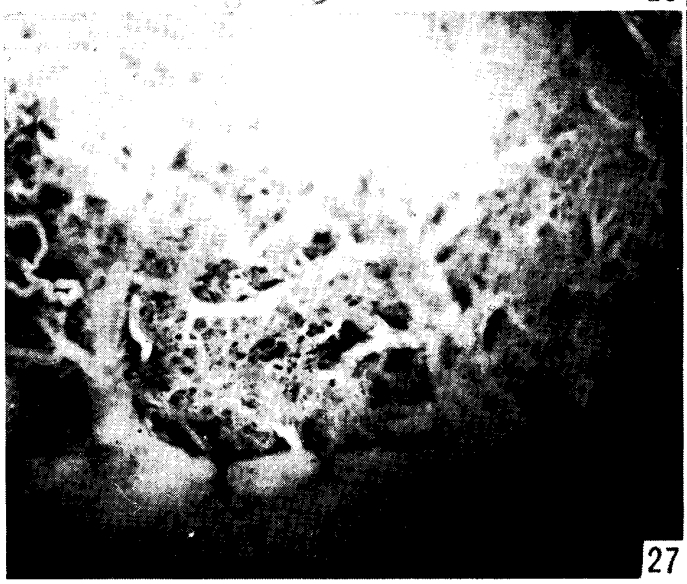
27


Vm
Vm
28


Am
zr
Vml
29