Revised version: Manuscript for Neuropathology. March 22, 2010

High expression of MeCP2 in JC virus-infected cells of progressive multifocal leukoencephalopathy brains

Saya Shirai,[1] Kenta Takahashi,[1] Shinji Kohsaka,[1] Tetsu Tsukamoto,[2] Hiroshi Isogai,[3] Shinichi Kudo,[4] Hirofumi Sawa,[5] Kazuo Nagashima,[6] Shinya Tanaka[1]

[1]Laboratory of Cancer Research, Department of Pathology, Hokkaido University Graduate School of Medicine, [2]Department of Pathology, Ebetsu City Hospital, [3] Animal Research Center, Sapporo Medical University, [4]Department of Microbiology, Hokkaido Institute of Public Health, [5]Department of Molecular Pathobiology, Research Center for Zoonosis Control, and Global COE Program, Hokkaido University, [6]Department of Pathology, Sapporo Higashi-Tokushukai Hospital

Correspondence: Kazuo Nagashima, Department of Pathology, Sapporo Higashi-Tokushukai Hospital, 3-1 E14, N33 Higashi-ku, Sapporo 065-0033, Japan
Tel: 011-722-1110, Fax: 011-722-0378, E-mail: path@higashi-tokushukai.or.jp

Abstract

Mutations of the methyl CpG binding protein 2 (MeCP2) gene are a major cause of Rett syndrome. To investigate whether the expression of this gene was related to JC virus (JCV) infection, we examined brains of four progressive multifocal leukoencephalopathy (PML) patients. JCV infection was confirmed by immunohistochemical labeling with antibodies against JCV VP1, Agnoprotein and large T antigen. MeCP2 expression was examined by immunohistochemistry using a specific polyclonal antibody against MeCP2. In normal brains and uninfected cortices of PML brains, MeCP2 expression was observed in the nuclei of neurons, but not observed in glial and endothelial cell nuclei. In PML brains, however, intense immunolabeling was observed in abnormally enlarged glial nuclei of JCV-infected cells. ~~The JCV infection was verified by immunolabeling against JCV VP1, Agnoprotein and large T antigen.~~ Double immunolabeling using antibodies against large T antigen (visualized as blue) and MeCP2 (visualised as red) revealed purple JCV infected nuclei, which confirmed that the JCV infected nuclei expressed MeCP2. ~~When we examined four MeCP2 related proteins, named as methyl CpG binding domains (MBD) 1, 2, 3, and 4, only MBD1 exhibited similar results to MeCP2.~~ We conclude that MeCP2 is highly expressed in the JCV infected nuclei of PML brain and these results may provide a new insight into the mechanism which regulates the MeCP2 expression in glial cells by the infection of JCV.

Key words: MeCP2, PML, JC virus infection, large T antigen, immunohistochemistry
Running title: MeCP2 in JC virus infected cells

INTRODUCTION

JC virus (JCV), a human polyomavirus and a member of the family of simian virus 40 (SV40), is the causative agent of the human demyelinating disease, progressive multifocal leukoencephalopathy (PML). [1, 2] Cell cycle-related proteins, p53, RB proteins and other proteins are known to bind to JCV large T antigen in a similar manner to SV40 large T antigen. [3,4,5] In addition, other viral proteins have been identified that bind to the promoter regions of JCV and which regulate viral transcription. [6,7] Recently, new transcription factors, viz., promyelocytic leukemia nuclear body proteins, and transcription regulating proteins have been shown to bind JCV. [8-11]

Methyl-CpG binding protein 2 (MeCP2) is an abundant nuclear protein of approximately 75 to 80 kDa and which preferentially binds to methylated CpG dinucleotides.[12] Extensive research suggests that MeCP2 plays a key role in the regulation of gene transcription, [13, 14] and mutations of the MeCP2 gene have been shown to cause Rett syndrome, a progressive neurodevelopmental disorder. [15] In addition, recent animal experiments have demonstrated that MeCP2 is not only related to gene repression, but also to gene transactivation. [16]

It is also of particular interest to investigate the expression profile of MeCP2 in various human disorders. In this study, we examined the expression of MeCP2 in JCV-infected cells of the central nervous system, since the regulatory regions of JCV also contain MeCP2 binding sites. ~~In the present study, we describe the results of immunohistochemical studies, which~~ We demonstrate that MeCP2 is strongly expressed in JCV-infected glial nuclei of brains with PML patients. ~~while in the normal brain, there is a weak expression limited to neuronal nuclei.~~

MATERIALS AND METHODS

Autopsy cases

Four brains, obtained at autopsy from PML patients, and two 'control' brains originating from patients with non-neurological disease were used for the present studies. The basic disease resulting in PML and the age and gender of the patients were as follows: hypogammaglobulinemia (27-year-old female), [17] two cases of AIDS (38-year-old male with hemophilia A, and 50-year-old male), and chronic renal failure with a longstanding hemodialysis (74-year-old female). [18]

Antibodies

Our original antibodies specific to JC virus capsid protein VP1 and Agnoprotein were used as previously reported.[17] Anti-large T antibody (Ab-2) was purchased from Calbiochem (Merck, Darmstadt, Germany). Antibody against MeCP2 was obtained by immunizing rabbits with a fusion protein containing the N-terminal 70 amino acid residues of MeCP2 and the glutathione S-transferase gene system. [14] ~~Rabbit polyclonal antibodies against methyl CpG binding domain (MBD), MBD1, MBD2, MBD3 and MBD4 were purchased from Santa Cruz Biotechnology Inc. (California, USA).~~

Immunohistochemical staining

Formalin-fixed paraffin-embedded sections of PML brains were deparaffinized with xylene and dehydrated with ethanol, treated with normal goat serum and 1% H_2O_2 methanol to stop endogenous peroxidase activity, and thereafter incubated with the primary antibody as described above. As the present studies were the first trial of immunohistochemistry, we have diluted antibodies 1,000 times, so that no-back ground staining was detected, and no cytoplasmic staining was observed. Selective neuronal staining was obtained in the cerebellar cortex and colonic Auerbach's plexus by taking into account that in rats MeCP2 mRNA expression is detected in these tissues and cells.[19] After incubation with the biotinylated second antibodies, immunoreactive products were either visualized by 3,3'-diaminobenzidine tetrahydrochloride (DAB) as brown, or by amino-ethyl carbazole (AEC) as red. For double immunolabeling, the sections were first incubated with an anti-large T monoclonal antibody which was visualized as blue by nitro-blue tetrazolium chloride/ 5-bromo-4-chloro-3'-indolylphosphatase (NBT/BCIP) via alkaline phosphatase reaction. Then, the sections were incubated with rabbit antibodies against MeCP2, and were visualized as red by AEC. Hence, cells containing both proteins are revealed as dark red in the tissue sections.

RESULTS

Immunohistochemically, MeCP2 was expressed in the nuclei of neuronal cells of the cerebral cortices of normal brains and in non-affected regions of PML brains (Fig. 1A). Both astrocytic and oligodendroglial nuclei remained unstained. In addition, endothelial cell nuclei were also unstained (Fig. 1A).

In the PML brain, there were enlarged basophilic nuclei in the demyelinated lesions, characteristic of JCV infection. These nuclei were immunohistochemically labeled with antibodies against JCV VP1, Agnoprotein and large T antigen (Fig. 1B). These findings confirm that enlarged basophilic nuclei in the demyelinated foci were actually infected with JCV.

MeCP2 immunolabeling of the PML brains disclosed that enlarged basophilic nuclei were also labeled with MeCP2 (Fig. 1C), while glial cell nuclei in the non-affected regions were unstained. The distribution of positive nuclei was quite similar to those of ~~JCV VP1~~ large-T antigen. Moreover, the intensity of immunolabeling was stronger than ~~the nuclei~~ nuclear staining of the normal brains and also resembled that of JCV VP1 and Agnoprotein (unpublished observation).

To confirm whether the JCV infected nuclei were simultaneously labeled with MeCP2, double immunolabeling was performed. The paraffin sections were first immunolabeled with JCV large-T, which is visualized as blue, then incubated with antibodies against MeCP2 which is visualized as red. Most of enlarged nuclei were dark red, resulting from both JCV large-T and MeCP2 immunolabeling, while only a few small nuclei stained red or blue. Hence, both JCV proteins and MeCP2 were localized in the same nuclei in PML brains.

~~With reference to the MeCP2 related proteins, there was intense MBD-1 immunolabeling in enlarged nuclei of the PML brains, similar to MeCP2, but MBD-4 was only weakly immunolabeled in the enlarged nuclei and MBD-2 and MBD-3 were not expressed. In addition, MBD-2 was positive in the neurons of the cerebral cortices.~~

DISCUSSION

MeCP2 is abundantly expressed in nuclei as a chromosomal protein and functions as a transcription repressor. Moreover, mutations in the MeCP2 gene ~~encoding MeCP2~~ are known to cause the neurodevelopmental disorder Rett syndrome.[15] However, recent studies using animal models have demonstrated that MeCP2 regulates the expression of a wide range of genes in the hypothalamus and may function as both an activator and a repressor of the target genes. [16]

MeCP2 mRNA has been examined by in situ hybridization in rats and is shown to be expressed in the ganglion cells and intestinal epithelium of the small intestine, Purkinje cells and other neurons in the brain, and in cells of the testis, [19] In humans, expression is also found in the colonic mucosa and colon cancers.[20] Neuronal expression found in rats is similar to the immunohistochemical findings revealed in the present study.

Although ~~many neuronal degenerative~~ several neurodegenerative and mental retarded disorders have been known to be associated with functional deficiency of MeCP2, [21] data suggesting an interaction of MeCP2 with viral proteins has been limited. Krithivas et al. examined the mechanism of latency-associated nuclear antigen (LANA) of Kaposi's sarcoma-associated herpesvirus (KSHV), and found that MeCP2 is one of the LANA binding proteins, and reported that MeCP2 ~~is important for~~ plays a role in the binding of LANA ~~to bind to~~ with chromosomes. [22] Griffiths and Whitehouse examined the monkey herpesvirus saimiri (HVS) homologous to KSHV, and found that the gene essential for ~~HSV~~ HVS episomal maintenance associates with MeCP2. [23] These reports suggest that MeCP2 is an important protein for viral episomal persistence and for subsequent persistent infection. As JCV is also asymptomatically persistent in human tissues, possibly in an episomal state in the latently infected cells, MeCP2 may be an essential factor ~~explaining~~ for its persistency. However, expression of MeCP2 in the cells with lytic infection has not been examined. Our present study demonstrates that high expression is observed in lytically infected cells with JCV, and hence we should also examine MeCP2 expression in the persistently infected cells. Alternatively, to better understand the present results, it is important to study MeCP2 expression in lytically infected cells with KSHV or HVS.

From the morphological point of view, the characteristic but unusual finding of PML is considerable enlargement of the infected oligodendroglial nuclei. To maintain nuclear enlargement it would be necessary to reinforce the strength of the nuclear membrane by related protein expression, for which MeCP2 may play an essential role by gene transactivation. In addition, MeCP2 associated gene expression may be closely related

to viral infection and subsequent demyalination. Further studies may be reqired to confirm this epigenetic phenomenon.

The expression of MeCP2 in JCV infected glial cells may be explained by following mechanisms. First, there may be an enhanced stability of the protein, probably by binding with some viral proteins, regulating ubiquitination. Second, there may be upregulation of the MeCP2 gene by association of the transcriptional regulatory region with a viral infection. To clarify the first hypothesis, interation of JCV with MeCP2 should be examined by immunoprecipitation assay. To investigate the secondary mechanism, the JCV protein which upregulate the MeCP2 gene should be determined by promoter analysis. ~~, as recent studies on MeCP2 expression have been mostly directed to downward regulation by MeCP2.~~ The present data may provide new insights into the epigenetic mechanisms of demyelination in PML brains.

REFERENCES

1. Frisque RJ, Bream GL, Cannella MT. Human polyomavirus JC virus genome. J Virol. 1984; 51: 458-69

2. Major EO, Amemiya K, Tornatore CS, Houff SA, Berger JR. Pathogenesis and molecular biology of progressive multifocal leukoencephalopathy, the JC virus-induced demyelinating disease of the human brain. Clin Microbiol Rev. 1992; 5: 49-73
.

3. Nagashima K, Tanaka S, Furuta Y et al. Viral neuro-oncogenesis in JC virus-medulloblastoma system. Proceedings of the XIth International Congress of Neuropathology, Neuropathology Supplement 4, pp310-315, 1990.

4. Ariza A, Mate JL, Fernández-Vasalo A, et al. p53 and proliferating cell nuclear antigen expression in JC virus-infected cells of progressive multifocal leukoencephalopathy. Hum Pathol. 1994; 25: 1341-5

5. Ariza A, Mate JL, Isamat M, Calatrava A, Fernández-Vasalo A, Navas-Palacios JJ. Overexpression of Ki-67 and cyclins A and B1 in JC virus-infected cells of progressive multifocal leukoencephalopathy. J Neuropathol Exp Neurol. 1998; 57: 226-30.

6. Tada H, Rappaport J, Lashgari M, Amini S, Wong-Staal F, Khalili K. Trans-activation of the JC virus late promoter by the tat protein of type 1 human immunodeficiency virus in glial cells. Proc Natl Acad Sci U S A. 1990; 87: 3479-83.

7. Okada Y, Sawa H, Tanaka S, et al. Transcriptional activation of JC virus by human T-lymphotropic virus type I Tax protein in human neuronal cell lines. J Biol Chem. 2000; 275: 17016-23

8. Sunden Y, Semba S, Suzuki T, et al. Identification of DDX1 as a JC virus transcriptional control region-binding protein. Microbiol Immunol. 2007; 51: 327-337.

9. Sunden Y, Semba S, Suzuki T, et al. DDX1 promotes proliferation of the JC virus through transactivation of its promoter. Microbiol Immunol. 2007; 51: 339-347.

10. Shishido-Hara Y, Higuchi K, Ohara S, Duyckaerts C, Hauw JJ, Uchihara T.

Promyelocytic leukemia nuclear bodies provide a scaffold for human polyomavirus JC replication and are disrupted after development of viral inclusions in progressive multifocal leukoencephalopathy. J Neuropathol Exp Neurol. 2008; 67: 299-308

11. Stettner MR, Nance JA, Wright CA, et al. SMAD proteins of oligodendroglial cells regulate transcription of JC viral early and late genes coordinately with the tat protein of human immunodeficiency virus type I. J Gen Virol. 2009; 90: 2005-2014.

12. Lewis JD, Meehan RR, Henzel WJ, et al. Purification, sequence, and cellular localization of a novel chromosomal protein that binds to methylated DNA. Cell. 1992; 69: 905-914.

13. Nan X, Ng HH, Johnson CA, et al. Transcriptional repression by the methyl-CpG-binding protein MeCP2 involves a histone deacetylase complex. Nature. 1998; 393: 386-389.

14. Kudo S. Methyl-CpG-binding protein MeCP2 represses Sp1-activated transcription of the human leukosialin gene when the promoter is methylated. Mol Cell Biol. 1998;18: 5492-5499.

15. Amir RE, Van den Veyver IB, Wan M, Tran CQ, Francke U, Zoghbi HY. Rett syndrome is caused by mutations in X-linked MECP2, encoding methyl-CpG-binding protein 2. Nat Genet. 1999; 23: 185-188.

16. Chahrour M, Jung SY, Shaw C, et al. MeCP2, a key contributor to neurological disease, activates and repress transcription. Science 2008; 320: 1224-1229.

17. Okada Y, Sawa H, Endo S, et al. Expression of JC virus agnoprotein in progressive multifocal leukoencephalopathy brain. Acta Neuropathol. 2002; 104: 130-136.

18. Arai Y, Tsutsui Y, Nagashima K,et al. Autopsy case of the cerebellar form of progressive multifocal leukoencephalopathy without immunodeficiency. Neuropathology. 2002; 22: 48-56.

19. Darwanto A, Kitazawa R, Mori K, Kondo T, Kitazawa S: MeCP2 expression and promoter methylation of cyclin D1 gene are associated with cyclin D1 expression in developing rat epididymal duct. Acta Histochem Cytochem 2008; 41: 135-142.

20. Darwanto A, Kitazawa R, Maeda S, Kitazawa S: MeCP2 and promoter methylation

cooperatively regulated E-cadherin gene expression in colorectal carcinoma. Cancer Sci 2003; 94: 442-447.

21. Urdinguio RG, Sanchez-Mut JV, Esteller M. Epigenetic mechanisms in neurological diseases: genes, syndromes, and therapies. Lancet Neurol. 2009; 8: 1056-1072.

22. Krithivas A, Fujimuro M, Weidner M, Young DB, Hayward SD. Protein interactions targeting the latency-associated nuclear antigen of Kaposi's sarcoma-associated herpesvirus to cell chromosomes. J Virol. 2002; 76: 11596-11604.

23. Griffiths R, Whitehouse A. Herpesvirus saimiri episomal persistence is maintained via interaction between open reading frame 73 and the cellular chromosome-associated protein MeCP2. J Virol. 2007; 81: 4021-4032.

Figure legends:

Figure 1. All figures are shown as original size x400.

A: Normal cerebral cortex of the PML brain. Immunolabeling for MeCP2 shows that nuclei of the pyramidal neurons are specifically labeled with MeCP2 antibody and shown as brown color by DAB. Note that nuclei of glial cells and endothelial cells (left lower part) remained unstained. DAB counter stained with methylene blue.

B: Demyelinated areas of the PML brain. Enlarged nuclei are intensely labeled with an antibody against large-T protein, which shows that the nuclei are infected with JCV. AEC (red) counter stained with methylene blue.

C: Demyelinated areas of the PML brain. Enlarged nuclei are strongly stained with anti-MeCP2 antibody, which shows that these nuclei contain large quantities of MeCP2. DAB (brown) counter stained with methylene blue.

D: Double staining with both large-T protein and MeCP2 of the demyelinated areas of the PML brain. Large T proteins are visualized as blue by NBT/BCIP, and MeCP2 as red by AEC. Most of enlarged nuclei are visualized as dark red, which shows that the nuclei contain large quantities of both JCV and MeCP2.

MeCP2 Fig for publish

Nagashima K

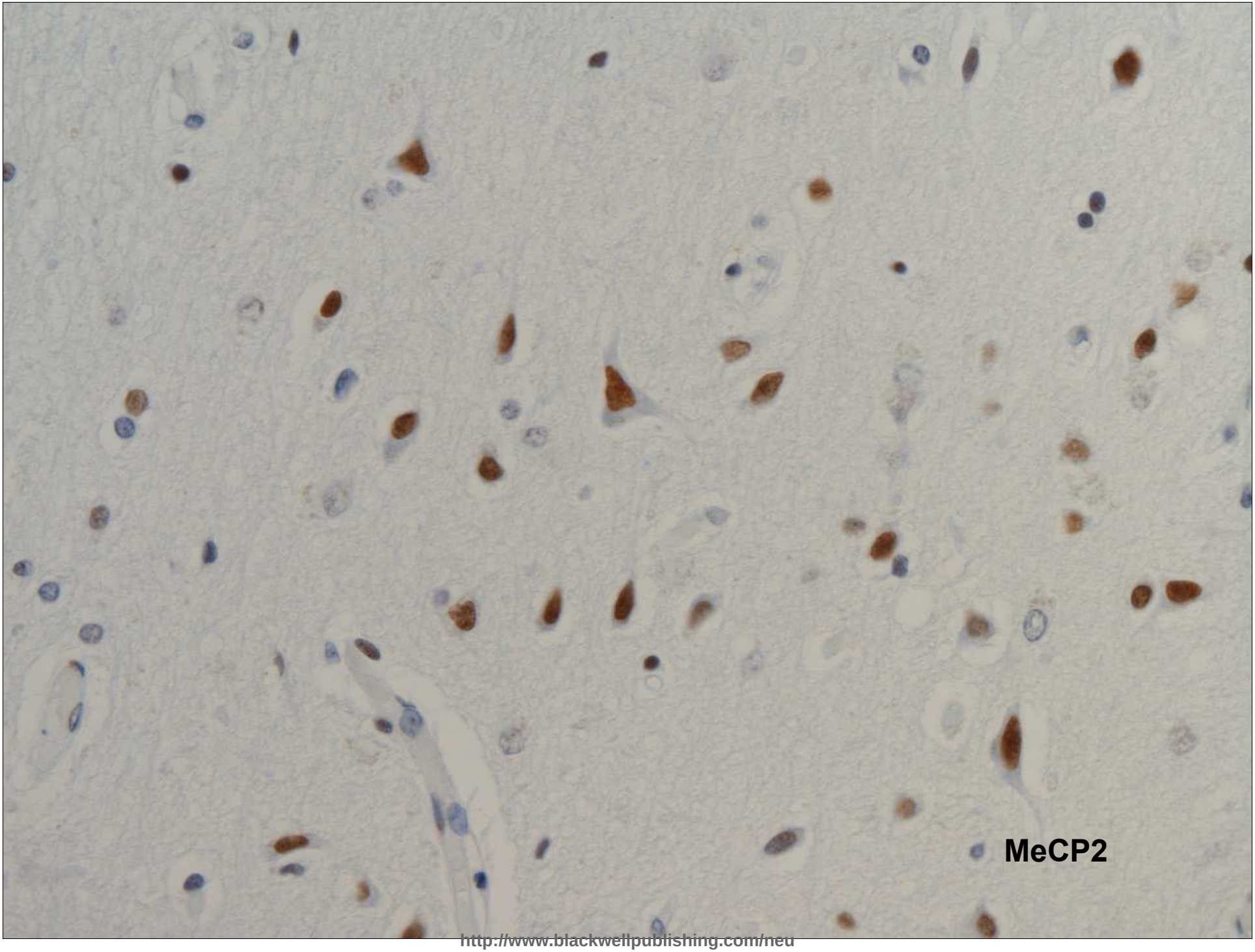
MeCP2

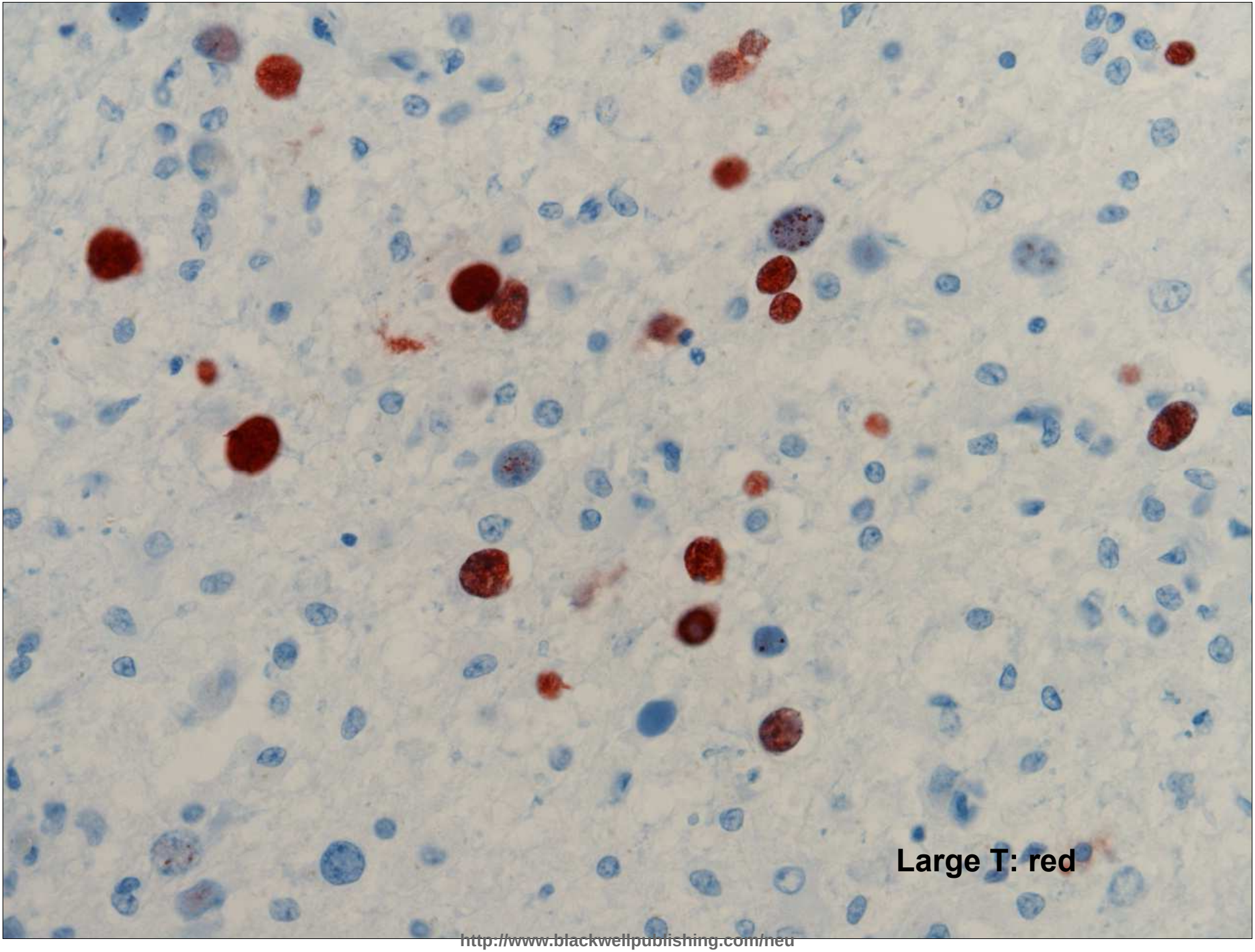
Large T: red

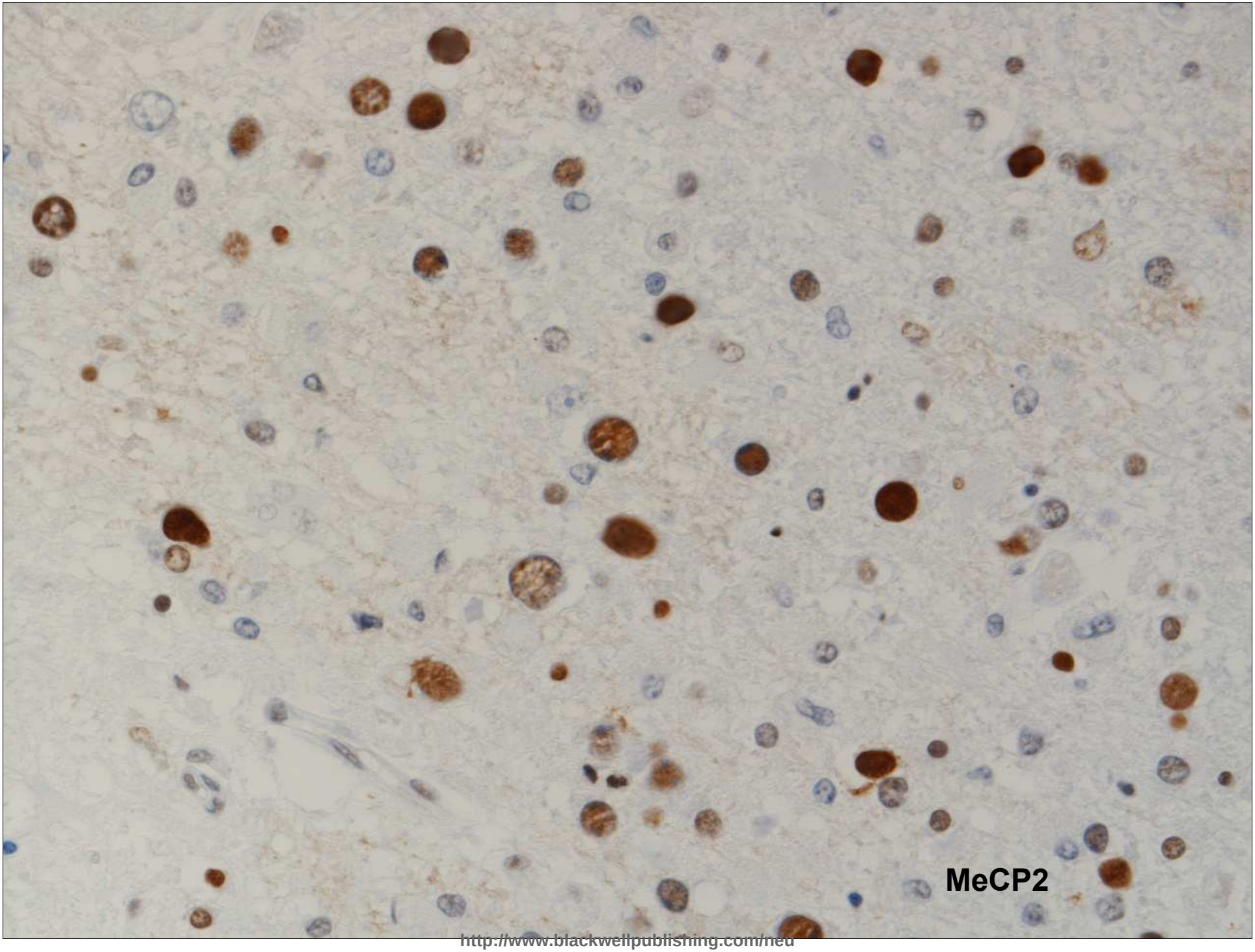
MeCP2

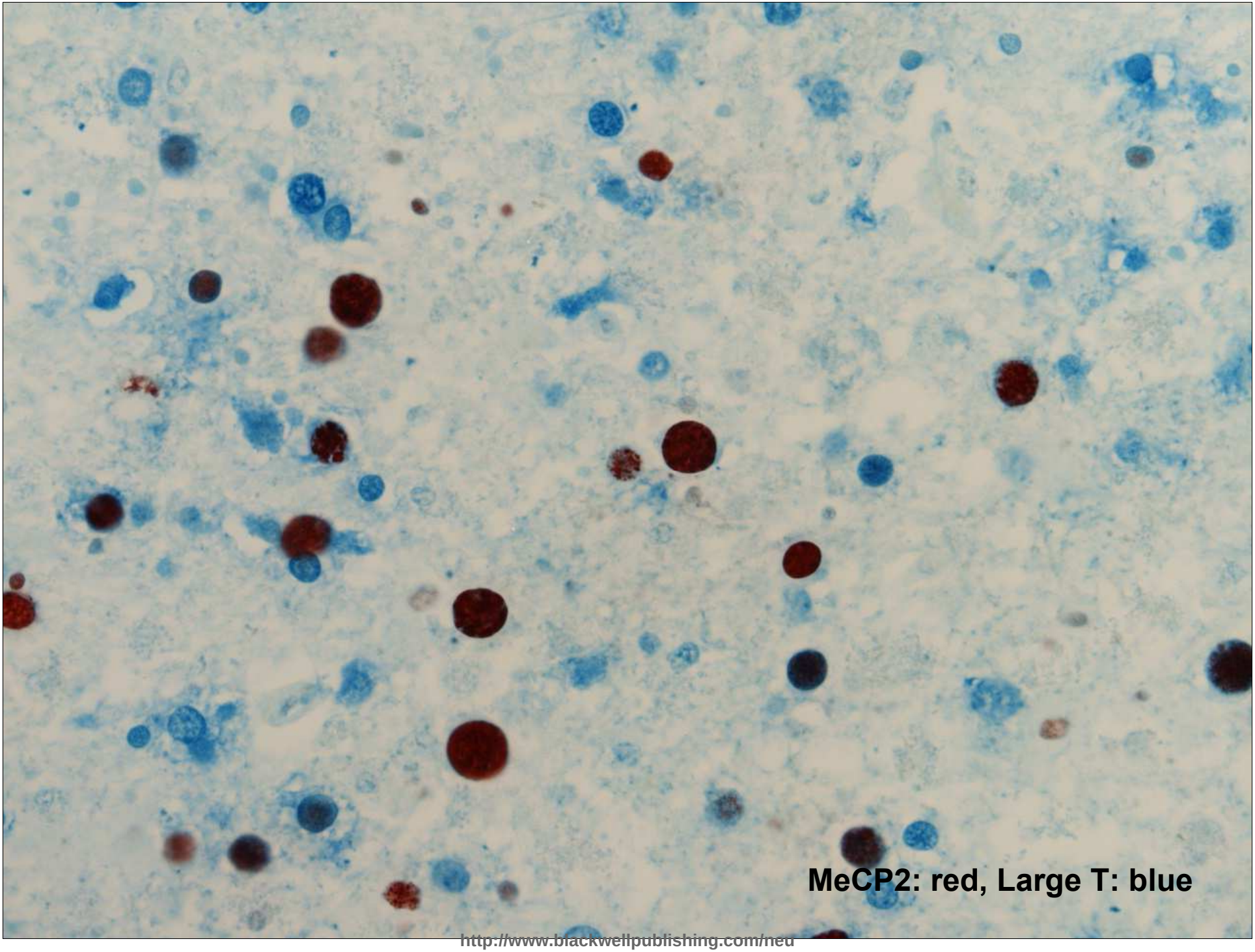
MeCP2: red, Large T: blue

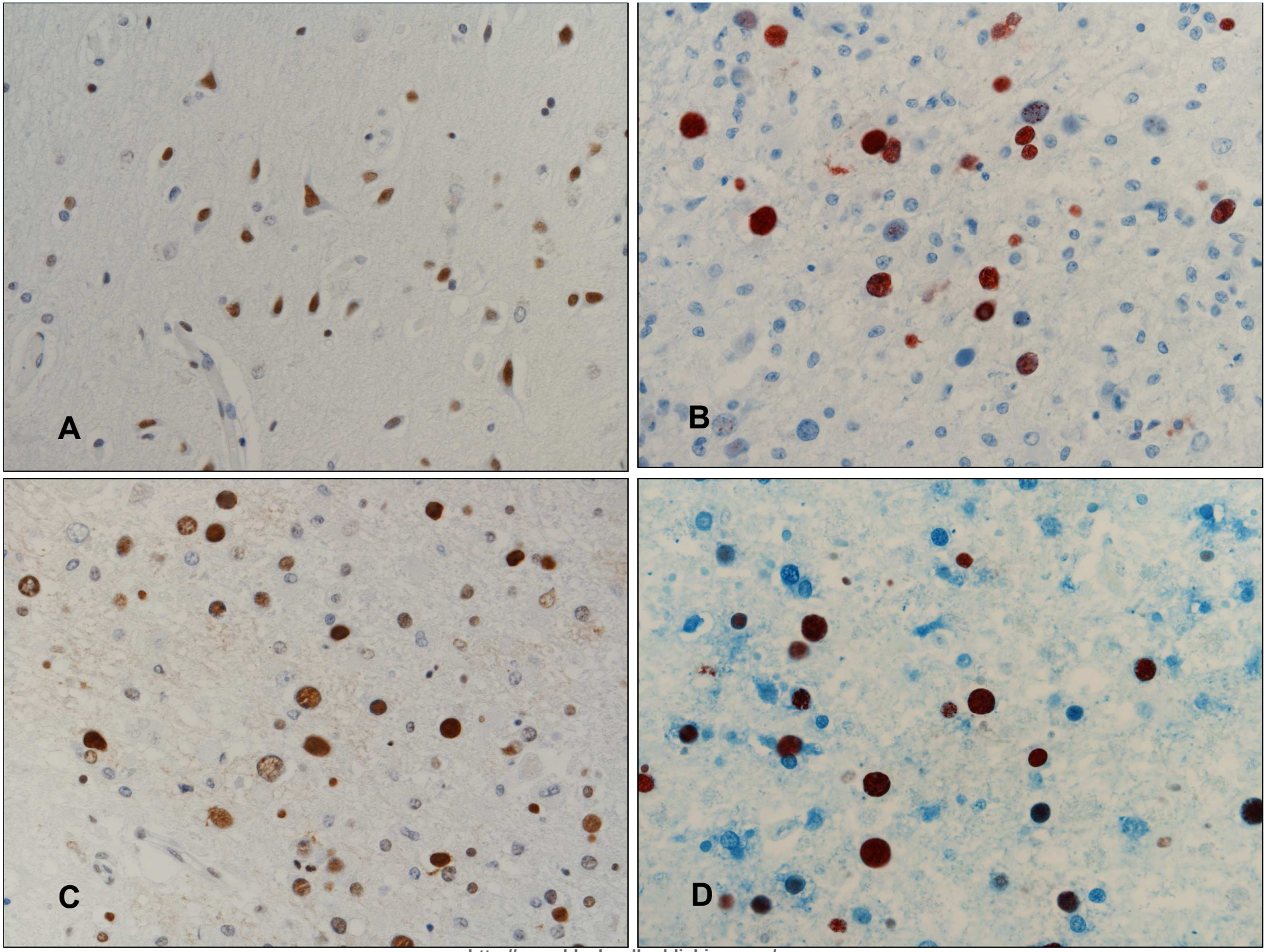
A
B
C
D