Title:

Salvage of broken screws using a hollow rubber tube (Nelaton catheter)

Abstract

Removing a broken screw tightly buried within the bone is an unenviable task. We report an inventive technique that makes use of rubber tubing placed over the broken screw. This technique is very effective, especially for the removal of screws in which the thread ridge has been worn down by the direct application of pliers to hold and rotate the screw. It is also time-saving and lessens debris contamination.

Introduction

Implant removal is controversial and not without complications[1]. Clinically, because of excessive torque during removal, surgeons frequently encounter screw stripping at the head and screw breakage at the neck, particularly when long screws are used or the implant has been in place for some time. In

these situations, we need a recovery strategy for removal of the retained broken screw tip. The conventional method involves excavating the bone around the screw with a burr, holding it with pliers, and turning repeatedly. This, however, does not always recover the situation and can indeed make it worse, because it wears the thread ridge from the screw, sometimes making the axial surface shine as if it were polished. If this happens, the more that the surgeon tries to twist with the pliers, the less the frictional force between the screw and pliers. We present an inventive method to remove the retained screw by increasing the frictional force between the screw and pliers. Instead of using rubber-grip pliers we have applied rubber to cover the screw.

Case report

A 37-year-old man sustained a symphyseal fracture of the mandible in a traffic accident. He underwent reduction and fixation of the fracture using a Lock plate with 4 screws (Compact Lock Mandible, Synthes, Davos, Switzerland); one of 11 mm and three of 13 mm. Eight months after fixation,

plate removal was performed under general anesthesia. One 11-mm screw and one 13-mm screw were removed with some torque resistance. However, the other two 13 mm screws fractured at the screw neck. We excavated the bone around the screw in the conventional manner to a depth of about 7 mm. We tried to hold the exposed screw with pliers and twist repeatedly, but this failed. The screw ridges became smooth and eventually we could not properly apply rotational torque. We therefore placed a 7 French Nelaton catheter (2.5 mm in outer diameter, Izumo Health, Nagano, Japan) onto it and held the screw with the overlying Nelaton catheter and turned it slowly with the pliers. The remaining screws were removed safely in this manner.

Discussion

Although controversy about plate removal remains[1], we have a policy of plate removal regardless of current plate-related complications. This is because we seek to regain the natural structural dynamic characteristics of the bone prior to injury or osteotomy. Should the patient have an accident in

the future, if a facial plate is not removed, a life-threatening fracture may occur because the metal plate may prevent a fracture of the bone, and the force may instead cause brain damage. Condylar fracture is a good example. It is actually a safety mechanism that prevents the condylar head from being driven into the middle cranial fossa.

At the genial site, the genioglossus and geniohyoid muscles attach to the mental spine, and appropriate forces caused by these stimulate bone healing and remodeling. However, if the supportive cortical bone is excessive or too dense, this will cause problems when removing screws.

Covering the screw with rubber and twisting with the naked jaws of pliers is quite opposite to the conventional method of using pliers with or without rubber on the top jaws for holding the naked screw. This new method has the further advantage of preventing debris contamination. The covering rubber exerts friction without causing direct metal-to-metal contact, and keeps the debris inside the rubber if it should be produced.

The Nelaton catheter, first developed as urethral catheter[2], is one type of

hollow rubber tube and a variety of sizes is available at a low price — this cost-effectiveness may also accelerate the application of this method.

Conflict of interest: None

References

1. Rallis G, Mourouzis C, Papakosta V, et al. Reasons for miniplate removal following maxillofacial trauma: a 4-year study. J Craniomaxillofac Surg. 2006;34:435-9.

2. Salam MA. Evolution of urological techniques. In: Salan MA, eds. Principles and practice of urology. 1st ed. Parkland, Fl: Brown Walker Press, 2003: 3-18.

Fig. 1

Photograph showing a broken screw. The head was broken off by twisting with high torque. To remove the remnant, the bone around the screw should

be excavated to lessen the resistance and to enable handling by pliers.

Fig. 2

A Nelaton catheter was applied to the broken screw. We held then held the screw with the overlying Nelaton catheter with the pliers and twisted slowly. The remaining screw tips were removed safely in this manner.

Fig. 3

Removed screws. The lower two screws were fractured. The axis surface of the broken screw was worn smooth by pliers. The screws were removed by present method.

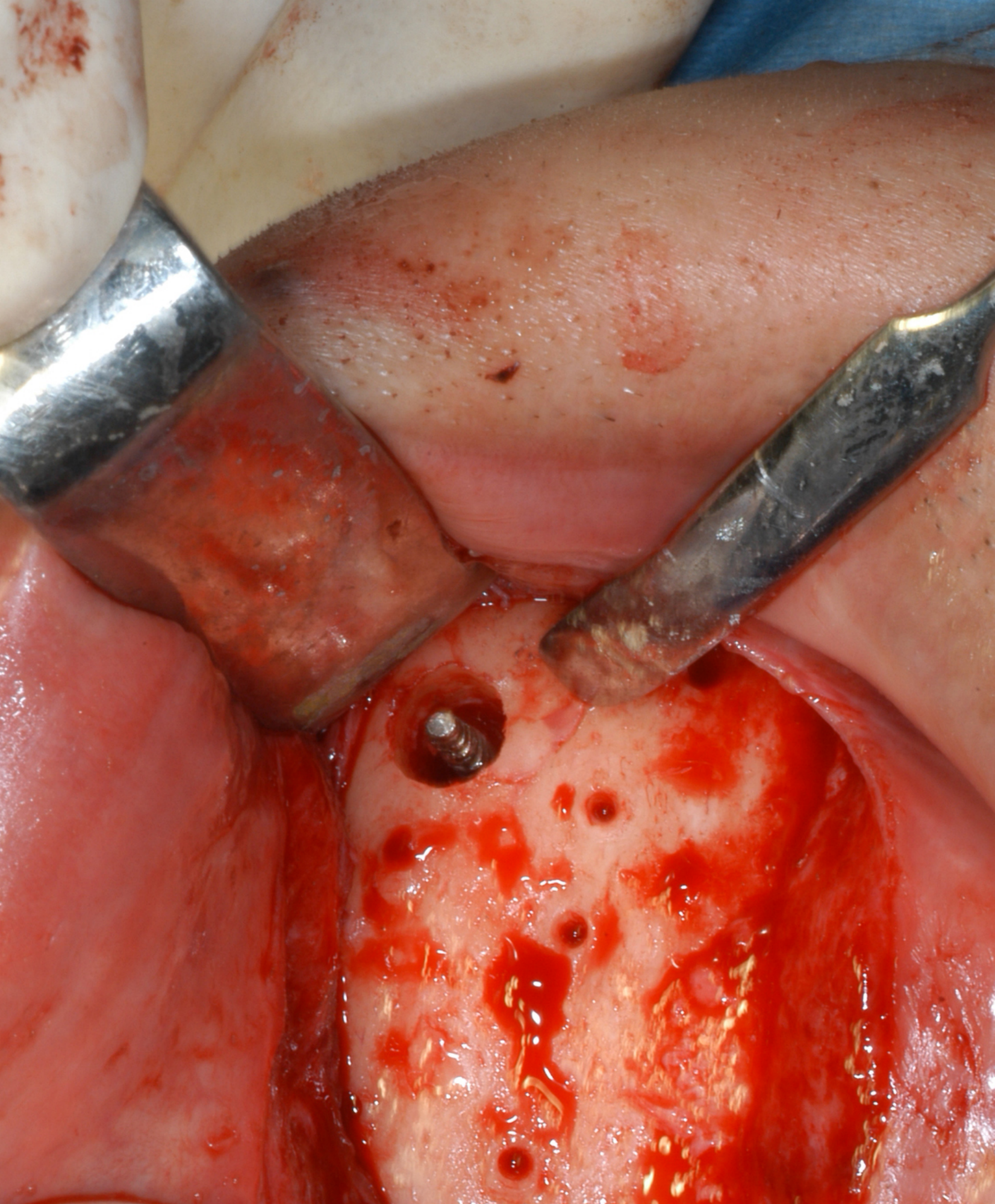

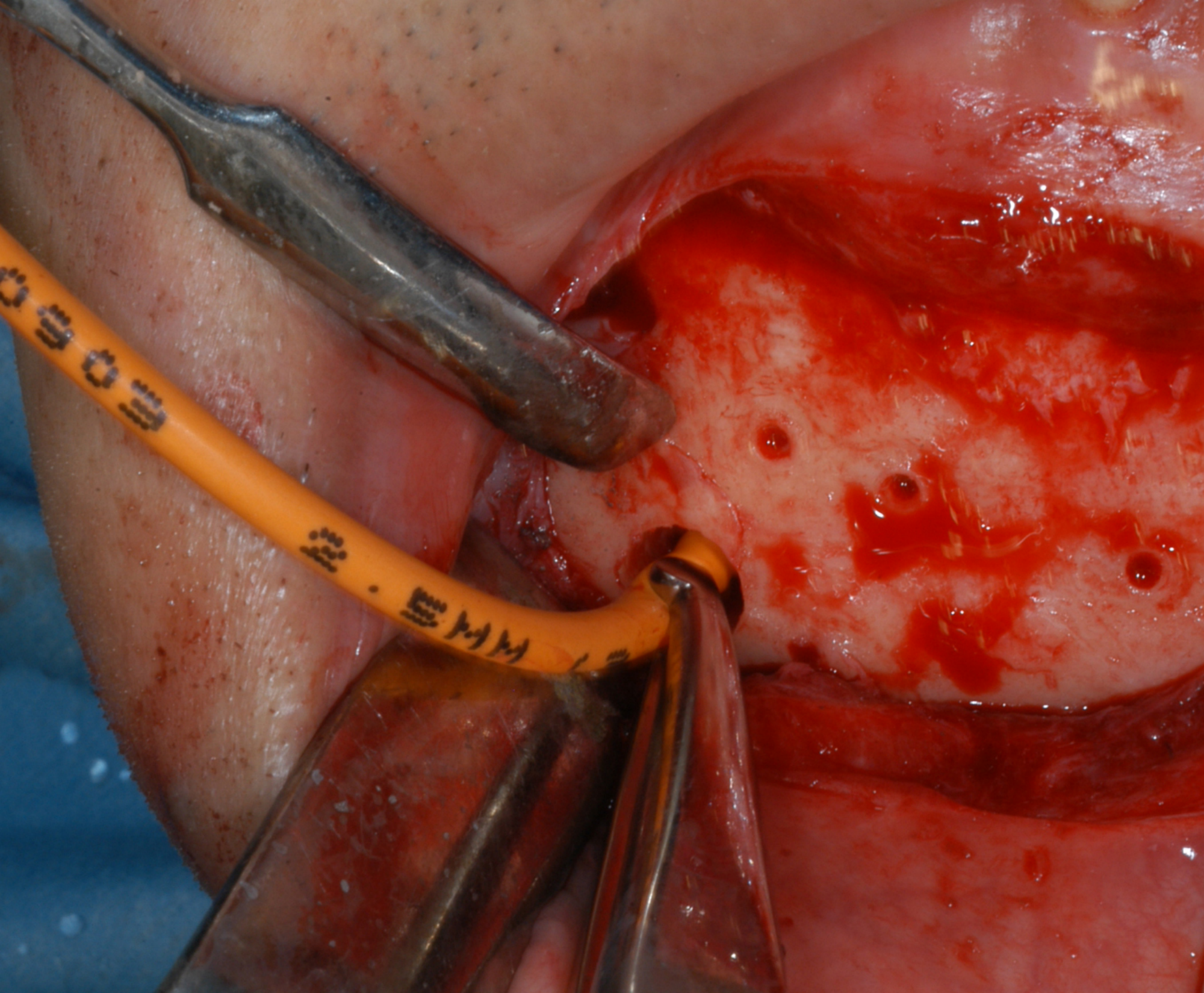


1
0