A Pilot Study of Anatomic Double-Bundle Anterior Cruciate Ligament Reconstruction with Ligament Remnant Tissue Preservation

Kazunori Yasuda, MD, PhD, Eiji Kondo, MD, PhD, Nobuto Kitamura, MD, PhD,

Yasuyuki Kawaguchi, MD, Shuken Kai, MD, Yoshie Tanabe, RPT, PhD

From the Department of Sports Medicine and Joint Surgery,

Hokkaido University Graduate School of Medicine, Sapporo, Japan

Address correspondence and reprint requests to: Kazunori Yasuda, M.D., Ph.D., Department of Sports Medicine and Joint Surgery, Hokkaido University Graduate School of Medicine, Kita-15 Nishi-7, Kita-ku, Sapporo, 060-8638, Japan.

Tel: +81-11-706-7211, Fax: +81-11-706-7822, E-mail: yasukaz@med.hokudai.ac.jp

The authors declare that they have no potential conflicts of interests.

The authors have received no financial support to write this review paper.

ABSTRACT

Purpose: The purpose of this pilot study is to clarify the preliminary results of an anatomic double-bundle ACL reconstruction procedure with ligament remnant tissues.

Methods: Using the trans-tibial technique, 2 doubled semitendinosus tendons were grafted into 4 tunnels created at the center of each bundle attachment, penetrating the ACL remnant tissue. Forty-four patients (27 men and 17 women) with an isolated ACL injury underwent ACL reconstruction using this procedure. The mean age of subjects was 29 years (range: 17–58). Postoperative clinical evaluations were performed at 16.6 months on average (range: 12 - 23). Radiological evaluations were also performed to evaluate the tunnel location in the femur and the tibia.

Results: The average operation time was 86 minutes (range: 72 – 96) in the cases with ACL reconstruction only. Postoperatively, the mean anterior laxity was 0.7 mm. The postoperative pivot-shift test was negative in 81.8 % of the patients, while there were no patients evaluated as ++. No patients showed any extension or flexion deficit. There were no patients evaluated as “Nearly abnormal” or “Abnormal” under the IKDC evaluation. The tunnel angles of the 4 tunnels were identical to those reported in the previous study.

Conclusions: The minimal 1-year clinical results of anatomic double-bundle ACL

reconstruction with ligament remnant tissue preservation were comparable to the previously reported results of the anatomic double-bundle reconstruction without remnant tissue preservation.

Level of Evidence: Level IV, Prospective case series

INTRODUCTION

The anterior criciate ligament (ACL) has a function as a proprioceptive sensory organ, initiating protective and stabilizing muscular reflexes.[1-4] Proprioception is critical to maintain joint stability under dynamic conditions. In addition, Barrett[5] reported that knee proprioception is closely correlated with both the functional outcome and the patient's satisfaction after ACL reconstruction. Therefore, restoration of better proprioception may be a potential goal of ACL reconstruction. How can we accelerate restoration of better proprioception in ACL reconstruction? It is known that the ACL-injured knee frequently has a ligament remnant tissue,[6] in which mechanoreceptors and free neural ends are found.[7-10] Therefore, theoretically, there is a strong possibility that preservation of the ACL remnant tissue may be able to restore proprioceptive functions of the graft after ACL reconstruction. Additionally, preservation of the ACL remnant tissue may enhance the revascularization and cellular proliferation of the graft after ACL reconstruction, because the ACL remnant tissue has good subsynovial and intrafascicular vascularity.[9] .

Thus, several investigators have developed single-bundle ACL reconstruction techniques with preservation of the ACL remnant tissue.[11-16] On the other hand, only a clinical report[17] has introduced a remnant-preserving technique for double-bundle ACL

reconstruction, in which 2 femoral tunnels and one tibial tunnel were made, although anatomic double bundle ACL reconstruction procedures have recently attracted notice because of biomechanical advantages in laboratory studies.[18-28] However, no previous studies have shown clinical evidence about utility of the ACL remnant tissue preservation in ACL reconstruction as of yet. To verify whether preservation of the ACL remnant tissue can really improve proprioceptive functions and enhance revascularization, we should conduct a randomized comparative trial with a sufficient number of patients to compare the 2 ACL reconstruction procedures with and without the remnant preservation in terms of proprioception and revascularization of the graft. Recently, we have developed a new remnant-preserving technique for anatomic double-bundle ACL reconstruction procedure using the semitendinosus tendon, in which 2 tibial and 2 femoral tunnels were created. To conduct a randomized trial with adequate numbers of patients in the near future to prove the utility of the remnant preservation in anatomic double-bundle ACL reconstruction, we have conducted this pilot clinical study to clarify whether it is acceptable for us to conduct the randomized study.

The purpose of this pilot study is to evaluate the minimum 1-year clinical results of anatomic double-bundle ACL reconstruction with ligament remnant tissue preservation in 44 patients. Our hypothesis is that the clinical results using ligament

preservation will be comparable to previously reported studies evaluating results of the conventional anatomic double-bundle reconstruction.

PATIENTS AND METHODS

1) Operative procedure

This procedure was performed for patients who had an ACL remnant tissue of Type I, II, or III, which was reported by Crain et al.[6] A surgical set-up and a fundamental double-bundle reconstruction procedure was previously reported.[25,29] We used an air tourniquet in all cases. After harvesting the semitendinosus tendon, we inserted a guide wire for the tibial PL tunnel using a Wire-navigator® device (Smith & Nephew Japan Inc., Tokyo, Japan), which was developed for the trans-tibial tunnel technique.[29] This device is composed of a Navi-tip and a Wire-sleeve. A feature of this device is that an axis of the Navi-tip and an axis of the Wire-sleeve always coincide with each other (Fig. 2). When we decide location and direction of the Navi-tip in an arthroscopic visual field, an extra-articular insertion point and direction of a guide wire are automatically decided. Thus, the guide wire can be inserted so that the intra-articular location and direction are same as those of the Navi-tip. The Navi-tip was placed at the center of the PL bundle attachment on the tibia from the lateral side of the ACL remnant

(Fig 3A and B). The posterior horn of the lateral meniscus was a useful landmark. The surgeon aimed the Femoral-indicator at the center of the PL bundle attachment on the femur at 90 degrees of knee flexion, keeping the Tibial-indicator at the center. The proximal end of the sleeve was fixed on the tibia, and a guide wire was drilled through the sleeve into the tibia (Fig 3C). Then, we placed the knee in the “figure-4” position, and confirmed whether the guide wire position was appropriate, using a C-arm fluoroscope (Fig 3D). A tibial PL tunnel was made with a cannulated drill.

To create a tibial AM tunnel, a shallow longitudinal incision was made in the ACL remnant along with the fiber orientation. The Navi-tip was introduced again into the joint cavity, and the Tibial-indicator was placed at the center of the AM bundle attachment on the tibia through the incision. Keeping the Tibial-indicator at this point, we then aimed the Femoral-indicator at the center of the femoral AM bundle attachment (Fig 4A). We could arthroscopically confirm the tip of the drilled guide wire in the remnant tissue by plobing (Fig 4B). Then, a tibial AM tunnel was made with a cannulated drill.

Before inserting a guide wire for femoral AM tunnel creation, we did not detach the adherent attachment of the remnant from the PCL or the femur, but we made a short deep incision parallel to the remnant fiber orientation on the femoral attachment

of the remnant tissue at the "1:30" or "10:30" orientation. A 5- or 6-mm offset guide (Transtibial Femoral ACL Drill Guide, Arthrex, Inc., Naples, FL, USA) was introduced into the joint cavity through the tibial AM tunnel and the longitudinal incision in the remnant (Fig 4C), and the tip of this guide was placed on the posterior part of the lateral chondyle at the "1:30" or "10:30" orientation through the above-described small slit. After we confirmed the tip location using a C-arm fluoroscope, a guide wire was inserted (Fig 4D). We gently drilled a tunnel and measured its length with a scaled probe (Fig 4E).

Then, the surgeon changed the arthroscopic portal from the lateral portal to the medial portal. The surgeon kept the femur horizontal, hanging the leg at 90 degrees of knee flexion. The surgeon manually held a guide wire and inserted it into the joint cavity through the tibial PL tunnel and the remnant tissue. Then, the surgeon aimed it at the center of the femoral attachment of the PL bundle midsubstance (Fig 3E), using the arthroscopy-assisted identification method.[29] When the center of the PL bundle attachment could not be identified because the remnant tissue obstructed an arthroscopic visual field, we determined an appropriate guide wire location using our newly developed radiological method[30] as shown in the Figure 5. After a guide wire was inserted, a femoral tunnel was gently drilled using a canulated drill, penetrating the

remnant tissue.

For graft preparation, the harvested semitendinosus tendon was cut in half. Each tendon was doubled over, and a commercially available polyester tape (Leeds-Keio Artificial Ligament, Neoligament Inc., U.K.) was mechanically connected at an un-looped end of the doubled tendons, using the previously reported technique[25,29] (Fig. 6).. Immediately before grafting, an Endobutton CL-BTB (Smith & Nephew Endoscopy, Andover, MA, USA) was attached at the looped end, based on our biomechanical study.[31] First, the PL graft was introduced through the tibial tunnel and the remnant tissue into the femoral tunnel, and fixed with an Endobutton (Fig 3F). Then, the AM graft was placed through the remnant tissue in the same manner (Fig 4F). An assistant surgeon simultaneously applied tension of 30 N to the 2 grafts at 90 degrees of knee flexion for 2 minutes. The surgeon simultaneously secured the 2 tape portions onto the tibia using two spiked staples (Meira Co. Nagoya, Japan) in a turn-buckle fashion (Video 1, available at www.arthroscopyjournal.org). The air tourniquet was deflated after the skin closure.

2) Indication and patient demographics

From January to December in 2009, we performed ACL reconstruction in a total of 80 patients with an isolated ACL injury in our hospital. Indication of our

anatomic double-bundle ACL reconstruction include the knees with functional insufficiency of both the AM and PL bundles, which was clearly diagnosed with the manual tests and/or MR imaging. In the decision-making process, we carefully discussed with the patient about the current symptom level, functional expectations, activity goals, and willingness to comply with the necessary restrictions to avoid significant reinjury events. Of the 80 patients, 44 patients (27 men and 17 women) had an ACL remnant tissue of Type I (30 knees), II (6 knees), or III (8 knees), according to Crain et al.[6] There were no patients with a tibial attachment tear or an isolated anteromedial or posterolateral bundle tear. This pilot study had been accepted by the institutional review board clearance in our hospital prior to commencement. The 44 patients were asked to participate in this pilot clinical study. The patients were informed that a C-arm fluoroscope would be used intraoperatively, and that 2 postoperative radiograms would be taken. Thus, based on the informed consent, all 44 patients underwent anatomic double-bundle ACL reconstruction with the below-described remnant tissue-preserving procedure. These surgical procedures were performed by 3 senior orthopaedic surgeons, who had experienced a number of conventional anatomic double-bundle ACL reconstruction cases in these past 10 years.

The average age of the patients was 29 (range: 17–58) years at the time of

surgery. The mean interval between injury and the time of operation was 4 (range 1-8) months. The height and body weight of the patients were 168 +/- 9 (the mean +/- S.D.) cm and 68 +/- 11 kg, respectively. The medial or lateral meniscus was injured in 27 knees. There were no medial and lateral meniscus injuries. Nine knees did not undergo any treatments at all because they had a small stable tear. Eight menisci were sutured, and the remaining 10 menisci were partially resected. No treatment was administered for softening or fissuring of the articular cartilage. After surgery, all the patients underwent postoperative management using the same rehabilitation protocol reported previously.[28]

3) Clinical Evaluations

All the patients were examined in our outpatient clinic by December 2010. The follow-up period ranged from 12 to 23 months (average, 16.6 months). The side-to-side anterior laxity was measured by an experienced orthopaedic surgeon, who was blinded to the procedure and not a coauthor of this study, using a KT-2000 arthrometer (MEDmetric, San Diego, CA, USA) at 30° of knee flexion under an anterior drawer force of 133 N. The orthopaedic doctor also performed the pivot-shift test. The pivot-shift results were evaluated according to a guideline reported in the previous studies.[17,25] The Lysholm knee score (maximum score, 100 points)[32] and the

International Knee Documentation Committee (IKDC) form[33] were used. Peak isokinetic torque of the quadriceps and the hamstrings was measured at 60° per second of angular velocity using Cybex II (Lumex, Ronkonkoma, NY, USA) in both knees before and after surgery. Muscle torque as measured postoperatively in the uninvolved knee was represented as a ratio (%) to the uninvolved value.

4) Radiological evaluations

To evaluate location of the tunnels created in our procedure, the tunnel angle reported by Kondo et al[34] was measured on 2 computed digital radiographs (Fujifilm Corporation, Tokyo, Japan) postoperatively taken in the anterior-posterior and lateral views (Fig 1). The tunnel angle was defined as the angle between the tunnel axis and the long axis of the tibia or the femur.[34] Additionally, at the time of follow-up examination, we asked the patients whether they would accept to undergo CT scans to evaluate the tunnel position (Fig. 7). We did not perform CT scans in the patients who preferred CT scans not to be taken.

RESULTS

1) Operation time and complications

We completed this remnant preserving procedure in all 44 patients. Namely,

there were no patients needing resection of the remnant tissue during surgery to change this procedure to the conventional remnant resecting procedure. The total operation time between skin incision and skin closure, including ACL reconstruction and additional meniscus surgeries, was 101 +/- 19 minutes (the average +/- standard deviation) with a range between 81 and 115 minutes. In the cases with only ACL reconstruction, the total operation time was 86 +/- 8 minutes with a range between 72 and 96 minutes. As for complications, an EndoButton for PL bundle fixation was intraoperatively found not to be on the femoral cortex but in the soft tissues in 3 knees. In these knees, the malposition was found intraoperatively by using a fluoroscope, and corrected to an appropriate position intra-operatively by making a 3-cm long incision made on the lateral thigh. We did not experience any other intra- and post-operative complications, such as iatrogenic cartilage injuries, tunnel mal-position, graft fixation failure, delayed wound healing, deep vein thrombosis, infection, Cyclops syndrome with extension loss in the knee motion, joint contracture, fracture.

2) Postoperative clinical and radiological evaluations

The Postoperative clinical results concerning the side-to-side anterior laxity, the pivot-shift test, loss of knee motion, the Lysholm knee score, the IKDC evaluation, the mean peak torque of the quadriceps and the hamstrings muscles were shown in Table 1.

The radiological results on 2 tunnel locations in the tibia and the femur were also shown in Table 1. Intra-observer variability for the tunnel measurement was satisfactory (mean intraclass correlation coefficient, 0.91; range, 0.86 to 0.95).

DISCUSSION

Although we should note that the clinical utility of the anatomic double bundle ACL reconstruction has not been established in comparison with single bundle reconstruction as of yet, we believe that it is of value to conduct a clinical study that clarifies the effect of the ACL remnant tissue preservation in anatomic double bundle reconstruction. We compared our clinical results (Table 1) with the previously reported results of anatomic double-bundle reconstruction using hamstring tendons (Table 2). In the literature, the averaged side-to-side anterior laxity values ranged from 1.1mm to 1.4 mm. In the present study, the averaged side-to-side laxity was 0.7 mm. The rate of negative pivot shift test, which is a subjective evaluation, ranged from 81% to 97% in the literature. In the present study, our evaluation was shown to be 81.8 %. The results in the present pilot study were comparable to those reported in the literature, although precise statistical analyses could not be performed. Furthermore, we compared the results of the present study (Table 1) with those of our conventional anatomic

double-bundle ACL reconstruction without remnant preserving. In our previous study,[25] the side-to-side anterior laxity was 1.2 +/- 1.9 mm. The postoperative pivot-shift test showed the negative result in 81%, 16 % were rated as +, and 3 % were evaluated as ++. In the IKDC evaluation, 64% were evaluated as “Normal”, 34% were evaluated as “Nearly normal”, and 2% were evaluated as “Nearly abnormal”. Again, our results in the present study were comparable to our previously reported results of the anatomic double-bundle reconstruction without remnant tissue preservation. These results were encouraging to conduct a prospective comparative clinical trial in the near future to verify whether preservation of the ACL remnant can improve proprioceptive functions and revascularization using a large number of patients.

A special feature of our technique is that the proximal attachment of the ACL remnant is not detached from the attachment. Namely, in the previously reported techniques, the proximal attachment has been completely detached to visualize the femoral condyle.[12-17] In the present study, we performed this tissue-preserving surgery for the knees with a Type-I, II, or III ACL remnant tissue reported by Crain et al.[6] Such knees existed in 55% of a total of 80 patients who underwent ACL reconstruction in our hospital in the same period. Crain et al reported that the knees with a Type-I, II, or III ACL remnant tissue existed in 58% of their 48 patients who underwent ACL

reconstruction. The rates are similar in both studies. However, it is unknown which type of remnant is an appropriate indication for this surgery. In future studies, a correct indication of this technique should be decided, based on the clinical results, when the utility of this procedure will be established.

It is most important in the case of anatomic double-bundle ACL reconstruction to create 4 tunnels at the center of each attachment of the AM or PL bundle midsubstance.[17,29,35] Commonly, it is technically difficult to create such tunnels in preserving the ACL remnant tissue, because the tissue hindered our arthroscopic observations to drill a guide wire. Therefore, we radiologically evaluated the tunnel position created in the present study in comparison with the previously reported tunnel position created with the anatomic double-bundle procedure without remnant preservation.[34] According to this study, the tibial PL tunnel angles averaged 40.7 degrees and 35.4 degrees in the anterior-posterior and lateral views, respectively, and tibial AM tunnel angles averaged 15.6 degrees and 41.4 degrees, respectively. In the femur, PL tunnel angles averaged 44.0 degrees and 52.0 degrees in the anterior-posterior and lateral views, respectively, and AM tunnel angles averaged 18.0 degrees and 49.8 degrees, respectively. Thus, each tunnel angle measured in the present study was quite similar to the tunnel angle created with the conventional anatomic double-bundle

reconstruction without remnant preservation. This fact showed that the technique presented in this study enabled us to create 4 tunnels at the center of each attachment of the AM or PL bundle midsubstance in spite of preserving the remnant ACL tissue as much as possible. This logical consideration was confirmed by CT observation in the patients who underwent CT examination (Fig. 7).

In the trans-tibial technique, we must create a tibial tunnel so that we will be able to insert a guide wire into the center of the femoral AM or PL bundle attachment through the tibial tunnel.[17,25,29,35] Namely, the axis of the created tibial tunnel must pass the center of the femoral AM or PL bundle attachment. If a surgeon fails to create such an appropriate tibial tunnel, the surgeon cannot aim a guide wire at the targeted point on the femur. However, once an appropriate tibial tunnel is created, the trans-tibial technique has the following advantages: Namely, it is easy to create the femoral tunnels, to pass the graft from the tibia to the femur, to flip an Endobutton, to shorten the operation time. In addition, this study suggested that the trans-tibial technique is a reasonable surgical strategy to easily place each tendon graft, penetrating the remnant ACL tissue, because the 2 tunnel axes and the remnant tissue axis approximately coincided with each other.

Our previous studies reported that the Wire-navigator® device was useful in

the conventional anatomic double-bundle ACL reconstruction using the trans-tibial tecnique.[17,25,29] However, it had been unknown whether this device was useful in the remnant-preserving technique. In the present study, first, we arthroscopically inserted a guide wire using the "Wire navigator" without radiographic navigation, and then, we confirmed the guide wire location using a C-arm fluoroscope to completely avoid tunnel malposition. In our experience, the guide wire location was constantly appropriate so that we did not need to re-insert a guide wire. Therefore, we confirmed that this device is useful in the remnant tissue-preserving procedure. This means that, for experienced surgeons, confirmation with a C-arm fluoroscopy may not be needed. However, it is most important to completely avoid tunnel malposition in ACL reconstruction. Therefore, we recommend less experienced surgeons to confirm a guide wire location using a C-arm fluoroscope. In our experience, it took only a few minutes for the confirmation using the above-described technique.

We have used the above-described composite tendon graft in ACL reconstruction.[17,25,29] We named this graft a "hybrid graft", but this graft is not an augmented graft.[36] Namely, only the doubled tendon portion was placed across the joint with tendon insertions of approximately 20 mm within the bone tunnels. Therefore, stress-shielding does not occur in the tendon portion. The reason why we used this

composite graft was due to the following advantages: Biomechanically, the maximum failure load of the femur-hybrid substitute-tibia complex is approximately 900 N, which is superior to the femur-bone-patella-bone-tibia complex fixed with interference screws, and this complex is the most resistant to graft tension relaxation.[37-39] The stiffness of the former complex is superior to the suture-screw post technique, although it is inferior to the interference screw fixation. In addition, clinically, the tape portion of the graft can be quickly fixed to the tibia with staples. This feature enables us to simultaneously fix the 2 grafts onto the tibia, monitoring initial graft tension. This is a technical benefit for double-bundle reconstruction.

Kim et al[28] reported the remnant-preserving double-bundle technique using the quadriceps tendon in which a 9-mm tibial tunnel was made. In our procedure, we commonly created two 6-mm tibial tunnels. In simple calculation, a cross-sectional area of one 9-mm tunnel is 254 mm^2, while a total area of the two 6-mm tunnels is 226 mm^2. Impairment of the ACL attachment due to creation of the 2 tunnels is comparable to that due to one tunnel creation, rather frequently less invasive than the one tunnel creation. In addition, the ACL attachment of the tibia is not round but oval. Therefore, we cannot create a 9-mm tunnel completely inside the tibial footprint of the ACL, because a short diameter of the footprint is frequently less than 9 mm. However, we can commonly drill

two 6-mm tunnels completely inside it. Therefore, we believe that it is beneficial to create 2 small tibial tunnels to preserve the remnant tissue around the grafts as much as possible. On the other hand, there is a possibility that the incision and the slit in the remnant may compromise proprioception and vascularity in the remnant, although it was needed to lessen damage to the core portion of the remnant tissue and to smoothly pass the graft through the remnant. Therefore, we should carefully evaluate the effect of the remnant incision on proprioceptive functions and early revascularization of the graft in the near future.

There are limitations in this pilot clinical study. This study was a case series without statistical comparisons. The number of the patients and the follow-up period were insufficient to establish the utility of the procedure. However, we believe that those were acceptable as a pilot study to clarify whether it is acceptable for us to conduct a randomized comparative trial for proving the possible clinical benefits of the remnant preservation in the near future. The potential benefits of this technique are hypothetical, and we should note that our remnant tissue preserving technique includes the following disadvantages. First, this technique demands a high level of surgical skills and sufficient experience. Our operation time showed a learning curve. The operation time taken by the less experienced surgeons may be much more. At the present time,

therefore, we cannot recommend average surgeons to perform this technique. Secondly, X-ray exposure by a fluoroscope is needed to intraoperatively confirm location of an inserted guide wire, although the maximal exposure time was a total of 3 minutes (commonly 1 to 2 minutes). In the future, if utility of the tissue-preserving surgery should be established, we may be able to develop a more useful guide wire navigator device, which does not need to make any radiological confirmation. Thirdly, the operation time of the remnant-preserving procedure is obviously longer than that of the conventional anatomic double-bundle procedure without remnant preservation. In our experience, the former time averaged 86 minutes, while the latter time averaged 78 minutes.[25] However, we believe that the difference of approximately 10 minutes may not be a problem for patients, and we will be able to shorten the operation time of the remnant-preserving procedure by developing some useful devices in the near future. A Cyclops lesion may be a possible problem in remnant preserving surgery,[8] although we had no patients with extension loss in our clinical results. We should conduct a second-look arthroscopic study to examine the possibility of a Cyclops lesion in the future. Beyond these limitations and disadvantages, however, we believe that the results of the present study are of value to conduct a randomized comparative trial with adequate numbers of patients in order to clarify whether preservation of the ACL

remnant tissue can improve proprioceptive functions and revascularization of the graft in double-bundle ACL reconstruction.

CONCLUSIONS

The minimal 1-year clinical results of anatomic double-bundle ACL reconstruction with ligament remnant tissue preservation were comparable to the previously reported results of the anatomic double-bundle reconstruction without remnant tissue preservation.

REFERENCES

1. Barrack RL, Skinner HB. The sensory function of knee ligaments. In: Daniel DM, Akeson WH, O'Connor JJ, eds. Knee ligaments. Structure, function, injury, and repair. New York: Raven, 1990;95-114.

2. Freeman MA, Wyke BD. Articular contributors to limb muscle reflexes. The effects of partial neurectomy of the knee joint on postural reflexes. Br J Surg 1966;53:61-69.

3. Hogervorst T, Brand RA. Mechanoreceptors in joint function: Current concepts review. J Bone Joint Surg Am 1998;80:1365-1378.

4. Hulstyn M, Fadall PD, Abate J, Walsh WR. Biomechanical evaluation of interference

screw fixation in a bovine bone–patellar tendon–bone autograft complex for anterior cruciate ligament reconstruction. Arthroscopy 1993;9:417-424.

5. Barrett DS. Proprioception and function after anterior cruciate reconstruction. J Bone Joint Surg Br 1991;73b:833-837.

6. Crain EH, Fithian DC, Paxton EW, Luetzow WF. Variation in anterior cruciate ligament scar pattern: Does the scar pattern affect anterior laxity in anterior cruciate ligament–deficient knees? Arthroscopy 2005;21:19-24.

7. Denti M, Monteleone M, Berardi A, Panni AS. Anterior cruciate ligament mechanoreceptors. Clin Orthop Relat Res 1994;308:29–32.

8. Georgoulis AD, Pappa L, Moebius U, et al. The presence of proprioceptive mechanoreceptors in the remnants of ruptured ACL as possible source of re-innervation of ACL autograft. Knee Surg Sports Traumatol Arthrosc 2001;9:364-368.

9. Dhillon et al. Immunohistological Evaluation of the proprioceptive potential of the residual stump of an injured Anterior Cruciate Ligament. Int Orthop 2010;34:737-741.

10. Ochi M, Iwasa J, Uchio Y, Adachi N, Sumen Y. The regeneration of sensory neurons in the reconstruction of the anterior cruciate ligament. J Bone Joint Surg Br 1999; 8:902–906.

11. Adachi N, Ochi M, Uchio Y, Sumen Y. Anterior cruciate ligament augmentation

under arthroscopy. A minimum 2-year follow-up in 40 patients. Arch Orthop Trauma Surg 2000;120:128–133.

12. Ochi M, Adachi N, Deie M, Kanaya A (2006) Anterior cruciate ligament augmentation procedure with a 1-incision technique: anteromedial bundle or posterolateral bundle reconstruction. Arthroscopy 22:463.e1-5

13. Lee BI, Min KD, Choi HS, Kim JB, Kim ST. Arthroscopic Anterior Cruciate Ligament Reconstruction With the Tibial-Remnant Preserving Technique Using a Hamstring Graft. Arthroscopy 2006;22:340.e1-340.e7.

14. Lee BI, Kwon SW, Kim JB, Choi HS, Min KD. Preserved Remnant in Arthroscopic Anterior Cruciate Ligament Reconstruction Using Quadrupled Hamstring Graft. Arthroscopy 2008;24:560-568.

15. Ahn JH, Lee YS, Ha HC. Anterior cruciate ligament reconstruction with preservation of remnant bundle using hamstring autograft: technical note. Arch Orthop Trauma Surg 2009;129:1011–1015.

16. Löcherbacha C, Zaynib R, Chambat P, Sonnery-Cottet B. Biologically enhanced ACL reconstruction. Orthopaedics & Traumatology: Surgery & Research 2010;96:810-815.

17. Kim SJ, Jo SB, Kim TW, Chang JH, Choi HS, Oh KS. A modified arthroscopic

anterior cruciate ligament double-bundle reconstruction technique with autogenous quadriceps tendon graft: remnant-preserving technique. Arch Orthop Trauma Surg 2009;129:403-407.

18. Yasuda K, Kondo E, Ichiyama H, Tanabe Y, Tohyama H. Clinical evaluation of anatomic double-bundle anterior cruciate ligament reconstruction procedure using hamstring tendon grafts: Comparisons among 3 different procedures. Arthroscopy 2006;22:240-251.

19. Aglietti P, Giron F, Cuomo P, Losco M, Mondanelli N. Single-and Double-incision Double-bundle ACL Reconstruction. Clin Orthop Relat Res 2007;454:108-113.

20. Yagi M, Kuroda R, Nagamune K, Yoshiya S, Kurosaka M. Double-bundle ACL reconstruction can improve rotational stability. Clin Orthop Relat Res 2007;454:100-107.

21. Jarvela T. Double-bundle versus single-bundle anterior cruciate ligament reconstruction: a prospective, randomize clinical study. Knee Surg Sports Traumatol Arthrosc 2007;15:500-507.

22. Muneta T, Koga H, Mochizuki T, et al. A prospective randomized study of 4-strand semitendinosus tendon anterior cruciate ligament reconstruction comparing single-bundle and double-bundle techniques. Arthroscopy 2007;23:618-628.

23. Jarvela T, Moisala AS, Sihvonen R, Jarvela S, Kannus P, Jarvinen M. Double-bundle anterior cruciate ligament reconstruction using hamstring autografts and bioabsorbable interference screw fixation: prospective, randomized clinical study with two-year results. Am J Sports Med 2008;36:290-297.

24. Siebold R, Dehler C, Ellert T. Prospective randomized comparison of double-bundle versus single-bundle anterior cruciate ligament reconstruction. Arthroscopy 2008;24:137-145.

25. Streich NA, Friedrich K, Gotterbarm T, Schmitt H. Reconstruction of the ACL with a semitendinosus tendon graft: a prospective randomized single blinded comparison of double-bundle versus single-bundle technique in male athletes. Knee Surg Sports Traumatol Arthrosc 2008;16:232-238.

26. Kondo E, Yasuda K, Azuma H, Tanabe Y, Yagi T. Prospective clinical comparisons of anatomic double-bundle versus single-bundle anterior cruciate ligament reconstruction procedures in 328 consecutive patients. Am J Sports Med 2008;36:1675-1687.

27. Meredick RB, Vance KJ, Appleby D, Lubowitz JH. Outcome of single-bundle versus double-bundle reconstruction of the anterior cruciate ligament: a meta-analysis. Am J Sports Med 2008;36:1414-1421.

28. Aglietti P, Giron F, Losco M, Cuomo P, Ciardullo A, Mondanelli N. Comparison Between Single- and Double-Bundle Anterior Cruciate Ligament Reconstruction: A Prospective, Randomized, Single-Blinded Clinical Trial. Am J Sports Med 2009;38:25-34.

29. Yasuda K, Kondo E, Ichiyama H, et al. Anatomical reconstruction of the anteromedial and posterolateral bundles of the anterior cruciate ligament using hamstring tendon grafts. Arthroscopy 2004;20:1015-1025.

30. Inoue M, Tokuyasu S, Kuwahara S, et al. Tunnel location in transparent 3-dimentional CT in anatomic double-bundle anterior cruciate ligament reconstructionwith the trans-tibial tunnel technique. Knee Surg Sports Traumatol Arthrosc 2010;18:1176-1183.

31. Miyatake S, Kondo E, Tohyama H, Kitamura N, Yasuda K. Biomechanical evaluation of a novel application of a fixation device for bone-tendon-bone graft (EndoButton CL BTB) to soft-tissue grafts in anatomic double-bundle anterior cruciate ligament reconstruction. Arthroscopy 2010;26:1226-1232.

32. Lysholm J, Gillquist J. Evaluation of knee ligament surgery results with special emphasis on use of a scoring scale. Am J Sports Med 1982;10:150-154.

33. Hefti F, Miiller W, Jakob RP, Stiiubli UH. Evaluation of knee ligament injuries with

the IKDC form. Knee Surg, Sports Traumatol, Arthroscopy 1993;1:226-234.

34. Kondo E, Yasuda K, Ichiyama H, Azuma C, Tohyama H. Radiologic evaluation of femoral and tibial tunnels created with the transtibial tunnel technique for anatomic double-bundle anterior cruciate ligament reconstruction. Arthroscopy 2007;23:869-876.

35. Yasuda K, Tanabe Y, Kondo E, Kitamura N, Tohyama H. Anatomic double-bundle anterior cruciate ligament reconstruction. Arthroscopy 2010;26:S21-34.

36. Yasuda K, Tsujino J, Ohkoshi Y, Tanabe Y, Kaneda K. Graft site morbidity with autogenous semitendinosus and gracilis tendons. Am J Sports Med 1995;23:706-714.

37. Miyata K, Yasuda K, Kondo E, Nakano H, Kimura S, Hara N. Biomechanical comparisons of anterior cruciate ligament reconstruction procedures with flexor tendon graft. J Orthop Sci 2000;5:585-592.

38. Yamanaka M, Yasuda K, Nakano H, Wada T, Tohyama H. The effect of cyclic displacement upon the biomechanical characteristics of anterior cruciate ligament reconstructions. Am J Sports Med 1999; 27:772-777.

39. Kitamura N, Yasuda K, Tohyama H, Yamanaka N, Tanabe Y. Primary stability of three posterior cruciate ligament reconstruction procedures: a biomechanical in vitro study. Arthroscopy 2005;21:970-978.

Table 1. The postoperative clinical results of our remnant-preserved double-bundle ACL reconstruction and radiological evaluations on location of 4 tunnels actually created in the femur and the tibia using our remnant-preserving technique.

Clinical measures		Results (n= 44)
Anterior laxity		0.7 +/- 1.8 mm
Pivot-shift test	(-)	36 patients (81.8%)
	(+)	8 patients (18.2%)
	(++)	0 patients (0 %)
Extension loss (> 5°)		0 patients (0 %)
Flexion Loss (> 15°)		0 patients (0 %)
Lysholm knee score		97.5 +/- 4.4 points
IKDC evaluation		A 73%, B 27%
Quadriceps torque		91.7 +/- 21.0 %
Hamstrings torque		89.7 +/- 18.1 %
Radiological evaluations		
Tibial Tunnel angle		
AM bundle (A-P view)		19.2 +/- 4.4 degrees
	(Lateral view)	40.5 +/- 4.0
PL bundle (A-P view)		38.9 +/- 3.1
	(Lateral view)	35.6 +/- 4.4
Femoral tunnel angle		
AM bundle (A-P view)		22.6 +/- 8.4 degrees
	(Lateral view)	52.6 +/- 8.1
PL bundle (A-P view)		49.6 +/- 9.2
	(Lateral view)	56.5 +/- 11.4

1) Data are shown as “average +/- standard deviation”
2) AM: Anteromedial, PL: Posterolateral, A-P: Anteroposterior

Table 2. Postoperative knee stability after ACL reconstruction using the hamstring tendon in previously published studies with the evidence level of I or II.

Authors	Patients	Average side-to-side anterior laxity (Negative / Total)	Pivot-shift test
Yasuda et al (2006)	72	1.1 mm	87.5 %
Aglietti et al (2007)	75	1.4	84.0
Muneta et al (2007)	68	1.4	85.3
Yagi et al (2007)	60	1.3	-
Jarvela (2007)	55	1.11)	96.7
Kondo et al (2008)	328	1.2	81.3
Jarvela et al (2008)	77	1.3	81.8
Siebold et al (2008)	70	1.0	97.1
Streich et al (2008)	49	1.1	95.8
Aglietti et al (2009)	70	1.2	85.0

1) The laxity values were calculated from the graph in the original paper.

LEGENDS OF FIGURES

Fig. 1: Anatomic double-bundle ACL reconstruction technique in which 2 tunnels were created in the femur and the tibia, respectively, preserving an ACL remnant tissue. The tunnel angle was measured as the angle subtended by the axis of each bone tunnel (white lines show PL tunnels, and black lines show AM tunnels) and the long axis of the femur or tibia (dot lines). White arrows show the outlet of the PL tunnel, and black arrows show the outlet of the AM tunnel.

Fig. 2: A Wire-navigator® device developed for the trans-tibial tunnel technique. In this device, the axis of the Navi-tip portion is the same as the axis of the Wire-sleeve so that we can insert a guide wire with the same location and direction as the Navi-tip portion.

Fig. 3: Remnant preserving technique to create tibial and femoral tunnels for the PL bundle reconstruction. **A:** A preoperative remnant tissue of the ACL. The torn AM bundle was adherent to the PCL. The PL bundle was elongated and thin. **B:** The Navi-tip of the Wire-navigator® device was placed at the center of the PL bundle attachment on the tibia from the lateral side of the ACL remnant. **C:** The tip of the guide wire inserted for PL tunnel creation can be seen behind the ACL remnant. **D:**

Confirmation of the guide wire position using a C-arm fluoroscope. **E**: A guide wire was aimed at the center of the femoral PL bundle attachment through the tibial tunnel in the "Figure-4" position. **F**: The doubled tendon was grafted, penetrating the remnant tissue.

Fig. 4: Remnant preserving technique to create tibial and femoral tunnels for the AM bundle reconstruction. **A**: The Navi-tip of the Wire-navigator® device was placed on the tibia through a longitudinal incision made in the AM bundle remnant tissue. **B**: The tip position of the guide wire drilled in the tibia was checked by retracting the AM bundle remnant. **C:** An offset guide was placed at the "10:30" position on the femur through the tibial AM tunnel and the remnant tissue. **D:** An offset guide position and a guide wire position were checked using a C-arm fluoroscope. **E:** The femoral tunnel length was measured with a scaled probe, retracting the remnant tissue. **F:** In the preserved ACL remnant tissue, the PL and AM grafts were placed anatomically (The tunnel positions were shown in Fig 6).

Fig. 5: In a fluoroscope image (lateral view) taken at 90 degrees of knee flexion, we can draw an imaginary circle on the posterior condyle shadow (note that this is not a cartilage margin) and an imaginary vertical diameter of this circle, which passes through

the contact point between the femoral condyle and the tibial plateau. On this line, we can determine a crossing point (p) to the Blumensaat' s line (B) and a crossing point (q) to the circle. The center of the attachment of the PL bundle midsubstance (PL) is located at the posterior point dividing the length between the above-described 2 points by a 45% versus 55% ratio (The PL-q length is 45% of the p-q length.).

Fig. 6: Graft fashioning. A commercially available polyester tape was mechanically connected in series with an un-looped end of the doubled tendon. An Endobutton CL-BTB was attached at the looped end.

Fig 7: Postoperative 3-demensional CT images show that 4 tunnels were created at anatomical positions. Note that the Resident's ridge was seen between the 2 white arrows. Black arrows indicate 2 femoral tunnel outlets.

Video 1: Arthoscopy-assisted surgical technique for anatomic double-bundle ACL reconstruction with ligament remnant tissue preservation

Video Still: Anatomic double-bundle ACL reconstruction was performed with ACL

remnant tissue preservation.

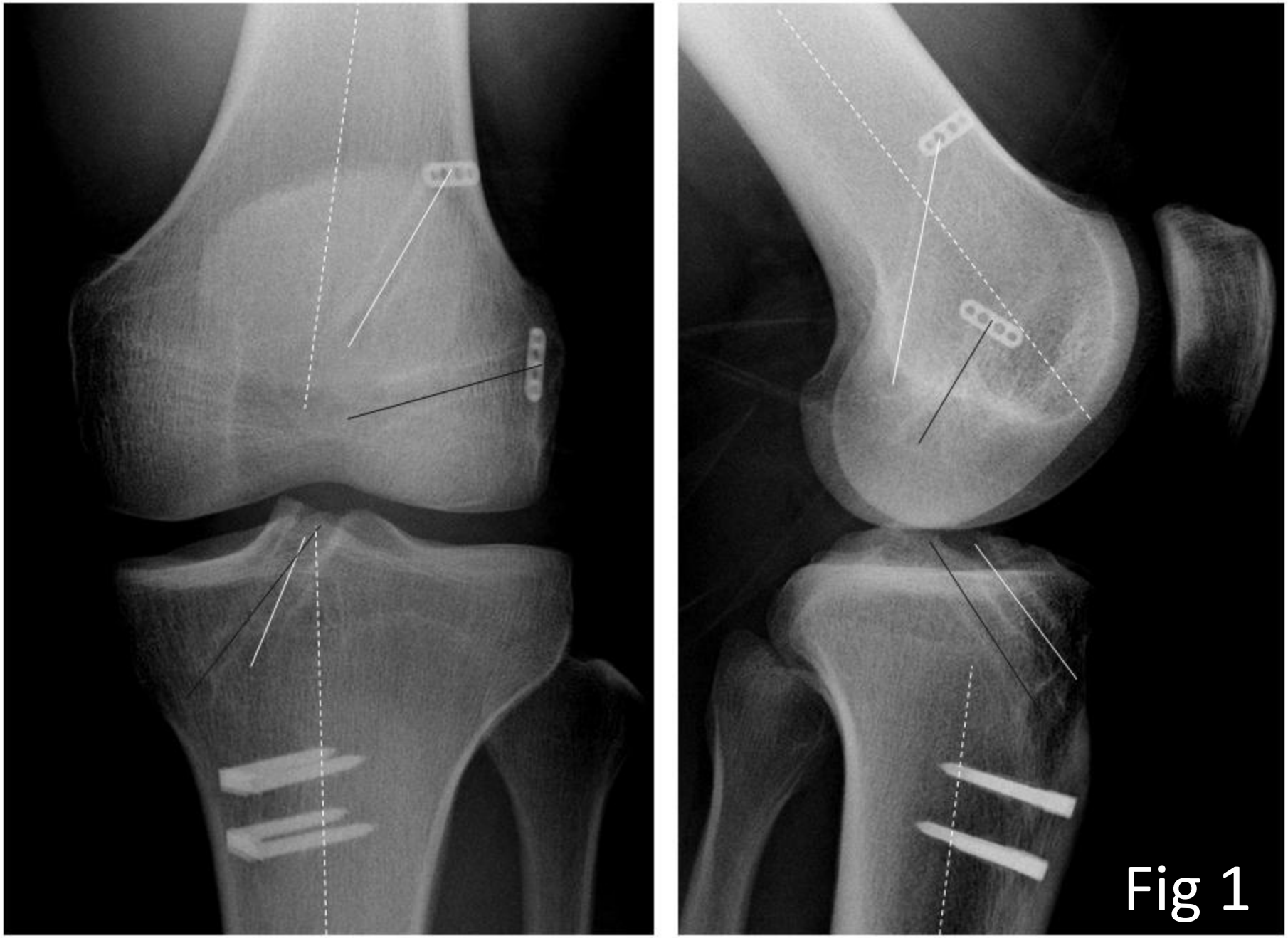
Fig 1

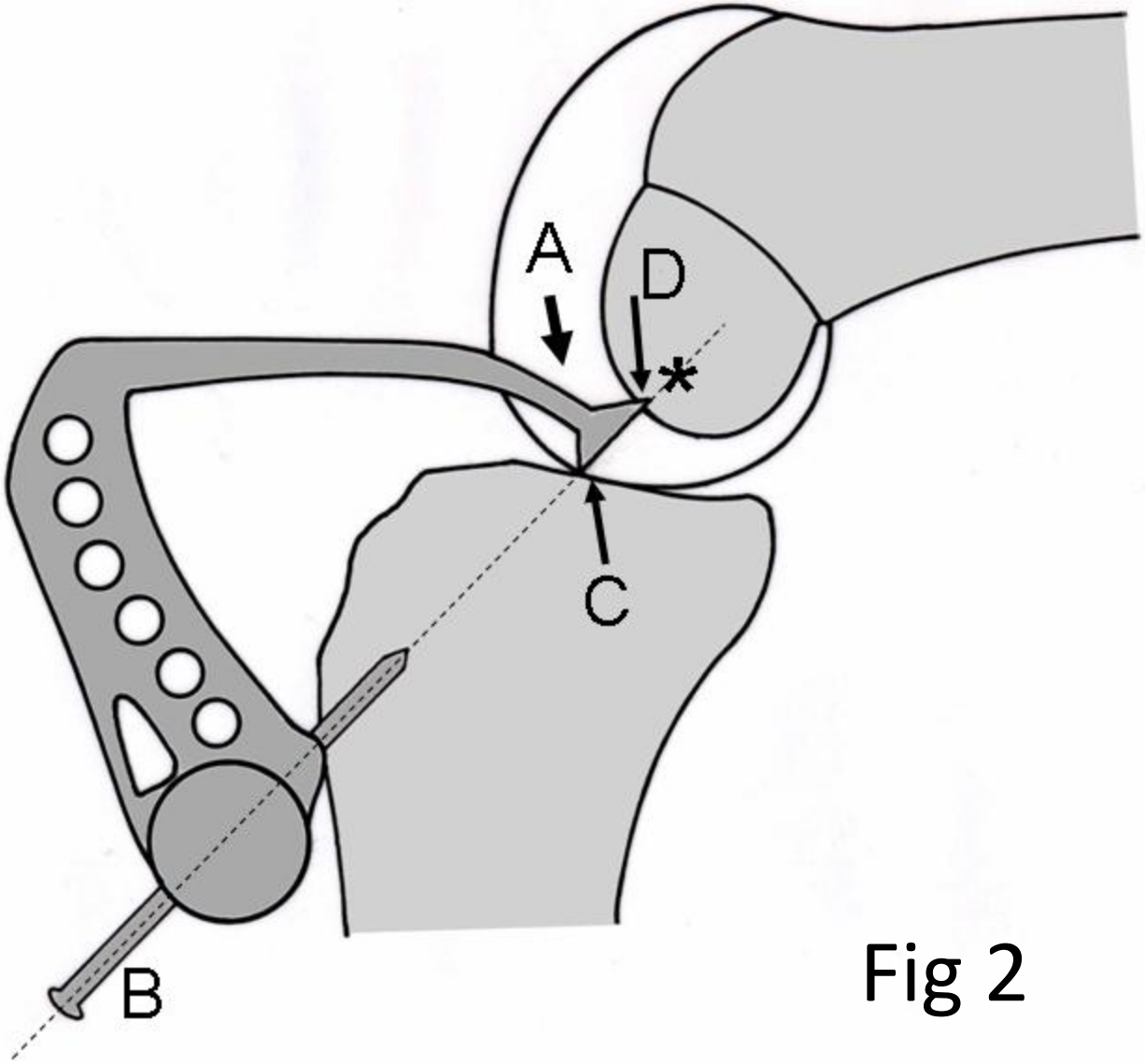

Fig 2

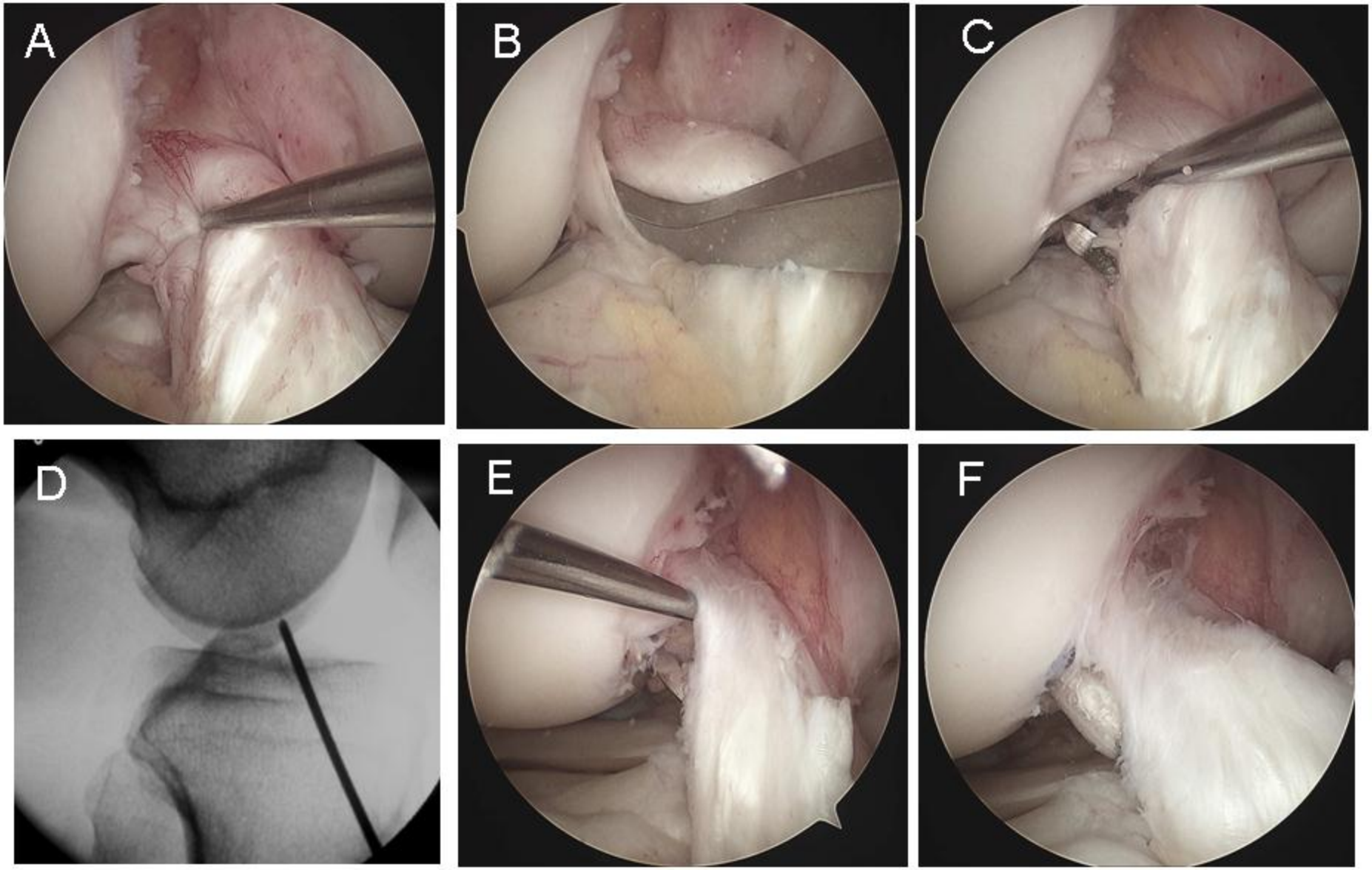

Fig 3

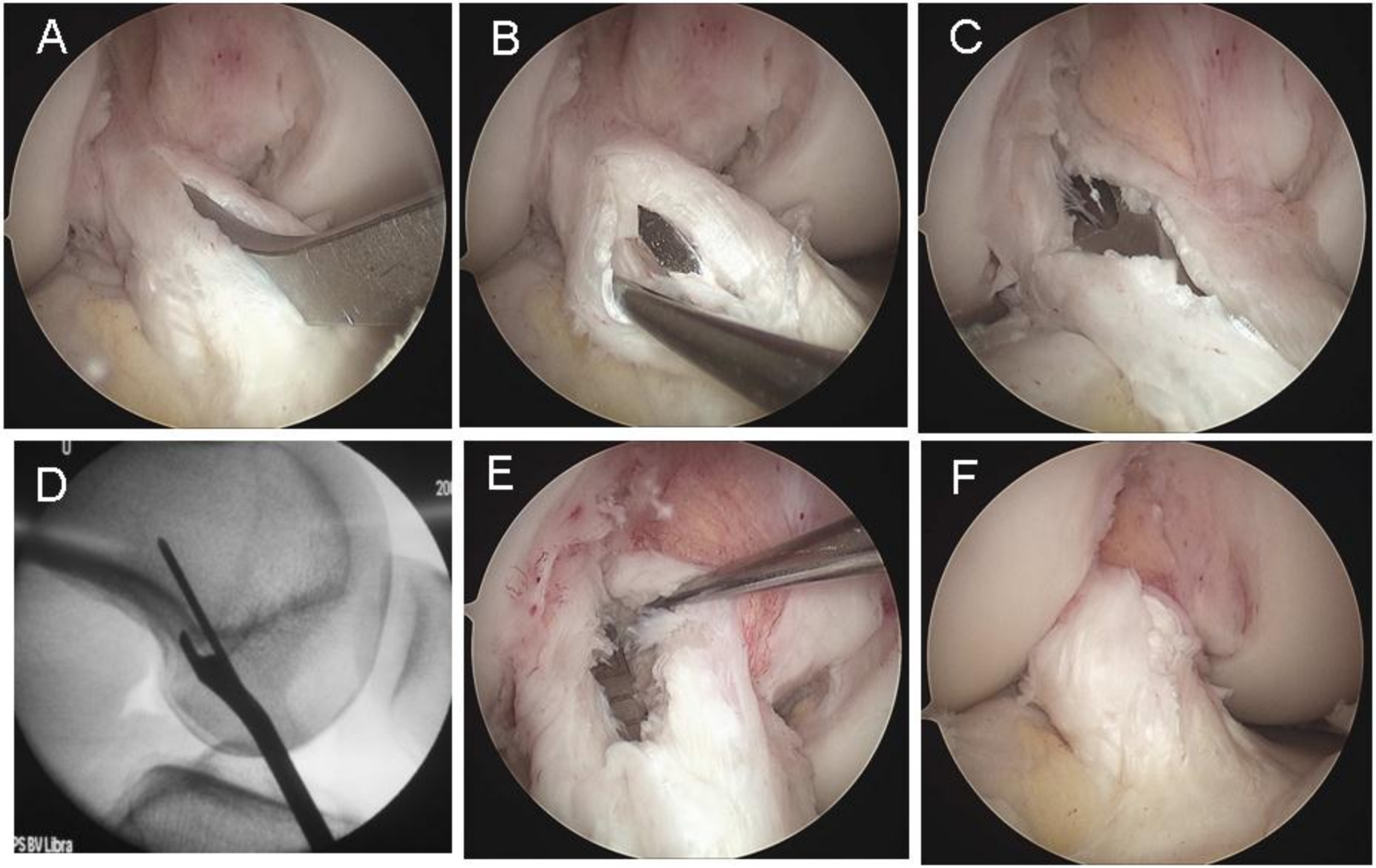

Fig 4

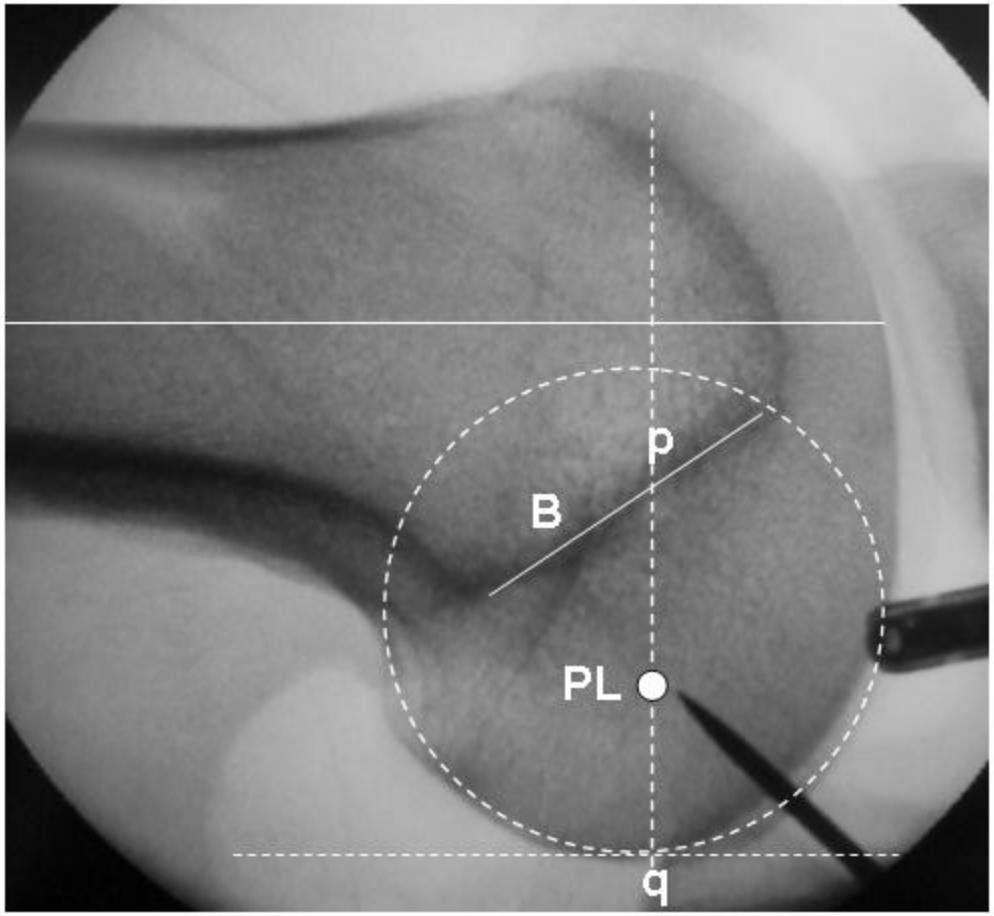

Fig 5

Fig 6

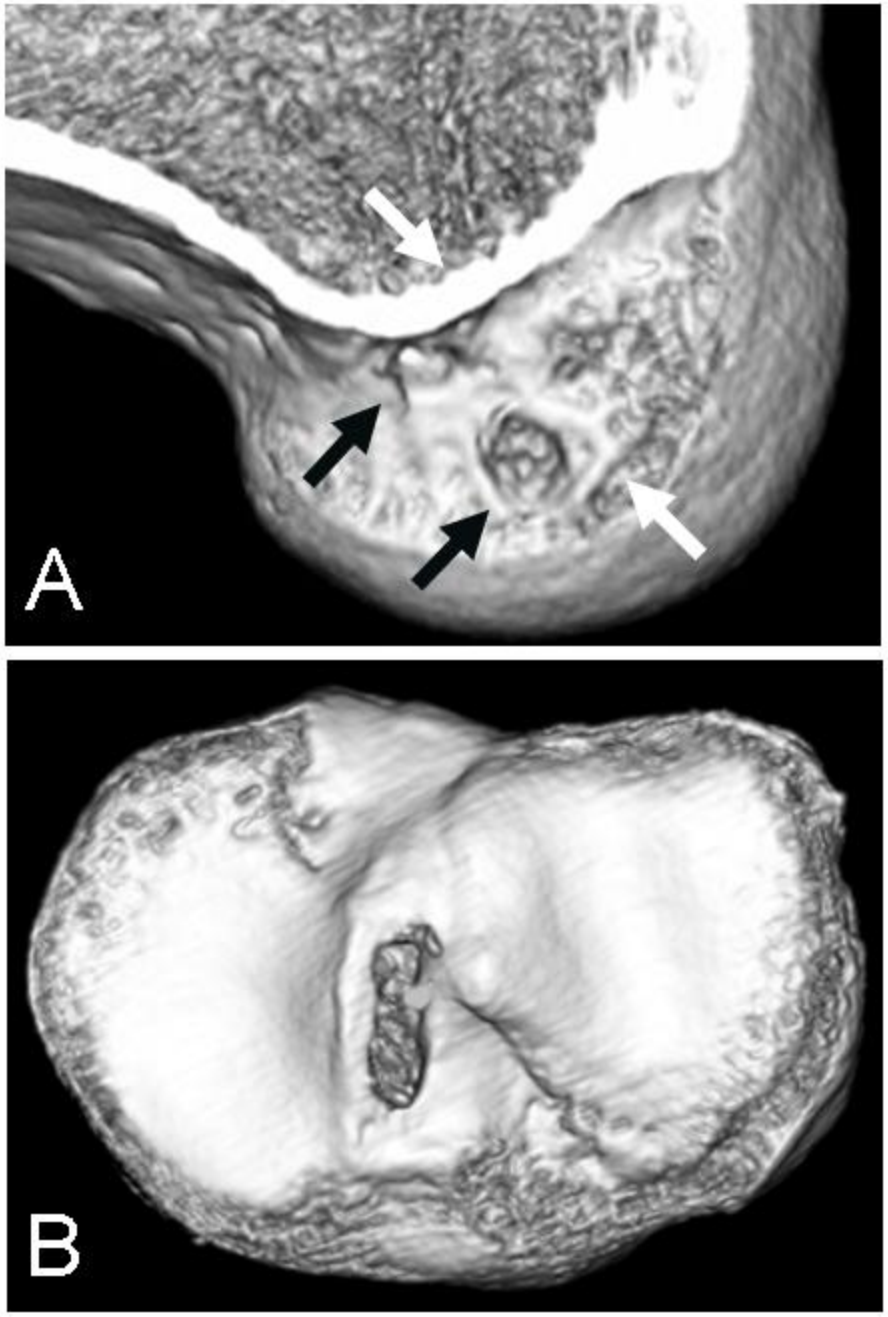

Fig 7