Recovery of Sensory Disturbance after Arthroscopic Decompression of Suprascapular Nerve

Naomi Oizumi, MD, PhD[1], Naoki Suenaga, MD, PhD [1],

Tadanao Funakoshi, MD, PhD [2], Hiroshi Yamaguchi, MD[3], Akio Minami, MD, PhD [2]

[1]The Upper Extremity Center of Joint Replacement and Endoscopic Surgery, Hokushin Orthopaedic Hospital, [2] Department of Orthopaedic Surgery, Hokkaido University Graduate School of Medicine, [3]Department of Orthopaedic Surgery, University of the Ryukyu Faculty of Medicine

Corresponding author: Naomi Oizumi, The Upper Extremity Center of Joint Replacement and Endoscopic Surgery, Hokushin Orthopaedic Hospital, 1-18 Kikusuimotomachi 3-jou 3-chome, Shiroishi-ku, Sapporo, 003-0823

Tel: +81-11-871-3660, Fax: +81-11-871-4237, E-mail: nao9877@gmail.com

Financial remuneration; none

Figure 2 and 3 must be published in color.

Abstract

Background: Recently, the existence of sensory branches of the suprascapular nerve (SSN) has been reported, and sensory disturbance at the lateral and posterior aspect of the shoulder has been focused on as a symptom of SSN palsy. We have performed arthroscopic release of SSN at the suprascapular notch in patients with the sensory disturbance since 2006. The purposes of this study were to introduce the arthroscopic surgical technique and to investigate postoperative recovery of sensory disturbance.

Methods: Twenty-five shoulders (11 men and 14 women, average age: 63.9 years (range, 41-77)) followed for more than 1 year were included in this study. Arthroscopic decompression of SSN was performed using a suprascapular nerve portal (SN portal) as a landmark for approaching the suprascapular notch. Sensory disturbance of the shoulder was evaluated pre- and postoperatively. The follow-up period was 12-30 months (avg. 18.5).

Results: The arthroscopic procedure was able to be performed safely. The preoperative sensory disturbance fully recovered postoperatively in all shoulders.

Conclusion: Arthroscopic release of SSN is considered to be a useful procedure for the entrapment of SSN at the suprascapular notch. The sensory disturbance at the lateral and posterior aspect of the shoulder can be used as one of the criteria of diagnosing SSN

palsy especially in shoulders with massive rotator cuff tear, which usually have difficulty in diagnosing and assessing the treatment results of associated SSN palsy.

Level of evidence: Level IV, Case series, Treatment study

Key words: suprascapular nerve; suprascapular notch; arthroscopic decompression; sensory disturbance; nerve palsy

Introduction

Suprascapular nerve (SSN) palsy is caused by various pathologies, such as an entrapment at the suprascapular notch or the spinoglenoid notch, compression by a space occupying lesion such as ganglion or tumor, and traction in overhead sports. For entrapment at the suprascapular notch, though satisfying results of open procedures of resection of the superior transverse scapular ligament (STSL) have been achieved, a large skin incision and invasion to the muscles are necessary. In 2006, Bhatia et al.[5] first described arthroscopic SSN decompression at the suprascapular notch. And, in 2007, Lafosse et al.[12] reported preliminary satisfactory results of the procedure. We have performed arthroscopic SSN decompression since October 2006. Recently, there have been some reports of the existence of sensory branch of SSN[2,9] and sensory disturbance in patients with SSN palsy.[11] In this series, we have performed arthroscopic SSN decompression for the patients with the sensory disturbance at the lateral to posterior aspect of the shoulder. The objectives of this study were to introduce our new procedure of arthroscopic decompression of SSN and to evaluate the postoperative change of the sensory disturbance.

Materials and Methods

Between October 2006 and October 2008, arthroscopic SSN decompression was performed in 30 shoulders of 30 patients with SSN palsy by the same surgeon. Among them, 25 patients (83.3%) were able to be followed for more than 1 year and included in this study. There were 11 men and 14 women; average age at the surgery was 63.9 years (range, 41-77 years). In this series, the patients were diagnosed as SSN palsy when they had dull pain or deep pain of the shoulder, and there existed sensory disturbance at the lateral and posterior aspect of the shoulder. Muscle atrophy and/or weakness of supraspinatus and infraspinatus that are not relevant in incomplete or small rotator cuff tear cases were observed in most cases. And effectiveness of SSN block test by a procedure that we have reported previously[15] are also considered to support the diagnosis. For our SSN block test, the needle was inserted at the midpoint of the anterolateral edge of the acromion and medial edge of the scapular spine, and inclined at a 30º angle toward the dorsal direction from the axis of the body until it reached the base of the coracoid process. Since the sensory branch of SSN usually runs along the dorsal aspect of the base of the coracoid process, [15] mixed 5ml of 1% lidocaine and 5ml of 0.75% ropivacaine was injected at that point. Nerve conductive velocity of the SSN was examined in 13 cases and only 1 cases showed delay. SSN palsy caused by

paralabral cysts was excluded from this study because, in many cases of paralabral cysts, the entrapment occurs at the spinoglenoid notch to the isolated infraspinatus branch. In 3 cases, degenerative changes of cervical spine at the level of C5 and C6 were found; however, no compression of the spinal cord or nerve roots was observed on MRI, and muscle weakness of biceps was not found.

Twenty-six associated diagnoses of the same shoulder were observed in 24 shoulders; there were 20 rotator cuff tears (5 incomplete tears, 3 medium tears, 2 large tears, and 6 massive tears) including 2 re-tear after cuff surgery, 3 rheumatoid arthritis, 2 cuff tear arthropathy, and 1 frozen shoulder. For these conditions, additional procedures (5 arthroscopic rotator cuff repair, 8 open rotator cuff repair, 4 arthroscopic subacromial decompression, 3 arthroscopic capsular release, 3 humeral head replacement, 2 arthroplasty of acromio-clavicular joint, and 2 total shoulder arthroplasty) were performed simultaneously.

Operative procedure

Surgery was performed in a beach chair position under general anesthesia. The mid-lateral portal was used as a viewing portal (Fig. 1). The antero-lateral portal and the portal between the coracoid process and clavicle (coraco-claviclar portal; CC portal)

were used as a working portal. And we used the suprascapular nerve (SN) portal to approach the suprascapular notch. The SN portal was placed at the midpoint of the line connecting the antero-medial angle of acromion and the medial edge of scapular spine. This portal was modified from the insertion point of the new SSN block method, which we have previously reported.[15] The SN portal also could be used as a working or retractor portal. At first, a blunt trocar was inserted from the SN portal parallel to the body axis until it reached to the supraspinatus fossa of scapula. Then, the tip of the trocar was moved toward antero-lateral direction along the supraspinatus fossa and the depression of the suprascapular notch was felt. There the STSL was oriented by feeling snapping of the tip of the trocar at the ligament. It is important the trocar was inserted beneath the STSL and held by the assistance. Then the scope and shaver were inserted from the antero-lateral portal and CC portal toward the trocar. Soft tissue was resected by a soft tissue shaver with suction around the trocar first to obtain the view, and then along the base of the coracoid process and anterior border of the supraspinatus muscle to expose the STSL. The suprascapular artery, which usually runs across the surface of the ligament, was used as a landmark to find the ligament (Fig. 2). Once the artery was identified, the trocar was used to retract the supraspinatus muscle to obtain better view of the STSL and suprascapular notch. The ligament was dissected by

scissors and excised by a punch and the suprascapular nerve was observed to be released (Fig. 3). When there is partial or complete ossification of the ligament, we remove the ossified ligament using a punch. In some cases, sensory branch that branched just distal to the ligament was observed. Postoperative immobilization and rehabilitation were applied according to the associated procedure.

Clinical evaluation

Pain sensation around the shoulder was investigated using a pinprick test pre- and postoperatively. The average follow-up period was 18.5 months (range; 12-30).

Results

There were no complications of the surgery including infection or nerve injury. Preoperative sensory disturbance area included the posterior angle of the acromion in all cases, and spread from the lateral side of the shoulder to the posterior aspect of axilla in most of the cases (Fig. 4). Twenty-two shoulders showed hypalgesia and 3 shoulders showed hyperalgesia. At the time of the final follow-up, the sensory disturbance was completely recovered in all shoulders.

Case presentation

Case; sixty-six year old female with SSN palsy and medium-sized cuff tear. Hyperalgesia of 120% was observed at the posterior and lateral aspect of the shoulder preoperatively (Fig. 5a). Arthroscopic release of SSN and arthroscopic rotator cuff repair were performed. Twelve months after surgery, the sensory disturbance has completely disappeared. Good repaired cuff integrity was observed on MRI (Fig. 5b). Comparing Y-shaped view of the pre- and postoperative MRI, postoperative improvement of the atrophy of the supraspinatus and infraspinatus muscle was observed (Fig. 5c).

Discussion

The existence of sensory branch of SSN has been reported,[2,9] however, there has been only one clinical series, to our knowledge, that focused on the sensory disturbance in association with the SSN palsy. Ikegami[11] reported that sensory disturbance of the posterior aspect of shoulder and axilla was observed in patients with SSN palsy at the site of suprascapular and/or spinoglenoid notch and the sensory disturbance improved postoperatively in some patients. In our series, all patients demonstrated the sensory disturbance at the lateral and posterior area of the shoulder, which always included the posterior angle of the acromion. And, the sensory disturbance completely recovered, usually in 2 weeks, postoperatively in all cases. From these facts, the lateral and posterior area of the shoulder is considered to be the proper area of SSN, and the sensory disturbance at this area is useful as diagnosing SSN palsy. In our series, all patients except for one had associated shoulder lesions that were treated at the same time; therefore, it is difficult to evaluate improvement of the clinical findings as the effect of the decompression of SSN separately. We believe that the postoperative improvement of the sensory disturbance proves the effect of decompression of the SSN. It is often difficult to diagnose SSN palsy especially in patients with massive rotator cuff tear because some symptoms, such as muscle atrophy or weakness of supraspinatus

and infraspinatus, are in common. And electrophysiological examination (EMG or nerve conductive velocity) often does not prove the compression of the SSN, as also in our series, possibly because the length of SSN between the suprascapular notch and the insertion to the muscles is short so that it is difficult to detect the delay of the nerve conduction. The sensory disturbance of SSN will be a useful finding to diagnose SSN palsy especially in such cases with massive supraspinatus and infraspinatus tendon tear.

Mallon[14] reported that SSN palsy occurred in massive cuff tear shoulders because the torn muscles were retracted proximally and the SSN was entrapped at the suprascapular notch. In our cases, however, SSN palsy existed not only in massive rotator cuff tear cases but patients with small or incomplete cuff tear or even no tears. And the associated pathology showed wide variety in each patient. Percentage of existence of SSN palsy in patients with shoulder disorders may be higher than we currently recognize. If SSN palsy is remained undiagnosed and untreated, the patient will have residual pain after a shoulder operation. Therefore, it is important to always consider a possibility of association of SSN palsy when we diagnose patients with shoulder problems. It is often difficult to repair massively torn cuff tendon at the original footprint and, therefore, it is uncertain if the entrapment of the SSN is

completely released after surgery. Mallon[14] reported that the nerve conduction improved after partial repair of massive rotator cuff tear in some cases but not in all. Moreover, Warner[24] suggested from the cadaveric study that the lateral advancement of the rotator cuff more than 1 cm may cause excessive tension in the motor branches of the SSN. Since arthroscopic release of SSN is low invasive and can be performed simultaneously with other procedures, we recommend to perform the SSN release in cases with SSN palsy in association with massive rotator cuff tear.

Since Bhatia[5] first reported the technique of arthroscopic decompression of SSN in 2006, this procedure has become noticeable and a number of papers of the anatomical studies regarding the approach to the suprascapular notch,[4,17,22] surgical techniques of excision of the STSL,[1,3,8,13,19,20,22] and case reports[1,3,10,20] were published. As a series of postoperative clinical outcome, Lafosse[12] reported postoperative improvement of pain and muscle strength in all 10 cases. Shah[21] reported satisfactory clinical results of 27 cases of SSN release without rotator cuff pathology. Regarding the operative procedure, Bhatia[5] and Lafosse[12] both reported an original portal to approach the SSN at the suprascapular notch. Bhatia used portal that was on the bisector between the clavicle and scapular spine and 25 mm medial from the medial edge of the acromion. Lafosse's portal was on the same line as Bhatia but 70 mm

medial from the lateral edge of the acromion. These portals, however, can vary according to individual body sizes, and have possibility to widely vary in the antero-posterior direction. Soubevrand[22] anatomically studied new portals to approach both the suprascapular notch and spinoglenoid notch; however, the approach needs wide detachment of the supraspinatus muscle. In most of the previous papers, the coracoclavicular ligament was first exposed along the clavicle and the STSL was found from the base of coracoclavicular ligament. This procedure has a risk of damaging the coracoclavicular ligament, and needs time for wide resection of soft tissue. Recently, Kim[13] reported that the superior border of scapula is useful as a landmark to approach the suprascapular notch. To make the approach to the STSL more reliably and faster, we have developed the new SN portal to approach the SNN. The SN portal uses the landmarks of acromion and scapular spine that are palpable from the body surface, and are not affected by individual body size. By inserting the scope and equipments towards the blunt trocar that was held through the SN portal, the time to expose the STSL was able to be shortened.

Reineck[17] reported 3 cases of suprascapular artery that ran beneath the STSL. It is important to recognize the possibility of anatomical variation in performing arthroscopic procedure. And, since partial or complete ossification of the ligament is

not a rare condition, [7,16,18,23] especially in elder patients, and the shape of the suprascapular notch has wide variety, [6,18] preoperative evaluation of 3D-CT is mandatory for performing this procedure. When there is narrowing of the notch by ossification of the ligament, we remove the ossified ligament and widen the notch.

Conclusion

In conclusion, we proved the accuracy and efficacy of the arthroscopic release of SSN by focusing on the postoperative change of the sensory disturbance. The operative procedure is low invasive and safe; and complete recovery of the sensory disturbance of SSN was obtained after surgery. The sensory disturbance at the lateral and posterior aspect of the shoulder was useful as criteria for diagnosing and evaluating postoperative improvement of SSN palsy.

References

1. Agrawal V: Arthroscopic decompression of a bony suprascapular foramen. Arthroscopy 2009; 25: 325-8. doi:10.1016/j.arthro.2008.06.014

2. Ajmani ML: The cutaneous branch of the human suprascapular nerve. J Anat 1994; 185: 439-42.

3. Barber FA: Percutaneous arthroscopic release of the suprascapular nerve. Arthroscopy 2008; 24: e1-4. doi:10.1016/j.arthro.2007.05.004

4. Barwood SA, Burkhart SS, Lo IK: Arthroscopic suprascapular nerve release at the suprascapular notch in a cadaveric model: an anatomic approach. Arthroscopy 2007; 23: 221-5. doi:10.1016/j.arthro.2006.11.011

5. Bhatia DN, de Beer JF, van Rooyen KS, du Toit DF: Arthroscopic suprascapular nerve decompression at the suprascapular notch. Arthroscopy 2006; 22: 1009-13. doi:10.1016/j.arthro.2006.05.012

6. Dunkelgrun M, Iesaka K, Park SS, Kummer FJ, Zuckerman JD: Interobserver reliability and intraobserver reproducibility in suprascapular notch typing. Bull Hosp Jt Dis 2003; 61: 118-22.

7. Edelson JG: Bony bridges and other variations of the suprascapular notch. J Bone Joint Surg Br 1995; 77: 505-6.

8. Ghodadra N, Nho SJ, Verma NN, Reiff S, Piasecki DP, Provencher MT, et al: Arthroscopic decompression of the suprascapular nerve at the spinoglenoid notch and suprascapular notch through the subacromial space. Arthroscopy 2009; 25: 439-45. doi:10.1016/j.arthro.2008.10.024

9. Horiguchi M: The cutaneous branch of some human suprascapular nerve. J Anat 1980; 130: 191-5.

10. Hosseini H, Agneskirchner JD, Tröger M, Lobenhoffer P: Arthroscopic release of the superior transverse ligament and SLAP fixation in a case of suprascapular nerve entrapment. Arthroscopy 2007; 23: e1-4. doi:10.1016/j.arthro.2006.07.033

11. Ikegami H, Ogawa K, Nakamichi N, Matsumura N, Shiono S : The evaluation of sensory function for patients with suprascapular nerve palsy. The Shoulder Joint 2006; 31:429-32.

12. Lafosse L, Tomasi A, Corbett S, Baier G, Willems K, Gobezie R: Arthroscopic release of suprascapular nerve entrapment at the suprascapular notch: technique and preliminary results. Arthroscopy 2007; 23: 34-42. doi:10.1016/j.arthro.2006.10.003

13. Kim SH, Kim SJ, Sung CH, Koh YG, Kim YC, Park YS: Arthroscopic suprascapular nerve decompression at the suprascapular notch. Knee Surg Sports Traumatol Arthrosc 2009; 17: 1504-7. doi:10.1007/s00167-009-0858-1

14. Mallon WF, Wilson RJ, Basamania CJ: The association of suprascapular neuropathy with massive rotator cuff tears: a preliminary report. J Shoulder Elbow Surg 2006; 15: 395-8. doi:10.1016/j.jse.2005.10.019

15. Matsumoto D, Suenaga N, Oizumi N, Hisada Y, Minami A: A new nerve block procedure for the suprascapular nerve based on a cadaveric study. J Shoulder Elbow Surg 2009; 18: 607-11. doi:10.1016/j.jse.2009.01.005

16. Prescher A: Anatomical basics, variations, and degenerative changes of the shoulder joint and shoulder girdle. Eur J Radiol 2000; 35: 88-102.

17. Reineck JR, Krishnan SG: Subligamentous suprascapular artery encountered during arthroscopic suprascapular nerve release: a report of three cases. J Shoulder Elbow Surg 2009; 18: e1-3. doi:10.1016/j.jse.2008.08.007

18. Rengachary SS, Burr D, Lucas S, Hassanein KM, Mohn MP, Matzke H: Suprascapular entrapment neuropathy: a clinical, anatomical, and comparative study. Part 2: anatomical study. Neurosurgery 1979; 5: 447-51.

19. Romeo AA, Ghodadra NS, Salata MJ, Provencher MT: Arthroscopic suprascapular nerve decompression: indications and surgical technique. J Shoulder Elbow Surg 2010; 19: 118-23. doi:10.1016/j.jse.2010.01.006

20. Sergides NN, Nikolopoulos DD, Boukoros E, Papagiannopoulos G: Arthroscopic

decompression of an entrapped suprascapular nerve due to an ossified superior transverse scapular ligament: a case report. Cases Journal 2009; 2: 8200.

21. Shah AA, Butler RB, Sung SY, Wells JH, Higgins LD, Warner JJ: Clinical outcomes of suprascapular nerve decompression. J Shoulder Elbow Surg 2011; E pub. doi:10.1016/j.jse.2010.10.032

22. Soubeyrand M, Bauer T, Billot N, Lortat-Jacob A, Gicquelet R, Hardy P: Original portals for arthroscopic decompression of the suprascapular nerve: An anatomic study. J Shoulder Elbow Surg 2008; 17: 616-23. doi:10.1016/j.jse.2007.10.002

23. Ticker JB, Djurasovic M, Strauch RJ, Ernest WA, Pollock RG, Flatow EL, et al: The incidence of ganglion cysts and other variations in anatomy along the course of the suprascapular nerve. J Shoulder Elbow Surg 1998; 7: 472-8.

24. Warner JP, Krushell RJ, Masquelet A, Gerber C: Anatomy and relationships of the suprascapular nerve: anatomical constraints to mobilization of the supraspinatus and infraspinatus muscles in the management of massive rotator-cuff tears. J Bone Joint Surg Am 1992; 74: 36-45.

Figure legends

Fig. 1; Portals for arthroscopic release of suprascapular nerve

Fig. 2; The superior transverse scapular ligament was exposed.

Fig. 3; The superior transverse scapular ligament was excised and the suprascapular nerve was released.

Fig. 4; Typical sensory disturbance at the posterior and lateral side of the shoulder.

Fig. 5a; Preoperative sensory disturbance at the shoulder and MRI.

Fig. 5b; Range of motion and MRI (oblique-coronal view) at 12 months after surgery.

Fig. 5c; Pre- and postoperative MRI (Y-shaped sagittal view) of cuff muscles.

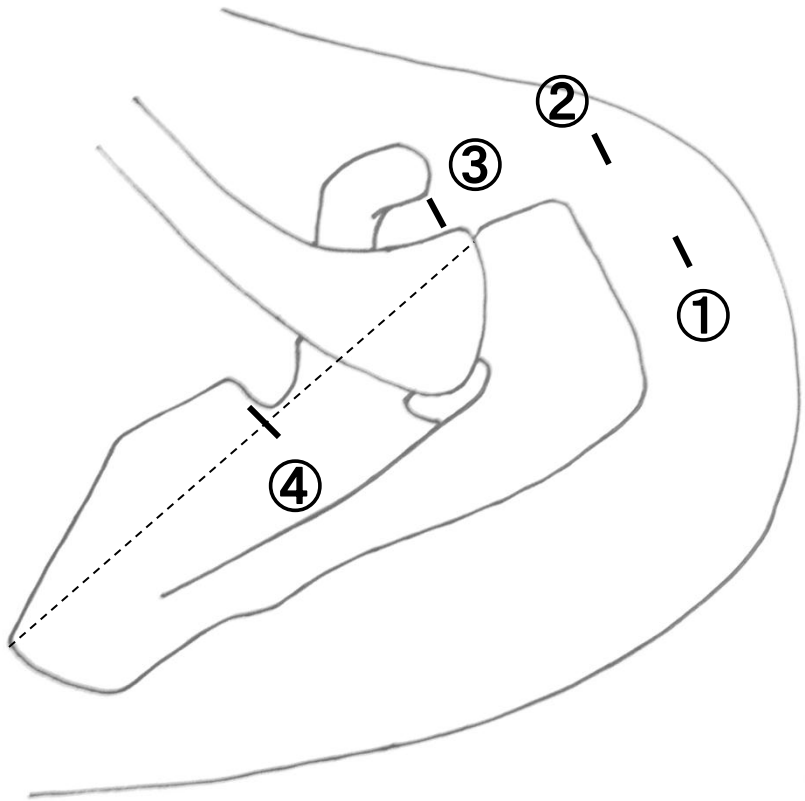

① Mid-lateral portal
② Antero-lateral portal
③ CC portal (Coraco-claviclar portal)
④ SN portal (Suprascapular portal)

Fig. 1

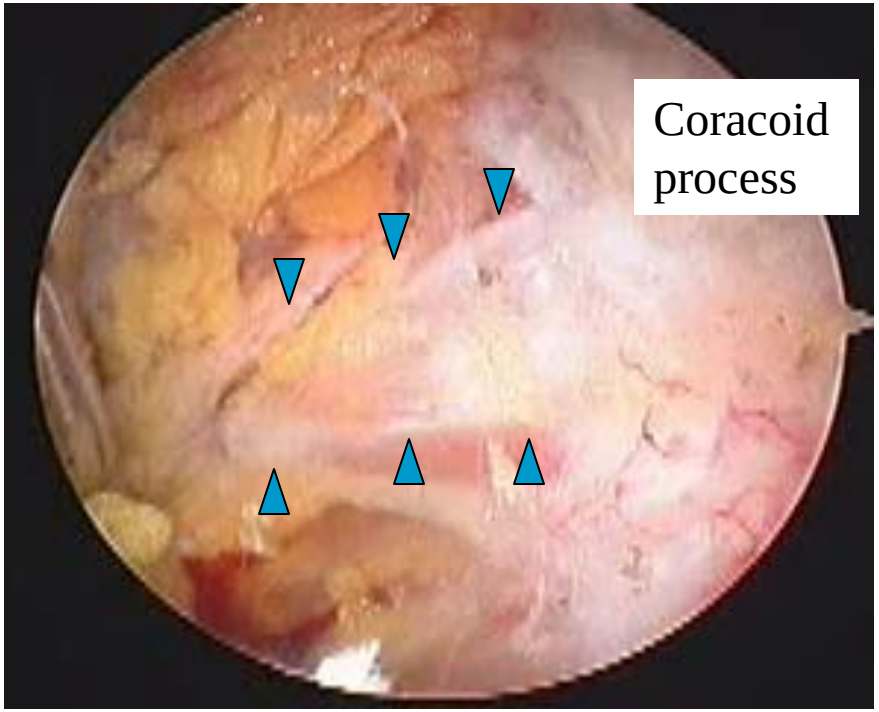

▲ Superior transverse scapular ligament

Fig. 2

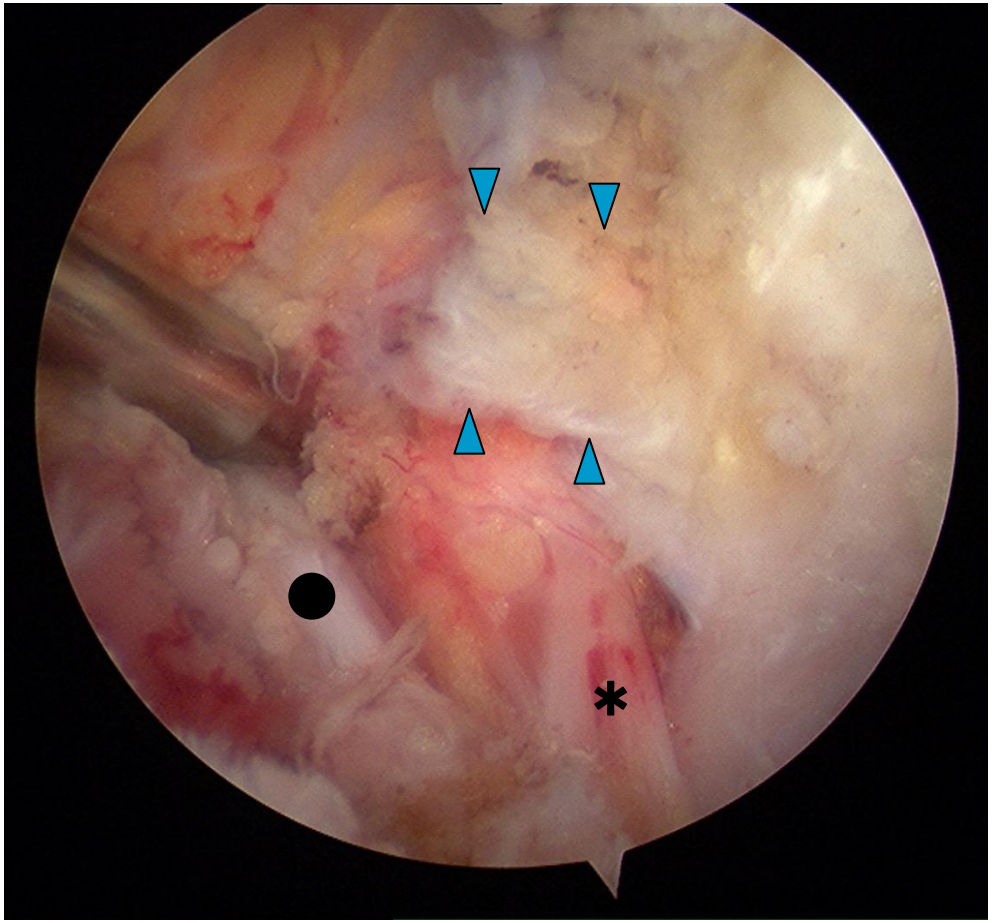

✱ Suprascapular nerve

● Suprascapular artery

▲ Excised superior transverse scapular ligament

Fig. 3

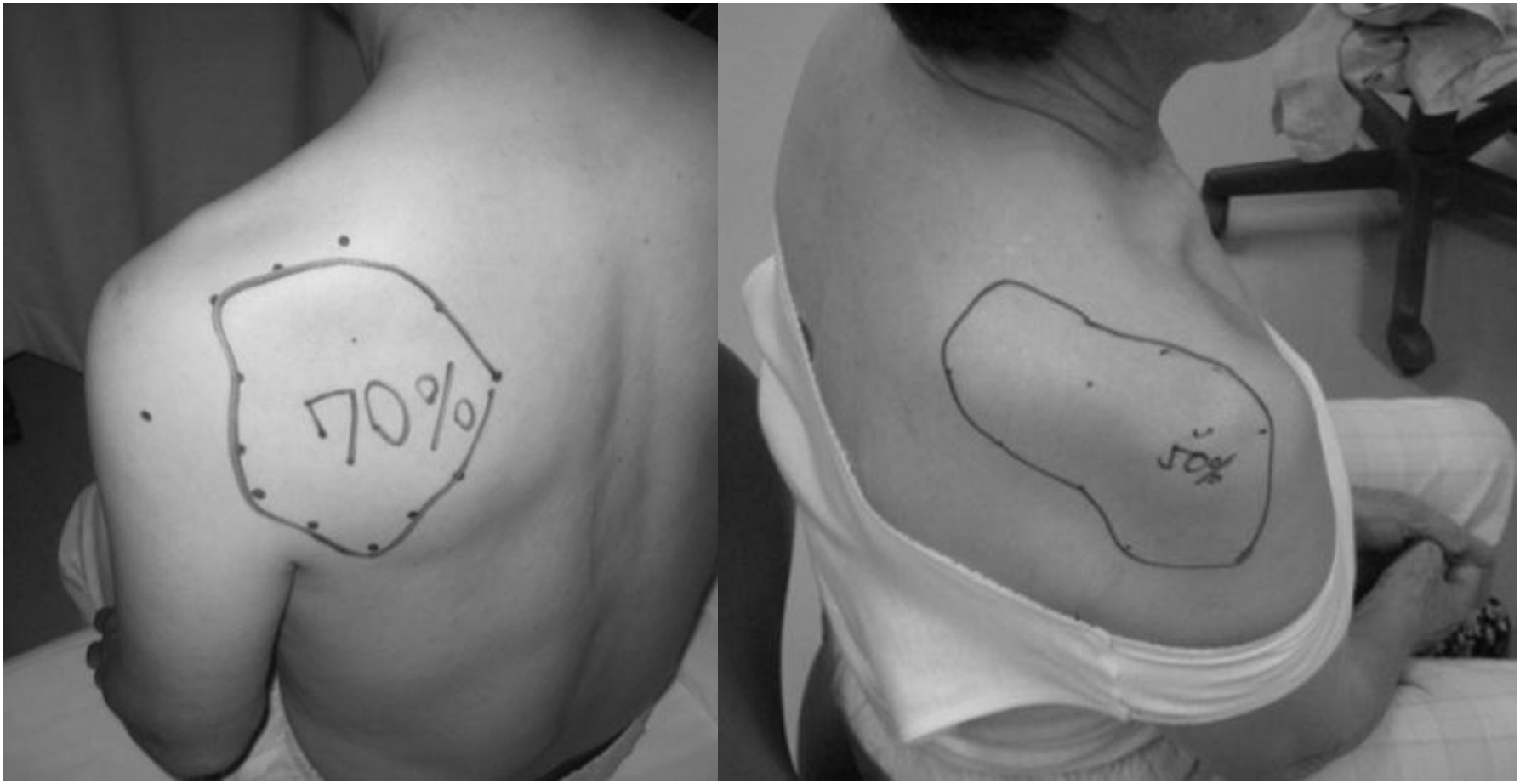

Fig. 4

Fig. 5a

Fig. 5b

Preop. **Postop. 12M**

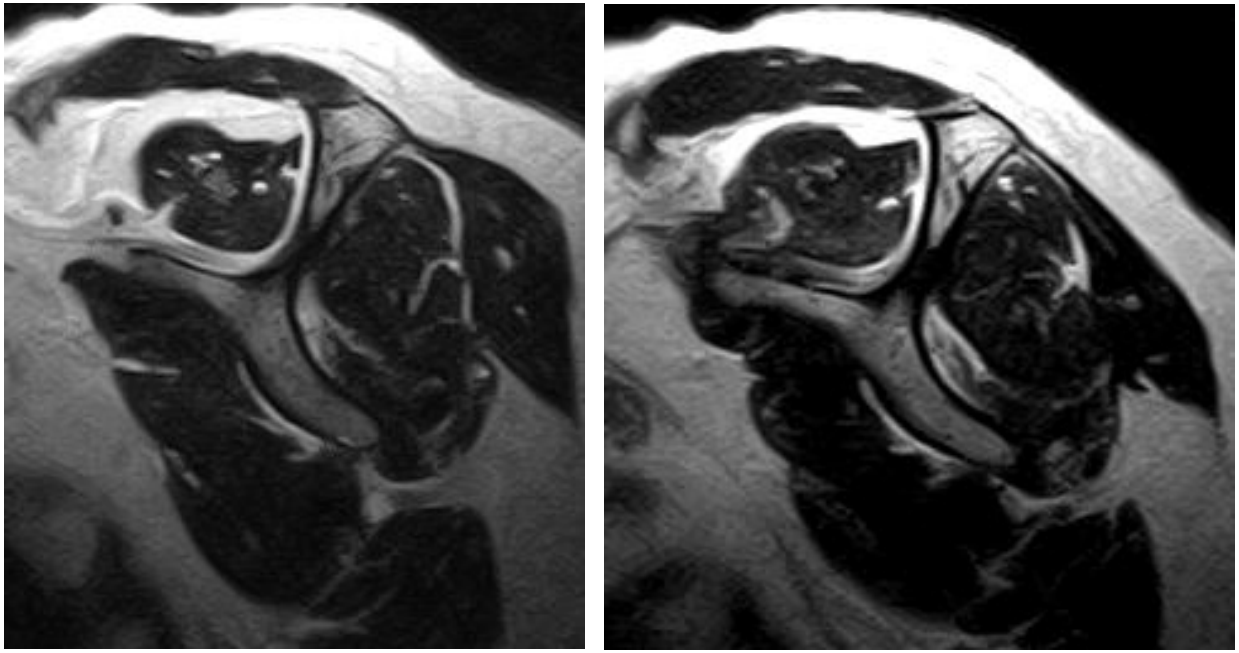

Fig. 5c