HOKKAIDO UNIVERSITY

Title	Pancreatic ductal adenocarcinomas with multiple large cystic structures : A clinicopathologic and immunohistochemical study of seven cases
Author(s)	Nitta, Takeo; Mitsuhashi, Tomoko; Hatanaka, Yutaka; Hirano, Satoshi; Matsuno, Yoshihiro
Citation	Pancreatology, 13(4), 401-408 https://doi.org/10.1016/j.pan.2013.05.004
Issue Date	2013
Doc URL	http://hdl.handle.net/2115/53346
Type	article (author version)
File Information	Pancreatology_13_401-408.pdf

Instructions for use

Hokkaido University Collection of Scholarly and Academic Papers : HUSCAP

Pancreatic ductal adenocarcinomas with multiple large cystic structures: A clinicopathologic and immunohistochemical study of seven cases

Takeo Nitta[1, 2], Tomoko Mitsuhashi[1], Yutaka Hatanaka[1], Satoshi Hirano[2] and Yoshihiro Matsuno[1]

[1]*Department of Surgical Pathology, Hokkaido University Hospital, Sapporo, Hokkaido, Japan*

[2]*Department of Surgical Oncology, Division of Cancer Medicine, Hokkaido University Graduate School of Medicine, Sapporo, Hokkaido, Japan*

Correspondence: Tomoko Mitsuhashi, M.D., Ph.D., Department of Surgical Pathology, Hokkaido University Hospital, N14, W5, Kita-ku, Sapporo, Hokkaido 060-8648, JAPAN

Running title: PDAs with multiple large cystic lesions

Abstract

Background/Objectives: Pancreatic ductal adenocarcinoma (PDA) with cystic change is classified into several types according to the features of the cysts; however, those tumors do not constitute a uniform group, and the classification is controversial. In this study, we have described a series of cystic PDAs that show distinctive and previously unreported morphologic and immunohistochemical features. ***Methods*:** We analyzed 200 cases of PDA treated surgically at a single institution, and extracted the clinical and histopathological features of 7 tumors showing multiple large cystic (MLC) structure. ***Results***: Preoperative radiographic images revealed a multilocular mass in the pancreas which was similar to intraductal papillary mucinous neoplasm or mucinous cystic neoplasm. These tumors were associated with more than 5 large cystic structures and numerous intratumoral microcysts lined by epithelial cells with various degrees of atypia. The average maximal diameter of the cysts (3.7 cm) was much larger than that of previously reported. Immunohistochemically, the cyst-lining epithelia were almost negative for mucin core protein (MUC) 1, MUC2, and MUC6, and showed only focal staining for MUC5AC. Maspin, CEA, and p53 were strongly positive, and the Ki-67 labeling index was high in both cells in solid areas and cyst-lining epithelia. ***Conclusion*:** We considered the MLC structures in PDA to be a mixture of ectatic

neoplastic glands and retention cysts with ductal cancerization or pancreatic intraepithelial neoplasia (PanIN); however, they might represent a new entity of cystic PDA because of the unusually large size of the dilated cysts.

Key words: pancreas; cyst; multiple large cysts; ductal adenocarcinoma; PanIN

Introduction

Ductal adenocarcinoma with a solid growth pattern is the major type of pancreatic tumor,[1, 2] characterized by irregular glandular proliferation of tumor cells on a fibrous stroma background. Cystic tumors of the pancreas are relatively rare in comparison with solid tumors; however, they are being diagnosed increasingly often due to improvements in abdominal imaging modalities such as high-resolution computed tomography (CT) and magnetic resonance imaging (MRI).[3] The commonest cystic pancreatic tumors are intraductal papillary-mucinous neoplasm (IPMN), serous cystic neoplasm (SCN), mucinous cystic neoplasm (MCN) and solid pseudopapillary neoplasm (SPN).[2-6] We recently analyzed 200 cases of pancreatic ductal adenocarcinoma (PDA) that were treated surgically at a single institution, and extracted the clinical and histopathological features of 7 cases that showed an unusual multiple large cystic (MLC) structures.

PDAs with MLC lesions did not wholly fulfill the criteria proposed by Kosmahl *et al.*[2] for classification of cystic PDAs. Since, like conventional PDAs, MLC-type PDA has a very poor prognosis, diagnostic pathologists should bear in mind that MLC-type PDA can form cystic lesions similar to those of IPMN and MCN.

Materials and methods

Patient selection

A total of 200 PDAs, which were surgically resected at the Department of Surgical Oncology, Hokkaido University Hospital, between December 2000 and July 2011, and had been pathologically confirmed, were examined for the present analysis. Among them, 22 (11%) showed cystic lesions. Fifteen out of these 22 cases were classifiable as cystic pancreatic ductal adenocarcinomas on the basis of the criteria of Kosmahl *et al.*[2] The remaining 7 cases were PDAs with a MLC structure that were not classifiable by those criteria. Here we describe the clinicopathological and immunohistochemical features of these MLC-type PDAs. All of the tumors had been diagnosed on the basis of the WHO classification. The clinical characteristics and follow-up data for the patients were obtained from the medical records and, in some cases, from the physicians in charge.

Validation test

An additional 5 cases (Cases A to E) of non-cystic (conventional) PDAs archived from our files were used to validate the immunohistochemical staining in our hospital.

Histopathological examination

All specimens were fixed with 10% neutral buffered formalin, and embedded in paraffin. Deparaffinized sections were stained with hematoxylin-eosin and examined by light microscopy.

Immunohistochemistry

Representative serial sections were prepared from formalin-fixed, paraffin-embedded (FFPE) tissue blocks. Immunohistochemistry was performed using the EnVision+ system (Dako Cytomation, Glostrup, Denmark). Details of the primary antibodies used are listed in Table 1. Negative and positive controls were included on each of the tested glass slides.

KRAS mutation analysis

In the 7 PDAs showing prominent MLC structures, we investigated the presence of mutations in codon 12 of the *KRAS* gene. The method used has been described previously. Briefly, it is a high-throughput screening system utilizing Luminex (xMAP) technology (the fluorescent bead-based multiplex analyte profiling method), in combination with the polymerase chain reaction-reverse sequence-specific

oligonucleotide method using FFPE tissues, giving results comparable to those obtained by direct sequencing.[7]

Postoperative survival

Follow-up information after surgical resection was available for all 22 patients diagnosed as having PDA with a cystic structure. Response to chemotherapy was evaluated by the criteria based on the Response Evaluation Criteria in Solid Tumors (RECIST) version 1.0.[8] The mean follow-up period was 23 months (range, 4-60 months). We compared the postoperative survival of patients with cystic PDA with and without MLC structures.

Statistical analysis

Statistical analyses were performed using StatFlex 6.0 (Artech Co. Ltd., Japan). Survival curves were calculated by the Kaplan-Meier method, and differences in survival were evaluated using the log-rank test. Statistical significance was set at $p<0.05$.

Results

Clinical and radiographic features

The main clinicopathologic features are summarized in Table 2. Of the 7 studied patients, 5 were men and 2 were women, and their mean age was 66 years (range, 51 to 79 years). Four patients were asymptomatic, and their pancreatic tumors had been identified incidentally during routine medical examinations. The remaining 3 patients complained of epigastralgia, diarrhea and back pain, respectively. One patient had a history of acute pancreatitis (case 7). Two patients revealed no elevation of serum tumor marker preoperatively. The remaining 5 patients revealed elevation of serum tumor marker, either carbohydrate antigen 19-9 (CA19-9) or carcinoembryonic antigen (CEA) .

Clinical imaging studies revealed the presence of pancreatic tumors with MLC features. A representative image from case 6 is shown in Figure 1. Ultrasonography demonstrated the MLC structure as a hypoechoic multilocular lesion, and contrast-enhanced CT imaging demonstrated a round, circumscribed, multilocular fluid attenuation mass in the pancreas. No definite communication between the cysts and pancreatic ducts was identified. Axial T2-weighted MRI demonstrated a round, circumscribed, multilocular high T2 signal-intensity lesion in the pancreas. Magnetic

resonance cholangiopancreatography (MRCP) revealed a multilocular high-signal-intensity lesion and obstruction of the main pancreatic duct. Summary of the endoscopic retrograde pancreatography (ERP) or MRCP findings of MLC-type PDAs is described in Table 3. In most cases, the ERP or MRCP of MLC-type PDAs demonstrated the dilatation and obstruction (or narrowing) of the main pancreatic duct and showed communication between the main pancreatic duct and cysts in three cases.

All of these neoplasms were located in the pancreatic body and tail. All of the patients underwent either distal pancreatectomy (n=3, 43%) or distal pancreatectomy with en bloc celiac axis resection (n=4, 57%). Four of the patients received postoperative chemotherapy; gemcitabine only for cases 3, 4, and 7, and gemcitabine and S-1 for case 1. Three out of 4 patients who received postoperative chemotherapy had progressive disease. The tumor response was not evaluable in 1 patient (case 7) in whom contrast enhanced CT examination had not been performed yet due to a short duration since postoperative chemotherapy started. Four of the patients suffered postoperative recurrence, and 3 were alive without recurrence at the time of writing. Recurrent tumors were observed in the peritoneum in 2 cases (cases 3 and 5), and the lymph nodes around the abdominal aorta (case 1) and lung (case 4) in the remaining 2 cases, respectively.

Macroscopic features

All of the MLC-type PDAs had similar characteristic macroscopic features: a mixture of various-sized rounded large cysts distributed at the periphery of solid lesions and intratumoral small cysts (Figure 2). Most of these tumors contained multiple (more than 5) large cystic structures. The maximal cyst diameter was 2.0 cm or more in all patients (range, 2.0 to 5.0 cm, mean 3.7 cm). The average tumor size including the MLC structure was 6.0 cm (range, 4.0 to 8.0 cm).

Histologic features

The cysts in the neoplasms were lined by cuboidal to columnar epithelial cells (Figure 3) and formed a single cell layer, although occasional papillary projections and Roman-bridge-like structures were partially evident. The cytoplasm was usually eosinophilic, and the nuclei were irregularly round to oval. The mitotic count in the high-grade dysplastic epithelial cells lining the cyst wall varied from case to case (range, 0 to 3 per 10 high-power fields, Table 2). Mucin secretion was not evident. Cyst-lining epithelial cells tended to show high-grade dysplasia in closer proximity to the tumor, whereas low-grade dysplasia and partially normal epithelium were predominant in the

periphery (Figure 3C-D). The cystic structures were embedded in a paucicellular fibrotic and/or desmoplastic stroma, which did not resemble an ovarian-like stroma.

Most of the tumors were classified as moderately differentiated tubular adenocarcinoma as they contained a mixture of medium-sized duct-like structures, small tubular glands of variable size and shape, and partially cribriform glands. Numerous angular or irregular neoplastic duct-like glands were present within the tumor, forming a honeycomb-like pattern (Figure 3A-B).

Immunohistochemical features

The immunohistochemical profiles are summarized in Table 4 and Figure 4. Immunohistochemically, all of the MLC-type PDAs were positive for maspin and CEA in the both cells of the cyst lining and intervening smaller tubular glands in the solid area. In some cases, these components were stained weakly for MUC5AC. The cyst-lining epithelia of the MLC-type PDAs were completely negative for MUC1. On the other hand, their non-cystic lesions stained focally and strongly by anti-MUC1. No immunoreactivity was seen for MUC2 in the both of cyst-lining epithelia and solid lesions in the MLC-type PDAs. Out of seven MLC-type PDAs, only two cases were focally and weakly positive for MUC6 in the cystic epithelia and solid lesions,

respectively. Nuclear staining for p53 was evident in the majority of the neoplastic epithelia in the tumors. The Ki-67 labeling index varied from case to case (mean; 34.2%, range; 23.3-44.7%).

All five cases of non-cystic (conventional) PDAs, used as validation tests, were strongly immunostained by anti-MUC1. The results of other markers (MUC2, MUC5AC, MUC6, maspin and p53) were almost consistent with those of solid lesions of MLC-type PDAs.

KRAS mutation analysis

Analysis of the *KRAS* gene demonstrated mutation involving the codon 12 in 6 out of 7 cases (86%, Table 2).

Postoperative outcome

The overall survival (OS) rate for the 7 MLC-type PDAs patients was 80% at 1 year, 53% at 3 years after surgery. On the other hand, the OS rate for the 15 other cystic-type PDAs patients was 76% at 1 year, 38% at 3 years after surgery.

A postoperative follow-up study of the 22 patients with PDAs with cystic structures revealed that postoperative outcome was not affected by the presence of a MLC

structure (overall survival, p=0.528, disease-free survival, p=0.801) (Figure 5).

Discussion

Most pancreatic neoplasms have a solid growth pattern and are classified as ductal adenocarcinoma.[1, 2] Cystic neoplasms of the pancreas are relatively uncommon, but have increasingly attracted a great deal of attention recently because they encompass a wide spectrum of pathologic entities that vary considerably in morphology, clinical behavior, and pathogenesis.[2-6] As a result of recent improvements in abdominal imaging modalities, an increasing number of neoplastic cystic lesions of the pancreas are being identified in patients who are clinically asymptomatic.[3] The pathological classification of these various types of cystic pancreatic neoplasms is still evolving, but the most common types include IPMN, SCN, MCN, and SPN.[2-6] Rarer cystic neoplasms include acinar cell cystadenocarcinoma,[9] acinar cell cystadenoma,[10] cystic neuroendocrine tumor[11] and cystic mesenchymal tumor.[12] However, it should always be borne in mind that the differential diagnoses of cystic neoplasms of the pancreas should also include PDA with cystic change.

Recently, a morphological variant of PDA forming large ductal elements, “large duct type” ductal adenocarcinoma, has been reported.[13] These tumors may have microcystic and papillary growth patterns that closely mimic those of non-invasive cystic and papillary pancreatic tumors such as IPMN, MCN, and the ducts involved in PanIN.[13]

Based on the descriptions of those tumors, we consider that the features of the large ductal elements they contained were similar to those seen in the large cysts in our present series of 7 MLC lesions, although the cysts in the latter had a much larger average diameter. Our studied cases also showed microcystic changes within the solid area, which have also been reported as a characteristic feature of cystic PDAs.

Kosmahl *et al.*[2] screened for macrocystic changes in a series of 483 PDAs and their variants, such as adenosquamous carcinomas and undifferentiated carcinomas with and without osteoclast-like giant cells. They reported that 38 (8%) of those tumors had cystic features, and classified them into four broad categories: PDA with large-gland features, PDA with intratumoral degenerative cystic changes, pancreatic ductal adenocarcinoma with retention cysts, and pancreatic ductal adenocarcinoma with attached pseudocysts. The largest group (63%) in their series represented PDAs with a neoplastic component, termed the large-gland type. Most of those pancreatic neoplasms contained multiple cystic structures including intratumoral cysts with diameters ranging from 0.4 to 1.8 cm (not exceeding 2.0 cm). Histologically, the cysts were lined by atypical cuboidal to flat epithelial cells, occasionally forming papillary projections. The epithelial cells lining the cystic structures were confirmed by immunohistochemistry to express CEA and/or MUC1, suggesting that these cystic structures retained malignant

features. Another marker that was expressed in about 60% of the cases was p53. The second largest group in their series was PDA with degenerative cystic change due to extensive central tumor necrosis. Most of the tumor cells in this group showed a high proliferation index and were classified as undifferentiated carcinomas. The third group was PDA with unilocular retention cysts located outside the tumor, lined by flat ductal epithelial cells without atypia. The epithelium of the retention cysts lacked immunoreactivity for MUC1, MUC2, and p53. Finally, the fourth and least frequent type was PDA with attached pseudocysts in which the cystic lesions were filled with necrotic tissue, hemorrhagic material and turbid fluid, no epithelial lining being detectable.

In the present study, we examined the clinicopathologic and immunohistochemical features of 7 PDAs with a MLC structure that did not wholly fulfill the above criteria of Kosmahl *et al.* for the classification of cystic PDAs. The following features of our MLC-type PDAs are considered as characteristic: (1) the presence of large cystic lesions (mean size, 3.7 cm); (2) the presence of multiple (more than 5) cystic structures around the tumors and numerous intratumoral cysts; (3) the presence of atypia varying from none to high-grade dysplasia in the cyst-lining epithelial cells; (4) lack of expression of MUC 1, 2, and 6, and only focal expression of MUC5AC in the cyst-lining epithelial

cells; (5) strong expression of maspin, CEA and p53 in both tumor cells in the solid area and the cyst-lining epithelial cells; (6) a high proliferation index based on Ki-67 immunostaining (Ki-67 labeling index) in both tumor cells in the solid area and the cyst-lining epithelial cells ; (7) analysis of the *KRAS* demonstrated mutations involving the codon 12 in 6 out of 7 cases (86%).

In the classification of PDA with cystic features proposed by Kosmahl *et al*., MLC appears to bear some resemblance to the large-gland type, especially in lesions with multiple cysts together with intratumoral cysts, and showing positive staining for CEA and p53 in both the tumor cells and cyst-lining cells.[2] However, the size of the cystic lesions and MUC immunoreactivity differed between the MLC type and the large-gland type. The cystic structures in the MLC type, exceeding 2.0 cm in maximum diameter, were apparently larger than those of the large-gland type, and were mostly MUC series-negative, whereas the large-gland type were generally positive, especially for MUC1, MUC5AC, and MUC6. Moreover, the cyst-lining epithelial cells in the MLC type, whose atypia varied from none to high-grade dysplasia, were also different from those of the large-gland type, which consists of wholly neoplastic cells and never contains normal epithelial cells.

Other entities that have to be considered in the differential diagnosis of MLC include

IPMN and MCN, both of which may have associated invasive carcinomas. IPMN is an intraductal, grossly visible epithelial neoplasm of mucin-producing cells, arising in the main pancreatic duct or its branches.[1,4,13-18] The neoplastic epithelia of IPMN form mostly papillary structures, and show various degrees of mucin secretion, duct dilatation (cyst formation), and variable degrees of dysplasia.[1,4,14-18] Immunohistochemical studies of the MUC protein series are essential for diagnosis of IPMN, and in particular, MUC5AC is expressed in all morphological subtypes of IPMN.[1,5,15] Approximately 30% of resected IPMNs have associated invasive carcinomas, which can be divided into two distinct types: invasive mucinous adenocarcinoma and invasive tubular (conventional ductal) adenocarcinoma.[1,16,17,19] Mucinous adenocarcinoma is usually associated with intestinal-type IPMN.[1] Tubular adenocarcinoma associated with IPMN is morphologically indistinguishable from the usual form of conventional ductal adenocarcinoma, and generally arises in either gastric- or pancreatobiliary-type IPMNs.[1] Intestinal-type IPMN consistently expresses the intestinal differentiation marker MUC2, in addition to MUC5AC, but does not express MUC1, whereas pancreatobiliary-type IPMN expresses MUC1 and MUC5AC, but not MUC2.[1,5,16] The immunohistochemical expression of the MUC series in MLC-type PDA was not consistent with that in IPMN, as we have stated in the Results section.

MCN of the pancreas presents as a well circumscribed unilocular or multilocular cystic tumor, and most cases are localized in the body and tail of the pancreas.[1,3,4,15,17] The cysts do not communicate with the main pancreatic duct[1]. Approximately one third of MCNs have an associated invasive carcinoma that resembles infiltrating ductal adenocarcinoma, forming tubular and duct-like structures;[1,4,15] accordingly, MCN with an associated invasive carcinoma might be considered as part of the differential diagnosis of MLC-type PDA. However, the ovarian-like stroma underlying the cyst epithelium, a defining feature of MCN,[1,4,15,17] is not evident in MLC-type PDA. Moreover, as shown in the summary of ERP or MRCP findings of MLC-type PDAs, the communication between main pancreatic duct and cysts was recognized in some cases, which is not consistent with the nature of MCN[1].

According to the results of *KRAS* mutation analysis, the MLC-type PDAs appeared to have a common biology with similar molecular alterations to conventional ductal adenocarcinomas. On the other hand, according to the prognostic data of MLC-type and other cystic-type PDAs, clinical behavior of PDAs with cystic structures appears to be better than that of non-cystic conventional type PDAs.[20] Possibly, expression of the tumor suppressor genes coded protein such as SMAD4/DPC4 might be also preserved in PDAs with cystic structures, as was reported in most noninvasive IPMNs (cystic

neoplasms with low malignant potential).[1,21]

The precise mechanism responsible for the development of MLC is still unclear. As a potential explanation for this unique lesion, we hypothesize that it represents a PDA with a mixture of neoplastic glandular ectasia and retention cysts. The wide spectrum of atypia shown by the epithelial cells of the cyst wall of MLC-type PDA, ranging from none to high-grade dysplasia, might represent displacement of the normal epithelia of retention cysts by neoplastic cells. The epithelial cells of these cysts tended to show a higher grade of dysplasia in close proximity to the solid tumor, whereas in the periphery, lower-grade dysplasia and partially no atypia were evident. Alternatively, *de novo* PanIN occurring in the cyst-lining cells could also be considered, since PanIN occurring in the branch ducts has been widely recognized as the precursor lesion of PDA. This hypothesis could also explain why the MLC lesions lacked expression of MUC1 and MUC2 protein, as is the case for retention cysts.[2] Moreover, there was no significant difference in either overall or disease-free survival between patients with MLC-type PDAs and those with other cystic PDAs. However, the size of the retention cysts and large gland-type cysts rarely exceeds 2.0 cm,[2] and the large cyst size (mean, 3.7 cm) of the MLC type is thus a distinctive characteristic, suggesting that the MLC type could represent a novel form of cystic PDA.

In general, when encountering any cystic neoplasm of the pancreas with MLC structures using preoperative radiographic imaging, branch duct-type IPMNs or MCNs, which are usually slow-growing and show lower malignant potential, tend to be considered first in the differential diagnosis. However, it should be borne in mind that PDAs, which are associated with very poor survival and mortality rates, can form cystic lesions similar to those of IPMNs and MCNs, which are associated with better prognosis.

In summary, we have described a series of cystic PDAs, termed the “MLC” type, that show distinctive and previously unreported morphologic and immunohistochemical features. These findings suggest that MLC lesions can probably be considered as PDAs with a mixture of neoplastic glandular ectasia and retention cysts, but that MLC-type PDA might also represent a new entity of cystic PDA exhibiting extraordinarily large cysts.

Disclosure/conflict of interest statement

None of the authors have any conflicts of interest to disclose.

References

1. Bosman FT, Carneiro F, Hruban RH, et al. WHO Classification of Tumors of the Digestive System. IARC Press: Lyon, 2010.
2. Kosmahl M, Pauser U, Anlauf M, Klöppel G. Pancreatic ductal adenocarcinomas with cystic features: neither rare nor uniform. *Mod Pathol* 2005; 18(9):1157-64.
3. Donahue TR, Hines OJ, Farrell JJ, Tomlinson JS, Eibl G, Reber HA. Cystic neoplasms of the pancreas: results of 114 cases. *Pancreas* 2010; 39(8):1271-6.
4. Klöppel G, Kosmahl M. Cystic lesions and neoplasms of the pancreas. The features are becoming clearer. *Pancreatology* 2001; 1(6):648-55.
5. Kosmahl M, Pauser U, Peters K, Sipos B, Luttges J, Kremer B et al. Cystic neoplasms of the pancreas and tumor-like lesions with cystic features: a review of 418 cases and a classification proposal. *Virchows Arch* 2004; 445(2):168-78.
6. Molvar C, Kayhan A, Lakadamyali H, Oto A. Non-neoplastic cystic lesions of pancreas: a practical clinical, histologic, and radiologic approach. *Curr Probl Diagn Radiol* 2011; 40(4):141-8.
7. Fukushima Y, Yanaka S, Murakami K, Abe Y, Koshizaka T, Hara H et al. [High-throughput screening method of KRAS mutations at codons 12 and 13 in

formalin-fixed paraffin-embedded tissue specimens of metastatic colorectal cancer]. *Gan To Kagaku Ryoho* 2011; 38(11):1825-35.

8. Eisenhauer EA, Therasse P, Bogaerts J, Schwartz LH, Sargent D, Ford R, et al. New response evaluation criteria in solid tumours: revised RECIST guideline (version 1.1). *Eur J Cancer.* 2009;45(2):228-47.
9. Colombo P, Arizzi C, Roncalli M. Acinar cell cystadenocarcinoma of the pancreas: report of rare case and review of the literature. *Hum Pathol* 2004; 35(12):1568-71.
10. Zamboni G, Terris B, Scarpa A, Kosmahl M, Capelli P, Klimstra DS et al. Acinar cell cystadenoma of the pancreas: a new entity? *Am J Surg Pathol* 2002; 26(6):698-704.
11. Ligneau B, Lombard-Bohas C, Partensky C, Valette PJ, Calender A, Dumortier J et al. Cystic endocrine tumors of the pancreas: clinical, radiologic, and histopathologic features in 13 cases. *Am J Surg Pathol* 2001; 25(6):752-60.
12. Lee JS, Kim HS, Jung JJ, Han SW, Kim YB. Ancient schwannoma of the pancreas mimicking a cystic tumor. *Virchows Arch* 2001; 439(5):697-9.
13. Bagci P, Andea AA, Basturk O, Jang KT, Erbarut I, Adsay V. Large duct type invasive adenocarcinoma of the pancreas with microcystic and papillary patterns: a

potential microscopic mimic of non-invasive ductal neoplasia. *Mod Pathol* 2012; 25(3):439-48.

14. Hruban RH, Takaori K, Klimstra DS, Adsay NV, Albores-Saavedra J, Biankin AV et al. An illustrated consensus on the classification of pancreatic intraepithelial neoplasia and intraductal papillary mucinous neoplasms. *Am J Surg Pathol* 2004; 28(8):977-87.
15. Tanaka M, Chari S, Adsay V, Castillo CF, Falconi M, Shimizu M et al. International consensus guidelines for management of intraductal papillary mucinous neoplasms and mucinous cystic neoplasms of the pancreas. *Pancreatology* 2006; 6(1-2):17-32.
16. Adsay NV, Merati K, Basturk O, Iacobuzio-Donahue C, Levi E, Cheng JD et al. Pathologically and biologically distinct types of epithelium in intraductal papillary mucinous neoplasms: delineation of an “intestinal” pathway of carcinogenesis in the pancreas. *Am J Surg Pathol* 2004; 28(7):839-48.
17. Basturk O, Coban I, Adsay NV. Pancreatic cysts: pathologic classification, differential diagnosis, and clinical implications. *Arch Pathol Lab Med* 2009; 133(3):423-38.

18. Salvia R, Crippa S, Falconi M, Bassi C, Guarise A, Scarpa A et al. Branch-duct intraductal papillary mucinous neoplasms of the pancreas: to operate or not to operate? *Gut* 2007; 56(8):1086-90.

19. Adsay NV, Pierson C, Sarkar F, Abrams J, Weaver D, Conlon K et al. Colloid (mucinous noncystic) carcinoma of the pancreas. *Am J Surg Pathol* 2001; 25(1):26-42.

20. Witkowski ER, Smith JK, Tseng JF. Outcomes following resection of pancreatic cancer. *J Surg Oncol.* 2013;107(1):97-103.

21. Iacobuzio-Donahue CA, Klimstra DS, Adsay NV, Wilentz RE, Argani P, Sohn TA et al. Dpc-4 protein is expressed in virtually all human intraductal papillary mucinous neoplasms of the pancreas: comparison with conventional ductal adenocarcinomas. *Am J Pathol.* 2000;157(3):755-61.

Titles and legends to figures

Figure 1

Representative radiologic features of pancreatic ductal adenocarcinomas (PDAs) with multiple large cystic (MLC) structures (case 6). A, Ultrasonography demonstrates the MLC structure as a hypoechoic, multilocular lesion (arrows). B, Axial enhanced computed tomography shows multiple low-density, relatively well demarcated tumors with a maximum diameter of 3.5 cm in the pancreatic body (arrows). C, Axial T2-weighted magnetic resonance image reveals a homogeneously increased T2 signal (arrows). D, Magnetic resonance cholangiopancreatography shows a multilocular high-signal intensity lesion (arrows) and obstruction of the main pancreatic duct (arrowhead).

Figure 2

Macroscopic images of the cut surface of the surgically resected specimen from case 6. The tumor appears as a firm, tan-white solid mass with intratumoral small cysts (arrows), and multiple large cystic structures at the periphery.

Figure 3

Microscopic images of pancreatic ductal adenocarcinomas with multiple large cystic structures lined by variably atypical epithelial cells. All of them are from the same case. A, A low-magnification image shows some large cystic structures at the periphery of the solid tumor with numerous intratumoral microcysts (hematoxylin and eosin [H&E]; original magnification, x10). B, A high-magnification image of the tumor shows neoplastic microcystic structures embedded in a fibrous and/or desmoplastic stroma (H&E; original magnification, x100). C, A high-magnification image of a large cystic structure shows high-grade dysplastic epithelial cells lining the cyst wall (arrows) (H&E; original magnification, x200). D, A high-magnification image of another large cystic structure shows low-grade dysplastic epithelial cells (arrows) and the cyst is partially lined by apparently normal epithelial cells (arrowhead) (H&E; original magnification, x200).

Figure 4

Immunohistochemical features of pancreatic ductal adenocarcinomas with multiple large cystic structures (original magnification, ×400). Tumor cells in the solid area and the cyst-lining epithelia are negative for MUC1, MUC2, and MUC6, whereas only focal

and weak membranous staining for MUC5AC is evident. Maspin, CEA, and p53 are strongly positive in both tumor cells in the solid part and the cyst-lining epithelial cells (this figure shows only the cyst-lining epithelial cells). The Ki-67 labeling index is high in both tumor cells in the solid part and the cyst-lining epithelial cells (this figure shows only the cyst-lining epithelial cells).

Figure 5

Kaplan-Meier survival curves for patients with pancreatic ductal adenocarcinoma with multiple large cystic structures, and patients with other cystic lesions (cystic lesions other than multiple large cystic structures). X-axis : time in months. Y-axis : cumulative survival.

Table 1. Antibodies Employed for Immunohistochemistry

Antibody	Source	Clone	Dilution
MUC1	Novocastra	NCL-MUC-1	1:100
MUC2	Novocastra	Ccp58	1:20
MUC5AC	Novocastra	CLH2	1:50
MUC6	Novocastra	CLH5	1:50
Maspin	BD Pharmingen	G167-70	1:1000
CEA	Nichirei	ZC23	RTU
p53	Novocastra	DO-7	1:200
Ki-67	Dako	MIB-1	1:200

Table 2. Clinicopathologic Features of Pancreatic Ductal Adenocarcinomas with Multiple Large Cystic Structures

Case	Age (y)	Sex	Symptom	Elevation of serum tumor markers[a] (U/ml)	Location	Operation	Tumor size (cm)[b]	Cyst size (cm)[c]	Mitotic Count / 10 HPF	*KRAS* mutation (location)	Response to postoperative chemotherapy[d] (Regimen)	Prognosis
1	79	M	Free	WNL	B	DP	2.7	4.5	2	+ (codon 12 ; GAT)	PD (GEM+S-1)	Recurrence (Para Ao L/N) at 10 mo DD (60 mo)
2	51	M	Free	WNL	B	DP-CAR	3.0	2.0	0	-	No chemotherapy	AN (13 mo)
3	68	F	Free	CA19-9 (141.5)	BT	DP-CAR	8.0	3.5	0	+ (codon 12 ; CGT)	PD (GEM)	Recurrence (peritoneum) at 11 mo DD (34 mo)
4	56	M	Epigastric pain	CA19-9 (93.2)	B	DP-CAR	4.0	3.0	1	+ (codon 12 ; GAT)	PD (GEM)	Recurrence (lung) at 31 mo Alive (54 mo)
5	68	M	Diarrhea	CEA (24.8)	BT	DP-CAR	5.5	5.0	1	+ (codon 12 ; GAT)	No chemotherapy	Recurrence (peritoneum) at 6 mo DD (8 mo)
6	76	F	Back pain	CA19-9 (103.4)	BT	DP	8.0	3.5	3	+ (codon 12 ; GAT)	No chemotherapy	AN (7 mo)
7	64	M	Free	CA19-9 (415)	BT	DP	2.5	4.5	1	+ (codon 12 ; GAT)	NE (GEM)	AN (4 mo)

[a] Serum tumor markers (CA19-9 and CEA) were measured preoperatively. [b] Tumor size is represented by the maximum width of the neoplasm.
[c] Cyst size is represented by the maximum width of the cystic structures. [d] Response to chemotherapy was evaluated by the criteria based on Revised RECIST guideline (version 1.1).
AN indicates patient is alive with no evidence of disease ; B, body ; BT ; body and tail ; CA19-9, carbohydrate antigen 19-9 (range:0-37 U/ml) ; CEA, Carcinoembryonic antigen (range:1.0-6.5 ng/ml) ; DD, died from disease; DP, distal pancreatectomy ; DP-CAR, distal pancreatectomy with en bloc celiac axis resection ; F, female ; GEM, gemcitabine ; HPF, high-power field ; M, male ; mo, month ; NE, not evaluable ; Para Ao L/N, Lymph nodes around the abdominal aorta ; PD, progress disease ; WNL, within normal limits.

Table 3. Summary of the ERP or MRCP Findings of Pancreatic Ductal Adenocarcinomas with Multiple Large Cystic Structures

Case	ERP or MRCP findings	
	Configuration of pancreatic duct	**Communication between pancreatic duct and cysts (+ / -)**
1	MPD is diffusely dilated with sudden obstruction at the level of the Pb	+
2	MPD is irregularly dilated with sudden obstruction at the level of the Pb	+
3	N/A[a]	N/A[a]
4	MPD is either not visualized clearly or presents a smooth narrowing	+
5	N/A[a]	N/A[a]
6	MPD is diffusely dilated with sudden obstruction at the level of the Pb	-
7	MPD is diffusely dilated with sudden obstruction at the level of the Pt	-

[a] N/A, there are no available imaging files of ERP or MRCP for cases 3 and 5.

ERP, endoscopic retrograde pancreatography; MPD, main pancreatic duct ; MRCP, magnetic resonance cholangiopancreatography ; Pb, pancreatic body ; Pt, pancreatic tail

Table 4. Summary of immunohistochemical features

Pancreatic Ductal Adenocarcinomas with Multiple Large Cystic Structures								
Case	**MUC1 (Cyst/T)**	**MUC2 (Cyst/T)**	**MUC5AC (Cyst/T)**	**MUC6 (Cyst/T)**	**Maspin (Cyst/T)**	**CEA (Cyst/T)**	**p53 (Cyst/T)**	**Ki-67 LI (%) (Cyst/T)**
1	-/Focal +	-/-	-/-	-/-	+/+	+/+	+/ +	30.7 / 35.6
2	-/Focal +	-/-	Focal +/Focal +	-/-	+/+	+/+	+/ +	24.0 / 27.3
3	-/+	-/-	-/-	-/-	+/+	+/+	-/Focal +	17.7 / 21.6
4	-/Focal +	-/-	Focal +/Focal +	-/-	+/+	+/+	+/+	39.7 / 28.3
5	-/Focal +	-/-	-/Focal +	-/-	+/+	+/+	Focal +/Focal +	23.3 / 36.0
6	-/Focal +	-/-	Focal +/Focal +	Focal +/-	+/+	+/+	+/+	23.3 / 28.3
7	-/Focal +	-/-	Focal +/Focal +	-/Focal +	+/+	+/+	+/+	34.0 / 28.8
Non-cystic (conventional) Pancreatic Ductal Adenocarcinomas								
Case	**MUC1**	**MUC2**	**MUC5AC**	**MUC6**	**Maspin**	**CEA**	**p53**	**Ki-67 LI (%)**
A	+	-	Focal +	-	+	+	+	35.3
B	+	-	Focal +	Focal +	+	+	Focal +	39.7
C	+	-	Focal +	-	+	+	+	34.0
D	+	Focal +	+	Focal +	+	+	Focal +	29.0
E	+	-	Focal +	-	+	+	+	34.3

Cyst /T, Cystic epithelium/Tumor (solid lesion); LI, labeling index

A
B
C
D

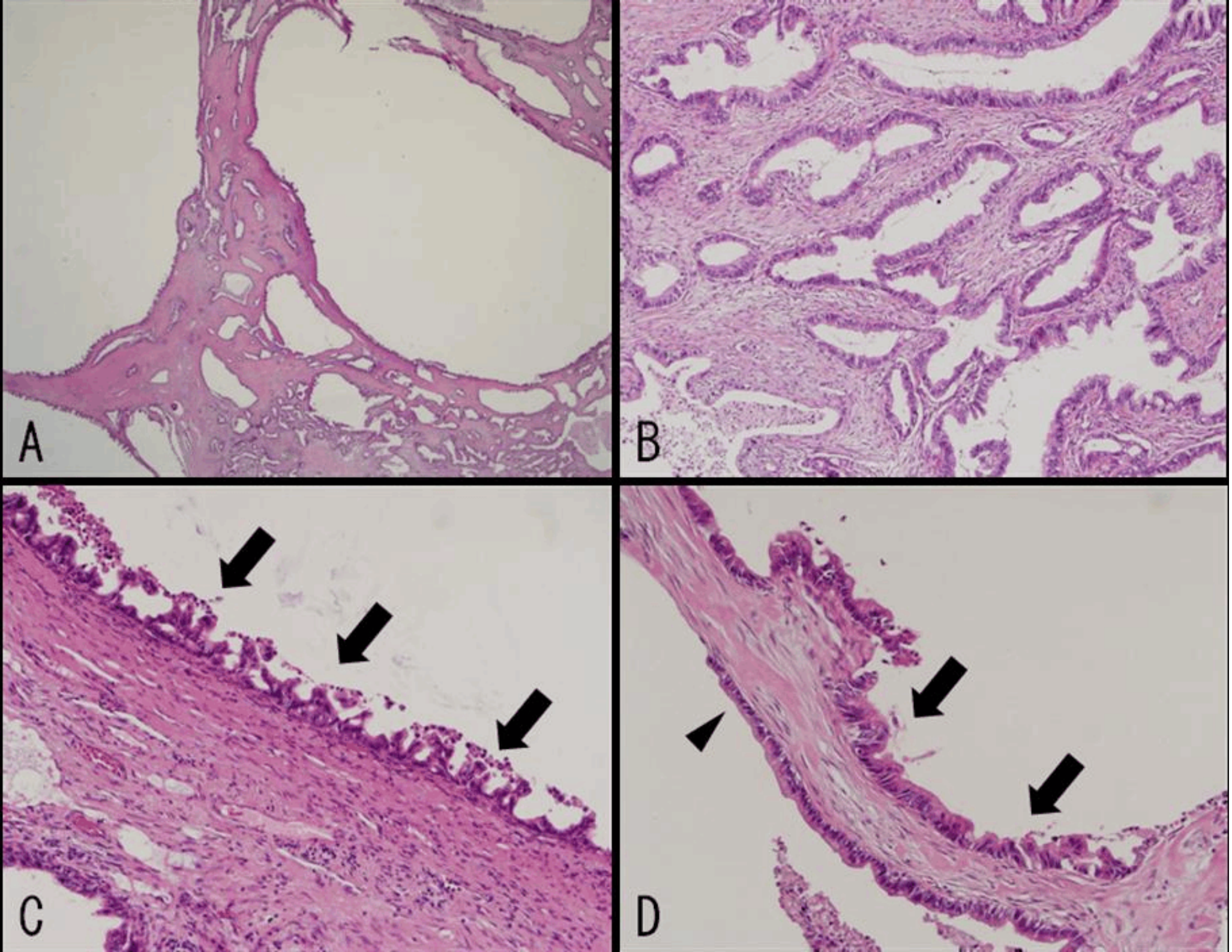
A
B
C
D

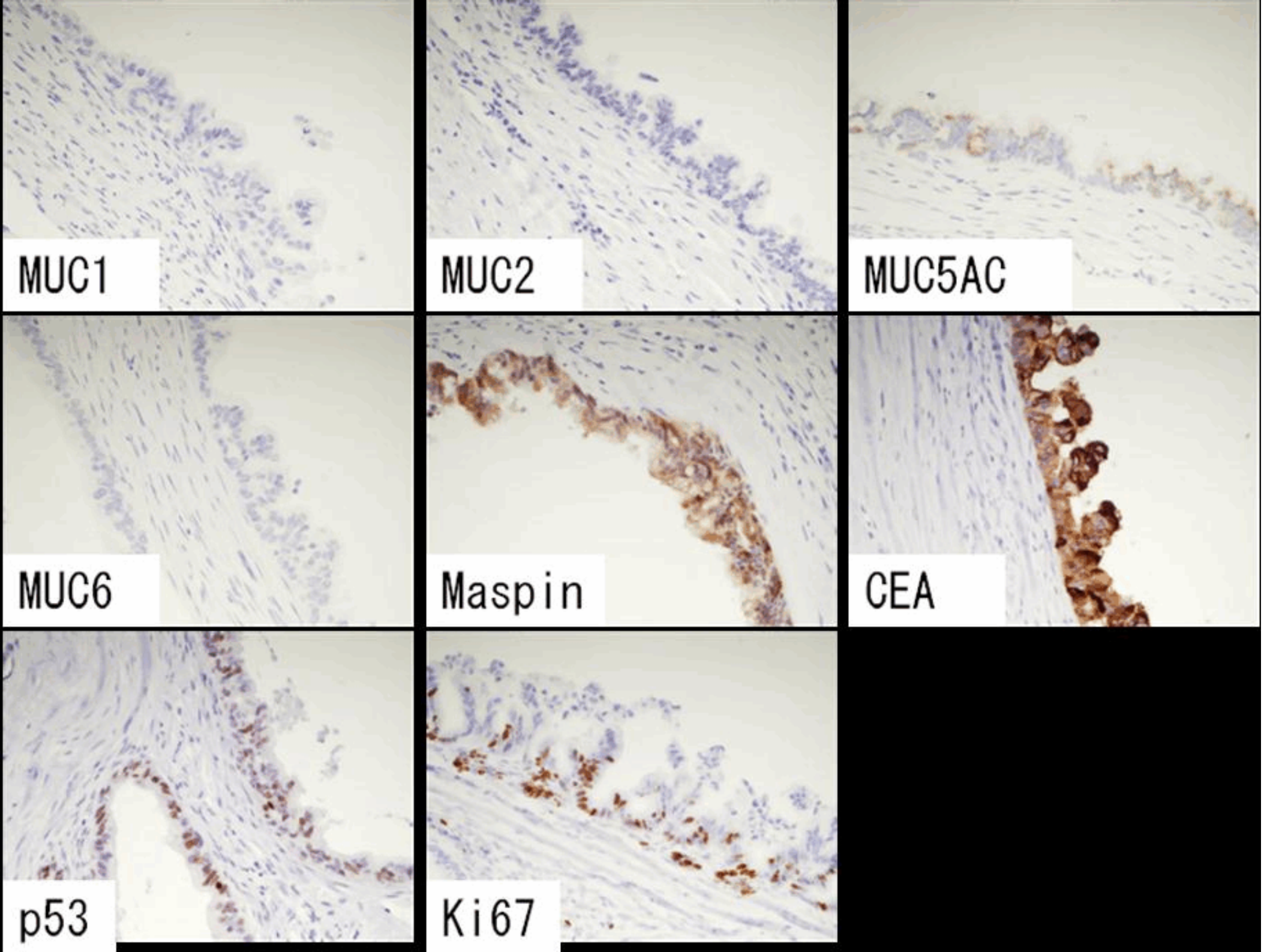
MUC1
MUC2
MUC5AC
MUC6
Maspin
CEA
p53
Ki67

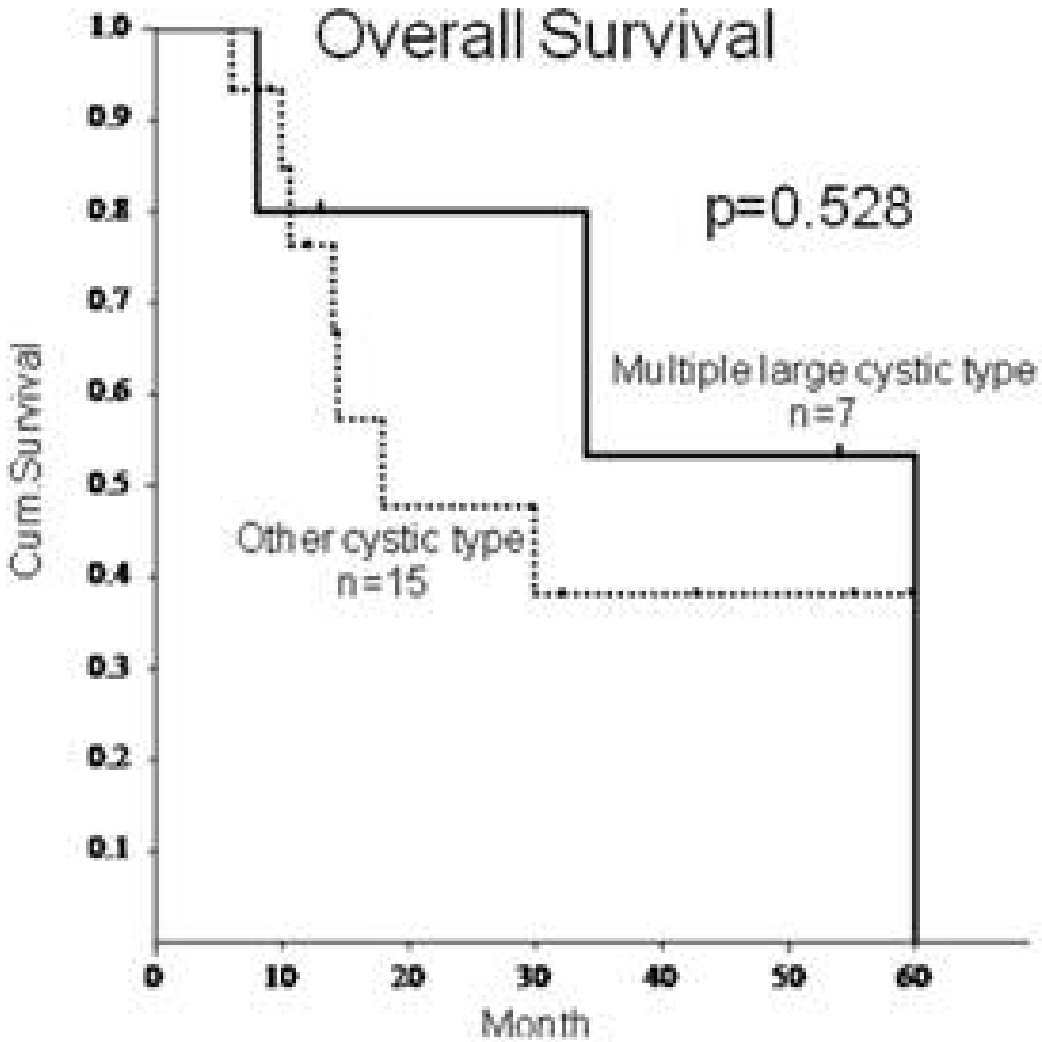
Overall Survival
p=0.528
Multiple large cystic type
n=7
Other cystic type
n=15
Cum Survival
1.0
0.9
0.8
0.7
0.6
0.5
0.4
0.3
0.2
0.1
0
10
20
30
40
50
60
Month

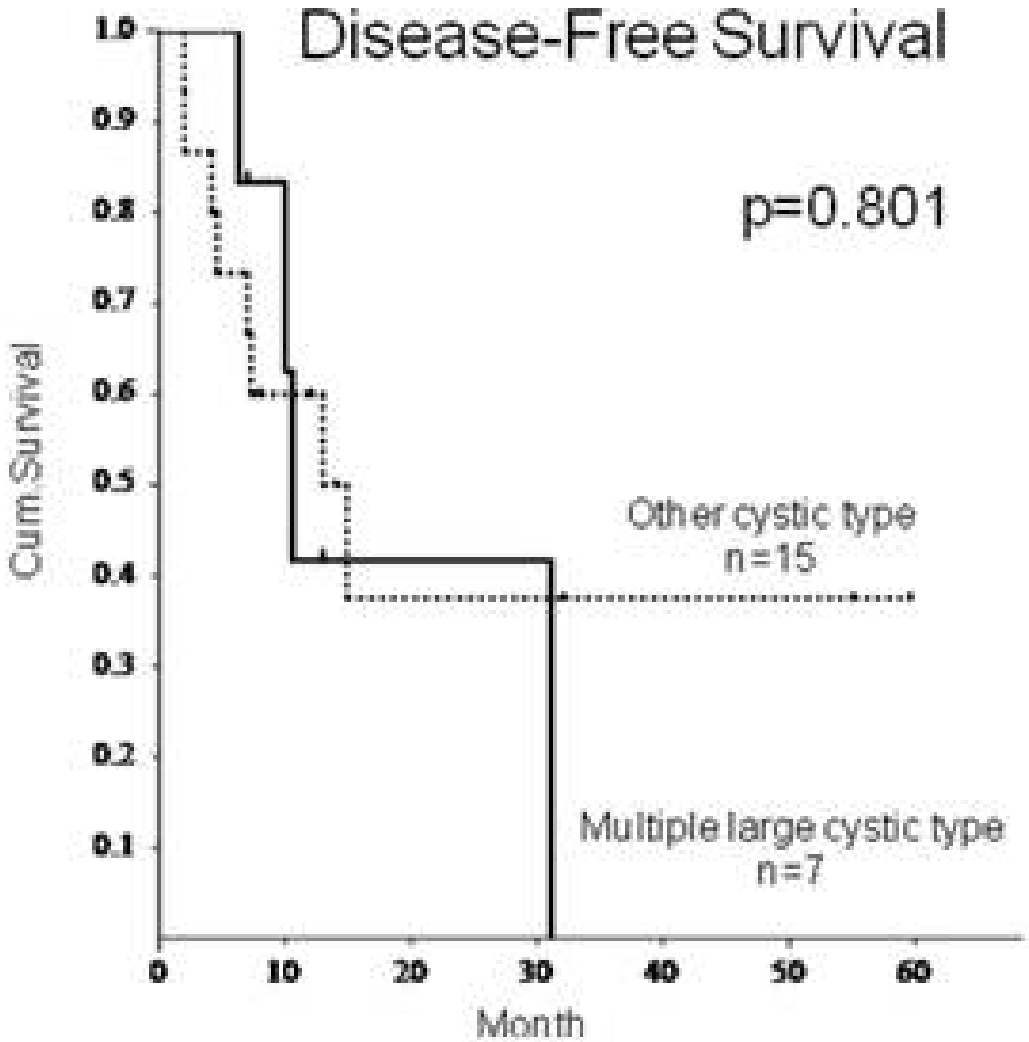
Disease-Free Survival
p=0.801
Other cystic type
n=15
Multiple large cystic type
n=7
Cum Survival
1.0
0.9
0.8
0.7
0.6
0.5
0.4
0.3
0.2
0.1
0
10
20
30
40
50
60
Month