HOKKAIDO UNIVERSITY

| | |
|---|---|
| Title | Simple prediction of right ventricular ejection fraction using tricuspid annular plane systolic excursion in pulmonary hypertension |
| Author(s) | Sato, Takahiro; Tsujino, Ichizo; Oyama-Manabe, Noriko; Ohira, Hiroshi; Ito, Yoichi M.; Sugimori, Hiroyuki; Yamada, Asuka; Takashina, Chisa; Watanabe, Taku; Nishimura, Masaharu |
| Citation | International journal of cardiovascular imaging, 29(8), 1799-1805<br>https://doi.org/10.1007/s10554-013-0286-7 |
| Issue Date | 2013-12 |
| Doc URL | http://hdl.handle.net/2115/57868 |
| Rights | The final publication is available at link.springer.com |
| Type | article (author version) |
| File Information | Int J Cardiovasc Imaging_29(8)_1799-1805.pdf |

Instructions for use

Hokkaido University Collection of Scholarly and Academic Papers : HUSCAP

**Simple prediction of right ventricular ejection fraction using tricuspid annular plane systolic excursion in pulmonary hypertension**

Takahiro Sato, M.D., Ph.D.[a], Ichizo Tsujino, M.D., Ph.D.[a], Noriko Oyama-Manabe, M.D., Ph.D.[b] Hiroshi Ohira, M.D., Ph.D.[a], Yoichi M. Ito, Ph.D.[c], Hiroyuki Sugimori Ph.D.[d], Asuka Yamada, M.D.[a], Chisa Takashina, M.D.[a], Taku Watanabe, M.D., Ph.D.[a], Masaharu Nishimura, M.D., Ph.D.[d]

[a]First Department of Medicine and [b]Department of Diagnostic and Interventional Radiology, Hokkaido University Hospital, [c]Department of Biostatistics, Hokkaido University Graduate School of Medicine, [d]Department of Radiological Technology, Hokkaido University Hospital, [e]First Department of Medicine, Hokkaido University School of Medicine, Sapporo, Japan

Corresponding author: Ichizo Tsujino M.D., Ph.D.
First Department of Medicine, Hokkaido University Hospital,
North 14, West 5, Kita-ku, Sapporo 060-8648, Japan.
Tel: +81-11-706-5911, FAX: +81-11-706-7899
E-mail: itsujino@med.hokudai.ac.jp

**Abstract**

**Purpose:** The present study examined whether tricuspid annular plane systolic excursion (TAPSE) can simply predict right ventricular ejection fraction (RVEF) in patients with pulmonary hypertension (PH). The TAPSE cut-off value to predict reduced RV EF was also evaluated.

**Methods and results:** The association between TAPSE and cardiac magnetic resonance imaging (CMRI)-derived RVEF was examined in 53 PH patients. The accuracy of the prediction equation to calculate RVEF using TAPSE was also evaluated. In PH patients, TAPSE was strongly correlated with CMRI-derived RVEF in PH patients ($r=0.86$, $p<0.0001$). We then examined the accuracy of the two equations: the original regression equation (RVEF = 2.01 x TAPSE + 0.6) and the simplified prediction equation (RV EF = 2 x TAPSE). Bland-Altman plot showed that the mean difference ± limits of agreement was 0.0 ± 10.6 for the original equation and −0.6 ± 10.6 for the simplified equation. Intraclass correlation coefficient was 0.84 for the original and 0.82 for the simplified equation. Normal RV EF was considered to be ≥ 40% based on the data from 53 matched controls, and the best TAPSE cut-off value to determine reduced RV EF (< 40%) was calculated to be 19.7 mm (sensitivity 88.9%, specificity 84.6%).

**Conclusion**: A simple equation of RV EF = 2 x TAPSE enables easy prediction of RV

EF using TAPSE, an easily measurable M-mode index of echocardiography. TAPSE of 19.7 mm predicts reduced RV EF in PH patients with clinically acceptable sensitivity and specificity.

## Introduction

Pulmonary hypertension (PH) is defined as a mean pulmonary artery pressure (PAP) ≥ 25 mmHg at rest [1]. Elevation of PAP increases right ventricular (RV) pressure-overload, leading to right heart failure and, potentially, premature death. As right heart failure is the direct cause of death in most patients with PH, adequate evaluation of RV function is critical in the management of PH [2,3].

Recent progress of cardiac magnetic resonance (CMR) has enabled accurate calculation of RV ejection fraction (EF), and CMR-derived RV EF is currently considered as the gold-standard for the evaluation of RV systolic function [4]. The clinical value of CMR-derived RV EF has also been reported in PAH; for example, CMR-derived RV EF of <35% is considered to be an risk for the poor outcome in PH patients [2]. Meanwhile, the application of CMR-derived RV EF has been hampered by the limited availability of the imaging facility and the need for dedicated software and expertise. Accordingly, simple assessment of RV systolic function by more widely applicable modalities has been warranted.

Tricuspid annular plane systolic excursion (TAPSE) is a measurement of M-mode echocardiography that reflects longitudinal contraction of the right ventricle [5]. Unlike left ventricle, myocardial fibers project longitudinally rather than

circumferentially in right ventricle, and TAPSE is used as a simple echocardiographic index of RV systolic function. Also, prior publications including ours have reported close correlations between TAPSE and RV EF [6-9]. However, few studies have focused on the ability of TAPSE for the mathematical prediction of RV EF. This ability is clinically important because it would be valuable if RV EF, an emerging therapeutic target in the management of PH, can be simply and precisely predicted by a easily applicable modality such as echocardiography.

We have recently reported a close correlation between TAPSE and CMR-derived RV EF (CMR-derived RV EF = 2.03 x TAPSE - 0.93) in 37 patients with PH [8]. In this study, however, we did not examine the results from a standpoint that CMR-derived RV EF can be mathematically predicted by TAPSE.

In the present study, we aimed to calculate a regression equation for the prediction of RV EF using TAPSE in a larger PH population than in our previous study. The accuracy and the precision of the equation were validated by Bland Altman analysis and intraclass correlation coefficient (ICC). We also measured TAPSE in PH patients and matched controls, and sought to define the TAPSE cut-off value that predicts reduced RV EF in PH patients.

## Methods

*Subjects*

Patients with PH were prospectively enrolled between April 2010 and May 2012. Entry criteria were a resting mean PAP of ≥25 mmHg and pulmonary wedge pressure of ≤15 mmHg, as evaluated by right heart catheterization (RHC). Exclusion criteria were: 1) inability to obtain/analyze CMR or echocardiography images for any reason, 2) comorbid left heart disease that might have affected RV geometry and function, and 3) signs/symptoms indicative of unstable PH. All enrollees underwent echocardiography, CMR imaging (CMRI), and RHC within 1 week, during which they were clinically stable. Age- and gender-matched subjects who did not have cardiac or respiratory disease were recruited as controls.

*Echocardiography*

Echocardiograms were obtained using Vivid q (GE Healthcare, Milwaukee, WI, USA) and the images were analyzed off-line after the procedure in the same manner in our previous report [8]. In short, 2-dimensional parasternal and apical views were used to obtain left ventricular (LV) and left atrial diameters. For the measurement of TAPSE, we adopted the method recommended in the guidelines from the American Society of

Echocardiography [10,11]. Briefly, the M-mode cursor was oriented to the junction of the tricuspid valve plane with the RV free wall, and the total displacement of the tricuspid annulus from end-diastole to end-systole was measured.

Image acquisition and analysis were performed by a single experienced cardiologist who was unaware of the CMR measurements (T.S.). The reproducibility of the measurement of TAPSE was shown to be high by both Bland-Altman plot and ICC (≥0.90) in our previous publication[8].

*Cardiac magnetic resonance*

CMRI studies were performed on a 1.5-Tesla Philips Achieva MRI system (Philips Medical Systems, Best, The Netherlands) with Master gradients (maximum gradient amplitude 33 mT/m, maximum slew rate 100 mT/m/ms). Imaging was performed with subjects in the supine position using a five-element cardiac phased-array coil with breath-holding in expiration, and with a vector-cardiographic method for ECG-gating. Localizing scans were followed by breath-hold cine imaging in the axial orientation. From the coronal localizing images that demonstrated gross cardiac anatomy, a transverse stack of slices was planned to cover the heart from a level just below the diaphragm to the bronchial bifurcation, covering the entire heart in

diastole. A total of 12 axial slices were acquired using an SSFP pulse sequence (TR=2.8 ms, TE=1.4 ms, flip angle=60, acquisition matrix=192 × 256, field of view=380 mm, slice thickness=10 mm, 0 mm inter-slice gap, 20 phases/cardiac cycle).

CMR images were analyzed using commercially available analysis software (Extended MR Work Space: ver. 2.6.3, Philips Medical Systems, Amsterdam, The Netherlands). In the axial data sets, the endocardial contours of the right ventricle were manually traced, starting at the most apical slice and finishing with the uppermost slice. RV and LV end-diastolic volume (EDV) and end-systolic volumes (ESV) were computed. RV and LV stroke volume (SV) and ejection fraction (EF) were calculated as SV = EDV − ESV and EF = SV / EDV × 100%, respectively. CMR image analysis was performed by a single experienced radiologist who was unaware of the results of echocardiographic evaluations (N.M.).

*Statistical analysis*

The correlation between TAPSE and CMRI-derived RVEF was examined using Pearson's correlation coefficient. We then calculated the regression equation by which RV EF is represented by TAPSE and also simplified the original equation so that it can be easily applicable in the clinical setting. The accuracy and the precision of

original and simplified equations were validated using Bland-Altman analysis and ICC.

To obtain the cut-off TAPSE value indicating reduced RV EF in PH patients, we determined both the lower limit of the normal range and mean – 2SD of CMRI-derived RV EF of control subjects. We then used receiver operating characteristic (ROC) curve analysis to calculate the cut-off value of TAPSE that distinguishes between PH patients with and without RV EF reduction. The suitability of the TAPSE values that are currently used in the guidelines, i.e., 20 and 15 mm[1], were also evaluated by calculating their sensitivity, specificity, positive predictive value, and negative predictive value for the prediction of preserved or reduced RV EF.

The correlation between TAPSE and mean PAP was also evaluated by Pearson's correlation coefficient.

All statistical analyses were performed using JMP® Version 10 (SAS Institute Inc, Cary, NC, USA). p values less than 0.05 were considered statistically significant. Results are expressed as mean ± standard deviation (SD).

The present study was approved by the ethics committee of the Hokkaido University Graduate School of Medicine, and written informed consent was obtained from all participants.

## Results

A total of 53 PH patients and 53 age- and gender-matched controls (male/female 29/24, age 51±10 yr) were enrolled. Demographics of the 53 PH patients are summarized in table 1. Images for the measurement of TAPSE were obtained from all participants. Representative images from a healthy control and from a PH patient are presented in Figure 1A and 1B respectively. Echocardiography and CMRI measurements in PH patients and controls are shown in table 2.

In the 53 PH patients, there was a significant correlation between TAPSE and CMRI-derived RVEF ($r = 0.86$, $p < 0.0001$) (Fig. 2). The regression equation between the two variables was RVEF=2.01 x TAPSE + 0.6. This original equation was simplified to RV EF = 2 x TAPSE, and the accuracy and the precision of the original and simplified equations were evaluated. In the Bland-Altman analysis, the difference between 2.01 x TAPSE + 0.6 and CMRI-derived RV EF was 0.0 ± 10.6 (Fig. 3A), and the difference between 2 x TAPSE and CMRI-derived RV EF was −0.6 ± 10.6 (Fig. 3B). The Bland-Altman range encompassing 4 SD was 21.2 for both original and simplified equations. ICC between CMRI-derived RV EF and 2.01 x TAPSE + 0.6 was 0.84, and that between CMRI-derived RV EF and 2 x TAPSE was 0.82.

CMRI-derived RV EF in the control subjects was 53.2 ± 6.8% (SD) (Fig. 4).

Based on the minimum value (40.5%) and the mean – 2SD (39.6%) in the control subjects, the lower limit of normal RV EF was considered to be 40%**.** Receiver operating characteristic curve analysis showed that the best cut-off TAPSE value for the prediction of reduced RV EF (< 40%) was 19.7 mm (Fig. 5; AUC  0.89, sensitivity 84.6%, specificity 88.9%, positive predictive value 88%, and negative predictive value 85.7%). The sensitivity, specificity, positive predictive value, and negative predictive value of TAPSE ≥ 20 mm in predicting preserved RV EF (≥ 40%) were 80%, 93%, 72.7%, and 95.2%, respectively; and those of TAPSE ≤ 15 mm in predicting reduced RV EF (< 30%) were 86.7%, 80%, 76.9%, and 88.8%, respectively.

There was no significant correlation between TAPSE and mean PAP (p=0.21).

**Discussion**

The present study demonstrated that TAPSE is strongly correlated with CMRI-derived RV EF (r=0.86, p<0.0001) in PH patients, and that CMRI-derived RV EF can be calculated by a regression equation: RV EF = 2.01 x TAPSE + 0.6 and also by a simplified equation of RV EF = 2 x TAPSE, with clinically acceptable accuracy and precision. Further, TAPSE of 19.7 mm was shown to be a reliable cut-off value in predicting reduced RV EF (< 40%), with a sensitivity of 84.6% and specificity of

88.9%.

In our previous report, we examined the accuracy of five echocardiographic indices of RV systolic function and found that the five indices, particularly TAPSE, had acceptable accuracy in PH[8]. In the present study, we confirmed that TAPSE is strongly correlated with CMRI-derived RV EF in an expanded cohort of PH patients (n=53).

In the present study, we also examined the accuracy and precision of the simplified prediction equation: RV EF = 2 x TAPSE, using Bland-Altman analysis and ICC. The difference between the means of CMRI-derived RV EF and 2 x TAPSE was small (−0.6), suggesting that TAPSE x 2 predicts RV EF without overt overestimation or underestimation. Also, ICC between CMRI-derived RV EF and TAPSE x 2 was 0.82, indicating high agreement between the two variables in PH patients either with reduced or preserved RV EF.

CMRI allows for observer independent evaluation of RV morphology and function, and has been used as the gold standard in prior publications [2,12-14]. However, it requires a dedicated program and expertise, limiting its widespread use. In contrast, echocardiography is a convenient and repeatedly accessible tool for the evaluation of right ventricle. We believe the present and our previous studies indicate a

high clinical relevance of echocardiography in the evaluation of right heart morphology and function in PH [8].

In the current guidelines for the management of PH, TAPSE greater than 20 mm is stated to predict favorable outcome and, conversely, that less than 15 mm is stated to indicate poor outcome [1]. Moreover, in a recent echocardiographic study, TAPSE less than 15 mm was associated with poor prognosis in patients with idiopathic pulmonary arterial hypertension [15]. The present study seems to validate the clinical relevance of these cut-off values. For example, TAPSE ≥ 20 mm indicated preserved RV EF (≥ 40%) based on our prediction equation, with a positive predictive value of 87%. In contrast, TAPSE ≤ 15 mm indicated noticeably reduced RV EF (≤ 30%) based on our prediction equation and also predicted reduced RV EF (< 40%) with a positive predictive value of 100%. We thus believe that categorizing PH patients by TAPSE ≥ 20 mm and < 15 mm is clinically relevant because these cut-off values discriminate between PH patients with preserved or reduced RV systolic function with high positive predictive values.

Interestingly, there was no significant correlation between TAPSE and mean PAP in the present study. This suggests that TAPSE is a suitable indicator of RV systolic function but not of the degree of PH itself. In fact, this result may be deemed as

reasonable considering the Frank-Starling's law which can explain the nonlinear association between PAP and RV systolic function [16].

There are several limitations that merit discussion in the present study. First, it should be noted that the present study included PH patients with diverse etiologies and varying treatment regimens, which might have significantly affected the results. Larger studies with controlled enrollment of PH patients are needed to clarify this issue. Second, we carefully selected matched control subjects; however, normal RV EF range and right-heart response to PH may vary with different CMRI protocol or among different ethnicities [13,14]. Thus, the results of the present study need to be extrapolated with caution when applied to non-Asian populations. Third, echocardiography-derived RV EF was not examined in the present study. At present, however, echocardiography-derived RV EF can be calculated by 3 dimensional echocardiography which requires dedicated equipments, software and expertise similar to MRI [17]. Thus, the scope of the present study focusing on TAPSE, a simple parameter of the 2 dimensional echocardiography, can be justified from a practical viewpoint. Lastly, the difference between MRI-derived RV EF and 2 x TAPSE may be clinically significant despite their close correlation. The clinical relevance of the prediction equations presented in the presented study needs further evaluations.

In conclusion, the present study proposed a simple equation that enables prediction of RV EF using TAPSE, an easily measurable M-mode index of echocardiography. Also, TAPSE of 19.7 mm predicts reduced RV EF in PH patients with clinically acceptable sensitivity and specificity. Further, the present study indicated that TAPSE ≥ 20 mm provides a good positive predictive value for a preserved RV EF and that TAPSE ≤ 15 mm have a 100% specificity for a reduced RV EF in PH patients.

**Figure legends**

**Figure 1. Representative echocardiographic images for the measurement of TAPSE**

A: An apical 4-chamber view (left) and an M-mode view (right) of a healthy control. TAPSE was 28.4 mm. B: An apical 4-chamber view (left) of a PH patient shows enlarged RA and RV. TAPSE was decreased to 6.3 mm (M-mode view, right)

TAPSE: tricuspid annular plane systolic excursion, RA: right atrium, LA: left atrium, RV: right ventricle, LV: left ventricle,

**Figure 2. Correlation between TAPSE and CMRI-derived RV EF**

TAPSE, tricuspid annular plane systolic excursion; CMRI, cardiac magnetic resonance imaging; RV right ventricular; EF, ejection fraction

**Figure 3. Bland-Altman analysis between CMRI-derived RV EF and either the original equation (RV EF = 2.01 x TAPSE + 0.6) or the simplified equation (RV EF = 2 x TAPSE)**

A: The difference between CMRI-derived RV EF and the original equation (RV EF = 2.01 x TAPSE + 0.6) was 0.0 ± 10.6 mm (mean difference ± limits of agreement). B: The difference between CMRI-derived RV EF and the simplified equation (CMRI-derived RV EF = 2 x TAPSE) was -0.6 ± 10.6. The Bland-Altman range

encompassing 4 SD was 21.2 for both original and simplified equations.

CMRI, cardiac magnetic resonance imaging; TAPSE, tricuspid annular plane systolic excursion; RV right ventricular; EF, ejection fraction

**Figure 4. CMRI-derived RV EF of PH patients and control subjects**

CMRI-derived RV EF in PH patients was 38.2±10.7%, and that in controls was 53.2 ± 6.8%.

CMRI, cardiac magnetic resonance imaging; RV right ventricular; EF, ejection fraction; PH, pulmonary hypertension

**Figure 5. Receiver operating characteristic curve of the ability of TAPSE x 2 to predict CMRI-derived RV EF**

The best TAPSE cut-off value for the prediction of reduced RV EF (< 40%) was 19.7 mm (area under the curve 0.89, sensitivity 84.6%, specificity 88.9%, positive predictive value 88%, and negative predictive value 85.7%).

TAPSE, tricuspid annular plane systolic excursion; CMRI, cardiac magnetic resonance imaging; RV right ventricular; EF, ejection fraction

## References

1. Galie N, Hoeper MM, Humbert M, Torbicki A, Vachiery JL, Barbera JA, Beghetti M, Corris P, Gaine S, Gibbs JS, Gomez-Sanchez MA, Jondeau G, Klepetko W, Opitz C, Peacock A, Rubin L, Zellweger M, Simonneau G, Guidelines ESCCfP (2009) Guidelines for the diagnosis and treatment of pulmonary hypertension: the Task Force for the Diagnosis and Treatment of Pulmonary Hypertension of the European Society of Cardiology (ESC) and the European Respiratory Society (ERS), endorsed by the International Society of Heart and Lung Transplantation (ISHLT). Eur Heart J 30 (20):2493-2537. doi:10.1093/eurheartj/ehp297

2. van de Veerdonk MC, Kind T, Marcus JT, Mauritz GJ, Heymans MW, Bogaard HJ, Boonstra A, Marques KM, Westerhof N, Vonk-Noordegraaf A (2011) Progressive right ventricular dysfunction in patients with pulmonary arterial hypertension responding to therapy. J Am Coll Cardiol 58 (24):2511-2519. doi:S0735-1097(11)03336-5 [pii] 10.1016/j.jacc.2011.06.068

3. van Wolferen SA, Marcus JT, Boonstra A, Marques KM, Bronzwaer JG, Spreeuwenberg MD, Postmus PE, Vonk-Noordegraaf A (2007) Prognostic value of right ventricular mass, volume, and function in idiopathic pulmonary arterial hypertension. Eur Heart J 28 (10):1250-1257. doi:ehl477 [pii]

10.1093/eurheartj/ehl477

4. McLure LE, Peacock AJ (2009) Cardiac magnetic resonance imaging for the assessment of the heart and pulmonary circulation in pulmonary hypertension. Eur Respir J 33 (6):1454-1466. doi:33/6/1454 [pii]

10.1183/09031936.00139907

5. Kaul S, Tei C, Hopkins JM, Shah PM (1984) Assessment of right ventricular function using two-dimensional echocardiography. Am Heart J 107 (3):526-531

6. Kjaergaard J, Petersen CL, Kjaer A, Schaadt BK, Oh JK, Hassager C (2006) Evaluation of right ventricular volume and function by 2D and 3D echocardiography compared to MRI. Eur J Echocardiogr 7 (6):430-438. doi:S1525-2167(05)00198-8 [pii]

10.1016/j.euje.2005.10.009

7. Ahmad H, Mor-Avi V, Lang RM, Nesser HJ, Weinert L, Tsang W, Steringer-Mascherbauer R, Niel J, Salgo IS, Sugeng L (2012) Assessment of right ventricular function using echocardiographic speckle tracking of the tricuspid annular motion: comparison with cardiac magnetic resonance. Echocardiography 29 (1):19-24. doi:10.1111/j.1540-8175.2011.01519.x

8. Sato T, Tsujino I, Ohira H, Oyama-Manabe N, Yamada A, Ito YM, Goto C, Watanabe T, Sakaue S, Nishimura M (2012) Validation study on the accuracy of

echocardiographic measurements of right ventricular systolic function in pulmonary hypertension. J Am Soc Echocardiogr 25 (3):280-286. doi:S0894-7317(11)00963-1 [pii] 10.1016/j.echo.2011.12.012

9. Speiser U, Hirschberger M, Pilz G, Heer T, Sievers B, Strasser RH, Schoen S (2012) Tricuspid annular plane systolic excursion assessed using MRI for semi-quantification of right ventricular ejection fraction. Br J Radiol 85 (1017):e716-721. doi:10.1259/bjr/50238360

10. Rudski LG, Lai WW, Afilalo J, Hua L, Handschumacher MD, Chandrasekaran K, Solomon SD, Louie EK, Schiller NB (2010) Guidelines for the echocardiographic assessment of the right heart in adults: a report from the American Society of Echocardiography endorsed by the European Association of Echocardiography, a registered branch of the European Society of Cardiology, and the Canadian Society of Echocardiography. J Am Soc Echocardiogr 23 (7):685-713; quiz 786-688. doi:10.1016/j.echo.2010.05.010

11. Bolca O, Gungor B, Gurkan U, Yilmaz H (2012) Assessment of right ventricular systolic function in patients with pulmonary hypertension. J Am Soc Echocardiogr 25 (7):804. doi:10.1016/j.echo.2012.04.019

12. Zafrir N, Zingerman B, Solodky A, Ben-Dayan D, Sagie A, Sulkes J, Mats I,

Kramer MR (2007) Use of noninvasive tools in primary pulmonary hypertension to assess the correlation of right ventricular function with functional capacity and to predict outcome. Int J Cardiovasc Imaging 23 (2):209-215. doi:10.1007/s10554-006-9140-5

13. Grothues F, Moon JC, Bellenger NG, Smith GS, Klein HU, Pennell DJ (2004) Interstudy reproducibility of right ventricular volumes, function, and mass with cardiovascular magnetic resonance. Am Heart J 147 (2):218-223. doi:10.1016/j.ahj.2003.10.005

14. Alfakih K, Reid S, Jones T, Sivananthan M (2004) Assessment of ventricular function and mass by cardiac magnetic resonance imaging. Eur Radiol 14 (10):1813-1822. doi:10.1007/s00330-004-2387-0

15. Ghio S, Klersy C, Magrini G, D'Armini AM, Scelsi L, Raineri C, Pasotti M, Serio A, Campana C, Vigano M (2010) Prognostic relevance of the echocardiographic assessment of right ventricular function in patients with idiopathic pulmonary arterial hypertension. Int J Cardiol 140 (3):272-278. doi:S0167-5273(08)01207-2 [pii] 10.1016/j.ijcard.2008.11.051

16. Katz AM (2002) Ernest Henry Starling, his predecessors, and the "Law of the Heart". Circulation 106 (23):2986-2992

17. Niemann PS, Pinho L, Balbach T, Galuschky C, Blankenhagen M, Silberbach M, Broberg C, Jerosch-Herold M, Sahn DJ (2007) Anatomically oriented right ventricular volume measurements with dynamic three-dimensional echocardiography validated by 3-Tesla magnetic resonance imaging. J Am Coll Cardiol 50 (17):1668-1676. doi:10.1016/j.jacc.2007.07.031

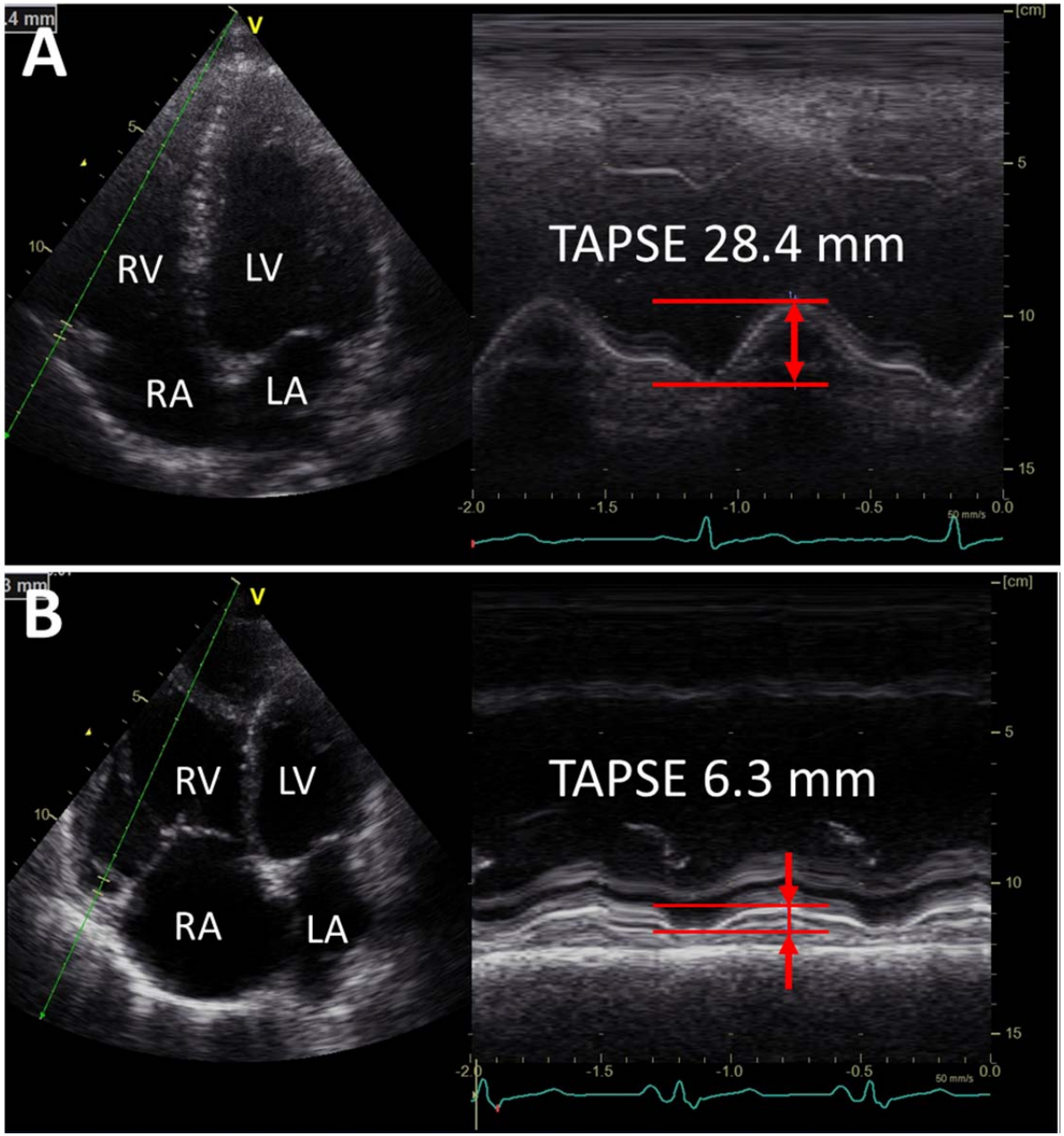
A
RV
LV
RA
LA
TAPSE 28.4 mm
B
RV
LV
RA
LA
TAPSE 6.3 mm

## Figure 2

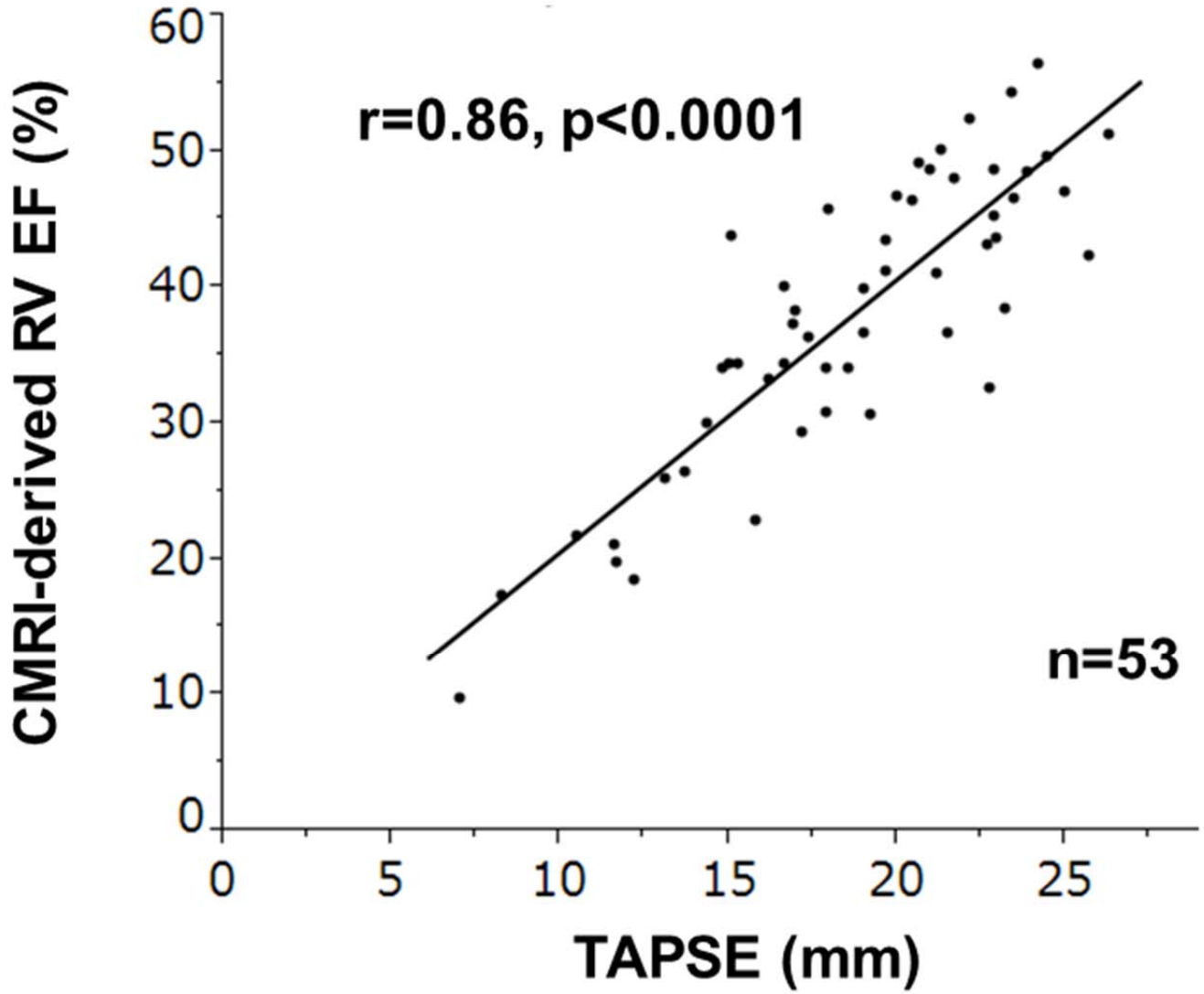
r=0.86, p<0.0001
n=53
CMRI-derived RV EF (%)
TAPSE (mm)
0
10
20
30
40
50
60
0
5
10
15
20
25

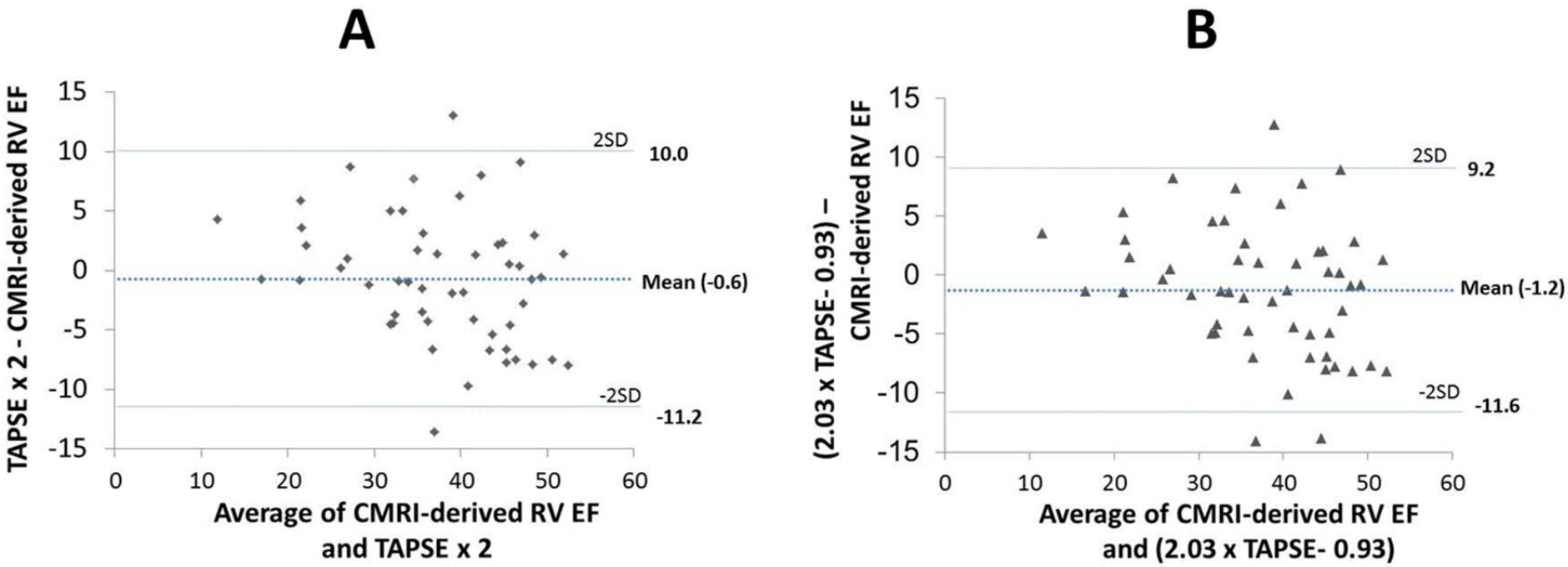
A
TAPSE x 2 - CMRI-derived RV EF
15
10
5
0
-5
-10
-15
2SD
10.0
Mean (-0.6)
-2SD
-11.2
0
10
20
30
40
50
60
Average of CMRI-derived RV EF and TAPSE x 2
B
(2.03 x TAPSE- 0.93) – CMRI-derived RV EF
15
10
5
0
-5
-10
-15
2SD
9.2
Mean (-1.2)
-2SD
-11.6
0
10
20
30
40
50
60
Average of CMRI-derived RV EF and (2.03 x TAPSE- 0.93)

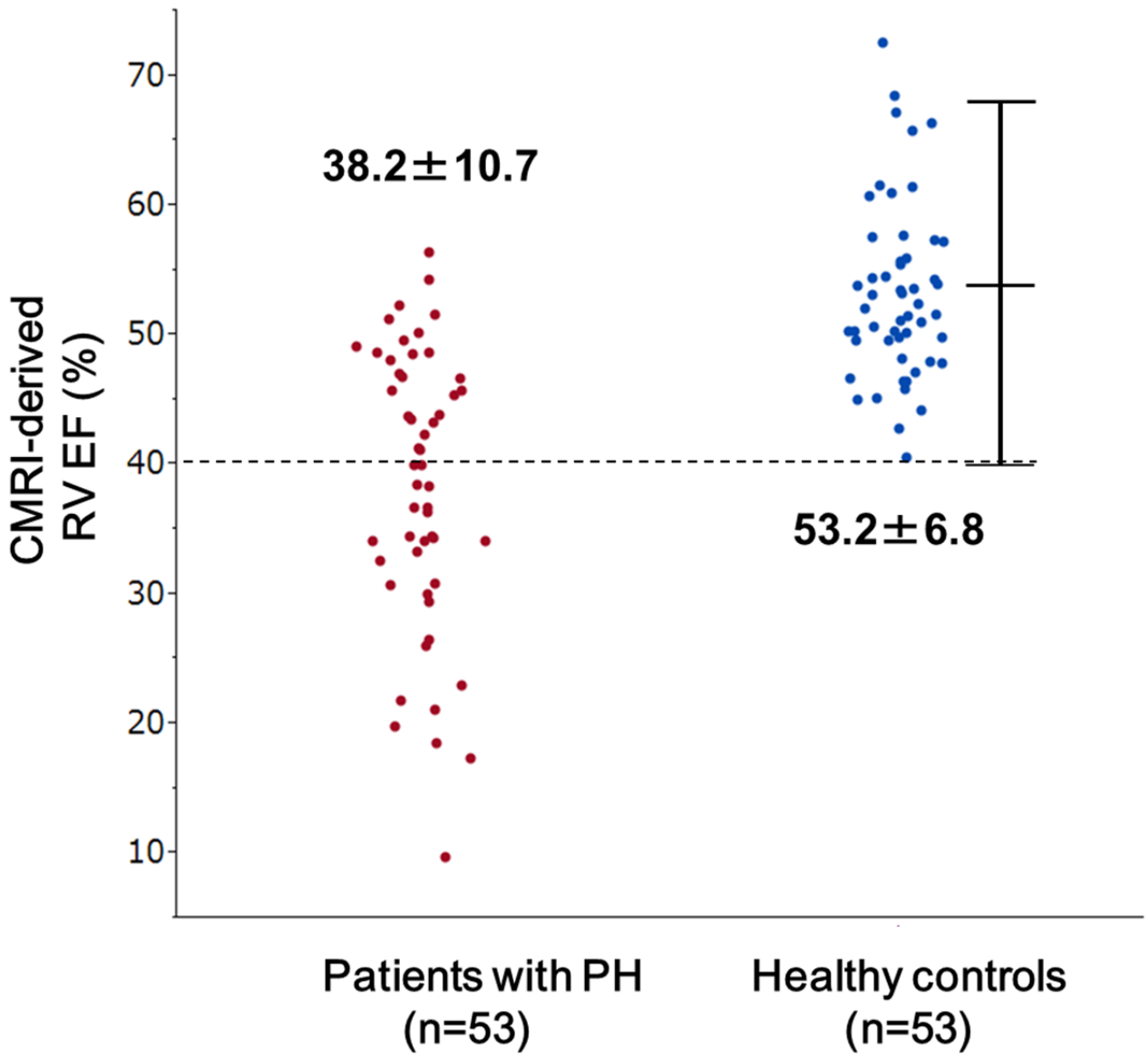
CMRI-derived
RV EF (%)
70
60
50
40
30
20
10
38.2±10.7
53.2±6.8
Patients with PH
(n=53)
Healthy controls
(n=53)

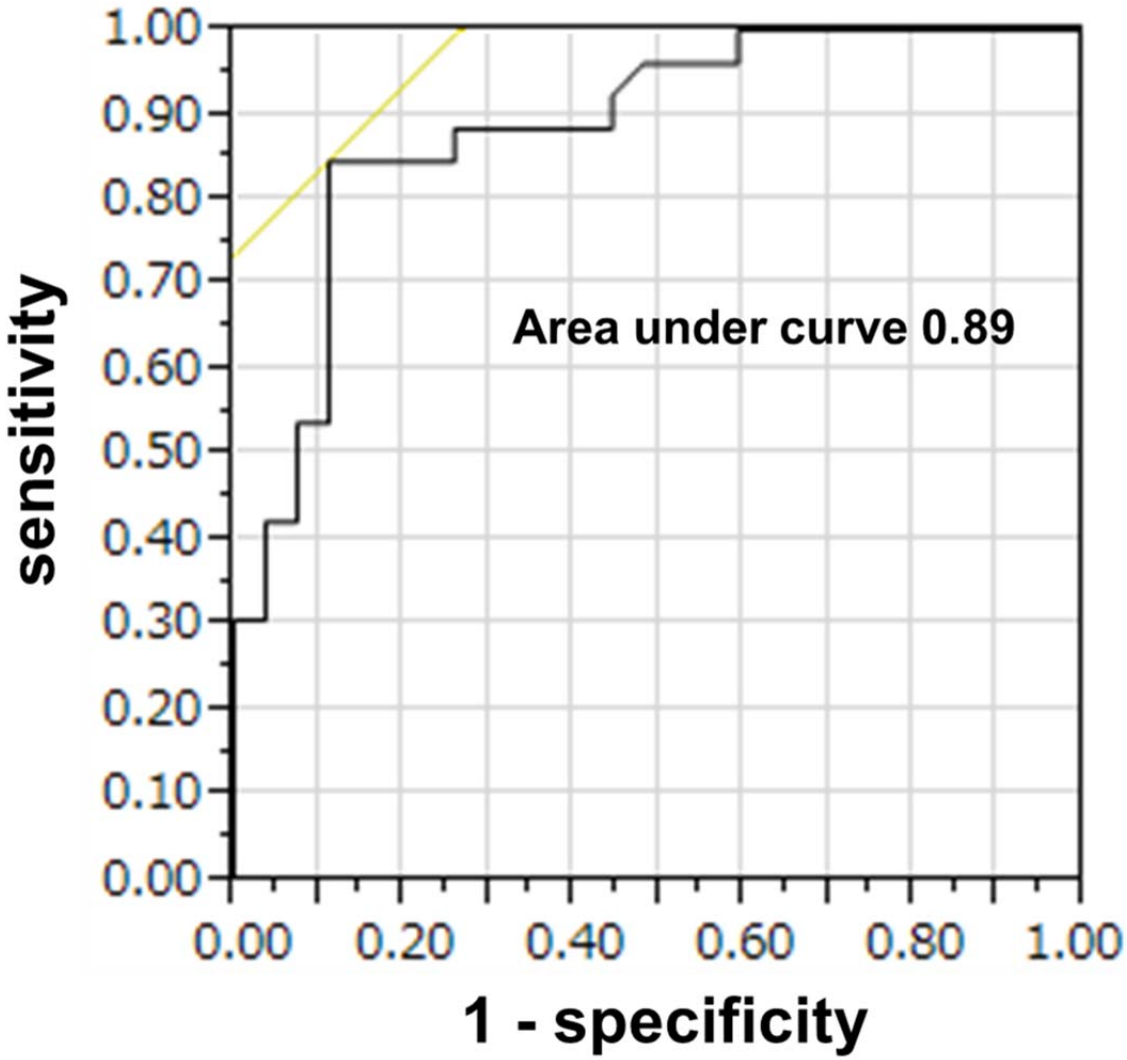
1.00
0.90
0.80
0.70
0.60
0.50
0.40
0.30
0.20
0.10
0.00
sensitivity
Area under curve 0.89
0.00
0.20
0.40
0.60
0.80
1.00
1 - specificity

**Table 1. Characteristics of patients with pulmonary hypertension**

| | |
|---|---|
| **Diagnosis** | |
| Pulmonary arterial hypertension [*1] | 26 |
| Pulmonary hypertension due to lung disease and/or hypoxia | 8 |
| Chronic thromboembolic pulmonary hypertension | 15 |
| Other | 4 |
| **Age (years)** | 52 ± 15 |
| **Male/Female** | 15/38 |
| **WHO functional class** | |
| I | 2 (3%) |
| II | 21 (40%) |
| III | 24 (45%) |
| IV | 7 (13%) |
| **Use of pulmonary hypertension-specific vasodilators** | |
| Beraprost | 19 (36%) |
| Endothelin receptor antagonist | 16 (30%) |
| Phosphodiesterase 5 inhibitor | 12 (23%) |

| | |
|---|---|
| Intravenous epoprostenol | 4 (8%) |
| Combination therapy | 18 (34%) |
| None | 25 (47%) |
| **Domiciliary oxygen therapy** | 23 (43%) |
| **6-minute walk distance**[*2] (m) | 380 ± 121 |
| **Brain natriuretic peptide** (pg/ml) | 38 (18 – 140) |
| **Hemodynamics** | |
| Pulmonary capillary wedge pressure (mmHg) | 8 ± 2 |
| Mean pulmonary artery pressure (mmHg) | 39 ± 11 |
| Systolic pulmonary artery pressure (mmHg) | 64 ± 20 |
| Diastolic pulmonary artery pressure (mmHg) | 24 ± 7 |
| Mean right atrium pressure (mmHg) | 6 ± 2 |
| Cardiac index ($L/min/m^2$)*[3] | 2.8 ± 0.8 |
| Pulmonary vascular resistance ($dyne \cdot s \cdot cm^{-5}$) | 614 ± 285 |
| Mixed venous $O_2$ saturation (%)*[4] | 69 ± 7 |

Data are presented as mean ± SD or median (25 – 75 percentile)

*[1] Idiopathic and heritable pulmonary arterial hypertension, n=8, connective tissue disease-associated pulmonary arterial hypertension, n= 13, others, n= 4. *[2] Not

performed in 7 patients who were assessed as WHO functional class IV. *[3] Mean of at least 3 measurements obtained by the thermodilution method. *[4] Obtained during oxygen inhalation (0.5-8 L/min) in 11 patients.

**Table 2. Echocardiography and cardiac magnetic resonance imaging measurements in controls and patients with pulmonary hypertension**

| | Healthy controls (N=53) | Patients with PH (N=53) | P value |
|---|---|---|---|
| ***Echocardiography*** | | | |
| Left ventricular diastolic diameter (mm) | 43 ± 3 | 40 ± 6 | <0.001 |
| Left ventricular fractional shortening (%) | 42 ± 7 | 44 ± 9 | 0.224 |
| Left atrial diameter (mm) | 31 ± 6 | 33 ± 6 | 0.084 |
| Eccentricity index | 1.0 ± 0.0 | 1.3 ± 0.2 | <0.001 |
| Tricuspid annular plane systolic excursion (mm) | 26.1 ± 2.7 | 18.7 ± 4.5 | <0.001 |
| ***Cardiac magnetic resonance imaging*** | | | |
| *Right ventricular measurements* | | | |
| End-diastolic volume index (mL/m$^2$) | 50 ± 12 | 108 ± 40 | <0.001 |
| End-systolic volume index (mL/m$^2$) | 26 ± 9 | 68 ± 36 | <0.001 |
| Ejection fraction (%) | 53 ± 7 | 38 ± 11 | <0.001 |

| | | | |
|---|---|---|---|
| *Left ventricular measurements* | | | |
| End-diastolic volume index (mL/$m^2$) | 52 ± 10 | 60 ± 14 | <0.587 |
| End-systolic volume index (mL/$m^2$) | 23 ± 11 | 24 ± 9 | 0.010 |
| Ejection fraction (g/$m^2$) | 65 ± 6 | 60 ± 9 | <0.001 |

PH: pulmonary hypertension