Japanese Journal of Veterinary Research 63(1): 37–43, 2015

FULL PAPER

Quadricuspid aortic valves in Syrian hamsters and their formation according to current knowledge on valvulogenesis

Alejandro López-García, M. Carmen Fernández, Ana Carmen Durán, Valentín Sans-Coma and Borja Fernández*

Department of Animal Biology, Faculty of Science and Biomedical Research Institute of Málaga (IBIMA), University of Málaga, 29071 Málaga, Spain

Received for publication, October 30, 2014; accepted, February 2, 2015

Abstract

Occurrence of quadricuspid aortic valves has been reported in humans, in nine dogs and in a greater white-toothed shrew. Moreover, two cases of developing aortic valves with four anticipated leaflets have been described in Syrian hamster embryos. Currently, however, no case of quadricuspid aortic valve in adult hamsters has been recorded. The aim here is to present four adults of this rodent species, two of them with unequivocally quadricuspid aortic valves and the other two with quadricuspid-like aortic valves. The four anomalous aortic valves were detected among 4,190 Syrian hamsters examined in our laboratory, representing an incidence of 0.09%. None of the affected hamsters showed apparent signs of disease. The present findings are considered on the light of current empirical knowledge about the morphogenesis of quadricuspid and bicuspid aortic and pulmonary valves. Quadricuspid aortic valves result from the partition of one of the normal mesenchymal cushions which normally give rise to normal (tricuspid) valves, while quadricuspid-like valves might be the product of a combined mechanism of fusion and partition of the cushions at the onset of the valvulogenesis. The presence of aortic valves with four leaflets in ancient mammalian lineages such as insectivors and rodents suggest that quadricuspid aortic valves, although showing almost certainly a low incidence, may be widespread among the different groups of mammals, including domestic animals.

Key Words: Aortic valve anomalies, Embryogenesis, Heart, Quadricuspid aortic valve, Syrian hamster

Introduction

The condition of the aortic valve characterized by the existence of four instead of three leaflets is a rare congenital anomaly that has been reported in both humans and non-human mammals. In humans, quadricuspid aortic valve (QAV) may be totally silent clinically and

*Corresponding author: Dr. Borja Fernández; Department of Animal Biology, Faculty of Science; University of Málaga; 29071 Málaga; Spain
Fax: +34–952–131668. E-mail: borjafe@uma.es
doi: 10.14943/jjvr.63.1.37

compatible with normal function. In fact, the defect has been often detected incidentally at necropsy or at surgery[1]. There is enough evidence, however, that the natural history of QAV can be best described as progressive valve insufficiency[13,23,24].

Among animals, QAV was noticed in a wild living greater white-toothed shrew, where the anomalous valve occurred in association with a single coronary ostium in aorta[3]. In addition, presence of a QAV was described in nine dogs[13,20,22], in all of which the valve showed a mild to moderate regurgitation. In most (n = 7) cases, the QAV was associated with other heart disease, such as ventricular septal defect, enlarged coronary ostium, degenerative mitral valve disease and patent ductus arteriosus[14,20].

In previous papers, we described two cases of developing QAVs in embryos of Syrian hamsters[6,7]. Until now, however, there were no data about the occurrence of QAVs in adult Syrian hamsters. The aim here is to report four adult hamsters in which the aortic valve was quadricuspid or quadricuspid-like, and to offer a plausible interpretation of their embryonic origin.

Materials and methods

The animals included in the present study belonged to a Syrian hamster colony, composed of four inbred strains, which has been used during more than two decades in our laboratory for the study of congenital anomalies of the coronary arteries and cardiac semilunar valves, and especially the bicuspid condition of these valves. The characteristics of the colony and the housing and management of the animals were described elsewhere[9,10]. To our knowledge, the hamsters were not exposed to teratogenic agents. They were handled in accordance with the Spanish Regulations for the Protection of Experimental Animals (R.D. 1201/2005, B.O.E. 21.10.2005) and with the approval of the institutional committee. So far, we have retrospectively assessed the aortic valve morphology of 4,190 hamsters of our colony that meet the following inclusion criteria: adult (aged 2 months or above) males (n = 2,068) and females (n = 2,122), sacrificed as described below or found dead, in which the anatomic condition of the aortic valve could be clearly identified by stereomicroscopy.

The animals were killed with carbon dioxide delivered into a chamber at a concentration of 75%. The heart was exposed by means of a thoracotomy at the level of the fifth intercostal space, removed, transferred to heparinised 0.1 M phosphate buffered saline (pH 7.3), and dissected to expose the aortic and pulmonary valves. The gross anatomical conditions of the arterial valves were assessed by opening them in the distoproximal direction under a Leica Wild M650 (Leica, Wetzlar, Germany) stereomicroscope.

Two of the QAVs (Nos 41-7 and 225-3) were examined by scanning electron microscopy. The valves were removed and fixed by immersion in 1% paraformaldehide and 2% glutaraldehyde in 0.05 M sodium-cacodylate buffer (pH 7.3) with osmolarity adjusted to 330 milliosmol/l overnight (ratio of fixative:tissue volume, 80 :1). Thereafter, the specimens were dehydrated in increasing concentrations of ethanol, dried by the critical point method and gold sputter coated. Observations were made using a Jeol JSM-840 scanning electron microscope (Jeol, Tokyo, Japan), operated at 10 kV.

The nomenclature used in this study is that proposed by Sans-Coma *et al.*[18,19] and Fernández *et al.*[6] for the components the aortic and pulmonary valves in Syrian hamsters.

Results

We identified four hamsters with quadricuspid or quadricuspid-like aortic valve among 4,190 animals of our colony. The four animals (code numbers: 41-7, 137-6, 162-2, 225-3) were males; they were aged 127, 348, 149 and 99 days, respectively. All of them belonged to the same

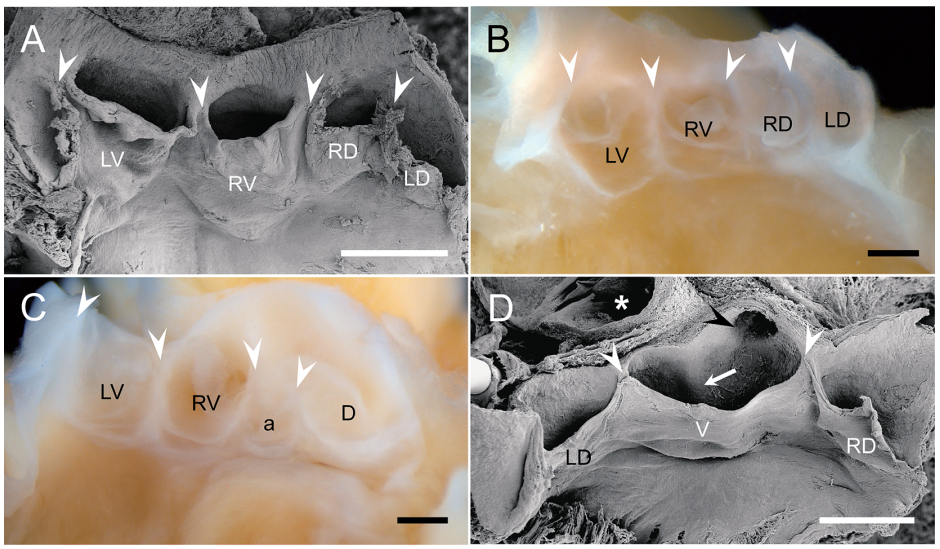

Fig. 1. Scanning electron micrographs (A, D) and stereomicroscopic photographs (B, C) of the quadricuspid (A: specimen No 41-7, B: specimen No 162-2) and quadricuspid-like (C: specimen No 137-6, D: specimen No 225-3) aortic valves. The specimens were opened through the left-dorsal (A and B), dorsal (C), or right-dorsal (D) aortic sinus to expose the ventral aspect of the valve. The white arrowheads mark the valve commissures. In panel D, the black arrowhead points to a coronary ostium, the arrow to a raphe, while the asterisk indicates the pulmonary artery. a: accessory leaflet; D: dorsal leaflet; LD: left-dorsal leaflet; LV: left-ventral leaflet; RD: right-dorsal leaflet; RV: right-ventral leaflet; V: ventral leaflet. Scale bar = 500 μm.

strain (code: T-strain), and specifically to the 4th (No 41-7), 17th (No 137-6), 19th (No 162-2) and 22th (No 225-3) inbred generations. None of these animals showed external signs of disease before being sacrificed following our protocol for morphological studies of aortic valves in Syrian hamsters. They were active, showed bright eyes and firm muscle tone. The routine observations looking for indicators of ill health are described in Inglis[12] and Poole[17].

Two hamsters (Nos 41-7 and 162-2) had an unequivocally QAV, with the leaflets and their supporting sinuses located in the right-ventral, left-ventral, right-dorsal and left-dorsal positions (Figs. 1A, B; 2A, B). In both cases, the right and left coronary arteries arose from the right-ventral and left-ventral sinuses, respectively. In one QAV (No 41-7), the left-ventral leaflet and sinus were larger than the other three (Figs. 1A; 2A). This arrangement does not correspond to any of the types described by Hurwitz and Roberts[11] in humans. In the remaining QAV (No162-2), there were two equal, larger ventral leaflet and sinuses and two equal, smaller dorsal leaflet and sinuses (Figs. 1B; 2B), a condition equivalent to "type c" of humans[11].

The other two anomalous aortic valves included in the present report (Nos 137-6 and 225-3) showed less patent quadricuspid morphology in comparison with the two preceding cases. Therefore, we have tentatively called them quadricuspid-like aortic valves (Figs. 1C, D; 2C, D). In one case (No 137-6) the right and left ventral leaflets were totally fused in cephalo-caudal direction, resulting in a single, large leaflet when viewed from the ventricular side (Figs. 1C; 2C). The ventral fibrous subaortic interleaflet triangle, which normally exists between the right and left ventral leaflets (see Sans-Coma *et al.*[18]), was lacking. When seen from the aortic side, however, two cavities, right and left, of similar size could be well identified at the sites where the true right and left leaflets with their corresponding sinuses should have been. The right coronary artery originated from the wall of the right cavity, and the left coronary artery from the wall of the left cavity. On the dorsal aspect of the valve there was a relatively

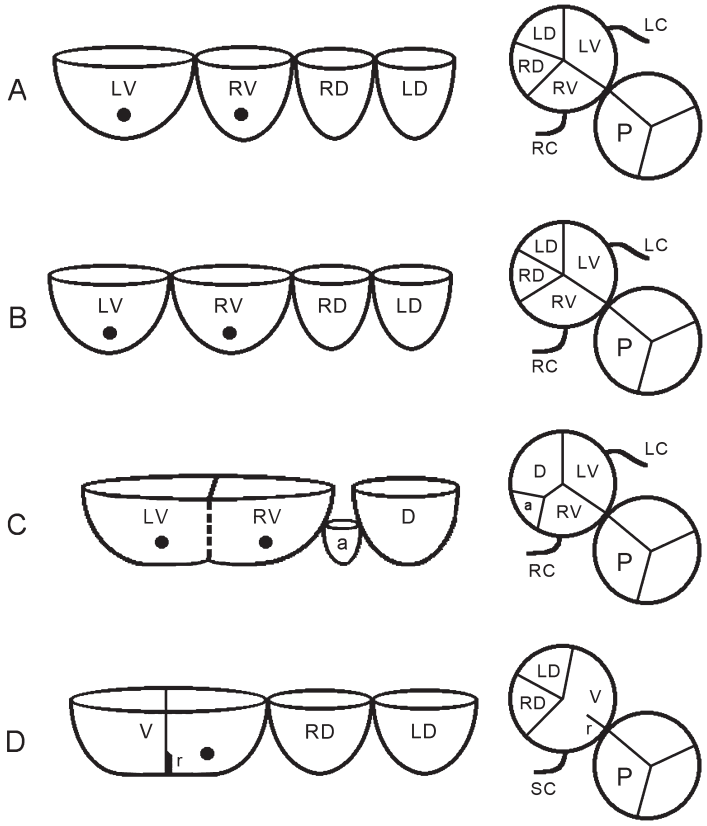

Fig. 2. Diagrammatic representation of the quadricuspid and quadricuspid-like aortic valves. The valves are shown in frontal view on the left side and in occlusal view on the right side. A. Quadricuspid aortic valve from specimen No 41-7. B. Quadricuspid aortic valve from specimen No 162-2. C. Quadricuspid-like aortic valve from specimen No 137-6. D. Quadricuspid-like aortic valve from specimen No 225-3. The dark points on the left sided diagrams indicate the position of the coronary ostia. The dotted line in C indicates the fused commissure between the left-ventral (LV) and right-ventral (RV) leaflets. In D, a raphe (r) encroaches toward the single ventral leaflet (V). a: accessory leaflet; D: dorsal leaflet; LC: left coronary artery; LD: left-dorsal leaflet; LV: left-ventral leaflet; P: pulmonary valve; RC: right coronary artery; RD: right-dorsal leaflet; RV: right-ventral leaflet; SC: single right coronary artery trunk.

large dorsal leaflet and, at its right side, a small (accessory) leaflet, the free margin of which was somewhat shifted proximally with respect to the other leaflets.

The remaining quadricuspid-like valve (No 225-3) consisted of a large ventral leaflet and two dorsal leaflets of equal size (Figs. 1D; 2D). A well developed raphe was located in the ventral sinus, approximately at the anticipated site of the ventral commissure. The raphe encroached towards the proximal portion of the leaflet. In this specimen there was a sole coronary ostium located in the right side of the single ventral aortic sinus.

It should be noted that in all four hamsters, the pulmonary valve displayed a normal (tricuspid) condition and that none of them showed other cardiac malformations.

Discussion

The present paper is the first to report the occurrence of quadricuspid and quadricuspid-like aortic valves in adult Syrian hamsters. Two of the four anomalous valves included in this study were unequivocally quadricuspid; they had four aortic sinuses, each supporting its own leaflet. In contrast, the other two valves showed a design that, though resembling that of QAVs, diverged

to some extent from the typical quadricuspid morphology. Therefore, we decided to designate them as quadricuspid-like aortic valves, a term that seems to be consistent with the presumptive morphogenesis of such valves which we propose below.

It is well known that the development of the arterial valves does not substantially differ between humans and non-human mammals (see Fernández *et al.*[5,7]). As to the formation of quadricuspid aortic and pulmonary valves, the only empirical data reported up to now are those obtained from Syrian hamster embryos[6–8]. These data indicate that in both arterial valves, the presence of four instead of three leaflets and sinuses results from the partition of one of the three valve cushions that give rise to a normal valve (Fig. 3A, C). The partition of the cushion is due to the invagination of the endothelial layer that covers its luminal side at a very early stage of the valvulogenesis. As pointed out by Fernández *et al.*[6], these findings contradict the classical hypotheses on the development of QAVs, which implicated mechanisms such as an anomalous septation of the cardiac outflow tract, anomalous excavation of one of the valve cushions, and septation of a normal valve cushion due to an inflammatory episode.

While the morphogenetic mechanism leading to a QAV appears to be explained satisfactorily, the formation of the valves classified herein as quadricuspid-like valves is unclear. It has been shown that in Syrian hamsters, more or less extensive fusions of the mesenchymal cushions during embryonic life give rise to fusions of the leaflets and formation of raphes in the semilunar valves[8,18] (Fig. 3B). As a result, different morphotypes of aortic and pulmonary valves appear, forming in each case a phenotypic continuum, the variation of which ranges from a genuine tricuspid valve to a bicuspid valve devoid of any raphe. The intermediate stages of the continuum are represented by tricuspid valves with a more or less extensive fusion of the leaflets and by bicuspid valves with a more or less extensive raphe located in the sinus resulting from the fusion of the mesenchymal cushions[5,8,18]. This, together with the data on the development of the QAVs allows us to speculate that a combined mechanism of fusion and partition of the cushions at the onset of the valvulogenetic process might account for the quadricuspid-like valves (Fig. 3D). Thus, the

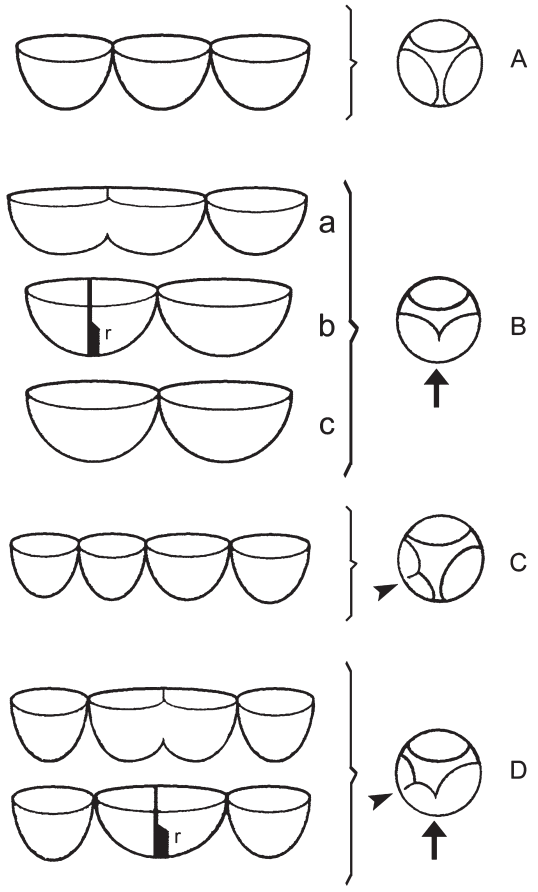

Fig. 3. Aortic valve morphologies in adult Syrian hamsters and arrangement of the aortic valve cushions at the beginning of the valvulogenesis. A. Normal (tricuspid) aortic valve originated from three independent embryonic valve cushions. B. Tricuspid aortic valve with fusion of the ventral commissure (a), bicuspid aortic valve with a raphe (r) (b), and bicuspid aortic valve devoid of raphe (c), resulting from different degrees of fusion (arrow) of two embryonic valve cushions. C. Quadricuspid aortic valve formed as a consequence of the division (arrowhead) of one of the three embryonic valve cushions. D. Formation of quadricuspid-like aortic valves based on a hypothetical combined mechanism of fusion (arrow) and partition (arrowhead) of embryonic valve cushions. r: raphe.

quadricuspid-like aortic valve of the specimen No 137-6 (Figs. 1C; 2C) may be the result of a partial fusion of the right and left aortic valve cushions combined with an unequal partition of the dorsal aortic cushion. The quadricuspid-like aortic valve of the specimen No 225-3 (Figs. 1D; 2D) may result from a total fusion of the right and left aortic valve cushions combined with a symmetrical partition of the dorsal aortic cushion, both at an early stage of the valvulogenesis.

The four anomalous aortic valves reported herein were detected among 4,190 Syrian hamsters examined in our laboratory, representing an incidence of 0.09%. If only considering the true QAVs, the incidence amounts to 0.045%. These values do not diverge from those in humans, where the estimated frequency of QAV ranges between 0.033% and 1.46%[2,4,11,15,16,21,23,25]. Of notice is that the four hamsters were all males. From this small number of cases, however, it is not possible to draw any inference about the possible influence of sex on the occurrence of QAVs in the Syrian hamster. In humans, the QAV appears to have an equal sex distribution[11], though a slight male predominance (1.61 : 1) has been reported[24].

As already noted, both human and canine QAVs are prone to valve regurgitation. In the present Syrian hamsters, the defective valves did not seem to cause any signs of disease, at least under laboratory conditions. In fact, they were incidentally detected at necropsy. In any instance, we can not discard that the affected animals could have some degree of valve insufficiency. Further experiments involving endurance exercise would be required to gain more insight into this question. However, it should be noted that the low incidence of QAVs, the difficulty to diagnose this valvular condition in small mammals and the absence of external signs of disease in animals carrying QAVs are important limitations to program and implement such experimental studies.

The presence of QAVs in species belonging to old mammalian lineages such as insectivors (e.g., shrews) and rodents (e.g., hamsters) suggests that these defective valves, although showing almost certainly a low incidence, may be widespread among the different groups of mammals. This, together with the fact that in dogs QAV can cause clinical complications, alerts that its possible occurrence in domestic animals should be borne in mind, especially in suspected cases of aortic insufficiency.

Acknowledgments

This work was supported by Grants P10-CTS-06068 from Junta de Andalucía (Sevilla, Spain); and Red de Investigación Cardiovascular (RIC; RETICs) (Madrid, Spain). The authors would like to thank Mr. Luis Vida, Málaga, for his technical assistance and Mr. Gregorio Martín, Málaga, for assistance in operating the scanning electron microscope.

References

1) Butany, J., Collins, M. J., Duchnay, M., Demellawy, D. E. and Karski, J. 2005. A quadricuspid aortic valve. *J. Card. Surg.*, **20**: 193–197.
2) De Vries, W. M. 1918. Ueber Abweichungen in der Zahl der Semilunarklappen. *Beitr. Pathol. Anat.*, **64**: 39–54.
3) Durán, A. C. 1996. Quadricuspid aortic valve and single coronary artery in a greater white-toothed shrew, *Crocidura russula*. *J Wildlife Dis.*, **32**: 658–660.
4) Feldman, B. J., Khandheria, B. K., Warnes, C. A., Seward, J. B., Taylor, C. L. and Tajik, A. J. 1990. Incidence, description and functional assessment of isolated quadricuspid aortic valves. *Am. J. Cardiol.*, **65**: 937–938.
5) Fernández, B., Durán, A. C., Fernández-Gallego, T., Fernández, M. C., Such, M., Arqué, J. M. and Sans-Coma, V. 2009. Bicuspid aortic valves with different spatial orientations of the leaflets are distinct etiological entities. *J. Am. Coll. Cardiol.*, **54**: 2312–2318.
6) Fernández, B., Durán, A. C., Martire, A., López, D. and Sans-Coma, V. 1999. New

embryological evidence for the formation of quadricuspid aortic valves in the Syrian hamster (*Mesocricetus auratus*). *J. Comp. Pathol*., **121**: 89–94.

7) Fernández, B., Durán, A. C., Thiene, G., Cardo, M., Arqué, J. M. and Sans-Coma, V. 1994. Embryological evidence for the formation of a quadricuspid aortic valve in the Syrian hamster. *Cardiovasc. Pathol.*, **3**: 287–291.
8) Fernández, B., Fernández, M. C., Durán, A. C., López, D., Martire, A. and Sans-Coma, V. 1998. Anatomy and formation of congenital bicuspid and quadricuspid pulmonary valves in Syrian hamsters. *Anat. Rec.*, **250**: 70–79.
9) Fernández, M. C, Durán, A. C., Real, R., López D., Fernández, B., de Andrés, A. V., Arqué, J. M., Gallego, A. and Sans-Coma, V. 2000. Coronary artery anomalies and aortic valve morphology in the Syrian hamster. *Lab. Anim.*, **34**: 145–154.
10) Fernández, M. C., Durán, A. C., Fernández, B., Arqué, J. M., Anderson, R. H. and Sans-Coma, V. 2012. Factors other than genotype account largely for the phenoptypic variation of the pulmonary valve in Syrian hamsters. *J. Anat*., **221**: 30–38.
11) Hurwitz, L. E. and Roberts, W. C. 1973. Quadricuspid semilunar valves. *Am. J. Cardiol*., **31**: 623–626.
12) Inglis, J. K. 1980. Introduction to Laboratory Animal Science and Technology. Pergamon Press, Oxford.
13) Jagannath, A. D., Johri, A. M., Liberthson, R., Larobina, M., Passeri, J., Tighe, D. and Agnihotri, A. K. 2011. Quadricuspid aortic valve: a report of 12 cases and a review of the literature. *Echocardiography*, **28**: 1035–1040.
14) Kettner, F., Côté, E. and Kirberger, R. M. 2005. Quadricuspid aortic valve and associated abnormalities in a dog. *J. Am. Anim. Hosp. Assoc*., **41**: 406–412.
15) Mathison, M., Furuse, A., Kotsuka, H., Tanaka, O. and Chikaba, M. 1990. Quadricuspid aortic valve: case reports. *Kyobu Geka*, **43**: 383–288.
16) Olson, L. J., Subramanian, R. and Edwards, W. D. 1984. Surgical pathology of pure aortic insufficiency: a study of 225 cases. *Mayo Clin. Proc*., **59**: 835–841.
17) Poole, T. B. 1987. The UFAW Handbook on the Care and Management of Laboratory Animals. 6th ed. Longman Scientific and Technical, Essex, UK.
18) Sans-Coma, V., Fernández, B., Durán, A. C., Thiene, G., Arqué, J. M., Muñoz-Chápuli, R. and Cardo, M. 1996. Fusion of valve cushions as a key factor in the formation of congenital bicuspid aortic valves in Syrian hamster. *Anat. Rec.*, **244**: 490–498.
19) Sans-Coma, V., Fernández, M. C., Fernández, B., Durán, A. C., Anderson, R. H. and Arqué, J. M. 2012. Genetically alike Syrian hamsters display both bifoliate and trifoliate aortic valves. *J. Anat.,* **220**: 92–101.
20) Serres, F., Chetboul, V., Sampedrano, C. C., Gouni, V. and Pouchelon, J. -L. 2008. Quadricuspid aortic valve and associated abnormalities in the dog: report of six cases. *J. Vet. Cardiol.,* **10**: 25–31.
21) Simonds, J. P. 1923. Congenital malformations of the aortic and pulmonary valves. *Am. J. Med. Sci*., **166**: 585–595.
22) Sisson, D. and Riepe, R. 2000. Congenital quadricuspid aortic valve anomaly in two dogs. *J. Vet. Cardiol*., **2**: 23–26.
23) Timperley, J., Milner, R., Marshall, A. J. and Gilbert, T. J. 2002. Quadricuspid aortic valves. *Clin. Cardiol.*, **25**: 548–552.
24) Tutarel, O. 2004. Quadricuspid aortic valve: a comprehensive review. *J. Heart Valve Dis.*, **13**: 534–537.
25) Yotsumoto, G., Iguro, Y., Kinjo T., Matsumoto, H., Masuda, H. and Sakata, R. 2003. Congenital quadricuspid aortic valve; report of nine cases. *Ann. Thoracic Cardiovasc. Surg*., **9**: 134–137.