



Title	Wide-bladed mandibular channel retractor efficiently secures surgical manoeuvres during ramus osteotomy
Author(s)	Matsushita, Kazuhiro
Citation	British Journal of Oral & Maxillofacial Surgery, 53(2), 210-211 <a href="https://doi.org/10.1016/j.bjoms.2014.11.015">https://doi.org/10.1016/j.bjoms.2014.11.015</a>
Issue Date	2015-02
Doc URL	<a href="http://hdl.handle.net/2115/58505">http://hdl.handle.net/2115/58505</a>
Type	article (author version)
File Information	BR J ORAL M_53(2).pdf



[Instructions for use](#)

**Wide-blade mandibular channel retractor efficiently secures surgical maneuvers in  
ramus osteotomy**

Kazuhiro Matsushita,

Department of Oral and Maxillofacial Surgery, Division of Oral Pathobiological  
Science, Graduate School of Dental Medicine, Hokkaido University, N13 W7, Kita-ku,  
Sapporo, Hokkaido 060-8586, Japan

Corresponding author: Kazuhiro Matsushita

Tel/Fax: +81-11-706-4283

E-mail: matsushi@den.hokudai.ac.jp

Although sagittal split ramus osteotomy is a very popular procedure for correcting mandibular deformities,<sup>1</sup> complications involving the facial artery or vein have been reported.<sup>2</sup> Postoperative pseudoaneurysm has also recently been described.<sup>3</sup> Such complications may be due to the anatomical relationship in the vicinity of the mandibular antegonial notch, where these vessels are often located and where the bottom end of the vertical osteotomy line at the buccal site should be placed. Particularly for successful splitting using the Epker method,<sup>4</sup> the very bottom end of the osteotomy line should be extended just inside the inferior border, but this increases the risk of vessel injuries. To protect surrounding soft tissues, including vessels, from injury by osteotomes and rotational burrs, a channeled retractor is usually inserted between the bone and periosteum, and is to be engaged at the inferior border. Conventional retractors, however, do not always sufficiently prevent soft tissue injury, because inadequate engagement of the border allows surrounding soft tissues onto the edge of the saucer-shaped blade. Visual errors in direction between vectors of the actual burr and of the retractor may also lead to soft tissue injury. We therefore developed a novel channeled retractor specially designed to avoid vessel injuries (Figs. 1, 2). The head is extended 4.0 mm on both sides and 5.0 mm on top to cover the mandibular border more widely in a sagittal direction and more deeply transversally. The blade surface is about 6

times larger than the conventional large size. Indeed, this wide blade sufficiently received cutting devices coming from the upper and lateral sides (Fig. 3) without permitting soft tissue intrusion in clinical situations. Even if the direction of the retractor is not exactly parallel to that of the device, secure handling is achieved. This device alleviates the worry about neighboring soft tissues becoming wound up in the rotational burr or vessels being penetrated by the fine chisel.

## **Discussion**

This instrument was developed with just a little ingenuity, but offers great benefits other than vessel protection. Unlike the conventional retractor, which faces the periosteum on a small surface of the blade, this wide-blade retractor provides a large surface, and the periosteum is not easily torn when pushing the retractor downward incidentally, since the large blade exerts a lower pressure per unit area when the same load is applied. As another merit, for surgeons in training or inexperienced assistants, the instrument actually ensures the safety of osteotomy because the blade is sufficiently large to protect soft tissues even if the channel retractor is inadvertently moved out of the correct position. The retractor has the further advantage of adjusting the distal and proximal segments during plate fixation. The wide blade enables easy contact with the inferior

borders of both the distal and proximal segments and pulls them up to the same level simultaneously. This avoids creation of a step at the bottom of the osteotomy line.

Above all, this retractor encourages a sense of safety.

Conflict of interest: None declared.

Ethical approval: Not required.

## References

1. Bell WH, Proffit WB, White RP. Surgical Correction of Dentofacial Deformities. Philadelphia: WB Saunders, 1980.
2. Lanigan DT, Hey J, West RA. Hemorrhage following mandibular osteotomies: a report of 21 cases. J Oral Maxillofac Surg 1991;49:713-24.
3. Jo HW, Kim YS, Kang DH, Lee SH, Kwon TG. Pseudoaneurysm of the facial artery occurred after mandibular sagittal split ramus osteotomy. Oral Maxillofac Surg 2013; 17:151-4.
4. Epker BN. Modifications in the sagittal osteotomy of the mandible. J Oral Surg 1977;35:157-9.

## Figures

**Fig. 1** Conventional and novel retractors. **A)** Narrow-channel retractor used for placement on the lingual aspect of the mandible. **B)** Wide-channel retractor used for engaging the inferior border of the mandible on the buccal side and making a space for instrument handling. **C)** The novel wide-blade retractor. This instrument is much wider than the other two retractors and engages the inferior border on the buccal side widely and reliably. It is about 6 times as large as Retractor B. No soft tissues reach the center of the saucer from the edge. Osteotomy using burrs and malleting chisels can be performed safely, with no need for worry about vessel injuries.

**Fig. 2** Concrete example of the retractor engaging the inferior border of the mandible in a model. Sufficient engagement is obtained more widely in a sagittal direction and more deeply transversally.

**Fig. 3** Intraoperative picture of wide-blade retractor placement. The periosteum is completely detached and the retractor is suitably engaged at the inferior border. The facial artery and vein are protected behind the wide blade.

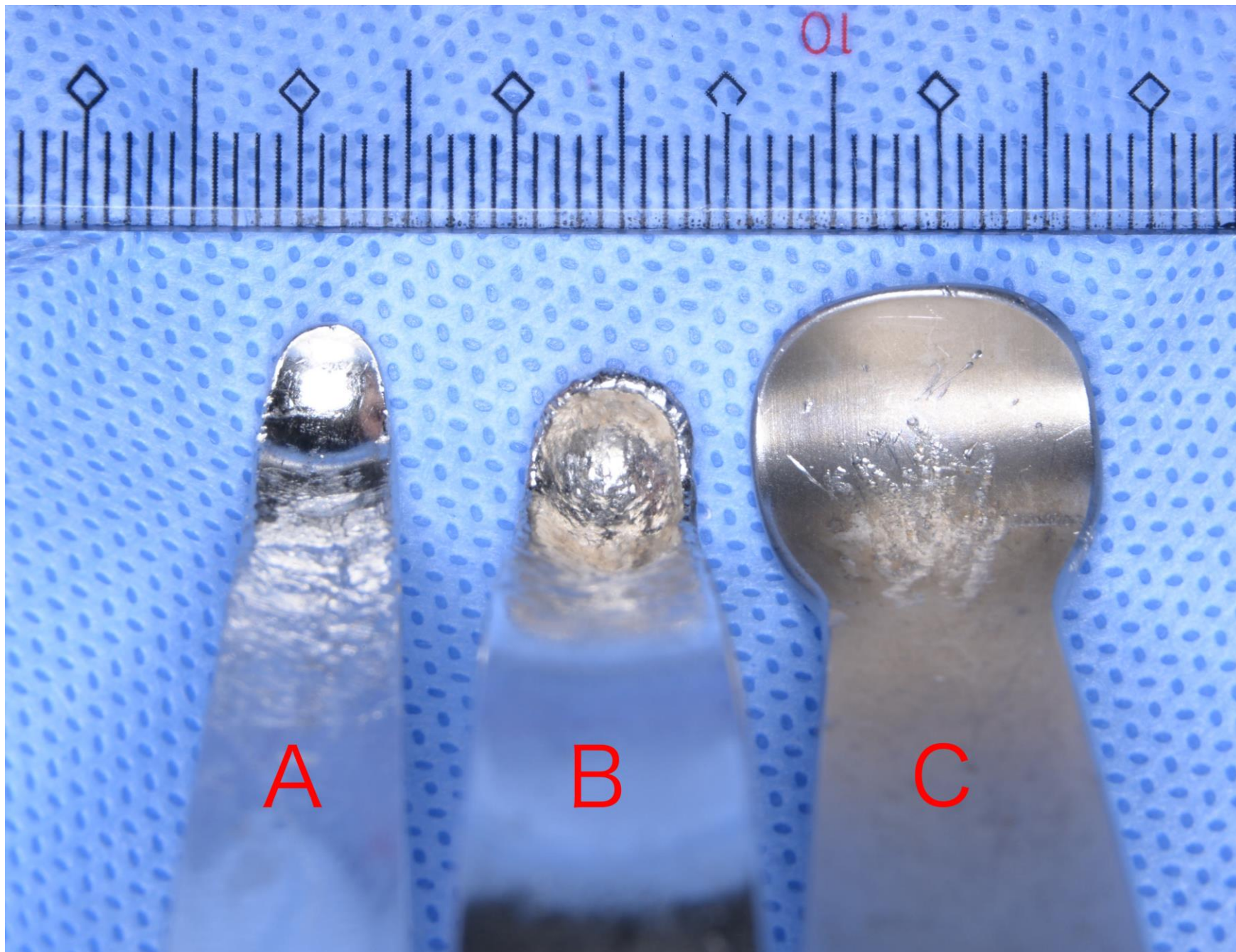


Fig. 1



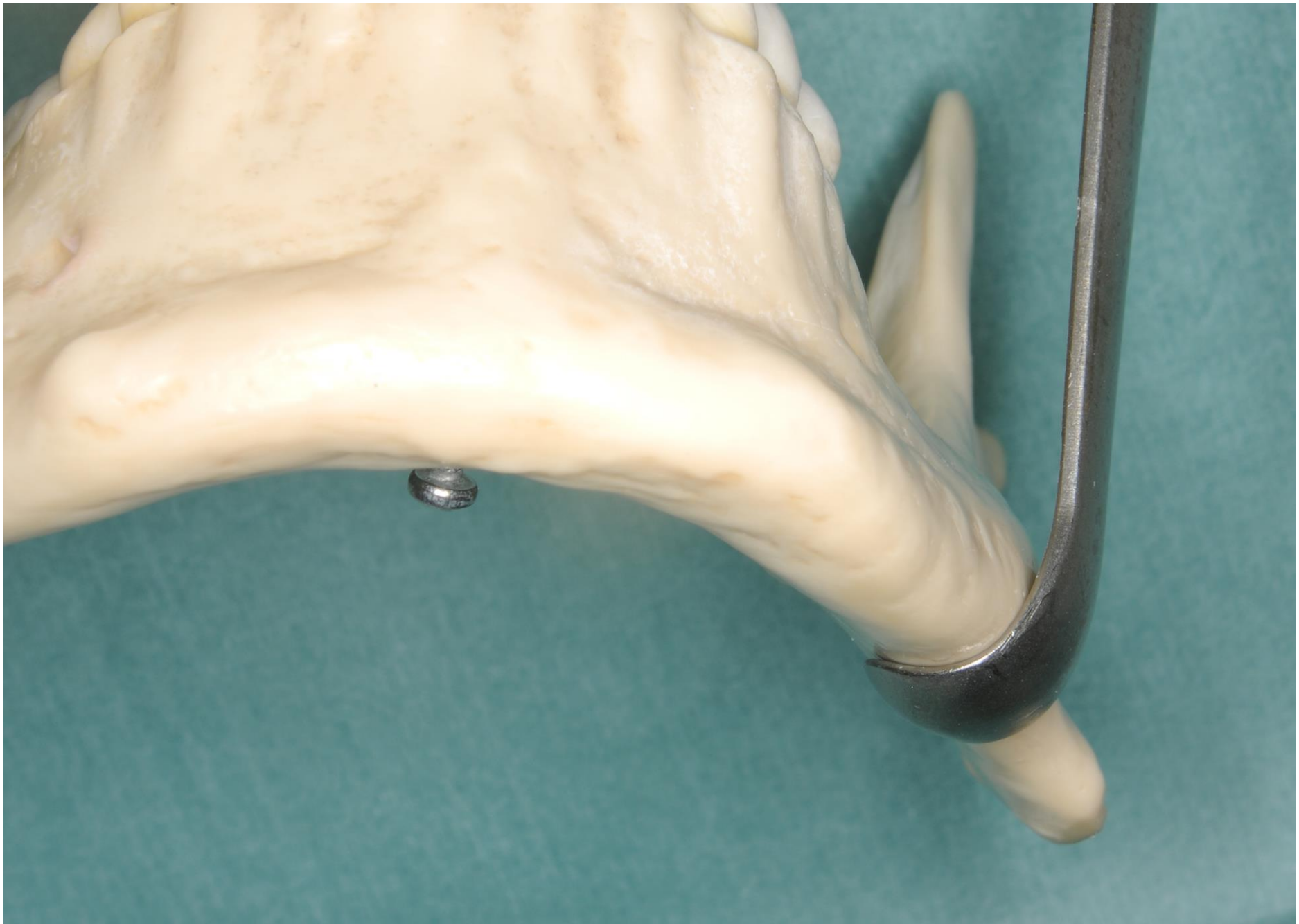

Fig. 2

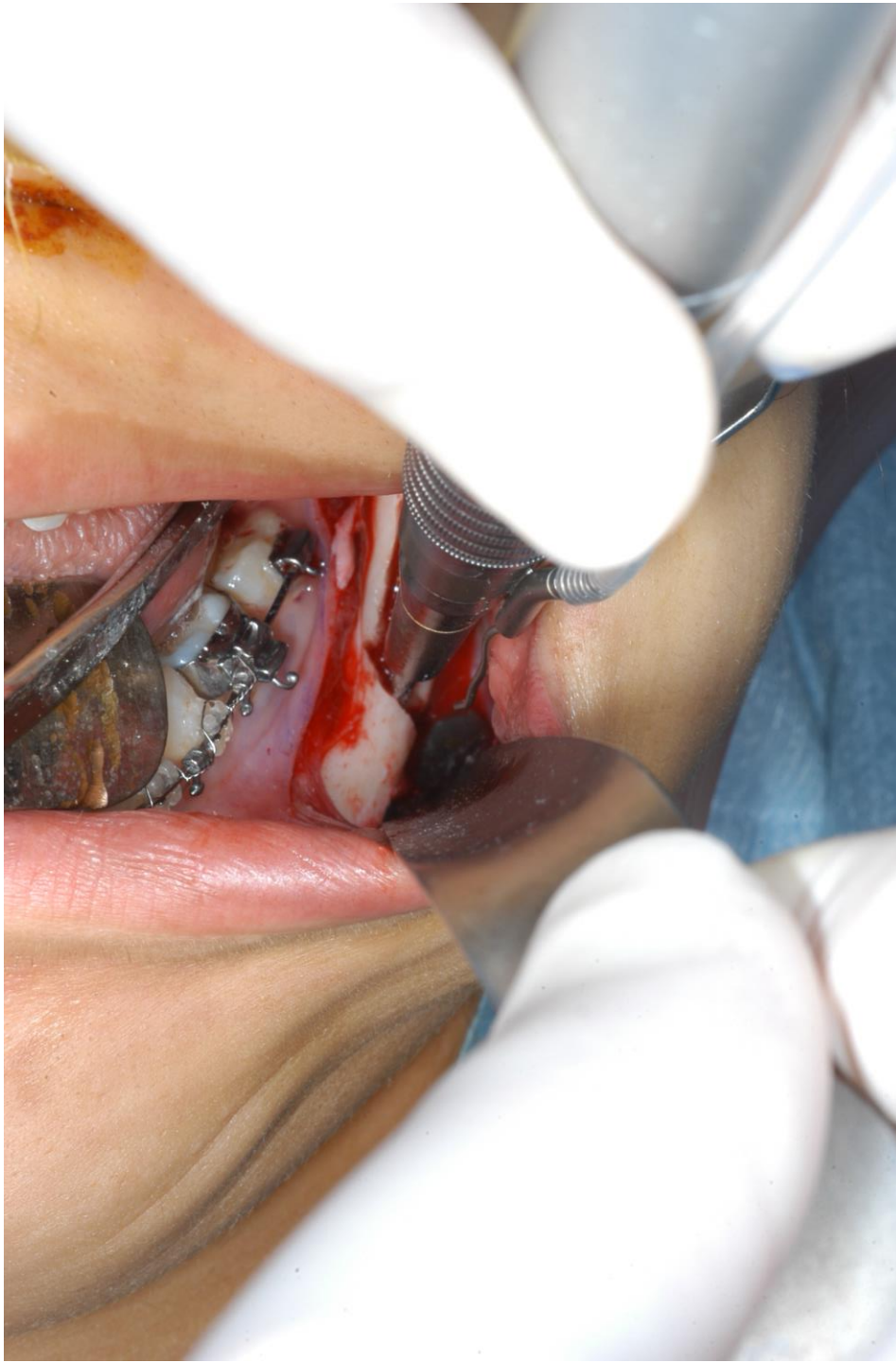

Fig. 3