The efficacy of superselective intra-arterial infusion with concomitant radiotherapy for adenoid cystic carcinoma of the head and neck

Akihiro Homma, Tomohiro Sakashita, Hiromitsu Hatakeyama, Satoshi Kano, Takatsugu Mizumachi, Yuji Nakamaru, Daisuke Yoshida*, Rikiya Onimaru*, Kazuhiko Tsuchiya*, Koichi Yasuda*, Hiroki Shirato*, and Satoshi Fukuda. Department of Otolaryngology-Head & Neck Surgery, *Radiation Medicine, Hokkaido University Graduate School of Medicine, Sapporo, Japan

Corresponding author: Akihiro Homma;

Department of Otolaryngology – Head & Neck Surgery, Hokkaido University Graduate School of Medicine

Kita 15, Nishi 7, Kita-ku, Sapporo 060-8638, Japan

Phone: +81-11-706-5958; Fax: +81-11-717-7566;

E-mail: ak-homma@med.hokudai.ac.jp

ABSTRACT

CONCLUSIONS: Superselective intra-arterial cisplatin infusion with concomitant radiotherapy (RADPLAT) is considered to be one of the treatments of choice for patients with adenoid cystic carcinoma (ACC) who prefer not to undergo radical surgery.

OBJECTIVE: To evaluate the efficacy of RADPLAT for patients with ACC of the head and neck.

PATIENTS AND METHODS: Between 2001 and 2010, 9 patients with untreated ACC were given superselective intra-arterial infusion of cisplatin (100-120 mg/m^2/week) with simultaneous intravenous infusion of thiosulfate to neutralize cisplatin toxicity and radiotherapy (65-70Gy).

RESULTS: Five patients had tumors arising in the base of tongue, 2 in the maxillary sinus, and the remaining 2 in the nasopharynx. The median follow-up period was 9y7m (range 4y6m - 12y5m), and the 5-year local control (LC), overall survival (OS), and disease-free survival rates were 88.9 %, 88.9%, and 55.6%, respectively. The 10-year OS rate was 57.1%, but all patients who remained alive for over 10 years are still alive with disease. Primary tumor recurrence was observed in 5 of the 9 patients, with the median time to recurrence being 6y (range 4-9 years). Five of the 9 patients had distant metastasis, and all of these 3 patients also had primary recurrence.

Keywords: intra-arterial, cisplatin, adenoid cystic carcinoma, head and neck, chemotherapy, radiotherapy.

INTRODUCTION

Adenoid cystic carcinomas ~~(ACCs)~~ usually arise in the salivary glands and are rare malignant tumors, corresponding to just 1% of all head and neck malignant tumors excluding those in the major salivary glands [1]. They exhibit slow but not indolent behavior, and are associated with early perineural invasion, frequent local recurrence, delayed distant metastasis, and eventual death [2,3].

Surgery is considered the mainstay for treatment. However, complete resection is not always achieved and local recurrence is not uncommon, even after postoperative radiotherapy [4-6]. Radiotherapy is indicated for patients with unresectable disease or patients who refuse surgery. Treatment results are considered poor after radiotherapy without surgery [5,7]. However, recent reports have shown promising results associated with chemoradiotherapy [8,9], although the role of chemotherapy in the treatment of Adenoid cystic carcinoma (ACC) has been considered limited and there have been few reports on the application of definitive chemoradiotherapy for the management of ACC.

It has also been shown that superselective intra-arterial cisplatin infusion with concomitant radiotherapy (hereafter called RADPLAT) is a promising treatment, achieving an 80% complete response rate in advanced cases of squamous cell carcinoma of the head and neck [10]. The treatment program incorporates a novel technique for infusing cisplatin directly into the tumor bed, while minimizing the effects of the drug systemically. Here we report our experience of ACC treated with RADPLAT.

PATIENTS AND METHODS

A retrospective analysis was performed using data from 9 patients with previously untreated ACC of the head and neck who were treated with RADPLAT in Hokkaido University Hospital between 2001 and 2010.

All patients were initially evaluated by a multidisciplinary team consisting of head and neck surgeons and radiation oncologists, and tumors were classified according to the 7th Edition of the Union for International Cancer Control (UICC) staging system published in 2009. Patients visiting our hospital before 2009 were restaged according to the UICC 7th edition. The stage of the tumor was determined on the basis of patient history, physical examination, chest x-rays, as well as computed tomography (CT) and/or magnetic resonance imaging (MRI). Approval for this study was obtained from the Institutional Review Board at Hokkaido University.

Chemotherapy: All patients received concurrent intra-arterial cisplatin and intravenous sodium thiosulfate infusions with concomitant radiotherapy as follows: cisplatin (100–120 mg/m^2 per week for four weeks) was infused through a microcatheter placed angiographically to selectively encompass only the dominant blood supply of the targeted tumor. At the same time, sodium thiosulfate (20–24 g) was given intravenously, as described by Robbins et al., to neutralize the cisplatin [11]. All arterial catheterizations were accomplished transcutaneously through the femoral artery, and the catheters were removed immediately after infusion. To encourage the rapid excretion of the cisplatin, 8 L of lactated Ringer's solution were given over a 24-h period. A 5HT3-receptor

antagonist was given to all patients before arterial infusion to minimize nausea and vomiting. Chemotherapy was completed during the first four weeks of treatment, provided that patients responded well in the early treatment period and received three arterial infusions.

Radiotherapy: A thermo-plastic mask was used for immobilization for all patients. Patients were treated using megavoltage (4 or 6 MV) X-rays from linear accelerators. Seven patients were treated by 3-dimensional conformal radiotherapy and two patients were treated by intensity-modulated radiotherapy. The clinical target volume (CTV) was calculated from the gross tumor volume (GTV) by adding a 10- to 15-mm margin. A margin of 3 mm was added in all directions to the CTV to produce the planning target volume (PTV). Once-daily fractions of 2.0 Gy were given 5 days per week or fractions of 2.2-2.5 Gy were delivered 4 days per week. A total dose of 60-70 Gy was prescribed to the PTV. For the prophylaxis of perineural extension, we added the neural tract from the GTV to the skull base to the CTV up to a total dose of 40-50Gy. Prophylactic nodal irradiation was applied for one patient with nodal metastasis at the time of treatment. The treatment plan was made so that the maximum dose to the brain stem and spinal cord did not exceed its tolerance dose.

Statistical analysis: All toxicities encountered during therapy were evaluated according to the Common Terminology Criteria for Adverse Events *v4.0 (2009)*. The probability of overall survival, disease-free survival, local control were computed from the beginning of treatment to the time of death from any cause, recurrence or death from any cause, and local relapse. They were calculated

by the Kaplan-Meier method. Statistical analysis was performed using JMP Pro 11.0.0 statistical software (SAS Institute, Cary, NC).

RESULTS

Five patients had tumors arising in the base of tongue, 2 in the maxillary sinus, and the remaining 2 in the nasopharynx. Lymph node involvement was observed in 1 patient (N2b).

Seven of the 9 patients (78%) experienced grade III to IV acute toxicity, consisting of leucopenia (n=3), nausea/vomiting (4), mucositis (3), and facial nerve palsy (1). However, RADPLAT was feasible (3 or 4 infusions of IA cisplatin and a full dose of radiation therapy within 7 days of treatment interruptions) in all patients. With regard to late adverse reactions, osteonecrosis (grade 2) of mandible, which did not require any surgery, was observed in one patient, while another patient developed ocular/visual problems (grade 3) and brain necrosis (grade 1).

The median follow-up period was 9y7m (range 4y6m - 12y5m), and the 5-year local control (LC), overall survival (OS), disease-free survival (DFS) rates were 88.9 %, 88.9%, and 55.6%, respectively. The 10-year OS rate was 57.1%, but all patients who remained alive for over 10 years are still alive with disease. Primary tumor recurrence was observed in 5 of the 9 patients, with the median time to recurrence being 6y (range 4-9 years). Five of the 9 patients had distant metastasis, and all of these 3 patients also had primary recurrence. The median time to distant metastasis was 4y (range 1y11m - 8y).

DISCUSSION

Surgery with or without postoperative radiation therapy is considered to be the standard treatment of care for patients with ACC [5,7]. However, wide resection is required for ACC, which results in significant disfigurement and/or loss of function. Furthermore, such surgery does not necessarily lead to a good result. Many patients suffer recurrent primary disease and/or distant disease. Local and distant metastases are also common in patients with ACC, even several years or more after initial curative therapy. During the first 5 years of follow-up, local treatments suggest a high success rate, with 50% to 75% remaining disease-free. However, subsequent follow-up periods show a steady rise in the number of patients with local recurrence and/or metastases, with only 10% to 20% remaining disease-free at 15 years. In addition, some patients refuse surgery due to perceived functional or cosmetic deficits, while others have unresectable disease at the time of presentation [12].

Wang et al. reported 20 cases of ACC of the nasopharynx. All patients were treated by radiotherapy, with 6 undergoing surgery. As a result, the 5- and 10-year overall survival rates were 78% and 49.5%, respectively [13]. Based on meta-analysis of the literature and data from the International ACC Study Group, the 5- year OS rate was 62% among patients with ACC of the nasal cavity, paranasal sinus, and the nasopharynx [6], and adjuvant treatment in the form of radiotherapy or chemoradiotherapy was not associated with a better outcome than surgery alone or primary chemoradiotherapy. Seong et al. reported the 5-year DFS rate was 37.5% among 30 patients with sinonasal ACC [14]. Of these 30 patients, 27 (90%) underwent surgical resection as initial treatment.

Patients with T4 disease had significantly worse OS and DFS than those with T1-2 or T3 disease. Iyer et al. reported 67 patients with malignant minor salivary gland tumors of the oropharynx [15]. Sixty-one patients (91%) received surgery. Among the 16 patients with ACC, 2 developed recurrent primary disease, and 5 developed distant metastasis. The 5- and 10-year OS rates were 85% and 38%, respectively. In our study, the 5- and 10-year OS rates were 88.9 % and 57.1%, respectively, and the 5-year DFS rate was 55.6%, all of which appear to be comparable or better than the results shown in previous reports.

Conley et al. described ACC as 'radiosensitive but not radiocurable' [16]. Indeed, previous reports have suggested that radiotherapy is not considered sufficient to eradicate the disease [7]. ~~However, Hosokawa et al. showed the utility of radiation alone for local palliation [15].~~ Further, chemotherapeutic agents were not active for ACC, although cisplatin has shown some effect [12], while other cytotoxic agents as well as molecular-targeted therapies have been found to be inactive to date. Recently, Samant et al. reported promising results for radiation therapy with cisplatin for ACC [9]. Lastly, we have applied RADPLAT to patients with ACC for over 10 years [17].

This case series suggests that RADPLAT had some beneficial effects on patients with ACC. Primary recurrence occurred in 5 patients. One patient received salvage surgery, although lung metastasis was discovered thereafter, while salvage surgery was either not indicated for or refused by the remaining 4 patients with primary recurrence. None of these patients have experienced either pain or dysfunction related to very slow-growing primary recurrence to date. Samant reported that RADPLAT appeared to be quite beneficial, with 6 of 6 patients achieving lasting local disease

control with a median follow-up of 64 months (range, 46-93 months) [9].

Particle radiation therapy, such as neutron radiation therapy [18] and carbon ion therapy [19], produced favorable local control and survival rates in cases of ACC [20]. However, we have to wait to evaluate the results of longer follow-up periods and late complications due to the fact that ACC is slow-growing over periods of 10 years or more.

Based on the above results, RADPLAT could be one of the treatments of choice for patients with ACC who prefer not to undergo radical surgery as the wide surgical resection often result in significant disfigurement and impairment of function and does not necessarily lead to good results when viewed long term. Patients in this series had either unresectable disease or required total glossectomy and laryngectomy, or extended total maxillectomy, if surgery were indicated. Nevertheless, the patients in this series maintained a good QOL for a long period. RADPLAT, therefore, played a beneficial role.

In conclusion, the present study findings confirmed the characteristics of ACC, such as local recurrence and distant metastasis arising many years after initial treatment, and, although patient numbers were small, and represented only a single institution, demonstrated that the results of RADPLAT are comparable to those of surgery followed by radiotherapy. Therefore, RADPLAT is considered to be a treatment of choice for patients with ACC who prefer not to undergo radical surgery or who have unresectable disease.

Presented at the 8th International Conference on Head & Neck Cancer, Toronto, Canada, July 21-25, 2012.

ACKNOWLEDGMENTS

This study was supported in part by Health and Labour Sciences Research Grants for Clinical Cancer Research (H22-017 and H26-141) from the Ministry of Health, Labour and Welfare of Japan, the National Cancer Center Research and Development Fund (23-A-21 and 26-A-4) of Japan, and a Grant-in-Aid for Scientific Research (C) (KAKENHI 24592587) from the Ministry of Education, Culture, Sports, Science, and Technology of Japan.

REFERENCES

[1] Japan society for head and neck cancer, Cancer registry committee: Report of head and neck cancer registry of Japan clinical statistics of registered patients, 2012. Jpn J Head Neck Cancer 2014;40: supplement. http://www.jshnc.umin.ne.jp/pdf/2012syourei_houkoku.pdf

[2] Andrade MF, de Faria PR, Cardoso SV, Santos MR, Dias FL, Eisenberg AL, et al. Adenoid cystic carcinoma of the maxillary sinus: a clinical-pathological report of 10 years of experience from a single institution. Int J Oral Maxillofac Surg 2014;43:1313-8.

[3] Pommier P, Liebsch NJ, Deschler DG, Lin DT, McIntyre JF, Barker FG 2nd, et al. Proton beam radiation therapy for skull base adenoid cystic carcinoma. Arch Otolaryngol Head Neck Surg

2006;132:1242-9.

[4] van Weert S, Bloemena E, van der Waal I, de Bree R, Rietveld DH, Kuik JD,et al. Adenoid cystic carcinoma of the head and neck: a single-center analysis of 105 consecutive cases over a 30-year period. Oral Oncol 2013;49:824-9.

[5] Balamucki CJ, Amdur RJ, Werning JW, Vaysberg M, Morris CG, Kirwan JM, et al. Adenoid cystic carcinoma of the head and neck. Am J Otolaryngol 2012;33:510-8.

[6] Amit M, Binenbaum Y, Sharma K, Ramer N, Ramer I, Agbetoba A, et al. Adenoid cystic carcinoma of the nasal cavity and paranasal sinuses: a meta-analysis. J Neurol Surg B Skull Base 2013;74:118-25.

[7] Iseli TA, Karnell LH, Graham SM, Funk GF, Buatti JM, Gupta AK, et al. Role of radiotherapy in adenoid cystic carcinoma of the head and neck. J Laryngol Otol 2009;123:1137-44.

[8] Haddad RI, Posner MR, Busse PM, Norris CM Jr, Goguen LA, Wirth LJ, et al. Chemoradiotherapy for adenoid cystic carcinoma: preliminary results of an organ sparing approach. Am J Clin Oncol 2006;29:153-7.[9] Samant S, van den Brekel MW, Kies MS, Wan J, Robbins KT, Rosenthal DI, et al. Concurrent chemoradiation for adenoid cystic carcinoma of the head and neck. Head Neck 2012;34:1263-8.

[10] Robbins KT, Kumar P, Wong FS, Hartsell WF, Flick P, Palmer R, et al. Targeted chemoradiation for advanced head and neck cancer: analysis of 213 patients. Head Neck 2000;22:687-93.

[11] Robbins KT. The evolving role of combined modality therapy in head and neck cancer. Arch Otolaryngol Head Neck Surg 2000;126:265–9.

[12] Papaspyrou G, Hoch S, Rinaldo A, Rodrigo JP, Takes RP, van Herpen C, et al. Chemotherapy and targeted therapy in adenoid cystic carcinoma of the head and neck: a review. Head Neck. 2011;33:905-11.

[13] Wang CC, See LC, Hong JH, Tang SG. Nasopharyngeal adenoid cystic carcinoma: five new cases and a literature review. J Otolaryngol 1996;25:399-403.

[14] Seong SY, Hyun DW, Kim YS, Cho HJ, Lee JG, Yoon JH, et al. Treatment outcomes of sinonasal adenoid cystic carcinoma: 30 cases from a single institution. J Craniomaxillofac Surg 2014;42(5):e171-5. doi: 10.1016/j.jcms.2013.08.002. Epub 2013 Sep 9.

[15] Iyer NG, Kim L, Nixon IJ, Palmer F, Kraus D, Shaha AR,et al. Factors predicting outcome in malignant minor salivary gland tumors of the oropharynx. Arch Otolaryngol Head Neck Surg 2010;136:1240-7.

[16] Conley JJ, Casler JD. Adenoid Cystic Cancer of the Head and Neck. New York: Thieme, 1991.

[17] Homma A, Furuta Y, Suzuki F, Oridate N, Hatakeyama H, Nagahashi T, et al. Rapid superselective high-dose cisplatin infusion with concomitant radiotherapy for advanced head and neck cancer. Head Neck 2005;27:65-71.

[18] Douglas JG, Laramore GE, Austin-Seymour M, Koh W, Stelzer K, Griffin TW, et al. Treatment of locally advanced adenoid cystic carcinoma of the head and neck with neutron radiotherapy. Int J Radiat Oncol Biol Phys 2000;46:551-7.

[19] Mizoe JE, Hasegawa A, Jingu K, Takagi R, Bessyo H, Morikawa T, et al. Results of carbon ion radiotherapy for head and neck cancer. Radiother Oncol 2012;103:32-7.

[20] Morimoto K, Demizu Y, Hashimoto N, Mima M, Terashima K, Fujii O, et al. Particle radiotherapy using protons or carbon ions for unresectable locally advanced head and neck cancers with skull base invasion. Jpn J Clin Oncol. 2014;44:428-34.

Figure Legend

Figure 1.

Kaplan-Meier analysis of overall survival, local control, and disease-free survival in patients with ACC.

Figure 2.

MRI findings for a 60-year-old female with ACC of the base of tongue (T4aN0M0) are shown (a). Angiography suggested that the right lingual artery was the main artery supplying the tumor (b), and the left lingual artery also contributed in part. Cisplatin was infused into these arteries using each procedure. A post-treatment MRI shows the absence of any tumor (c). Multiple lung metastases appeared 3 years and 6 months after the first visit. She subsequently developed a primary recurrent tumor (e) 8 years and 4 months after the first visit, and died 9 years and 8 months after the first visit.

Figure 1

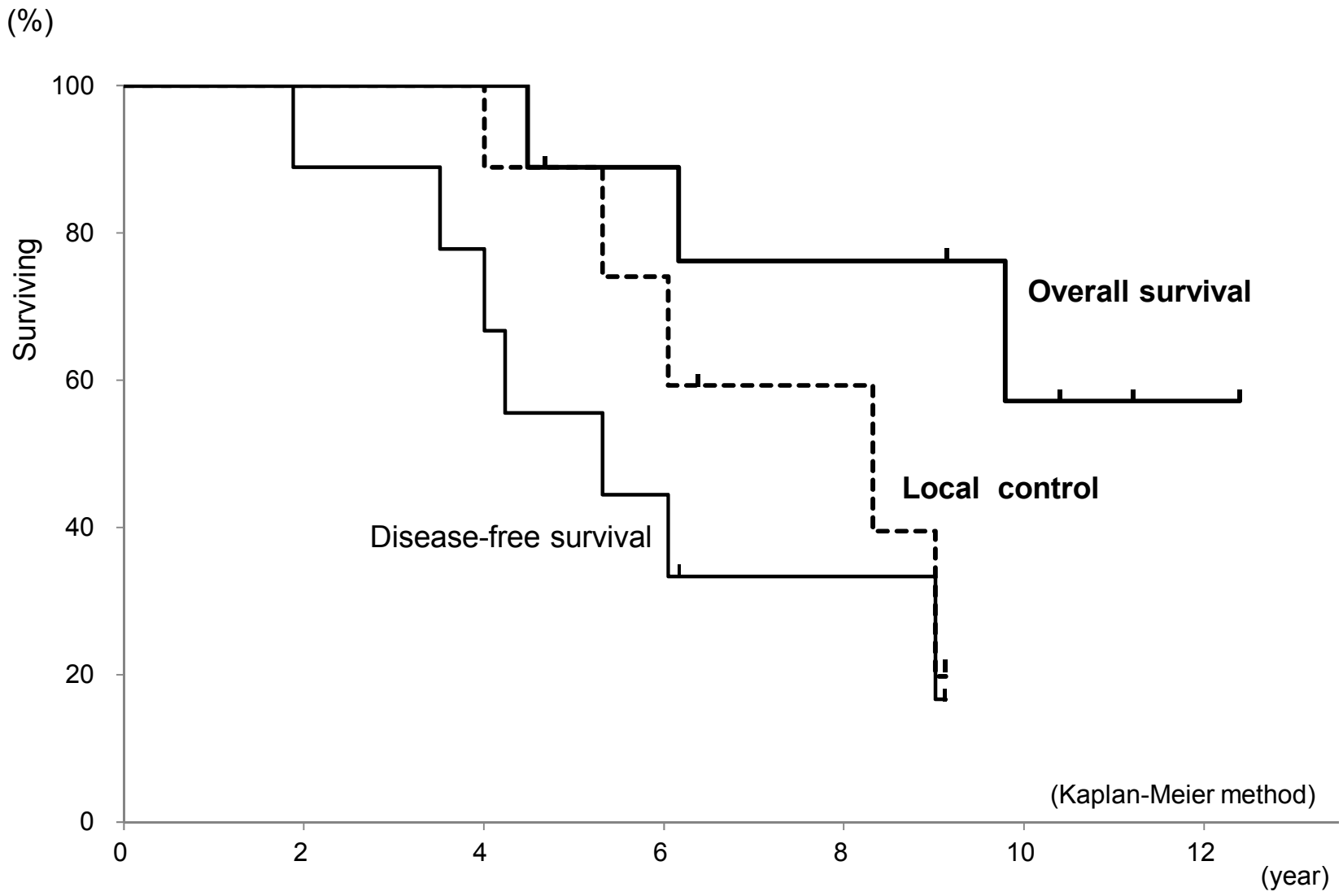
(%)
100
80
60
40
20
0
Surviving
Overall survival
Local control
Disease-free survival
(Kaplan-Meier method)
0
2
4
6
8
10
12
(year)

Figure 2

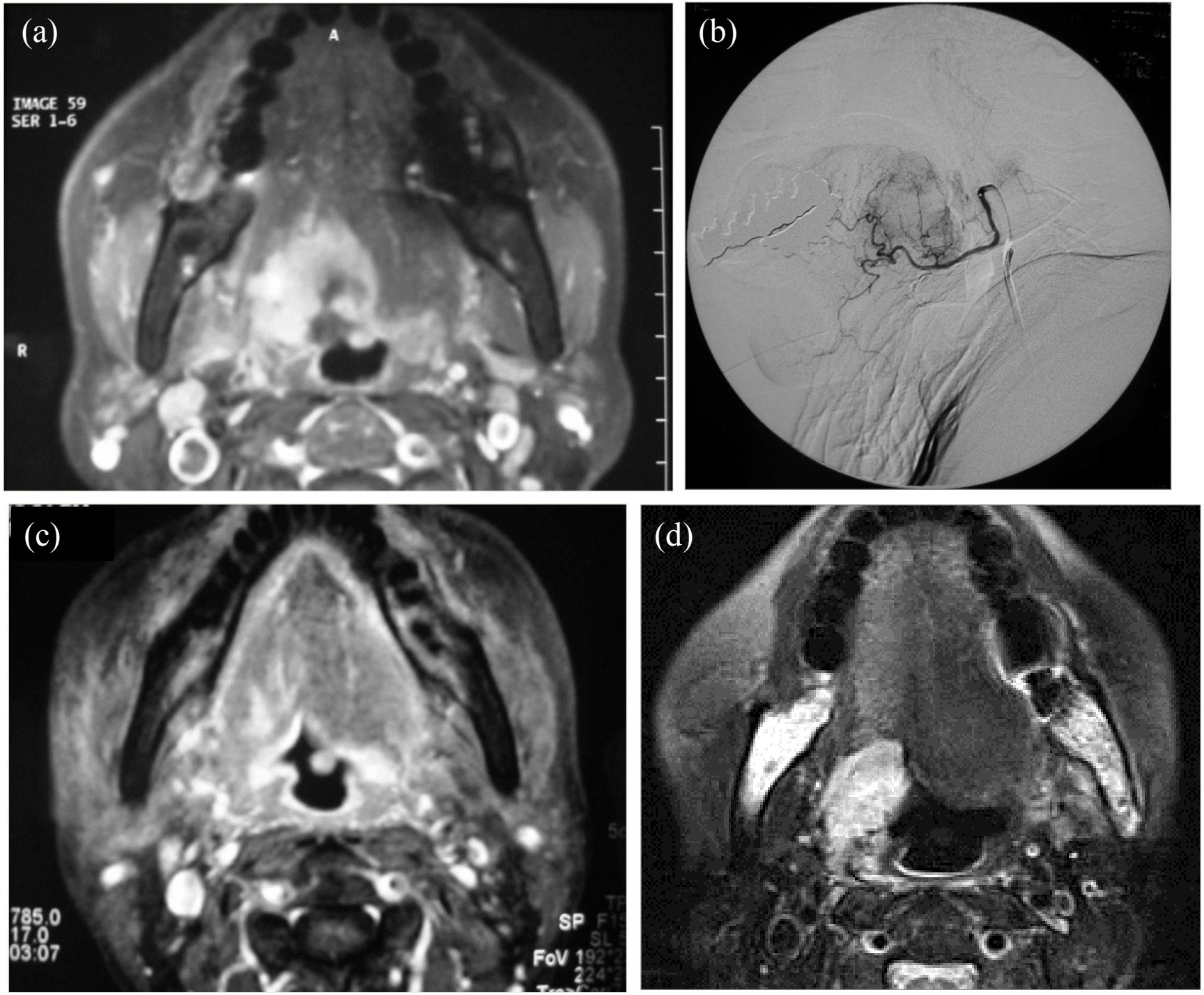

Table 1. Patient characteristics and outcome

No	Age	Sex	Stage	Site	Recurrence	Current status (follow-up)
1	60	F	T4aN0M0	base of tongue	Lung 3y6m, Primary 8y4m	DOD 9y8m
2	55	F	T2bN0M0	nasopharynx	Primary 9y	AWD 12y5m
3	55	M	T4bN0M0	maxillary sinus	Primary 4y, Lung 4y	DOD 6y2m
4	26	F	T4aN0M0	base of tongue	Primary 5y4m, Lung 8y	AWD 11y2m
5	70	F	T4aN0M0	maxillary sinus	-	NED 9y2m
6	53	F	T3N0M0	nasopharynx	Primary 6y1m	AWD 10y5m
7	57	F	T3N0M0	base of tongue	Lung 4y3m	DOD 4y6m
8	67	F	T2N2bM0	base of tongue	-	NED 6y5m
9	39	F	T4aN0M0	base of tongue	Lung 1y11m	AWD 4y8m

DOD: died of disease, AWD: alive with disease, NED: no evidence of disease