Early and long-term morbidity after minimally invasive total laryngo-pharyngo-esophagectomy with gastric pull-up reconstruction via thoracoscopy, laparoscopy and cervical incision.

Akihiro Homma[1], Yuji Nakamaru[1], Hiromitsu Hatakeyama[1], Takatsugu Mizumachi[1], Satoshi Kano[1], Jun Furusawa[1], Tomohiro Sakashita[1], Toshiaki Shichinohe[2], Yuma Ebihara[2], Satoshi Hirano[2], Hiroshi Furukawa[3], Toshihiko Hayashi[3], Yuhei Yamamoto[3], Satoshi Fukuda[1]

[1]Department of Otolaryngology- Head and Neck Surgery, [2]Gastroenterological Surgery II, and [3]Plastic and Reconstructive Surgery, Hokkaido University Graduate School of Medicine, Sapporo, Hokkaido, Japan

Corresponding author: Akihiro Homma;

Department of Otolaryngology – Head & Neck Surgery, Hokkaido University Graduate School of Medicine

Kita 15, Nishi 7, Kita-ku, Sapporo 060-8638, Japan

Phone: +81-11-706-5958; Fax: +81-11-717-7566;

E-mail: ak-homma@med.hokudai.ac.jp

ABSTRACT

Total laryngo-pharyngo-esophagectomy (TLPE) with gastric pull-up reconstruction is still considered to be associated with major complications and a significant risk of in-hospital death. Minimally invasive esophagectomy, avoiding thoracotomy and laparotomy, has been increasingly performed for esophageal malignancies with the hope of reducing mortality and morbidity, such as pulmonary complications. The aim in this study was to assess early and long-term morbidity as well as treatment outcomes in patients treated with TLPE with gastric pull-up reconstruction via thoracoscopy, laparoscopy and cervical incision. From 2004 to 2013, 10 patients with a median age of 64 years (range, 47-71 years) underwent minimally invasive TPLE with gastric pull-up reconstruction. Seven of the 10 patients had previously received radiotherapy. As for early postoperative complications, no patient died during the early postoperative period, and pneumonia was observed in 1, skin necrosis in 1, pseudomembranous enterocolitis in 1, arrhythmia in 2, hemorrhage in the neck in 2, anastomotic leakage in the neck in 3, and tracheal necrosis in 6 patients. Three patients developed tracheostomal stenosis as a long-term postoperative complication, and an anastomotic stricture was observed in one patient. All patients were able to achieve oral intake, but 3 patients required feeding tube support. In conclusion, postoperative systemic complications during the early postoperative period were considered to be acceptable, although wound complications such as tracheal necrosis and anastomotic leakage were commonly observed. Therefore, this minimally invasive procedure might help reduce mortality and morbidity in patients requiring TLPE with gastric pull-up reconstruction.

Key words: cervical esophageal cancer, hypopharyngeal cancer, postoperative complication, minimally invasive esophagectomy

Total laryngo-pharyngo-esophagectomy (TLPE) together with gastric pull-up reconstruction, which involves surgery to a wide area including the neck, chest and abdomen, remains a major surgical challenge. Recently, minimally invasive esophagectomy (MIE), which avoids the need for thoracotomy and laparotomy, has been increasingly performed for esophageal malignancies in the hope of reducing mortality and morbidity, such as pulmonary complications [1,2]. Several studies have reported on the complications and survival in patients undergoing TLPE together with gastric pull-up reconstruction [3-6]. However, these reports did not mention whether the esophagectomy was performed via an open or endoscopic approach. Based on the period in which the treatments were performed, we speculate that the surgery proceeded via a transhiatal or transthoracic esophagectomy with laparotomy. Further, there have been no reports of TPLE with gastric pull-up being performed both thoracoscopically and laparoscopically in a group of patients. At our institute, we have been performing this procedure for over ten years and, therefore, we have been able to assess the early and long-term morbidity as well as treatment outcomes in patients undergoing TLPE with gastric pull-up reconstruction via thoracoscopy, laparoscopy and cervical incision.

PATIENTS AND METHODS

Between 2004 and 2013, ten patients underwent TLPE with gastric pull-up reconstruction via thoracoscopy, laparoscopy and cervical incision for double cancers of the hypopharynx and thoracic esophagus (n=2), cervical esophageal cancer (n=5), or hypopharyngeal cancer with esophageal extension (n=3) (Table 1). Patients consisted of 8 males and 2 females, with a median age of 64 years (range 47-71 years). One patient

received total laryngectomy due to laryngeal cancer prior to the development of hypopharyngeal cancer. Seven patients had previously received radiotherapy, with five of the 7 patients receiving radiotherapy with or without chemotherapy for hypopharyngeal or cervical esophageal cancer, and 2 receiving postoperative radiotherapy for laryngeal cancer or oral cavity cancer. All of the cancers mentioned above were squamous cell carcinomas.

Three patients were unable to obtain adequate oral intake prior to surgery due to esophageal stenosis resulting from esophageal cancer (n=2) or chemoradiotherapy (n=1). In addition, one patient, who previously underwent total laryngectomy with bilateral neck dissection and postoperative radiotherapy, was unable to obtain oral intake due to a pharyngo-cutaneous fistula resulting from the previous surgery (n=1). This patient had undergone hypopharyngectomy due to hypopharyngeal cancer, resulting in a circumferential pharyngeal defect. A free jejunum transfer could not be indicated as there were no vessels with which to anastomose with vessels of a free jejunal flap in the neck due to the prior surgery and radiotherapy. Therefore, the pharynx was reconstructed using a pectoral major musculocutaneous flap; however, this resulted in anastomotic leakage and prevented oral intake. The remaining 6 patients were able to obtain adequate oral intake, but 3 of them required opioids for pain on swallowing. One patient received a tracheostomy due to airway compromise.

All 10 patients underwent reconstruction by gastric pull-up, and a free jejunal flap was also used in 1 patient. The grafts used were whole stomach (n=2), subtotal gastric tube (n=5), slender gastric tube (n=1), elongated stomach roll (n=1), and stomach roll with free jejunal flap (n=1), and the grafts were passed through the posterior

mediastinum (n=8), retrosternum (n=1), or antesternum (n=1). One patient (case 4) underwent reconstruction by gastric pull-up and a free jejunal flap as the stomach roll did not reach the stump of the pharynx. Although the design of the grafts and routes through which they passed were decided on the basis of the specific characteristics of each case and the surgeons' discretion, grafts were generally constructed from the subtotal gastric tube and passed through the posterior mediastinum. At least one lobe of the thyroid gland was left in contact with the trachea to avoid tracheal necrosis in 7 patients.

Postoperative complications, such as tracheal necrosis, skin necrosis, anastomotic leakage and hemorrhage, were divided into severe and mild groups. The severe groups included patients who required additional surgery in an operating room and those who required more than one month to recover. The mild groups consisted of patients to whom the above criteria did not apply. Complications were categorized as early (≤30 days postoperatively) or late (>30 days postoperatively).

RESULTS

As for early postoperative complications, no patient died during the early postoperative period, and pneumonia was observed in 1, arrhythmia in 2, anastomotic leakage in the neck in 3, tracheal necrosis in 6, and hemorrhage (severe) in the neck in 2 patients (Table 2). Two patients who experienced bleeding developed severe anastomotic leakage. One of the two experienced bleeding from the external carotid artery; however, his fistula closed spontaneously thereafter. The other patient experienced bleeding from the stump of the pharynx due to an infection in the surrounding tissue resulting from

anastomotic leakage, and the pharynx was reconstructed using a pectoral major musculocutaneous flap. One patient who suffered from crust formation on his trachea 3cm inferiorly from the tracheostoma for more than 2 months was among the 6 patients who developed tracheal necrosis. The five other patients who developed tracheal necrosis near the tracheostoma but involving an area of less than 1 cm needed only debridement. Skin necrosis (mild) and pseudomembranous enterocolitis were observed in one patient each in the early postoperative period. Three patients developed tracheostomal stenosis as a long-term postoperative complication and anastomotic stricture was also observed in one patient. All patients were able to achieve oral intake, although 3 patients required feeding tube support.

The follow-up period after surgery for surviving patients ranged from 8 to 23 months (median, 22 months). The three-year overall survival rate, calculated by the Kaplan-Meier method, was 64.3% (Figure 1). Two patients died of neck recurrence and distant metastasis without primary site recurrence, one patient died of an unknown cause, and 2 patients died of lung cancer. The lung cancers in these patients were confirmed pathologically not to have metastasized from either the previous head and neck or esophageal cancer. Five patients currently remain alive without disease, except for one patient with lung metastasis. No patient received a tracheo-esophageal shunt, and all of them communicate using an electrolarynx or through writing.

DISCUSSION

Carcinoma of the cervical esophagus has a poor prognosis, with 3- and 5-year survival rates reported to range from 18 to 35.4% and from 12 to 33%, respectively [7].

Similarly, hypopharyngeal cancer with esophageal extension also has a poor prognosis, and is staged as T4. Recent progress with concurrent chemoradiotherapy (CCRT) for patients with locally advanced head and neck or thoracic esophageal cancer has motivated many physicians to treat cervical esophageal cancer with initial CCRT. For most patients with cervical esophageal cancer, radical surgery has mandated simultaneous total laryngectomy. Therefore, most patients with cervical esophageal cancer prefer CCRT to surgery due to the potential for laryngeal preservation [8]. In reality, however, not a few patients have experience a residual or recurrent tumor after CCRT. Even if the tumor is successfully controlled by CCRT, pharyngeal or esophageal stricture can be a late complication at the tumor site [9] as the postcricoid area and cervical esophagus are anatomically narrow. Surgery is often indicated after CCRT for such patients, while for patients with previously irradiated hypopharyngeal, cervical esophageal or other head and neck cancer, surgery is the only curative option. Therefore, we focused on total laryngo-pharyngo-esophagectomy (TLPE) with gastric pull-up reconstruction for such patients.

Minimally invasive esophagectomy (MIE) has been introduced with the hope of reducing mortality and postoperative systemic complications, such as pulmonary infection. A prospective randomized controlled trial for patients with resectable cancer of the esophagus or gastro-esophageal junction was performed to compare open esophagectomy (n=56) and MIE (n=59) [1]. Sixteen patients (29%) in the open esophagectomy group developed pulmonary infection in the first 2 weeks compared with 5 (9%) in the MIE group (~~relative risk [RR] 0·30, 95% CI 0·12–0·76;~~ p=0.005). ~~Further, nineteen patients (34%) in the open esophagectomy group developed~~

~~pulmonary infection in-hospital compared with 7 (12%) in the MIE group (0·35, 0·16–0·78; p=0·005).~~ The authors concluded that this finding~~these findings~~ provides evidence for the short-term benefits of MIE for patients with resectable esophageal cancer. Additionally, MIE preserved quality of life (QOL) better than did open esophagectomy, with QOL measurements taken 6 weeks after surgery better for patients in the MIE group than for those in the open esophagectomy group. QOL measurements were not performed in this study, but we felt the early postoperative status of the patients included in this study was better than that in the early period of patients in the open surgery group in our institution, although no QOL data were obtained for that group either.

As for postoperative complications after TLPE with gastric pull-up reconstruction, the in-hospital mortality rate was previously reported to be 0-16% [4,5,6,10]. In this study, no patient died during the early postoperative period, although one patient died at home 3 months after surgery due to an unknown cause. As for postoperative pulmonary infection after TLPE, it was previously reported to be 10-26% [5, 6,10]. We found that 1 out of 10 patients (10%) in this study had pneumonia in the early postoperative period, although 9 out of 10 patients received mediastinal dissection simultaneously. This rate was thought to be low in comparison to the figures for post TLPE complications reported previously and we considered that this was due to MIS. Early postoperative complications were reported in detail by Shuangba et al, who reported the outcomes for 208 patients after TLPE with gastric pull-up reconstruction [6]. With regard to early postoperative thoraco-abdominal complications, pneumonitis was observed in 23 (11.1%), pleural effusion in 15 (7.2%), chylous fistula in 4 (1.9%),

heart failure in 4 (1.9%), hemoperitoneum in 2 (1%), and burst abdomen in 2 patients (1%). In this study, the only thoraco-abdominal complications observed involved arrhythmia in 2 patients (20%) and pneumonia in 1 patient (10%). It was difficult to compare the two studies, but the results of our study appear to be roughly comparable to Shuangbas' report. ~~Quality of life measurements were not performed in this study, but we felt the early postoperative status of the patients included in this study was better than that in the early period of patients in the open surgery group in our institution, although no QOL data were obtained for that group either.~~

Tracheal necrosis and anastomotic leakage most commonly appeared in the early postoperative period. We consider tracheal necrosis to be one of the most frequent and difficult problems to resolve. The cervical trachea receives its blood supply primarily from branches of the inferior thyroid artery, and the lower cervical trachea is supplied from the tracheoesophageal branch of the subclavian artery [11]. The superior thyroid artery does not extend any direct branches to the trachea. However, it is anastomosed with the inferior thyroid artery in and around the thyroid gland. The extreme distal thoracic trachea is always supplied by the bronchial artery. The rest of the blood supply is derived from the innominate-subclavian system. Thorough bilateral paratracheal dissection usually results in the sacrifice of the bilateral inferior thyroid arteries, although we try to leave the thyroid gland in contact with the trachea where possible. However, in this study, we found that 5 patients developed mild tracheal necrosis, so maintaining contact between the thyroid gland and the trachea was not sufficient to prevent tracheal necrosis. In patients with hypopharyngeal and esophageal cancer, thorough paratracheal dissection should be performed. Although preservation of the

blood supply to trachea from the inferior thyroid arteries results in incomplete dissection and might increase the risk of recurrence, it is preferable in order to preserve the blood supply to trachea from the inferior thyroid arteries. Therefore, the question of whether or not to preserve the blood supply to the trachea from the inferior thyroid arteries depends on the specific conditions in each individual case. Further, although the trachea is usually freed from the aorta by preserving the left bronchial arteries, the right bronchial artery is sacrificed during the esophagectomy. We now consider that recent progress in endoscopic surgery enables us to preserve the right bronchial artery. We expect that this will aid in preventing tracheal necrosis in future.

Anastomotic leakage developed in 3 patients who previously underwent irradiation. We speculate that this was due to the lack of blood supply to the graft and to delays in wound healing after the previous radiotherapy. The reason for the lack of blood supply to the graft was considered to involve the design, length and route of the graft. Stress on the suture lines also led to a lack of blood supply to the graft and anastomotic leakage. Reconstruction by gastric pull-up and free jejunal transfer might be one answer to these problems. We speculate that it would enable reconstruction with less stress, and might provide better blood supply to gastric grafts as well as aid in preventing anastomotic leakage.

Surgery following radiotherapy remains a technical challenge. In this series, 7 of the 10 patients had received previous radiotherapy. As a result, severe postoperative complications developed in 3 patients of 7 previously irradiated patients. However, they were all manageable and no patients died in the early postoperative period, partly because this surgical procedure is relatively simple in terms of both the surgical

resection and reconstruction. Therefore, while the surgery is still considered a procedure associated with major complications, complications involving the wound were relatively mild due to the fact that there were no dead spaces or anastomosis in the thorax as the gastric tube, which is larger than the esophagus, filled the thoracic defect and the suture line in this procedure was located in the neck area. These aspects are speculated to aid in minimizing morbidity while limiting complications.

As for treatment outcome, only 2 patients died of disease. Both patients had neck lymph node and distant metastasis. No patient developed primary site recurrence as this procedure removes the pharynx as well as the whole esophagus with surgical margins sufficient for primary site resection. In addition, no patient developed recurrence in the mediastinum. Based on this result, the procedure involving the mediastinum was considered to be performed appropriately. Two patients also died of lung cancer, and 2 patients had other head and neck cancers before surgery. Further, 2 patients received TLPE due to double cancers of the hypopharynx and thoracic esophagus. Therefore, a total of 6 patients had more than one cancer in the upper aerodigestive tract. All of them had histories of smoking and alcohol consumption, which is a problem that concerns every head and neck cancer patient. However, although follow-up period was short, 4 patients currently remain alive without disease despite such patients generally having a poor prognosis. To be honest, the postoperative quality of life of these patients is poor, with patients not being able to speak and all of them suffering from postgastrectomy syndrome and other sequelae. However, we would like to stress that while the 4 patients did not have oral intake preoperatively, all achieved oral intake after surgery. If patients cannot or will not swallow due to the presence of a tumor, this procedure is worthwhile.

In conclusion, no patient died during the early postoperative period and postoperative systemic complications such as pneumonia were considered to be equal to or less than other reports, although postoperative wound complications such as tracheal necrosis and anastomotic leakage were commonly observed in the early postoperative period. Further, to clarify the benefits of this procedure, QOL measurements are required in the early postoperative period. TLPE with gastric pull-up reconstruction is still considered a procedure associated with major complications and a significant risk of in-hospital death, but this minimally invasive procedure might help reduce mortality and morbidity in patients requiring TLPE with gastric pull-up reconstruction.

ACKNOWLEDGMENTS

This study was supported in part by Health and Labour Sciences Research Grants for Clinical Cancer Research (H22-017 and H26-141) from the Ministry of Health, Labour and Welfare of Japan, the National Cancer Center Research and Development Fund (23-A-21 and 26-A-4) of Japan, and a Grant-in-Aid for Scientific Research (C) (KAKENHI 24592587) from the Ministry of Education, Culture, Sports, Science, and Technology of Japan.

AUTHOR DISCLOSURE STATEMENT

No competing financial interests exist.

REFERENCES

1. Biere SS, van Berge Henegouwen MI, Maas KW, et al (2012) Minimally invasive versus open oesophagectomy for patients with oesophageal cancer: a multicentre, open-label, randomised controlled trial. Lancet 379:1887-1892

2. Mamidanna R, Bottle A, Aylin P, Faiz O, Hanna GB (2012) Short-term outcomes following open versus minimally invasive esophagectomy for cancer in England: a population-based national study. Ann Surg 255:197-203

3. Triboulet JP, Mariette C, Chevalier D, Amrouni H (2001) Surgical management of carcinoma of the hypopharynx and cervical esophagus: analysis of 209 cases. Arch Surg 136:1164-1170

4. Sreehariprasad AV, Krishnappa R, Chikaraddi BS, Veerendrakumar K (2012) Gastric pull up reconstruction after pharyngo laryngo esophagectomy for advanced hypopharyngeal cancer. Indian J Surg Oncol 3:4-7

5. Keereweer S, de Wilt JH, Sewnaik A, Meeuwis CA, Tilanus HW, Kerrebijn JD (2010) Early and long-term morbidity after total laryngopharyngectomy. Eur Arch Otorhinolaryngol 267:1437-1444

6. Shuangba H, Jingwu S, Yinfeng W, et al (2011) Complication following gastric pull-up reconstruction for advanced hypopharyngeal or cervical esophageal carcinoma: a 20-year review in a Chinese institute. Am J Otolaryngol 32:275-278

7. Daiko H, Hayashi R, Saikawa M, et al (2007) Surgical management of carcinoma of the cervical esophagus. J Surg Oncol 96:166-172

8. Uno T, Isobe K, Kawakami H, et al (2007) Concurrent chemoradiation for patients with squamous cell carcinoma of the cervical esophagus. Dis Esophagus 20:12-18

9. Lee WT, Akst LM, Adelstein DJ, et al (2006) Risk factors for hypopharyngeal/upper esophageal stricture formation after concurrent chemoradiation. Head Neck 28:808-812

10. Hartley BE, Bottrill ID, Howard DJ (1999) A third decade's experience with the gastric pull-up operation for hypopharyngeal carcinoma: changing patterns of use. J Laryngol Otol 113:241-243

11. Salassa JR, Pearson BW, Payne WS (1977) Gross and microscopical blood supply of the trachea. Ann Thorac Surg 24:100-107

Figure Legend

Figure 1. Overall survival curve

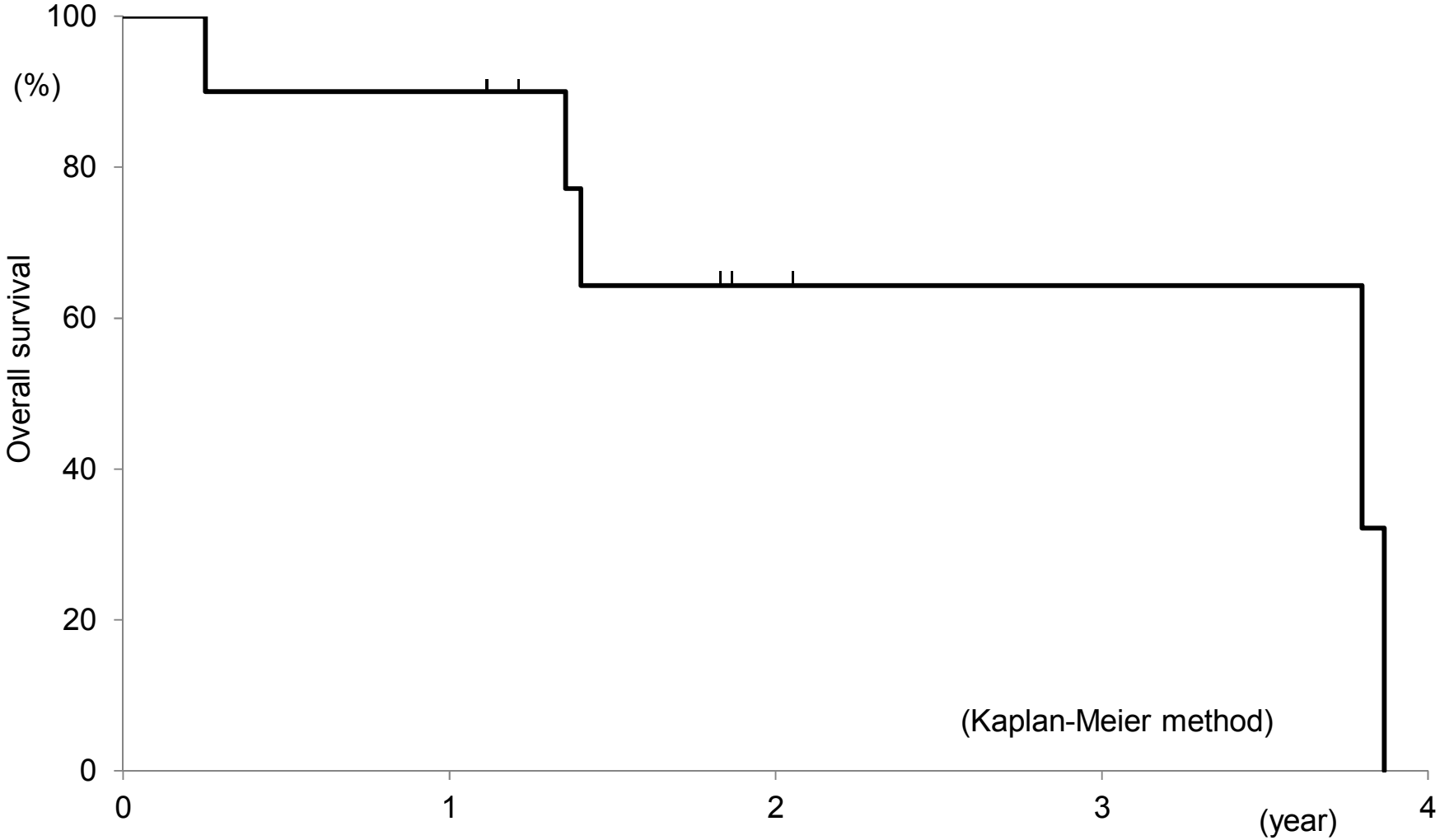
100
(%)
80
60
40
20
0
Overall survival
(Kaplan-Meier method)
0
1
2
3
4
(year)

Table 1. Patient characteristics , treatment, and outcome

No.	Age/Sex	Site/cStage	RT	oral intake (pre-op)	opioid use	tracheos tomy	thyroid left in contact with trachea	reconstruction route	postoperative complications	oral intake (post-op)	outcome follow-up period (months)
1	58/M	hypopharynx T3N2bM0 thoracic esophagus T1bN0M0	no	yes	yes	no	left	elongated stomach roll mediastinum	tracheal necrosis(mild)	yes (+tube sup)	dead 47
2	68/F	esophagus (Ce) T3N0M0	no	no	no	no	none	slender gastric tube retrosternum	arrhythmia, tracheostomal stenosis	yes (+tube sup)	alive 22
3	47/M	hypopharynx T4aN2bM0 + esophageal extension	yes	yes	yes	no	both	whole stomach mediastinum	anastomotic leakage(severe), hemorrhage(severe)	yes	dead 17
4	70/F	esophagus (Ce) T4N1M1	yes	no	no	yes	left	subtotal gastric tube + free jejunum antesternum	pneumonia, skin necrosis in the neck(mild), tracheal necrosis(mild), tracheostomal stenosis	yes	dead 46
5	61/M	esophagus (Ce) T4N1M0	yes	yes	no	no	none	subtotal gastric tube mediastinum	tracheal necrosis(mild)	yes	dead 17
6	69/M	esophagus (Ce) T4bN2M0	yes	no	no	no	right	subtotal gastric tube mediastinum	tracheal necrosis(severe), tracheostomal stenosis	yes	dead 3 (unknown)
7	57/M	hypopharynx T1N2bM0 + esophageal extension (at recurrence)	yes	yes	no	no	both	subtotal gastric tube mediastinum	arrhythmia, tracheal necrosis(mild)	yes	alive 25
8	59/M	esophagus (Ce) T3N1M0	yes (for oral cavity ca)	yes	yes	no	none	subtotal gastric tube mediastinum	hemorrhage(severe), gastric tube necrosis, anastomotic leakage(severe)	yes	alive 20
9	71/M	hypopharynx T4N0M0 + esophageal extension	yes (for laryngeal ca)	no	no	yes (TL)	right	whole stomach mediastinum	anastomotic leakage(mild), anastomotic stricture	yes (+tube sup)	alive 15
10	70/M	hypopharynx T2N0M0 + thoracic esophagus T2N0M0	no	yes	no	no	left	subtotal gastric tube mediastinum	pseudomembranous enterocolitis	yes	alive 11(lumg meta)

Ce: cervical, tube sup: feeding tube support

Table 2. Postoperative complications

	complication	n
Early		
	tracheal necrosis	6
	mild	5
	severe	1
	anastomotic leakage	3
	mild	1
	severe	2
	arrhythmia	2
	hemorrhage (severe)	2
	pneumonia	1
	skin necrosis in the neck (mild)	1
	pseudomembranous enterocolitis	1
Late		
	tracheostomal stenosis	3
	anastomotic stricture	1