# A MORPHOLOGICAL STUDY ON THE GASTRIC GLAND CELLS IN *HYNOBIUS* WITH SPECIAL REFERENCES TO NUCLEAR ACTIVITY

BY

**TEIJIRO HAYASHI**

(With 2 Text Figures and 2 Plates)

# 山椒魚胃中の分泌細胞の研究、特に其の核に就いて

林　禎　二　郎

## Introduction

In a previous paper on the poisonous glands of *Hynobius lichenatus*, BOUL.,* it was observed, that during the activity of the gland cells, the nuclei have an exceedingly important function on the new formation of the poisonous granules within cytoplasm. Furthermore, while studying the gastric gland cells of *Hynobius lichenatus*, the author has recently lighted upon some evidences, leading him to believe also in the nuclear secretions of these gland cells.

The secretive activities of nuclei in gland cells, however, were already observed by many authors; namely MARSHALL and VORHIES (1906), MAZIARSKI (1911), NAKAHARA (1917), KINNEY (1926), NOEL and PAILLOT (1927), BEAMS and WU (1929) and WU (1930) respectively on the spinning glands of insect larvae, and GARDIER (1927), GRESSON (1929) and MEHTA (1930) each on the insect oogenesis.

* Synonym of *H. retardatus* DUNN.

[Transact. Sapporo Nat. Hist. Soc., Vol. XI, Pt. 4. March, 1931]

Recently JACOBS (1929) published his studies on the gland of midgut of *Astacus leptodactylus*, stating that "Unabhängig von diesen Sekretbildungsvorgängen kommt oft, höchstwahrscheinlich in enger Beziehung zum Zellkern (Ausstossung von Nukleolensubstanz) die Bildung von sogenannten „Parasomen" vor; diese bleiben in Ein- und Mehrzahl gewöhnlich dicht distal vom Kern liegen".

The above mentioned observations are so far the important studies which have been made in the recent years concerning the interrelation between nucleus and the secretory granules of a gland cell. So far as I am aware there are but few contributions to literature on the gastric glands of the animals in this field, except, the remarkable observation by MA (1928) on the mitochondrial contents of the gastric glands of domestic animals. According to him, the zymogen granules of the gland cells are directly derived from the filamentous mitochondria by fragmentation of the granules. Though such mitochondrial theory of the secretory granules has been supported hitherto by many observations, quite recently WU (1930) described how in the spinning gland cells of Galleria mellonella, the mitochondria shows a negligible function in silk secretion.

Now with a view to determine the secretory questions of nuclei I have carried out the cytological study on the gastric gland of *Hynobius lichenatus* which stands very low in the zoological scale in many respects.

## Material and Methods

The material employed was a species of Urodela, *Hynobius lichenatus* BOUL., which is found abundantly in Hokkaido. The animal was kept in our laboratory, being fed artificially with small pieces of fish flesh, meat and insects. As the animal has preserved its health well, I could observe the normal tissues of the stomach which contained the food materials in it.

For fixation Gilson's fluid and Zenker's fluid were employed and for staining either the Delafield's haematoxylin-eosin method or Mallory's connective tissue stain method was used.

The method for the mitochondrial study was as follows: Fixed in the

mixture of 80 parts of 3% aqueous solution of potassium dichromate and 20 parts of neutral formalin for two days, changing the fluid every day. Then washed the tissue a few seconds in distilled water and transferred into the mixture which contained in equal parts acet. pyrolignosum rect. and 1% aqueous solution of chromic acid, to remain for 24 hours. Then continued the chromation in 3.5% potassium dichromate solution for three days changing the fluid every day. Next washed in running water for 24 hours. After cutting in paraffin stained the sections with Heidenhain's iron-haematoxylin.

## General observations

The gastric wall of *Hynobius* consists of four membranes as other vertebrates as follows; mucous, submucous, muscular and serous membranes (Text fig. 1).

The mucous membrane which makes the innermost coat of the stomach and includes the true functional cells for digestion, is divided into three layers; the epithelial layer (e), tunica propria (t.p) and muscularis mucosae (m.m). The epithelium of the membrane consists of tubular glands of various length and the epithelial cells. Tunica propria is the tissue which contains connective fibres arranged loosely making a reticular structure. It was an areolar appearances being provided with blood vessels or capillaries. In muscularis mucosae we can find two kinds of muscular bundles; the inner circular and the outer longitudinal layers of plain

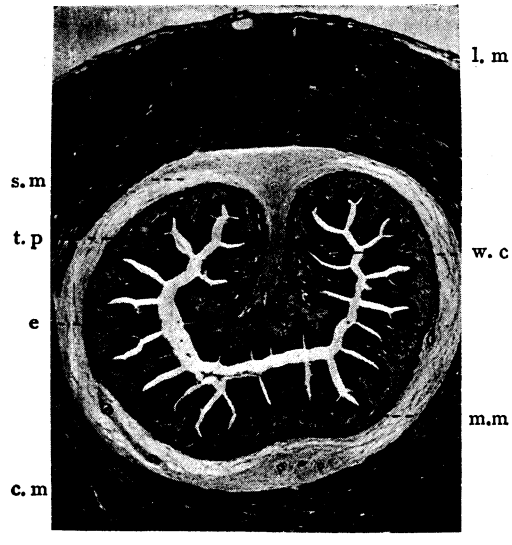


**Fig. 1.**

Cross-section of the pylorus region, surface epithelium (e); Muscularis mucosae (m); circular (c.m) and longitudinal (l.m) muscle bundles of muscular membrane; submucosa (sm); wandering cell (w.c). ×40

muscular fibres. As OPPEL (1896) described the mucous membrane of the amphibian stomach is divided into two areas, the anterior and the posterior regions. These are characterised by the distribution of the special glands, the former being occupied by the proper gastric glands (gl. gastricae), while the latter includes the pylorus glands (gl. pyloricae).

The submucosa (Text figure 1. s.m) consists of loosely arranged fibres of connective tissue with some elastic fibres. In this layer there are again many blood vessels besides nervous fibres and lymphaticus.

The muscular membrane comprises large bundles of the plane muscle fibres which make the inner circular (Text fig. 1, c.m) and the outer longitudinal (Text fig. 1, l.m) layers. In *Hynobius* in the pylorus region of the stomach, the inner circular muscle bundle occupies a greater part of the gastric wall, the outer longitudinal muscle bundle becoming minor, while in the anterior fundus region both develop equally.

At present the author confines himself to the study of the epithelial cells which take a direct part in the gastic secretion.

## I. Surface epithelium

The free surface of the gastric mucous membrane is covered with a single layered columnar epithelium (Text fig. 1, e) in which we can distinguish three kinds of cells of different structure, that is the ciliated epithelial cells, the ordinary mucous cells and the goblet cells.

### i. The ciliated epithelial cells (Fig. 1)

The ciliated epithelial cells of the stomach of Urodela were alreadv observed by SCHULTZE (1867). They were also found by PARTSCH (1877) and recently by ROGOSINA (1930) existing in the fish stomach. In the mucous membrane of *Hynobius lichenatus*, these ciliated columnar cells are found usually in the anterior part of the stomach. In the posterior pylorus region, most parts of the free surface are covered only by the ordinary mucous cells (Text fig. 1).

The ciliated cell shows a pyramid in shape and is somewhat greater than ordinary mucous cells. Its apical pole directs to the basement membrane. The cilia are stained weak reddish with Delafield's haematoxylin-eosin and the base-

ment granules of the cilia are stained deep purple. The nuclei in the cells occur in the broad cytoplasmic part of the pyramid and show either oval or long oval form. In the ordinary mucous cells, however, they occupy generally the basal part leaving a large space in the cytoplasm. Therefore the nuclear rows of the ciliated cells are seen more superficially than those of the mucous cells. From this we can easily distinguish the occurrence of the cells. There are usually two or three large nucleoli within the nucleus among numerous chromatin granules in the ciliated cells.

Sometimes, surrounding these oval nuclei there appears a clear zone, especially in the supranuclear part of the cytoplasm, and in addition to this by the mitochondrial method the fine granular bodies are often observed outside of the clear zone. Such a clear zone appears not only in the ciliated cells but also in the other kind of gland cells of the mucous membrane, perhaps as an indicator of the nuclear secretion which the writer will describe in detail later in this paper.

### ii. The ordinary mucous cells

The ordinary mucous cells are found most frequently in the surface epithelium of the stomach. The cells are possessed of the typical columnar forms. On the distal surface which is usually broad, there is always some amount of secretion which is stained either deep blue with Mallory's stain (Fig. 3) or grayish black with Heidenhain's iron-haematoxylin. The amount of secretion, as well as its staining capacity is variable according to the phases of the physiological activity of the cells. In the early stage of secretion there appear some granules on the surface of the cells. The granules show an intensive staining capacity. In a later stage the secretion becomes homogeneous and the affinity to any staining reagent is a little reduced. The present author could find neither the networks of fibrous structure nor the hyaline substances in the nucleus of the columnar epithelium which were once described by KLEIN (1878).

The nucleus of the mucous cell is observed in its basal part. This nucleus is generally long oval in shape (Fig. 2, 3, 4), the long axis of which corresponds to the long axis of the cell.

Usually, two large nucleoli occur within a nucleus being quite separately in the distal and the proximal parts (Fig. 3, 4). Sometimes, the nuclei contain just one great (Fig. 2) or several rather small nucleoli (Fig. 3).

In the mucous cells with a little mucous substance, the nuclei frequently have a peculiar form showing invagination in the nuclear membrane as illustrated in Fig. 3 and Fig. 4. In the nuclei, the nucleoli usually appear on the invaginated surfaces of the membranes and sometimes we observe large granules even outside of the nuclear membranes (Fig. 7). In Fig. 7 we see two granules within a pocket-like invagination. The one which is found close to the nuclear membrane stains almost the same colour reddish as the nucleoli, by the acid fuchsin (Mallory's method).

The other granule which appears in the distal part is stained blue with Mallory's stain. In this case these two granules are connected by a narrow bridge which shows the intermediate colour between the two granules. It is highly probable, that the former is the granules which was derived directly from the intranuclear nucleolus through the nuclear membrane while the latter is converted from the former.

In addition to this, the nuclear membrane of the mucous cell is frequently seen folded longitudinally, particulary in the active cells. This appears clearly in the cross-sections of the mucous membrane (Fig. 9). The condition has been already described by TSCHASSOWNIKOW (1927) being assigned no particular physiological significance.

In the ordinary mucous cells the author found numerous mitochondrial contents in comparison with other cells.

The mitochondria of the mucous cells were carefully observed by HOVEN (1912) and TSCHASSOWNIKOW (1927). According to them they consist of long filaments. On the other hand EKÖLF (1914) maintained that the mitochondria of the cells are possessed of granular units which take a linear arrangment. In my observation, in the mucous cells of *Hynobius*, mitochondrial granules are stained deep black with the iron-haematoxylin of Heidenhain's method (Fig. 4) and with Mallory's stain they show deep reddish colour (Fig. 3). These granules are found abundantly in the submucous layer of the cells, taking a linear arrangment.

OGNEFF (1892) described the structure of intercellular bridges between the epithelial cells, but according to CHAMBERS and RÉNGI (1925) who applied a recent method for the research, these intercellular bridges are probably the artefact of the fixative treatment. In case of the epithelial cells in the present study, I agree with CHAMBERS and RÈNGI (Fig. 9).

### iii. The goblet cells

The presence of the goblet cells in the fundus region of the stomach was first found by OPPEL (1896) in a fish and then in an Amphibian, *Bufo*, by BENSLEY (1928).

In *Hynobius* in the epithelium of the anterior fundus region, we can see the characteristic mucous cells (Fig. 5), in which a certain secretion occurs actively, leaving a little space for the cytoplasm in the apical pole. The nucleus is seen in the proximal cytoplasmic part, showing often an irregular form pressed by the secretion. The cytoplasm of the cell is stained a reddish colour with Delafield's haematoxylin-eosin. By this method we can observe in the secretion only some reticular structure which is of protoplasmic nature, showing the weak reddish colour. The distal pole of the cell opens to free surface with a small opening, the margin of which is surrounded by a membrane of cuticular nature. The cell above described, is the so-called goblet cell after OPPEL and BENSLEY without any doubt.

As mentioned above these goblet cells are found only in the anterior region of the stomach where the ciliated epithelial cells are present but their occurrence is not so frequent as in OPPEL's case in the fish stomach. In the pylorus region of *Hynobius*, I could hardly find the goblet cells, despite careful investigation.

It is generally accepted that there exists another kind of cell called "enterochromaffine cell" in the mucous epithelium of mamalian stomachs as HEIDENHAIN (1870), KULL (1925), and TEHVER (1930) respectively observed in domestic animals. Recently ROGOSINA (1930) also reported it in a ganoid fish, *Acipenser ruthenus*.

I could not find such "enterochromaffine cell" so far in the surface epithelium of *Hynobius*. However, in the fundus gland of the animal some cells have a

structure resembling the enterochromaffine cell of the above authors. On this subject I shall write again in detail later.

By the way it is remarkable that multiplication occours actively in the epithelial cells of the gastric gland, where we can find many fine mitotic figures of the cells (Fig. 6). However in the other parts generally the mitosis is very rare.

## II. The gastric gland

The gastric gland of the animal is composed of epithelium which invaginates to make a deep tubular depression. Each gland consists of three divisions, the mouth, the neck and the glandular body proper. The mouth of the gland (Text fig. 2, m) is formed by the low columnar cells continuous directly to those of the surface epithelium. Generally two or three conducting ducts of the glands open into a common opening, the mouth. The cell of the mouth has the structure of the mucous cell in which the amount of the secretion is not very great.

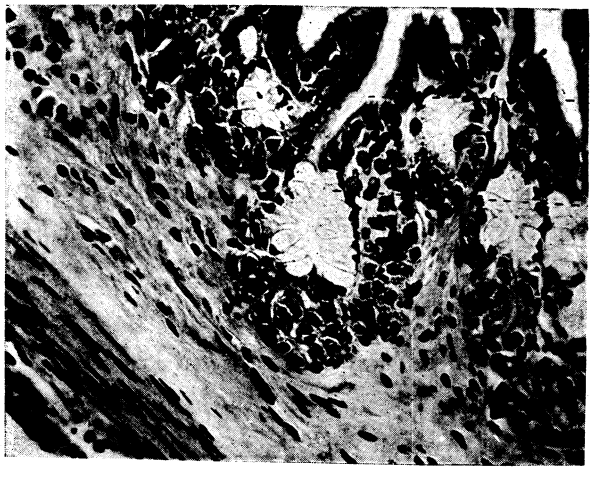


**Fig. 2.**

Cross-section of the fundus region, gland mouth (m); gland neck (n). ×160

Next, in the neck division (Text fig. 2, n) we can see the characteristic gland cells, which have almost the same appearance as the goblet cells of the surface epithelium. Then comes the proper gastric gland cell which shows in the inner part of the gland a different appearance according to the region of the stomach. As mentioned previously, the gastric glands of the animal are divided into two large groups according to the nature of the glandular tissues; namely the

funnus gland which is found in the fundus region and the pylorus gland which is observed only in the pyloric region.

### i. The fundus gland cells

Regarding the glandular cells of the fundus gland we much owe to the prior observation of HEIDENHAIN (1870), who worked on the fundus gland of the frog and found two different kinds of cell groups in it. As he described, the one which occupies the gland body proper corresponds to the parietal cells of a mammalian fundus gland and the other, which is found in the neck, possesses the nature of a mucous cell.

Hereupon we can enumerate a number of authors who worked respectively on amphibian fundus gland from the different points of view. Among others there are PARTSCH (1877) who found the characteristic mucous cells between the neck and the body of the gland; LANGLEY (1881) who described the granulated cells in the glandular bodies supposing that the granules have some relation to the pepsin formation; OPPEL (1889) who observed in *Proteus anguineus* the mucous secreting cells and granulated cells and BENSLEY (1898) who, reported on the other hand, on three kinds of cells, the mucous secreting cylinder cells, the large vesicular looking cells which are also regarded as mucous cells in the neck and the granular protoplasmic cells in the body of the gland.

Now, in the fundus gland of *Hynobius lichenatus* I found many large mucous secreting cells (Text fig. 2, n) as mentioned already, which are similar to those of the "neck chief cells" after BENSLEY (1898, 1928).

The next division is bordered with neck cells only which transform gradually into the body cells in the deeper part of the gland.

Subsequently one can distinguish two kinds of neck cells according to the place they take (Fig. 11). The first type is very large which shows a clear appearance after preparation (Fig. 10, 11, 12). In the clear region one can find minute reticular fibres of protoplasmic nature which are stained light reddish with Delafield's haematoxylin-eosin (Fig. 11) and faint blackish with iron-haematoxylin (Fig. 12). The nucleus is found in the apical protoplasmic pole of the cell attaching closely to the basement membrane (Fig. 12) and is provided

with numerous chromatin granules which are stained intensively with iron-haematoxylin (Fig. 10, 12). By MALLORY's stain the reticular structure of cytoplasmic fibres, above mentioned, appears in blue colour and the nucleus shows a deep reddish colour. In some cases we find some secretory materials stained blue among the reticular structure of the cell.

Of the second type of neck cell which appears in the inner part, the great majority is filled up with cytoplasm in which we can find some mitochondrial granules of reddish colour through Mallory's staining method. The nucleus is oval in shape. (Fig. 11).

Considering the above evidence, the opinion that these neck cells of the animal are possessed of the nature of mucous secretion as stated by the above authors, is quite valid.

The body cells show polygonal in form, and is characterised by containing rich granular bodies in it. (Fig. 10, 13, 15, 16, 18).

Through the mitochondrial method there appear in the cell abundant mitochondrial granules which are typical of it (Fig. 10). With Delafield's haematoxylin-eosin these granules are not so clearly demonstrated, but in turn there frequently come to appear large granules in the cytoplasmic area especially in the neighbourhood of the nuclei as in the case of ordinary mucous cells (Fig. 14, 17).

The nuclei of the cells are generally oval in form, each containing one large oval nucleoli within it (Fig. 15, 16, 18). There are a few chromatin granules in the nuclei, suspended in the intranuclear linin reticulum. (Fig. 15, 16). The nucleoli are stained either intensively black with iron-haematoxylin (Fig. 15, 18) or deep reddish by Mallory's staining method (Fig. 16). It is remarkable that the number and form of the nucleoli in the cell vary according to the phases of the activity. The nucleus often shows a peculiar form in the cell which has only a small number of characteristic granules in cytoplasm and is possessed of many nucleolar elements as compared with the other cell. Sometimes there occurs a pocket-like invagination from outside in the nuclear membrane as in the case of ordinary mucous cells (Fig. 13, 14, 17). In the early stage of the invagination the characteristic nucleolar granules come to appear in contact with the invaginated surface in the nucleus (Fig. 13). In another

case these granules are seen not only within the nucleus but also in the external cytoplasmic part, showing actually the same staining capacity. The more distant the granules are from the nucleus, the more they differ in grade of staining. By Mallory's stain the materials are stained deep blue (Fig. 16) and by Delafield's haematoxylin-eosin reddish (Fig. 14, 17).

In some cells the secreted nucleoli have gathered together into a certain mass in which the distal part from the nucleus differs from the proximal part in colour reaction (Fig. 14).

In the material which is fixed by Gilson's fluid and stained with Mallory's method one can distinguish two kinds of granules, namely the one of deep bluish colour and the other of reddish colour. The former is distributed in the peripheral part of the cells, while the latter occurs usually close to the nucleus which shows an oval form with one great nucleolus (Fig. 16).

Applying the method of the mitochondrial staining one can find some reticular structures in the cytoplasm close to the nuclear membrane as well as in the intranuclear part. Some of them are found connecting directly through the nuclear membrane (Fig. 18).

### ii. The pylorus gland cells

In the anterior part of the pylorus region we find a few mucous secreting cells similar to those of the neck division of the fundus gland. The granulated body cells are also greatly reduced in number as was already stated by OPPEL (1889, 1896) and BENSELEY (1898, 1928). In the posterior part of the region there are no neck cells in the gland which is greatly shortened in length as compared with that of the anterior part (Text fig. 1). The gland is composed of low columnar cells which have poorly granulated cytoplasm, an oval nucleus with two or three round nucleoli and in their distal part mucous fluid.

From the morphological point of view the gland cells of the pylorus gland are a part of the epithelial cells found in the surface of that region. The latter is mostly composed of long columnar mucous cells among which one can frequently find wandering cells (Text fig. 1, w. c), the significance of which has not yet been studied.

### iii. The basement membrane

According to IWAKIN (1895) the basement membrane of the vertebrate mucous epithelium is transformed from the material of the connective tissue of the tunica propria. Recently ROGOSINA (1930) also described in his studies on fish stomach the connective tissue origin of the membrana basilaris which is consisted in "homogene, kollagene Stoff".

By the staining method after Mallory I confirmed that the reticular fibre of tunica propria forms the basement membrane in *Hynobius*. Fig. 19 shows some connective tissue fibre being thrown into the above epithelium to make the membrane.

## Summary

The gastric epithelium of *Hynobius lichenatus* is composed of the surface epthelium and the gastric glands as in other amphibia. In the surface epthelium we can find three kinds of cells, that is ciliated cells, the ordinary mucous cells and the goblet cells. The goblet cells which are common in *Lophius piscatorius* (OPPEL, 1896) occur not so frequently in this case and are lacking completely in the pylorus region. The same is true in the case of ciliated cells which are seen mostly in the anterior part of the stomach. The middle and the posterior parts consisted of only ordinary mucous cells.

The gastric glands of the animal can be divided into two types; the fundus gland and the pylorus gland. Both show a tubular appearance branching into two or three. The fundus gland which is much greater than the pylorus gland, is divided into three divisions, the mouth, the neck and the body. The differentiation of the cells in the pylorus gland occurs not so conspicuously as in the fundus gland. The neck cells are found only in the anterior pylorus region in a small number. Now, there are found, so far, four kinds of glandular cells in the gastric mucous membrane, the goblet cells, the ordinary mucous cell, the neck and the body cell. The nucleus of each of these gland cells excepting the goblet cell always takes an active part in the secretion. In the present investigation the nuclear behaviour of the goblet cell is uncertain, but

in the other cells, in the early stage of the secreting activity the intranuclear granules come out into the cytoplasmic part through the invaginated part of the nuclear membrane, even though the process of secretion of these granules could not be actively followed.

These nucleolar extrusions were also described by many authors, MARSHALL and VORHIES, MAZIARSKI, NAKAHARA, KENNEY, NOEL and PAILLOT, BEAMS and WU, WU, GARDIER, GRESSON, MEHTA, JACOBS (loc. c) and others respectively.

It is highly probable that these granules are not extruded from the nuclear membrane keeping their original forms but are broken up into many fine threads as they pass, which in the cytoplasmic part again gather into a certain mass which is seen as a granule after fixation.

The nucleolar granules thus secreted, contain at first the nucleolar nature of the nucleus even in the cytoplasm but sooner or later they convert into substances of different chemical nature. This transformation usually occurs first from the peripheral part of the granules or from the distant part far from the nucleus. A similar phenomenon was also found by WU (1930) in his studies on the spinning gland cells. When the secretion of nuclear material is completed the nucleus which has an invagination on its surface recovers the form showing smooth oval in shape and in the adjacent area of the nucleus in this case there are found nucleolar granules in a great number. The granules which are situated farther from the nucleus have suffered from the greater chemical changes, Fig. 16.

Concerning the significance of the mitochondrial contents I could not find that they have any direct rôle in the secretion of the gland cells, even though their occurrence sometimes indicates active secretion by the cells.

Zoological Institute, Faculty of Agriculture,
Hokkaido Imperial University,
Sapporo, Japan.

## Literature Cited

BEAMS, H. W., and WU, C. F. 1928: Cytological studies on the spinning glands of Platyphylax designatus Walker. Anat. Rec., Vol. 41, No. 1.

BENSLEY, R. R. 1898: The structure of the mammalian gastric glands. Quart. Journ. Micr. Sci., Vol. 41.

BENSLEY, R. R. 1928: The gastric glands. Cowdry: Special cytology, Vol. 1, Section VI.

CHAMBERS, R., and RÉNY, G. S. 1925: The structure of the cells in tissues as revealed by microdissection. Amer. Journ. Anat., Vol. 35.

EKLÖF, H. 1914: Chondriosomenstudien an den Epithel -und Drüsenzellen des Magendarmkanals und den Oesoghagus-Drüsenzellen bei Säugetieren. Anat. Hefte, Bd. 51, Abt. 1.

GARDIER, M, S, 1927: Oogensis in Limulus polyphemus, with special reference to the behaviour of nucleus. Journ. Morph. and Physiol. Vol. 44.

GRESSON, R. A. R. 1929: Nuclear phenomena during oogenesis in certain Tenthredinidae. Quart. Journ. Micr. Sci. Vol. 73.

HEIDENHAIN, R. 1870: Uutersuchungen über den Bau der Labdrüsen. Arch. f. mikr. Anat. Bd. VI.

HOVEN, H. 1912: Contribution à l'ètude du fonctionnement des cellules glandulaires. Du rôle du chondriome dans la sécrétion. Arch. f. Zellforsch. Bd. 8.

IWAKIN, A. 1925: Der Bau der Basalmembran (Membranae basilares). Zeitschr. f. Anat. u. Entw. Bd. 75.

JACOBS, V. 1929: Untersuchungen über die Cytologie der Sekretbildung in der Mitteldarmdrüsen von Astacus leptodactylus. Zeitschr. f. Zellforsch. u. mikr. Anat. Bd. 8.

KINNEY, E. 1926: A cytological study of secretory phenomena in the silk gland of Hyphantria cunea. Biol. Bull. Vol. 51.

KLEIN, E. 1878: Observations on the structure of cells and nuclei. 1. Quart. Journ. Mikr. Sci. 18.

KULL, H. 1925: Die chromaffinen Zellen des Verdauungstraktus. Zeitschr. f. mikr. -anat. Forsch. Bd. 2, Heft. 1.

LANGLEY, J. N. 1881: On the histology and physiology of pepsin forming glands. Proc. Roy. Soci. London. Vol. 32.

MA, U. CH. 1928: The relation of mitochondria and other cytoplasmic constituents to the formation of secretion granules. Amer. Journ. Anat. Vol. 41.

MARSHALL, W. S., and VORHIES, C. T. 1906: Cytological studies on the spinning glands of Platyphylax designatus Walker. Intern. Monatschr. f. Anat. u. Physiol. Bd. 23.

MAZIARSKI, S. 1911: Recherches cytologiques sur le phénomènes sécrétoires dans les glandes filières des larves des lepidoptères. Arch. f· Zellforsh. Bd. 6.

MEHTA, D. R. 1930: Studies in the origin of yolk. III. Oogegesis of the fire-fly, Luciola gorhami. Quart. Journ. Micr. Sci. Vol. 73.

NAKAHARA, W. 1917: On the physiology of the nuclei as seen in the silk gland cells of certain insects. Journ. Morph. Vol. 29.

HAYASHI, T. 1930: A study on the glands of the skin in Hynobius (in Japanese). Reports of the Japanese Association for the Advancement of Science. Vol. VI.

NOEL, R., and PAILLOT, A. 1927: Sur la participation du noyau à la sécrétion dans les cellules des tubes sericigènes le Bombyx du Mûrier. Compt. Rend. d. Seanc. d. l. Soci. d. Biol. Tome 97.

OGNEFF, J. 1892: Einige Bemerkungen über das Magenepithel. Biol. Zentralb. Bd. 12.

OPPEL, A. 1889: Beiträge zur Anatomie des Proteus anguineus. I. Vom Verdauungstractus. Arch. f. mikr. Anat. Bd. 34.

OPPEL, A. 1896: Lehrbuch der vergleichenden mikroskopischen Anatomie der Wirbeltiere. Erster Teil, Der Magen.

PARTSCH, K. 1877: Beiträge zur Kenntnis des Vorderdarmes einiger Amphibien und Reptilien. Arch. f. mikr. Anat. Bd. 14.

ROGOSINA, M. 1930: Beiträge zur Kennthis des Verdauugskanals der Fische. II. Über den Bau des Epithels im Kardiaabschnitt des Magens von Acipenser ruthenus L. Zeitfchr. f. mikr. Anat. Forsch. Bd. 20.

SCHULTZE, F. E. 1867: Epithel und Drüsenzellen. Arch. f. mikr. Anat. Bd. 3, Heft 2.

TEHVER, J. 1930: Über die enterochromaffinen Zellen der Haussäugetiere. Zeitschr. f. mikr. -anat. Forsch. Bd. 21, Heft 1/3.

TSCHASSOWNIKOW, N. 1927: Über den Gang des Sekretionsprozesses in den Zellen des Magendeckepithels bei einigen Amphibien u. Säugern. Zeitschr. f. Zellforsch. u. mikr. Anat. Bd. 5,

WU, CH. F. 1930: Cytological studies on the spinning glands of the larva of Galleria mellonella, respective rôles played by the nucleus, the Golgi apparatus, and the mitochondria during secretion. Journ. Morph. and Physiol. Vol. 49.

## Explanation of plates

All the photomicrographs were taken by Leitz "Makam". Plate: Ilford screened and chromatic. Filter: Zettnow's mixture.

## Plate I

Fig. 1. Ciliated epithelium, fixed in Gilson's fluid, Delafield's haematoxylin-eosin stain. ×720

Fig. 2. Invagination in nucleus in the ordinary mucous cell. Gilson's fluid; Mallory's stain. ×1200

Fig. 3. Ordinary mucous cells in early phase of the activity, the invaginated nuclear membrane, mitochondrial granules and nucleoli are clearly seen. Gilson's fluid; Mallory's stain. ×1400

Fig. 4. Mitochondrial granules in submucous region, two nucleoli in a nucleus with reduced chromatin. Mitochondrial method. × 1400

Fig. 5. Goblet cell. Zenker's fluid; Delafield's haematoxylin-eosin stain. × 1400

Fig. 6. Mitotic figure in an epithelial cell, early metaphase. Mitochondrial method. × 1400

Fig. 7. Nucleolar secretion in the ordinary mucous cell. Gilson's fiuid, Delafield's haematoxylin-eosin stain. × 1400

Fig. 8. Two columnar cells containing chromatin-like materials. Gilson's fluid; Delfield's haematoxylin-eosin stain. × 1400

Fig. 9. Cross-section of the surface epithelium, Mitochondrial method. × 1400

Fig. 10. Fundus gland with granulated body cells and clear neck cells. Mitochondrial method. × 320

## Plate II

Fig. 11. Cross-section of a neck division in a fundus gland. Zenker's fluid; Delafield's haematoxylin-eosin stain. × 360

Fig. 12. Typical large neck-cell. Mitochondrial method. × 1400

Fig. 13. Nucleus with pocket-like invagination in a body cell. Mitochondrial method. × 2400

Fig. 14. Nuclear secretion in body cell. Gilson's fluid; Delafield's haematoxylin-eosin stain. × 1800

Fig. 15. Granulated body cell, in resting stage. In the nucleus one great nucleolus and fine chromatin granules are present. Mitochondrial method × 1400

Fig. 16. Three body cells in cross-section. Panchromatic plate and orange G filter were used. The granules having a blue colour are distinct while the granules having red are faint. The oval formed nuclei with large oval nuclei, chromatin network. Gilson's fluid; Mallory's stain. × 1350

Fig. 17. Nucleolar secretion in body cell. Gilson's fluid; Delafield's haematoxylineosin stain. × 1400

Fig. 18. Supranuclear network of body cell. Mitochondrial method. × 1800



Fig. 1

Fig. 2

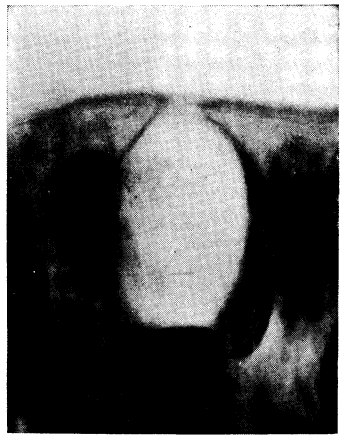

Fig. 5

Fig. 8

Fig. 3

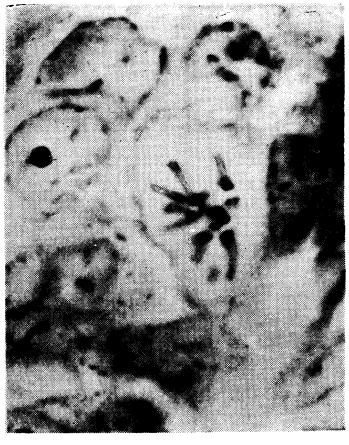

Fig. 6

Fig. 9

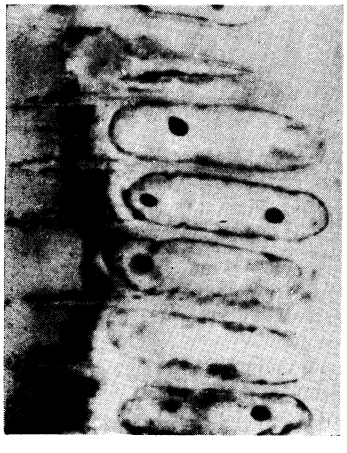

Fig. 4

Fig. 7

Fig. 10

Fig. 11

Fig. 14

Fig. 17

Fig. 12

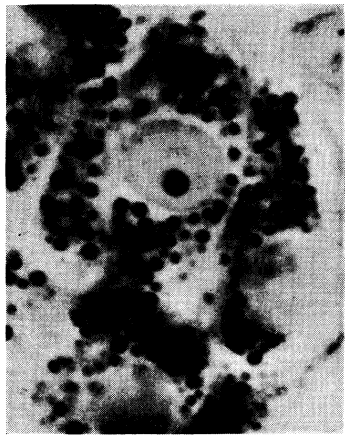

Fig. 15

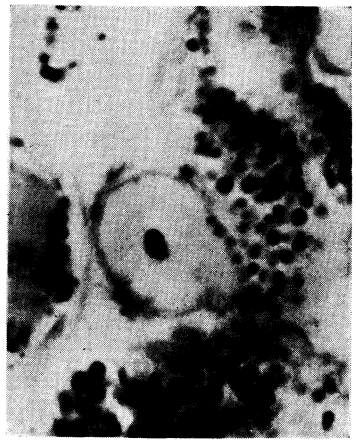

Fig. 18

Fig. 13

Fig. 16

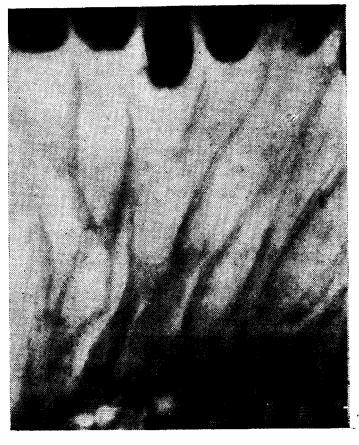

Fig. 19

Fig. 19. Basement membrane in surface epithelium. Gilson's fluid; Mallory's stain. × 1800

## 摘　　要

山椒魚の胃の内面を被覆せる上皮組織は甦毛上皮細胞(ciliated cell)酒盃細胞(goblet cell),粘液細胞(mucous cell)等に依つて構成され、上皮組織の陥没に依つて生じたる、腺組織は泡狀の頸部細胞(neck cell)及び特に顯著なる顆粒を含有せる体細胞(body cell)に依つて其の主要部を構成さる。以上の内甦毛上皮細胞以外のものは腺細胞として直接胃の消化に與るも酒盃細胞は其の分布の範圍狹く胃の前部に限られ數も亦僅少なり。而して粘液細胞、頸部細胞、体細胞等は其の分布も廣く數も亦過大にして粘膜に於ける主要なる分泌要素を構成す。之等三種の腺細胞は共に類似の分泌物轉化の過程を示し、分泌物の本原は共に核の内容に由來す。即ち將に活動期に入らむとする細胞に於ては核の一部が著しく灣入し、仁は其の灣入部に向つて移動し遂に核膜を通じて細胞質内に分泌さるゝ事を觀察せり。

尙、細胞質中に出されたる核の内容も其の當初に於ては核内に於ける其等と全く同樣の染色反應を示すも細胞の游離面に移動を開始するや、周圍より漸次各腺細胞の分泌物に類似の染色反應を現はす事を見たり。