A CASE OF A TESTIS-OVUM FOUND IN THE ADULT MALE FROG, *RANA TEMPORARIA L.*[1]

BY

SAJIRO MAKINO

(3 Text-figures)

エゾアカガヘルに見出された精巣異常の一例

牧 野 佐 二 郎

During the course of a series of investigations on the germ cells of the grass frog, *Rana temporaria L.* during 1930, I examined a large number of testes in sections and found an individual in which a testis showed anomaly. It is an ovum-containing testis[2] and only one case in about thirty males.

Description

This individual to be described was caught, together with a number of other grass frogs, in the afternoon of July 10, 1930, at Maruyama in the vicinity of Sapporo. It was killed in the evening and fixed in Flemming's strong solution. The testes were sectioned 10 micra in thickness and stained by Flemming's triple method. Althogh there is no special remark in my notes on the urogenital system and the measurement of body size, it seems to be certain, that from the external examination of the secondary sexual characters, the

1) Contribution No. 8, from the Zoological Institute, Faculty of Science, Hokkaido Imperial University, Sapporo.

2) In CHENG's ('29) nomenclature, an "ovum (ova)-containing testis" means a testis, in which there is contained the ovum-like body, to which the name "testis-ovum (ova)" is applied in an otherwise normal testicular tissue; while an "ovotestis" is such a testis that is composed of recognizable portions of both ovarian and testicular tissues containing ova in its spermatic substance.

[Transact. Sapporo Nat. Hist. soc., Vol. Pt. 4, 1931]

Fig. 1.

Part from a longitudinal section of the testis, showing a testis-ovum within a tubule. Microphotograph with aid of Leitz 'Makam', tube-length 170 mm., under magnification of Leitz obj. 3×oc. 8.

individual was considered to be a male, due to the presence of well-defined thumb pads. The appearances of both gonads were normal with respect to their shape, colouration and fat bodies. The size of gonads measured in section was about 2.4—2.6 mm. in length and 1.2—1.3 mm. each in width, thus somewhat smaller than the usual condition. The sections after examination showed that they were gonads of a male nature, but one of them, probably the left testis, exhibited an anomaly. In sections through the part close to the posterior end of this gonad, an ovum was found in a tubule near the periphery of the gonad, deeply imbedded among male cells (Fig. 1). It was the only one found throughout the gonad. Observed histologically, the gonad presents a normal testicular structure which corresponds exactly with that found in normal testes of this season. The tubules contain ripe spermatozoa and the cells of various stages of spermatogenesis. The chromosomes found in this gonad are also normal in number and behavior. Even the very tubule in which the ovum is imbedded, shows nothing deviated from the remaining tubules in its size and structure, and contains ripe spermatozoa, spermatocytes and spermatogonia of various stages (Fig. 2).

Fig. 2.

Enlarged view of a testis-ovum within a tubule, showing numerous nucleoli scattered throughout the nucleus. Note the spermatozoa and normal germ cells around the ovum. Microphotograph with aid of Leitz 'Makam', tube-length 170 mm., under magnification of Leitz obj. 7×oc. 8.

There is no anomaly in respect to the interstitial tissue surrounding the tubule, as often described in like cases by several investigators. The testis of the supposed right side is quite normal in appearance as well as in its microscopical structure.

The size of the ovum measures ca. 0.08 mm. in diameter and it was sectioned in eight pieces. Compared with cases described by CHENG ('29) and others, the ovum in the present case is much smaller in diameter. The shape of the cytosome is nearly oval and is devoid of ovarian follicles. The nucleus appears round in shape and possesses a magnitude covering five sections and measuring 0.05 mm. and 0.06 mm. respectively in vertical and horizontal diameters. Numerous nucleoli of various size and shape, stained dark red by safranin, are found scattered everywhere in the nucleus, which stains bright yellowish orange (Fig. 2). The oöplasm is compact in appearance, staining faintly dull violet and no yolk granules are visible. The numbers of nucleoli scattered in five sections, are respectively about 61, 109, 144, 128 and 53. In total, therefore about 500 nucleoli are found throughout the entire nucleus. They differ considerably in shape, but those of spherical shape are mostly abundant. They vary in size as measures show from ca. 0.0005 mm. to 0.007 mm.. But the most frequent ones, measure ca. 0.0015–0.0025 mm. in diameter. In most cases, the nucleoli of the largest category are composed of two or more smaller ones of various size and shape, which aggregate upon the ground substance stained dark violet (Fig. 3). Several vacuole-like granules stained reddish black are also found imbedded in the larger nucleoli. There is, however, no visible evidence of any chromatin-reticulum or any other like structure in the nucleus. All structures and conditions mentioned above seem to indicate no other features than those characteristic to degenerating processes.

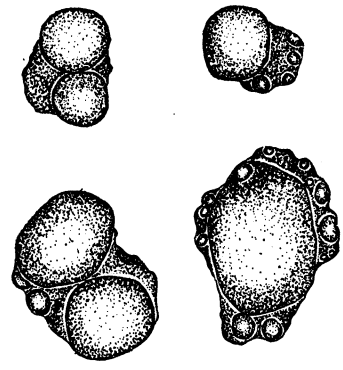

Fig. 3.
Various nucleoli found in the nucleus of the testis-ovum. Drawings are outlined with the aid of a Camera lucida, under magnification of Zeiss Apo. 2 mm. × K. 15.

From the facts above described, there is no doubt that the testis-ovum of

the present case is of no functional value. The presence of the thumb pads and perfect development of spermatozoa emphasize the conclusion that this abnormal testis must function simply as male, in spite of the presence of the ovum. Thus the significance of occurrence of the ovum or ova in the testis, remains unsolved.

Historical

The cases of sex-organ anomaly in anurans which have been described are summarized in two papers published in 1921, one by CREW and the other by WITSCHI. Of the forty cases enumerated by CREW ('21) in his review, twenty-one are represented by *Rana temporaria.*

Since 1921, more than forty reports of abnormal sex-organs in frogs and toads have been published and about eleven of these reports are concerned to *Rana temporaria.* CREW and FELL ('22) found in a male of *R. temporaria* a displaced testis which contained big round bodies closely resembling ova. According to the authors, these ovum-like bodies are no more than a product of liquefaction of the degenerating spermatozoa. WITSCHI ('23, '25, '29) described hermaphrodites of *R. temporaria* which had ovo-testes on one or both sides accompanying developed oviducts. DAUVART ('26, '27) recorded two specimens of heterotopic testis in *R. temporaria.* WORONZOWA ('26) and DRAIGOIU et POP ('27) described abnormal examples with ovotesticular glands in *R. temporaria.* SHAW and BRAMBELL ('28) noted one of aberrant ovary type in *R. temporaria.* More recently, EGGERT ('29) enumerates a new case of *R. temporaria* in which a single gonad is present on the right side only, and LLOYD ('29) describes two more cases of hermaphroditism in the same species.

That the numerous cases of sex-organ anomaly are discovered in *R. temporaria*, as stated above, does not mean, that this species is more prone to abnormality than other frogs, but should be attributed to the fact that this grass frog is used for laboratory purposes more commonly than others, thus offering more opportunities to meet with anomalies. Consequently I believe, that a more thorough and careful examination will show frequent occurrence of similar ova-like conditions in other species of anurans. It is by no means uninteresting that the

cases of sex-organ anomaly are found more frequently in anurans than in urodelans.

I wish to acknowledge my indebtedness to Prof. Dr. OGUMA for his valuable advice and suggestions. I also wish to thank Mr. H. YAMAGUCHI for his aid in making photographs.

27-Dec., 1930.

Literature

Brambell, F. W. R.	1930	The development of sex in vertebrates.
Crew, F. A. E.	1921	Jour. Genetics, vol. II
Crew & Fell	1922	Q. J. M. S., vol. 66
Cheng, T. H.	1929	Biol. Bull., vol. LVII
————	1929	Jour. Morph., vol. 48
Chidester, F. E.	1926	Anat. Rec., vol. 34
Christensen, K.	1929	Anat. Rec., vol. 43
Dauvart, A.	1926	Zeitschr. f. wiss. Biol., D., Bd. 108
————	1927	Cpt. Rend. Soc. de Biol., T. 97
Dragoiu et Pop	1927	Cpt. Rend. Soc. de Biol., T. 96
Ecker-Gaupp	1904	Anatomie des Frosches.
Eggert, B.	1929	Zeitschr. f. wiss. Zool., Bd. 133
Ikeda, S.	1896	Zool. Magazine, Tokyo, vol. 8
Lloyd, J. H.	1929	Am. Not., vol. 63
Maclean, B. L.	1928	Anat. Rec., vol. 41
Makino, S.	1930	Zool. Magazine, Tokyo, vol. 42
Shaw & Brambell	1928	Jour. Roy. Micr. Soc., London, ser. 3, vol. 48
Stohler, R.	1928	Zeitschr. f. Zellf. u. mikr. Anat., Bd. 7
Witschi, E.	1921	Arch. f. Entw.-Mech. d. Organ., Bd. 49
————	1923	Biol. Zentralbl., Bd. 43
————	1927	Biol. Bull., vol. 52
————	1929	Jour. Exp. Zool., vol. 54
Woronzowa, M. A.	1926	Trudy Lab. Eksper. Biol. Zoopark MOSCOW, T. 2

摘　　要

昭和五年の夏エゾアカガヘルの染色体をしらべてゐる間に、或る一頭の雄の生殖腺の一方に一個の卵の存在するのを見出したので、精巣異常の一例として玆に報告する次第である。

この個体は七月十日に固定されたもので、其の第二次性特徴から云つて完全に雄であつた者である。又其の精巣も形、色彩等に於て普通の雄に存在するものと異つた所は認められなかつた。卵の

見出されたのは恐らく左側の精巣と思はれるもので、この精巣に於ても、組織學的に云つて何等正常の雄と異つた構造は見當らず、只一個の卵が全く正規な精蟲發生をなしつゝある精巣の中に、ぽつんと存在するに過ぎないのである。卵の大さは約 0.08mm.其の核は約 0.05–0.06mm.で核の中には大小樣々な約 500個ばかりの仁が存在する。種々な点から推察して、恐らくこのものは卵としての機能を持つてゐるものではないと考へられる。他の一方の精巣は組織學的にも細胞學的にも全く正常なものである。

兩棲類中無尾類に於てはこの種生殖腺異常の現象は最も普通に見られるもので、文献に現はれたものだけでも驚くべき數に上つてゐる。同じ兩棲類でも有尾類にこの例が少いと云ふ事は興味のある事實であろう。

NOTES ON PLANTS OF THE WESTERN ALEUTIAN ISLANDS COLLECTED IN 1929 (II)

BY

MISAO TATEWAKI

西部アリユウシアン群島植物雜記（其二）

舘　脇　操

Pyrolaceæ.

19. ***Pyrola minor*** L. Sp. Pl. ed. 1. p. 396, (1753); MIYABE, Fl. Kuril. p. 248; MACOUN, Pl. Pribilof Isl. p. 568, (1899); KUDO, Fl. Isl. Paramushir, p. 140, (1922); KOMAR. Fl. Pen. Kamtschat. II. p. 353, (1929); Hult. Fl. Kamtchat. IV. p. 4, (1930).

Hab. In heaths and meadows: Chichagof, Isl. Attu. (n. 14814); Nazan, Isl. Atka. (n. 14382).

[Transact. Sapporo Nat. Hist. Soc., Vol. XI, Pt. 4, 1931]