CASE REPORT – OPEN ACCESS

International Journal of Surgery Case Reports 29 (2016) 137–140

Contents lists available at ScienceDirect

International Journal of Surgery Case Reports

journal homepage: www.casereports.com

Intraoperative localization of arteriovenous malformation of a jejunum with combined use of angiographic methods and indocyanine green injection: Report of a new technique

Hiromi Ono[a,*], Mitsuo Kusano[b], Futoshi Kawamata[c], Yasushi Danjo[b], Masato Kawakami[a], Kimimoto Nagashima[d], Hiroshi Nishihara[e]

[a] Department of Internal Medicine, Seiwa Memorial Hospital, 1-1, 1-Jo, 5-Chome, Kotoni, Nishi-ku, Sapporo 063-0811, Japan
[b] Department of Surgery, Seiwa Memorial Hospital, 1-1, 1-Jo, 5-Chome, Kotoni, Nishi-ku, Sapporo 063-0811, Japan
[c] Department of Gastroenterological Surgery I, Hokkaido University Graduate School of Medicine, Kita 15, Nishi 7, Kita-ku, Sapporo 060-8638, Japan
[d] Department of Anesthesiology, Seiwa Memorial Hospital, 1-1, 1-Jo, 5-Chome, Kotoni, Nishi-ku, Sapporo 063-0811, Japan
[e] Department of Translational Pathology, Hokkaido University Graduate School of Medicine, Kita 15, Nishi 7, Kita-ku, Sapporo 060-8638, Japan

ARTICLE INFO

Article history:
Received 27 June 2016
Accepted 11 October 2016
Available online 15 October 2016

Keywords:
Arteriovenous malformation
Indocyanine green
ICG fluorescence imaging
Superior mesenteric artery angiography

ABSTRACT

INTRODUCTION: The localization of small intestine sources of obscure gastrointestinal bleeding has been a challenge. The use of indocyanine green (ICG) is effective in aiding intraoperative localization if a bleeding lesion is identified on angiography.
CASE PRESENTATION: A 95-year-old Japanese man presented with hematochezia. Selective angiography of the superior mesenteric artery (SMA) established an arteriovenous malformation (AVM). ICG injection into the feeding vessel was administered intraoperatively, and the demarcated segment of the jejunum was resected.
DISCUSSION: Diluted ICG was injected in the SMA by intraoperative angiography, and the region could be easily and clearly visualized by the ICG fluorescence imaging; small patchy poolings of ICG were recognized. Ultimately, the region was diagnosed as an AVM of the jejunum. To the best of our knowledge, this is the first reported description of this technique.
CONCLUSION: Our new technique of combining selective angiography with intraoperative ICG injection and focused enterectomy is a safe, accurate, and cost-effective treatment.

1. Introduction

Obscure gastrointestinal bleeding (OGIB) from the small intestine has been a diagnostic and therapeutic challenge. Despite the current array of diagnostic studies, identification of the causative pathology may be elusive, particularly when the bleeding is intermittent. Herein, we present a new technique of combining selective angiography with intraoperative indocyanine green injection and focused enterectomy.

2. Presentation of case

A 95-year-old Japanese male was referred to our hospital with a suspected cerebral stroke in February 2015. He had experienced impairment of consciousness and his daughter discovered him unconscious near his bed. The patient was 167 cm in height and weighed 55.5 kg. Physical examination revealed bruises as the source of his pain on his right shoulder and knee. He had a past medical history of cerebral infarction, congestive heart failure, chronic renal failure, and hypertension. His body temperature was 37.8 °C, blood pressure was 178/79 mmHg, white blood cell count was 12,100/μL, haemoglobin level was 9.7 g/dL, creatinine level was 1.73 mg/dL, creatine kinase level was 3910 U/L, and C-reactive protein level was 19.56 mg/dL. During the admission, he presented with hematochezia, haemoglobin level of 6.0 g/dL, and symptomatic blood transfusion-dependent anemia. Upper and lower GI endoscopy images were normal. Initially, a double-balloon enteroscopy could not establish the source of intestinal bleeding. A selective angiography of the first jejunal branch of the superior mesenteric artery revealed an arteriovenous malformation as the source of bleeding (Fig. 1). Intraoperatively, diluted 2-mL ICG (Diagnogreen 0.5%; Daiichi Sankyo Co., Tokyo, Japan) was then injected via the selective angiographic microcatheter, immediately staining a 8-cm segment of the proximal jejunum. We recognized that the region was green in color (Fig. 2), and the region could be easily and clearly visualized by the ICG fluorescence imaging

* Corresponding author.
E-mail address: hiro_docto@yahoo.co.jp (H. Ono).

http://dx.doi.org/10.1016/j.ijscr.2016.10.030

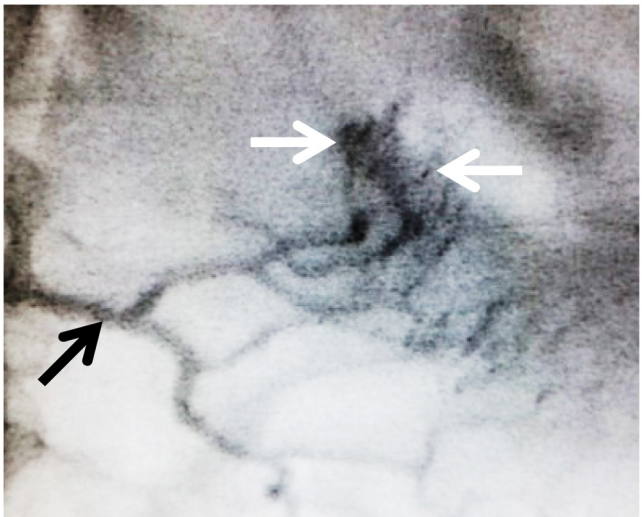

Fig. 1. A selective angiography for first jejunal branch (black arrow) of superior mesenteric artery showed poolings of the vessels and revealed an arteriovenous malformation as the source (white arrows).

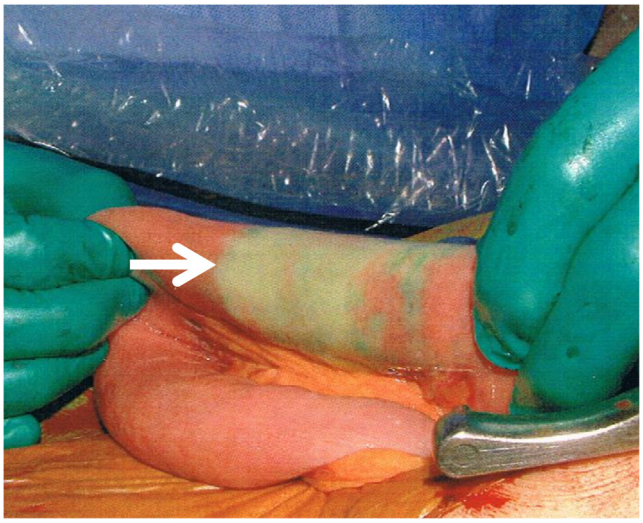

Fig. 2. Dilute ICG (2 mL) was injected via the selective angiographic microcatheter, immediately staining a 8 cm segment of the proximal jejunum, and the region was recognized by the green color observed (arrow).

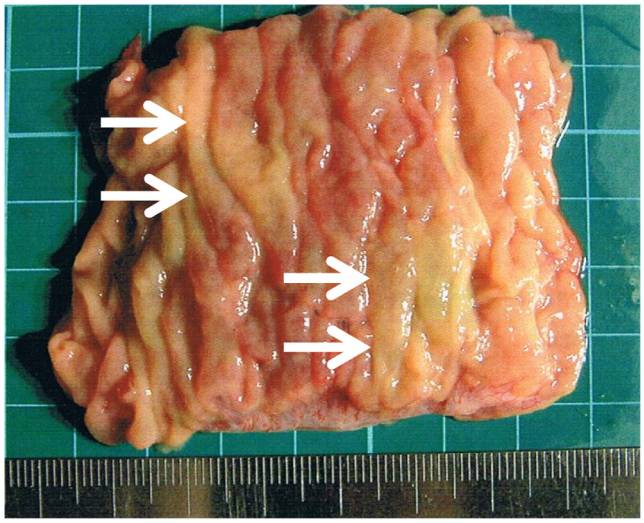

Fig. 4. Macroscopically, the mucosa of the resected specimen was patchy greenish (arrows), but the mucosa was almost intact.

(IFI) device (Photo dynamic emission camera; Hamamatsu Photonics K.K., Hamamatsu, Japan). The region was recognized as dilated marginal arteries (Fig. 3A) and small patchy areas (Fig. 3B) in ICG stained jejunum. A 10-cm segment of the jejunum was resected from the near ligament of Treitz. Macroscopically, the mucosa of the resected specimen was patchy greenish (Fig. 4). Microscopic examination revealed both thick- and thin-walled arteries and veins. Histological evaluation of the region revealed an intact mucosal cover and numerous abnormal vessels in the submucosa. The AVM diagnosis was characterized in the absence of malignancy (Fig. 5). The patient denied any signs or symptoms of postoperative GI bleeding until he was dead due to congestive heart failure and aspiration pneumonia five months after operation.

3. Discussion

Obscure GI bleeding (OGIB) is bleeding from an unknown origin that persists or recurs after an initial negative endoscopic evaluation, including esophagogastroduodenoscopy (EGD) and colonoscopy [1]. The incidence of OGIB occurring between the ligament of Treitz and the ileocecal valve is only 5% [2]. The incidence of OGIB occurring because of small intestine angiodysplasia, the

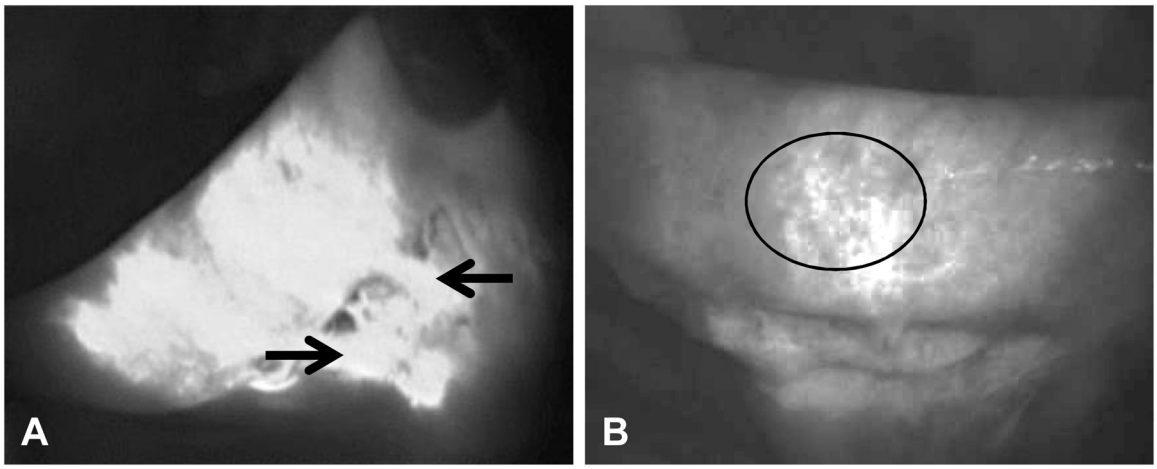

Fig. 3. The region was observed using a fluorescence imaging device. The region could be easily and clearly visualized by the ICG fluorescence imaging (IFI), where dilated marginal arteries at an early phase (arrows) (A) and small patchy poolings of ICG at a late phase (oval) (B) were recognized.

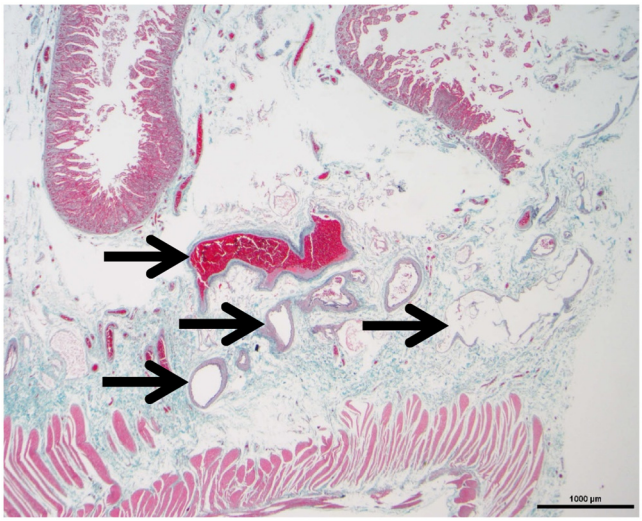

Fig. 5. Microscopic examination with elastica-masson staining revealed thick-and thin-walled sized arteries and veins (arrows). Histological evaluation revealed that the region showed an intact mucosal cover and numerous abnormal vessels in the submucosa (low-power magnification).

most common cause in older patients, is approximately 30–40% [3]. In patients aged less than 50 years, the most common sources are tumors, such as leiomyoma, leiomyosarcoma, carcinoid, lymphoma, and adenocarcinoma [4]. Common vascular lesions of the small intestine include angiodysplasia, telangiectasia, arteriovenous malformation, haemangioma, phlebectasia, and Dieulafoy's lesion [5,6]. However, the clinically distinguishing vascular malformation is sometimes difficult because these lesions have similar endoscopic appearances. Intestinal AVMs have been described as flat or mildly elevated hemorrhagic spots or erosions, whereas others lesions appear as a mass or polypoid lesions [7–9]. Therefore, in our case, the bleeding source could not be detected by a double-balloon enteroscopy. AVMs present with aberrant vessels with thickened, hypertrophic walls having varied thickness. An elastic segment can mimic areas with arterial features, such as an internal elastic layer, that interconnects with segments of veins with no internal elastic layer [10].

An algorithm for the diagnosis and management of obscure GI bleeding was proposed in 2005 [11]. In patients presenting with OGIB, EGD and colonoscopy should be performed. Overall, 20–30% of patients undergoing evaluation for obscure bleeding have lesions in the upper and lower GI tracts that may be missed on initial endoscopic evaluation [12,13]. Therefore, a second endoscopy evaluation should also be considered before proceeding with capsule endoscopy. Video capsule endoscopy (VCE) should be considered next for patients with GI bleeding if findings on EGD and colonoscopy are negative.

Mesenteric angiography is typically reserved to evaluate patients with OGIB. Diagnostic yield ranges from 27% to 77% for lower GI bleeding [14]. The use of methylene blue dye to aid the localization of these obscure sources of GI bleeding is well described in the literature. In 1978, the first case was reported, wherein 10 mL of methylene blue were injected in the superior mesenteric artery by intraoperative angiography [15]. Numerous case reports using similar techniques have described intraoperative enteric mapping of the small intestine lesion using methylene blue, followed by surgical exploration and selective resection [16–18].

There was an another technique used in a patient with angiodysplasia of the small intestine, wherein preoperative localization was done using percutaneous computed tomography (CT)-guided injection of methylene blue dye. This CT-guided percutaneous technique is potentially useful for enteric mapping prior to definitive surgical resection [19].

In our new technique, we injected 2 mL of ICG in the superior mesenteric artery by intraoperative angiography, and the region was immediately recognized owing to green in color. The region could be easily and clearly visualized by the ICG fluorescence imaging (IFI), where dilated marginal arteries and small patchy poolings of ICG were recognized. Ultimately, the region was diagnosed as an AVM of the jejunum. Subsequently, a short segment of the lesion was safely and accurately resected. To our knowledge, this is the first reported description of this technique.

4. Conclusion

Localization of OGIB of the small intestine continues to be a challenge. Our new technique of combining selective angiography with intra-operative indocyanine green injection and focused enterectomy is a safe, accurate, and cost-effective treatment. Based on our results, we recommend this novel method in such cases.

Conflicts of interest

The authors declare that they have no conflicts of interest.

Funding

None.

Ethical approval

This indocyanine green injection study was performed with the approval of the Internal Review Board on ethical issues of Seiwa Memorial Hospital.

Consent

Written informed consent was obtained from the patient's daughter for publication of this case report and accompanying images.

Authors' contribution

HO helped in writing and collecting the data. MK and FK have participated in caring for the patient. YD, MK and KN researched the literature review. HN helped in pathology interpretation. All authors contributed to the refinement of the case report and approved the final manuscript.

Guarantor

Hiromi Ono.

References

[1] ASGE Standards of Practice Committee, The role of endoscopy in the management of obscure GI bleeding, Gastrointest. Endosc. 72 (2010) 471–479.
[2] A. Szold, L.B. Katz, B.S. Lewis, Surgical approach to occult gastrointestinal bleeding, Am. J. Surg. 163 (1992) 82–90.
[3] P.G. Foutch, Angiodysplasia of the gastrointestinal tract, Am. J. Gastroenterol. 88 (1993) 807–818.
[4] B.S. Lewis, A. Kornbluth, J.D. Waye, Small bowel tumours: yield of enteroscopy, Gut 32 (1991) 763–765.
[5] U.S. Karnam, J.S. Barkin, Vascular malformations of small intestine, Curr. Treat. Options Gastroenterol. 4 (2001) 173–179.
[6] B.S. Lewis, Small intestinal bleeding, Gastroenterol. Clin. North Am. 29 (2000) 67–95.
[7] J.H. Cheon, H.J. Song, J.S. Kim, K.J. Park, W.H. Kim, H.C. Jung, et al., Recurrent lower gastrointestinal bleeding from congenital arteriovenous malformation

in the terminal ileum mimicking intestinal varicosis: a case report, J. Korean Med. Sci. 22 (2007) 746–749.
[8] L. Maeng, K.Y. Choi, A. Lee, C.S. Kang, K.M. Kim, Polypoid arteriovenous malformation of colon mimicking inflammatory fibroid polyp, J. Gastroenterol. 39 (2004) 575–578.
[9] M.L. Krinsky, M.E. Robert, J.C. Garcia, J.R. Korzenik, M. Topazian, Polypoid vascular malformation of the small intestine, Gastrointest. Endosc. 48 (1998) 530–533.
[10] J. Eastman, M. Nazek, D. Mangels, Localized arteriovenous malformation of the jejunum, Arch. Pathol. Lab. Med. 118 (1994) 181–183.
[11] M. Pennazio, G. Eisen, N. Goldfarb, ICCE consensus for obscure gastrointestinal bleeding, Endoscopy 37 (2005) 1046–1050.
[12] L.C. Fry, M. Bellutti, H. Neumann, P. Malfertheiner, K. Mönkemüller, Incidence of bleeding lesions within reach of conventional upper and lower endoscopes in patients undergoing double-balloon enteroscopy for obscure gastrointestinal bleeding, Aliment. Pharmacol. Ther. 29 (2009) 342–349.
[13] C.A. Robinson, C. Jackson, D. Condon, L.B. Gerson, Impact of inpatient status and gender on small-bowel capsule endoscopy findings, Gastrointest. Endosc. 74 (2011) 1061–1066.
[14] G.R. Zuckerman, C. Prakash, Acute lower intestinal bleeding: part I: clinical presentation and diagnosis, Gastrointest. Endosc. 48 (1998) 606–617.
[15] R. Fogler, E. Golembe, Methylene blue injection: an intraoperative guide in small bowel resection for arteriovenous malformation, Arch. Surg. 113 (1978) 194–195.
[16] C.A. Athanasoulis, A.C. Moncure, A.J. Greenfield, J.A. Ryan, T.F. Dodson, Intraoperative localization of small bowel bleeding sites with combined use of angiographic methods and methylene blue injection, Surgery 87 (1980) 77–84.
[17] S.M. Gifford, M.A. Peck, A.M. Reyes, J.B. Lundy, Methylene blue enteric mapping for intraoperative localization in obscure small bowel hemorrhage: report of a new technique and literature review: combined intraoperative methylene blue mapping and enterectomy, J. Gastrointest. Surg. 16 (2012) 2177–2181.
[18] J. Frydman, H. Bahouth, M. Leiderman, A. Ofer, Y. Kluger, Methylene blue injection via superior mesenteric artery microcatheter for focused enterectomy in the treatment of a bleeding small intestinal arteriovenous malformation, World J. Emerg. Surg. 9 (2014) 17.
[19] J.C. Martinez, J.L. Thomas, J.J. Lukaszczyk, Single incision laparoscopic surgery approach for obscure small intestine bleeding localized by CT guided percutaneous injection of methylene blue, Int. J. Surg. Case Rep. 5 (2014) 1082–1085.