Epidermal Sutureless Closure of the Umbilical Base Following Laparoscopic Colectomy for Colon Cancer

Susumu Shibasaki, Shigenori Homma, Tadashi Yoshida, Hideki Kawamura, Norihiko Takahashi, Akinobu Taketomi

Department of Gastroenterological Surgery I, Graduate School of Medicine, Hokkaido University, Sapporo, Japan

Address correspondence to:
Shigenori Homma, M.D., Ph.D.
Department of Gastroenterological Surgery I,
Graduate School of Medicine, Hokkaido University, Sapporo, Hokkaido, Japan.
N15, W7, Kita-Ku, Sapporo 060-8638, Japan
Tel: +81-11-706-5927, FAX: +81-11-716-7515
Email: homma.s@nifty.com

Funding/Support: The study had no sponsor or funding source.

Running title: Non-suturing method of umbilical closure

Word count: Text: 2,269 words; Abstract: 194 words

Tables: 5. **Figures**: 3 (no colors)

Abstract

Background At our institute, a non-suturing method for closure of the umbilical epidermis has been used in laparoscopic colorectal resection to prevent umbilical wound infection. We performed a retrospective evaluation of the incidence of umbilical wound infection using this technique for patients with colorectal cancer.

Methods From 2010 to 2014, 178 consecutive patients underwent elective laparoscopic resection of colorectal cancer. The umbilical fascia was closed using interrupted multifilament absorbable sutures. The skin surface of the umbilicus was compressed using a cotton ball and sealed by water vapor-permeable film.

Results Three (1.7%) patients required conversion from laparoscopic to open surgery. The mean surgery time was 174 ± 48 minutes, intraoperative blood loss was 29 ± 75 mL, and postoperative hospital stay was 10.5 ± 6.7 days. According to the Centers for Disease Control and Prevention criteria, umbilical superficial wound infection occurred in 2 (1.1%) patients. The two patients recovered from their wound infections after a few days of drainage and their hospital discharge was not delayed. Deep umbilical wound infection did not occur in any patient.

Conclusion Our non-suturing closure technique appeared to be effective in preventing wound infection after laparoscopic resection of colon cancer.

Key words: Colorectal cancer; laparoscopic colorectal resection; surgical site infection; umbilical wound infection.

Introduction

In recent years, laparoscopic colorectal resection has become accepted as a minimally invasive procedure for the treatment of benign and malignant colorectal disease. Compared to traditional open surgery, the advantages of laparoscopic surgery are less postoperative pain, faster recovery times, fewer wound-related complications, a lower incidence of postoperative adhesion formation, shorter hospital stays, and better cosmesis [1-4]. Oncological outcomes after laparoscopic resection for patients with colorectal cancer seem to be identical to outcomes after open surgery [5-8].

Although the laparoscopic approach likely contributes to reducing surgical site infections (SSIs) after colorectal surgery, SSIs remain one of the most common complications after this surgery [9-14]. SSIs disrupt cosmesis and increase the risk of a longer postoperative hospital stay, which leads to an increase in costs. Furthermore, an incisional hernia may develop during long-term follow-up. Therefore, it is important to reduce the incidence of SSIs to achieve optimum postoperative results.

At our institute, the method of non-suturing epidermis closure of the umbilical base has been used as an approach to prevent umbilical wound infection after laparoscopic colectomy in patients with colon cancer. The aim of the current study was to perform a retrospective evaluation of the ability of this closure method to protect against the occurrence of postoperative umbilical wound infection in this patient population.

Methods

Patients

From January 2010 to December 2014, 178 consecutive patients diagnosed with colon cancer underwent elective laparoscopic colectomy at our institute. Laparoscopic colorectal surgery is generally indicated for all patients with resectable colorectal cancers. Exclusion criteria for laparoscopic surgery include anticipated severe adhesions due to previous multiple laparotomies, simultaneous resection of other organs because of tumor invasion or synchronous metastasis, or intolerance of the procedure. The mean follow-up period was 21.9 ± 16.1 months. All patients provided informed written consent.

Preparation and perioperative management

When the bowel or rectum was not severely stenotic, patients received mechanical bowel preparation with 2 L polyethylene glycol electrolyte oral solution the day before surgery. Oral antibiotics were not administered during the bowel preparation. Preoperative fasting was initiated after the midday meal the day before surgery, but patients were allowed unlimited intake of clear fluids until 2 hours before the induction of anesthesia. A dose of 1 g flomoxef was administered intravenously within 30 minutes before skin incision and then every 3 hours during surgery. Twice daily administration of 1 g intravenous flomoxef was continued until the second postoperative day (POD). Nasogastric tubes were inserted only

during surgery. When the postoperative condition of the patient was satisfactory, clear fluids and solid food were reinstated on POD 1 and POD 3, respectively.

Operative technique

1) Umbilical incision and insertion of trocars

After induction of general anesthesia, the patient was placed in the lithotomy position. The umbilical skin and subcutaneous fat were incised using a scalpel. The linea alba was then incised without cutting the tight adhesion between the fascia and subcutaneous tissue underlying the umbilicus (Fig. 1). A 12-mm camera port (Endopath Xcel^{TM}, Ethicon Endo-Surgery, Cincinnati, OH, USA) was inserted after opening the peritoneum. The abdomen was then insufflated with CO_2 to a pressure of 10 mm Hg, and one 12-mm and three 5-mm trocars (Endopath Xcel^{TM}) were inserted. For reduced port surgery, a SILS^{TM} port (Covidien Ltd, Norwalk, CT, USA) with 3 built-in trocars was placed through a 30-mm umbilical incision. One additional port (Endopath Xcel^{TM}) was also inserted into the right lower quadrant. Harmonic ACE (Ethicon Endo-surgery) and Ligasure^{TM} (Covidien, Ltd.) suture materials were used for mobilization and dissection during the procedure.

2) Laparoscopic colectomy procedures

Following exploration of the abdomen, the mesocolon was mobilized and the

subsequent lymph node dissection was performed in accordance with the 2010 Japanese Society for Cancer of the Colon and Rectum guidelines [15], using the complete mesocolic excision with central vascular ligation technique [16]. For lesions located in the cecum to the proximal sigmoid colon, the umbilical wound was extended approximately 5 cm and protected using an Alexis wound retractor (Applied Medical, Rancho Santa Margarita, CA, USA). The colon and tumor were then extracted and transected extracorporeally using a linear stapling device. The bowel was anastomosed extracorporeally in a functional end-to-end fashion using a linear stapler. For tumors in either the distal sigmoid colon or rectosigmoid colon, the distal side of the rectum was clipped, irrigated, and then transected using staples applied with an endoscopic linear stapling device. After the umbilical wound was extended approximately 3 cm and protected by the Alexis wound retractor, the proximal colon was transected extracorporeally. Then, reconstruction was performed intracorporeally using a double-stapling technique and a 25-mm or 29-mm circular stapler (Proximate™ ILS stapler, Ethicon Endo-surgery) as previously described [17]. After lavage of the abdominal cavity, a closed drain was inserted into the subphrenic or intrapelvic space.

3) Umbilical wound closure

The umbilical fascia was closed with interrupted 0-Vicryl™ sutures (Ethicon, Somerville, NJ, USA). After irrigation with 500 mL saline solution, approximately 1 cm of

the umbilical wound and other trocar site edges were closed with skin staples. The base of the umbilical epidermis was compressed using a cotton ball without suturing and then wrapped with a vapor-permeable film (IV3000™; Smith and Nephew, Hull, UK) that maintained the shape and cleanliness of the umbilicus (Fig. 2).

Definition of umbilical wound infection

Wound infections within 30 days of surgery were classified according to the Centers for Disease Control and Prevention (CDC) criteria as superficial SSIs, which involved only the skin and subcutaneous tissue, or deep SSIs, which involved the muscle and fascial layers but not the organ space [18]. The criteria used to diagnose a wound infection included erythema, cellulitis, localized pain, swelling, tenderness, or purulent or culture-positive discharge. The condition of the umbilical wound was observed every day during the hospital stay. If a patient was discharged before POD 30, the condition of the wound was evaluated at an outpatient clinic.

Results

Patient demographics and tumor characteristics

The patients included 109 males and 69 females, with a mean (± standard deviation) age of 67.6 ± 9.9 years and mean body mass index (BMI) of 22.9 ± 3.9 kg/m^2. Forty-two

(23.6%) patients had diabetes mellitus. The mean tumor size was 39.0 ± 20.6 mm diameter. The tumor was located in the cecum in 28 (15.7%) patients, ascending colon in 40 (22.5%) patients, transverse colon in 27 (15.2%) patients, descending colon in 11 (6.2%) patients, sigmoid colon in 38 (21.3%) patients, and rectosigmoid colon in 34 (19.1%) patients. The pathological stage according to the Japanese Society for Cancer of the Colon and Rectum 2010 guidelines [15] was as follows: pStage 0, 14 (7.9%) patients; pStage I, 47 (26.4%) patients; pStage II, 58 (32.6%) patients; pStage III, 42 (23.6%) patients; and pStage IV, 17 (9.6%) patients (Table 1).

Operative procedures and outcomes

A total of 150 patients underwent the conventional five-port method, and 28 patients underwent reduced port surgery using a SILS™ port. The reconstruction procedure was functional end-to-end anastomosis in 125 patients and the double-stapling technique in 53 patients.

Conversion from laparoscopic to open surgery was required in 3 (1.7%) patients. One of these patients had a large (92 mm) tumor, and 2 had massive hemorrhage. The mean surgery time was 174 ± 48 min, mean intraoperative blood loss was 29 ± 75 mL, and mean postoperative hospital stay was 10.5 ± 6.7 days. Only 1 (0.6%) patient required readmission within 30 days of the initial operation. This patient was admitted because of a small bowel

obstruction, which was treated with fasting and Daikenchuto (a herbal medicine); it resolved after 4 days. The mean number of harvested lymph nodes was 16.8 ± 10.7 (Table 2).

Incidence of umbilical wound infection

Umbilical wound infection occurred in 2 (1.1%) patients: superficial infection was noted in 2 (1.1%) patients and deep wound infection in none. The demographics and tumor characteristics of the 2 patients with an umbilical wound infection are presented in Table 3. Both patients exhibited umbilical wound erythema with swelling, and purulent discharge was apparent after the wound was opened at the bedside. Wound cultures were positive for *Enterococcus raffinosus* in 1 patient and *Bacteroides fragilis* in the other. In both patients, the infection resolved within a few days after the single bedside drainage procedure. The length of postoperative hospital stay was 10 days for both patients; the hospital stay was not prolonged because of the wound infection in either case. A representative umbilical wound at 1 year after surgery is shown in Figure 3. No patient, including the 2 who developed a wound infection, was dissatisfied with the appearance of the umbilicus at or after hospital discharge.

Incidence of postoperative complications

Postoperative complications rated as Clavien-Dindo classification [19] grade II or higher occurred in 15 (8.4%) patients (Table 4). Grade II complications were noted in 11

(6.2%) patients, and ≥Grade III complications occurred in 4 (2.2%) patients. One patient with a dilated cardiomyopathy experienced decompensated congestive heart failure on POD 4. This patient was treated in an intensive care unit but died on POD 29. Thus, the operative mortality was 0.6% (1/176). Spastic angina occurred in 1 patient on POD 3, which required coronary angiography and treatment with a calcium channel blocker. Anastomotic leakage occurred in 2 patients. In 1 patient, the leakage occurred on POD 16 after laparoscopic transverse colectomy for a lesion of the splenic flexure; it required an emergency ileostomy. In the other patient, the leakage occurred on POD 2 after laparoscopic high anterior resection for rectosigmoid colon cancer; it also required an emergency ileostomy.

Discussion

In this study, we achieved a low (1.1%) incidence of postoperative wound infection following laparoscopic resection for colon cancer. Compared to open colorectal surgery, laparoscopic colorectal surgery itself is protective against SSIs, especially wound infections [9-14]. In prospective studies of laparoscopic colectomy, wound infections occurred in 3.2–5% of patients with colon cancer [20, 21]. Accordingly, our results were comparable to or better than these studies. We consider that our non-closure of the umbilical epidermis method contributed considerably to the prevention of umbilical wound infection because it produced effective drainage. Instead of closing the umbilical wound with sutures, the wound was

covered by a vapor-permeable film, IV3000™, which has a moisture vapor transmission rate of approximately 12,000 g/m^2 per day [22]. In doing so, the umbilical wound was prevented from drying, and cleanliness was maintained because excessive fluid discharged from the wound was able to evaporate through the film. As well, it is likely that our comprehensive use of a number of other strategies during surgery also contributed to the prevention of umbilical wound infections. Intraoperatively, we are always highly attentive to manipulating the tissues gently, avoiding direct contact with wounds by gloved hands, minimizing intraoperative bleeding, and reducing the time for both intra- and extra-corporeal manipulation. As a result, we have achieved relatively favorable operative outcomes, as shown by a mean surgery time of 174 ± 48 minutes, mean intraoperative blood loss of 29 ± 75 mL, and rate of conversion to open surgery of 1.7%. Therefore, we consider that these attitudes and behaviors, in addition to the non-suturing epidermal closure method, were responsible for our 1.1% umbilical wound infection rate.

Although we used a non-suture epidermal closure, the shape of the navel maintained cosmesis during the mean follow-up period of approximately 22 months after surgery. We attribute this successful outcome to maintaining the tight connection between the fascia and subcutaneous fat underlying the navel. Preserving this tight adhesive connection is a key aspect of our method. Use of the vapor-permeable film, IV3000™, is also important for maintaining cosmesis, as it allowed the umbilical wound to be compressed for 7 days after

surgery to produce a dimple with the appearance of a natural navel, without exposure to excessive fluid discharge. We did not conduct a detailed follow-up survey, but no patient complained about wound cosmesis (including the appearance of the umbilicus) at hospital discharge or during the mean follow-up period of approximately 22 months. There was also no evidence that a delayed complication, such as an incisional hernia, occurred during follow-up. These findings likely resulted from the low incidence of wound infection. A survey regarding pain, cosmesis, degree of satisfaction, and presence of an incisional hernia is currently being planned to more fully clarify the clinical benefits of our technique in addition to its protective effects against wound infection.

We could not identify risk factors associated with SSI after laparoscopic colectomy in this study because of the low incidence of infection. The patients who experienced wound infection had favorable characteristics, including a BMI <30 kg/m^2, tumor <5 cm diameter, and American Society of Anesthesiologists' (ASA) score ≤2, whereas other patients with less favorable characteristics (e.g., BMI ≥30 kg/m^2, ASA score of 3 or higher, Stage IV tumor, circumferentially narrowed tumor, or conversion to open surgery) did not experience wound infection. Commonly, obesity is regarded as a risk for wound infection after laparoscopic colorectal surgery. Reported wound infection rates are significantly higher in obese patients than in nonobese patients: 11.3–20.6% versus 3.5–7.5%, respectively [23-26]. In our current study, the mean BMI was 22.9 kg/m^2 and only 50 patients (24.2%) had a BMI >25.0 kg/m^2.

Thus, further investigations, including studies involving a greater number of obese patients, are required to more fully define the effect of our non-closure method on wound infection.

In conclusion, umbilical wound closure involving non-suturing of the epidermis can be an effective method of preventing postoperative wound infection. Since our study included a small number of patients and no control arm, further investigations using randomized controlled studies and larger numbers of patients will be necessary to firmly establish the benefits of this closure method.

Author Disclosure Statement: Drs. Shibasaki, Homma, Yoshida, Kawamura, Takahashi, and Taketomi have no conflicts of interest or financial ties to disclose.

References

1. Schwenk W, Haase O, Neudecker J, Muller JM (2005) Short term benefits for laparoscopic colorectal resection. Cochrane Database Syst Rev Cd003145.

2. Braga M, Vignali A, Zuliani W et al (2005) Laparoscopic versus open colorectal surgery: cost-benefit analysis in a single-center randomized trial. Ann Surg 242:890-5.

3. Aly EH (2009) Laparoscopic colorectal surgery: summary of the current evidence. Ann R Coll Surg Engl 91:541-4.

4. van der Pas MH, Haglind E, Cuesta MA et al (2013) Laparoscopic versus open surgery for rectal cancer (COLOR II): short-term outcomes of a randomised, phase 3 trial. Lancet Oncol 14:210-8.

5. Bonjer HJ, Hop WC, Nelson H et al (2007) Laparoscopically assisted vs open colectomy for colon cancer: a meta-analysis. Arch Surg 2007;142:298-303.

6. Kuhry E, Schwenk WF, Gaupset R, Romild U, Bonjer HJ (2008) Long-term results of laparoscopic colorectal cancer resection. Cochrane Database Syst Rev Cd003432.

7. Lacy AM, Delgado S, Castells A et al (2008) The long-term results of a randomized clinical trial of laparoscopy-assisted versus open surgery for colon cancer. Ann Surg 248:1-7.

8. Buunen M, Veldkamp R, Hop WC et al (2009) Survival after laparoscopic surgery versus open surgery for colon cancer: long-term outcome of a randomised clinical trial. Lancet Oncol 10:44-52.

9. Kiran RP, El-Gazzaz GH, Vogel JD, Remzi FH (2010) Laparoscopic approach significantly reduces surgical site infections after colorectal surgery: data from national surgical quality improvement program. J Am Coll Surg 211:232-8.

10. Yamamoto S, Fujita S, Akasu T et al (2007) Wound infection after elective laparoscopic surgery for colorectal carcinoma. Surg Endosc 21:2248-52.

11. Kennedy GD, Heise C, Rajamanickam V, Harms B, Foley EF (2009) Laparoscopy decreases postoperative complication rates after abdominal colectomy: results from the national surgical quality improvement program. Ann Surg 249:596-601.

12. Kang CY, Chaudhry OO, Halabi WJ et al (2012) Outcomes of laparoscopic colorectal surgery: data from the Nationwide Inpatient Sample 2009. Am J Surg 204:952-7.

13. Wilson MZ, Hollenbeak CS, Stewart DB (2014) Laparoscopic colectomy is associated with a lower incidence of postoperative complications compared with open colectomy: a propensity score-matched cohort analysis. Colorectal Dis 16:382-9.

14. Aimaq R, Akopian G, Kaufman HS (2011) Surgical site infection rates in laparoscopic versus open colorectal surgery. Am Surg 77:1290-4.

15. Watanabe T, Itabashi M, Shimada Y et al (2012) Japanese Society for Cancer of the Colon and Rectum (JSCCR) guidelines 2010 for the treatment of colorectal cancer. Int J Clin Oncol 17:1-29.

16. Hohenberger W, Weber K, Matzel K, Papadopoulos T, Merkel S (2009) Standardized

surgery for colonic cancer: complete mesocolic excision and central ligation--technical notes and outcome. Colorectal Dis 11:354-64.

17. Kawamata F, Homma S, Minagawa N, Kawamura H, Takahashi N, Taketomi A (2014) Comparison of single-incision plus one additional port laparoscopy-assisted anterior resection with conventional laparoscopy assisted anterior resection for rectal cancer. World J Surg 38:2716-23.

18. Horan TC, Gaynes RP, Martone WJ, Jarvis WR, Emori TG (1992) CDC definitions of nosocomial surgical site infections, 1992: a modification of CDC definitions of surgical wound infections. Infect Control Hosp Epidemiol 13:606-8.

19. Dindo D, Demartines N, Clavien PA (2004) Classification of surgical complications: a new proposal with evaluation in a cohort of 6336 patients and results of a survey. Ann Surg 240:205-13.

20. Yamamoto S, Inomata M, Katayama H et al (2014) Short-term Surgical Outcomes From a Randomized Controlled Trial to Evaluate Laparoscopic and Open D3 Dissection for Stage II/III Colon Cancer: Japan Clinical Oncology Group Study JCOG 0404. Ann Surg 260:23-30.

21. Guillou PJ, Quirke P, Thorpe H et al (2005) Short-term endpoints of conventional versus laparoscopic-assisted surgery in patients with colorectal cancer (MRC CLASICC trial): multicentre, randomised controlled trial. Lancet 365:1718-26.

22. Jones A (2004) Dressings for the management of catheter sites. JAVA 9:26-33.

23. Pikarsky AJ, Saida Y, Yamaguchi T et al (2012) Is obesity a high-risk factor for laparoscopic colorectal surgery? Surg Endosc 16:855-8.

24. Tsujinaka S, Konishi F, Kawamura YJ et al (2008) Visceral obesity predicts surgical outcomes after laparoscopic colectomy for sigmoid colon cancer. Dis Colon Rectum 51:1757-65.

25. Kamoun S, Alves A, Bretagnol F et al (2009) Outcomes of laparoscopic colorectal surgery in obese and nonobese patients: a case-matched study of 180 patients. Am J Surg 198:450-5.

26. Singh A, Muthukumarasamy G, Pawa N et al (2011) Laparoscopic colorectal cancer surgery in obese patients. Colorectal Dis 13:878-83.

Figure Legends

Figure 1. The umbilical skin and subcutaneous fat were incised with a sharp knife, and then the linea alba was incised. The tight adhesion between the fascia and subcutaneous tissues (white arrows) underlying the umbilicus was not included in the incision.

Figure 2. A. The umbilical fascia was closed with interrupted 0-Vicryl™ sutures. **B.** This shows the umbilical wound after closing the umbilical fascia. The umbilical wound edges were closed with a skin stapler. Because of tight adhesion between the fascia and subcutaneous tissues was preserved, the umbilical shape was maintained without suturing the epidermis. **C.** The center of the umbilical epidermis was compressed using a cotton ball without suturing and then covered with a vapor-permeable film to maintain the shape and cleanliness of the umbilicus.

Figure 3. A representative example of an umbilical wound at 1 year after surgery.

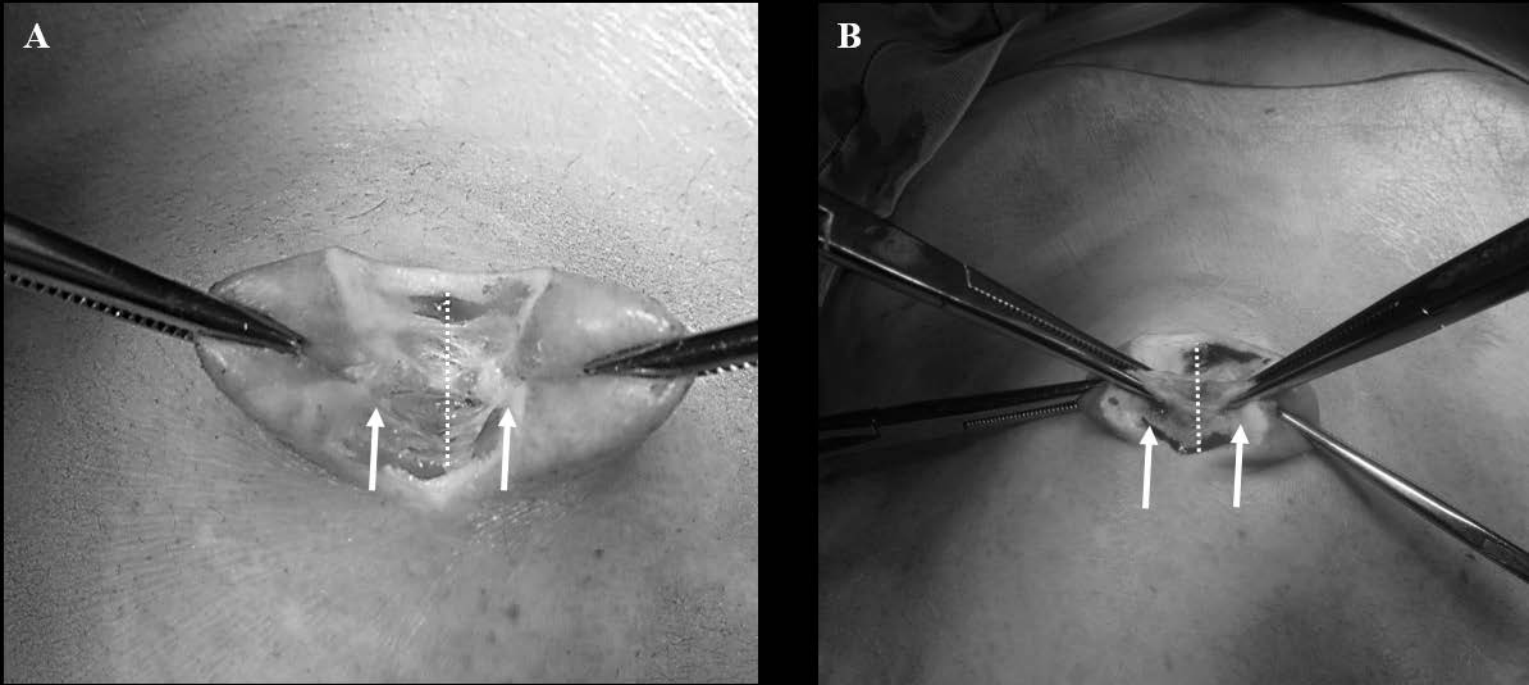
A
B

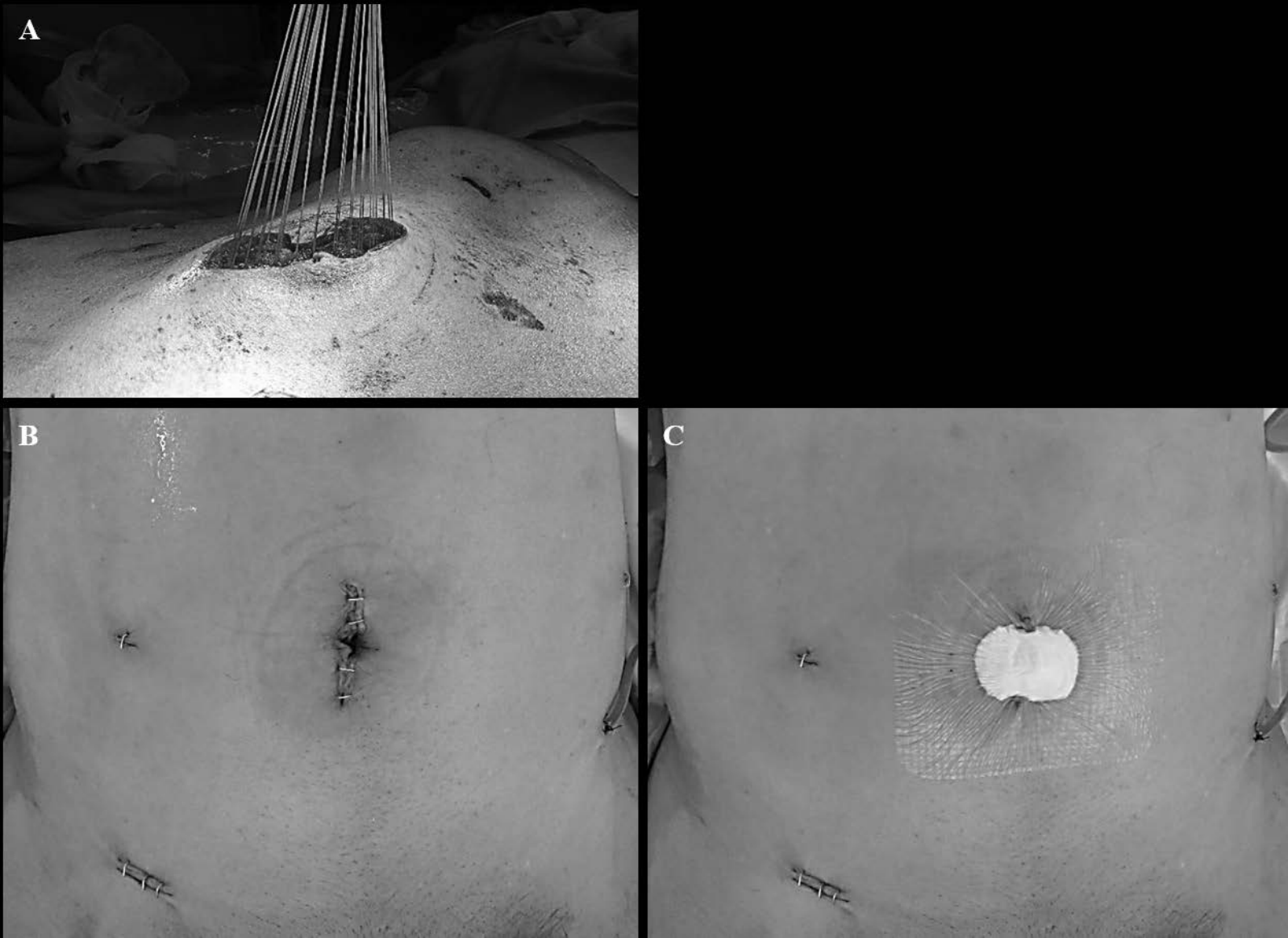
A
B
C

Table 1. Patient demographics and tumor characteristics (n=178)

Patient demographics		Number (%)	Mean ± SD
Age (years)			67.6 ± 9.9
Gender	Male	109 (61.2%)	
	Female	69 (38.8%)	
Weight (kg)			60.0 ± 12.0
BMI (kg/m^2)			22.9 ± 3.9
Diabetes		42 (23.6%)	
ASA physical status	1	37 (20.8%)	
	2	116 (65.2%)	
	3	25 (14.0%)	
Tumor characteristics			
Size (mm)			39.0 ± 20.6
Location	C / A / T / D / S / Rs	28 / 40 / 27 / 11 / 38 / 34	
pStage	0	14 (7.9%)	
	I	47 (26.4%)	
	II	58 (32.6%)	
	III	42 (23.6%)	
	IV	17 (9.6%)	

Abbreviations: A, ascending colon; ASA, American Society of Anesthesiologists'; BMI, body mass index; C, cecum; D, descending colon; Rs, rectosigmoid colon; S, sigmoid colon; T, transverse colon; SD, standard deviation

Table 2. Surgical procedures and outcomes (n=178)

Laparoscopic procedure	Number (%)	Mean ± SD
Conventional laparoscopic surgery	150 (84.3%)	
Reduced-port laparoscopic surgery	28 (15.7%)	
Reconstruction method		
Functional end-to-end anastomosis	125 (70.2%)	
Double stapling technique	53 (29.8%)	
Operative outcomes		
Conversion to open surgery	3 (1.7%)	
Operation time (min)		175 ± 48
Blood loss (mL)		29 ± 75
Length of hospital stay (days)		10.5 ± 6.7
Number of harvested lymph nodes		16.8 ± 10.7
Readmission within 30 days of operation	1 (0.6%)	

Abbreviations: SD, standard deviation

Table 3. Characteristics and results for the two patients with a wound infection

	Age (years)	M / F	BMI (kg/m^2)	ASA score	Location	Size (mm)	pStage	Operation time (min)	Blood loss (mL)	Onset	Bacteria detected	Treatment	Postoperative hospital stay (days)
1	61	F	28.0	1	Ascending colon	39	T2N2M0 (pStageIIIB)	159	0	POD 7	*Enterococcus raffinosus*	Drainage at bedside[a]	10
2	71	F	16.7	2	Descending colon	25	T3N2M0 (pStageIIIB)	104	0	POD 7	*Bacteroides fragilis*	Drainage at bedside[a]	10

Abbreviations: ASA, American Society of Anesthesiologists'; BMI, body mass index; F, female; M, male; POD, postoperative day

[a] only 1 bedside drainage procedure was performed for both patients

Table 4. Postoperative complications of Clavien-Dindo classification Grade II or higher within 30 days after surgery (n=178)

Complications		Grade II	≥ Grade III	Total	
Local	Small bowel obstruction	5		5	(2.8%)
	Anastomotic bleeding	1		1	(0.6%)
	Anastomotic leakage		2	2	(1.1%)
Systemic	Acute heart failure		1 (Grade V)	1	(0.6%)
	Spastic angina		1	1	(0.6%)
	Urinary tract infection	3		3	(1.7%)
	Enteritis	1		1	(0.6%)
	Catheter-related infection	1		1	(0.6%)
Total		11 (6.2%)	4 (2.2%)	15	(8.4%)