



Title	An intrathoracic ectopic liver with pleural effusion in a dog
Author(s)	Iwaki, Yoshimi; Takagi, Satoshi; Morishita, Keitaro; Hanazono, Kiwamu; Hosoya, Kenji; Okumura, Masahiro
Citation	Japanese Journal of Veterinary Research, 65(2), 95-99
Issue Date	2017-05
DOI	10.14943/jjvr.65.2.95
Doc URL	http://hdl.handle.net/2115/66487
Type	bulletin (article)
File Information	65-2 095-099.pdf



[Instructions for use](#)

An intrathoracic ectopic liver with pleural effusion in a dog

Yoshimi Iwaki¹⁾, Satoshi Takagi^{1,*)}, Keitaro Morishita¹⁾,
Kiwamu Hanazono¹⁾, Kenji Hosoya²⁾ and Masahiro Okumura²⁾

¹⁾ Veterinary Teaching Hospital, Department of Veterinary Clinical Sciences, Graduate School of Veterinary Medicine, Hokkaido University, Kita 18, Nishi 9, Kita-ku, Sapporo, Hokkaido, 060-0818, Japan

²⁾ Laboratory of Veterinary Surgery, Department of Veterinary Clinical Sciences, Graduate School of Veterinary Medicine, Hokkaido University, Kita 18, Nishi 9, Kita-ku, Sapporo, Hokkaido, 060-0818, Japan

Received for publication, August 30, 2016; accepted, March 31, 2017

Abstract

A 10-year-old, spayed female dog with intermittent coughing and respiratory distress was presented at our hospital. Thoracic radiographs revealed a 71 × 43 mm intrathoracic solitary mass. After one week, coughing worsened and pleural effusion was found. The intrathoracic mass had the same intensity as the liver in contrast-enhanced computed tomography images. There were no signs of diaphragmatic hernia, and attachment of the mass to the diaphragm and the caudal vena cava was observed during surgery. Histopathologically, the mass was composed of normal hepatic parenchyma, and based on this finding and the gross findings, it was diagnosed as an ectopic liver. Owing to its location, the ectopic liver may have caused regional venous occlusion, which resulted in the clinical symptoms observed.

Key Words: dog, intrathoracic ectopic liver, pleural effusion

Ectopic hepatic tissue is an autonomous island of normal hepatic parenchyma with no physical connection to normally positioned liver tissue. It is a rare anatomic anomaly in humans⁴⁾. Collan *et al.* (1978) divided human ectopic liver tissue into four distinct categories: (a) ectopic liver not connected to the main liver and usually attached to the gallbladder or intra-abdominal ligaments; (b) microscopic ectopic liver, which is found occasionally in the gallbladder wall; (c) a large accessory liver attached to the “mother” liver by a stalk; and (d) a small accessory liver

lobe attached to the main liver⁴⁾. In humans, an ectopic liver is often located adjacent to the gallbladder, pancreas, or spleen and is only rarely found in the thoracic cavity^{1,3,11,13)}. Although usually asymptomatic and discovered incidentally, an ectopic liver can be accompanied by chest pain, hemoptysis, or dry cough in humans^{6,14)}. In animals, there are only five reported cases of intrathoracic ectopic liver, one in cattle, two in dogs, and two in cats^{5,7-10)}. Coughing, anorexia and exercise intolerance were reported in the dogs and one of the cats^{5,8,10)}.

*Corresponding author: Satoshi Takagi, Veterinary Teaching Hospital, Department of Veterinary Clinical Sciences, Graduate School of Veterinary Medicine, Hokkaido University, Kita 18, Nishi 9, Kita-ku, Sapporo, Hokkaido, 060-0818, Japan

Fax: +81-11-706-5100. E-mail: staka@vetmed.hokudai.ac.jp

doi: 10.14943/jjvr.65.2.95

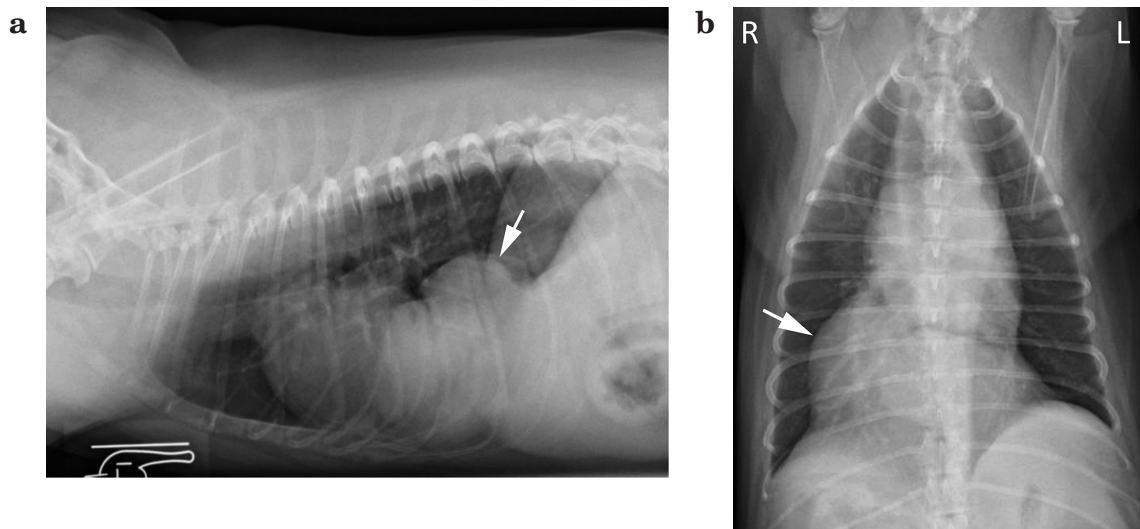


Fig. 1. Lateral (a) and ventrodorsal (b) thoracic radiographs of a 10-year-old dog. A soft tissue mass opacity is seen in the caudoventral region (arrow).

Herein we describe a case of an intrathoracic ectopic liver associated with respiratory distress due to pleural effusion in a dog. An intrathoracic ectopic liver might require surgical removal, despite the lack of symptoms in most cases.

A 10-year-old, 6.74 kg, spayed female crossbred dog (Maltese and toy poodle) experienced coughing and mild respiratory distress for 3 months. She was presented to the referring veterinarian and an intrathoracic mass was detected via chest radiography. The owner reported no history of traumatic events.

On presentation at our hospital, the dog was healthy except for intermittent coughing. A complete blood count and serum biochemical analysis revealed no abnormalities. Thoracic radiographs showed a 71×43 mm solitary mass with well-defined soft-tissue in the right caudoventral region of the thoracic cavity (Fig. 1). Ultrasound examination showed that the mass had the same ecogenicity as liver parenchyma; it contained normal hepatocytes as determined via fine needle biopsy. Tracheal collapse was clinically diagnosed via fluoroscopy and was assumed to be the main cause of the coughing.

For the treatment, prednisolone was prescribed at a dose of 0.37 mg/kg PO q24h. The dog's respiratory condition worsened the next

day. There was mild pleural effusion, atelectasis of the right cranial lobe of the lung and hyperventilation of caudal lung lobes (Fig. 2). Thoracocentesis was performed, and 120 ml of intrathoracic fluid was removed. The effusion was considered to be a modified transudate, as defined biochemically. The dog was anesthetized, and computed tomography (CT) was performed. The thoracic mass was $63 \times 43 \times 36$ mm and surrounded the caudal vena cava (Fig. 3). All branches of the intrahepatic portal vein were within the abdominal cavity, and an extra branch diverged from the central branch and continued to the intrathoracic mass (Fig. 4). No other abnormalities of hepatic vein or parenchyma was noted in the ectopic liver. The accessory lobe of the lung was compressed by the mass. There was no signs of lung lobe torsion, including abruptly ending bronchus, and trapped air.

Midline sternotomy and laparotomy were performed. The diaphragm was intact with no signs of dehiscence or rupture (Fig. 5a). Consistent with the CT images, a firm circumferential mass around the caudal vena cava was confirmed (Fig. 5b). The mass was divided into two portions and then removed. All normal liver lobes were present in the abdominal cavity. A thoracostomy tube was placed postoperatively, and the

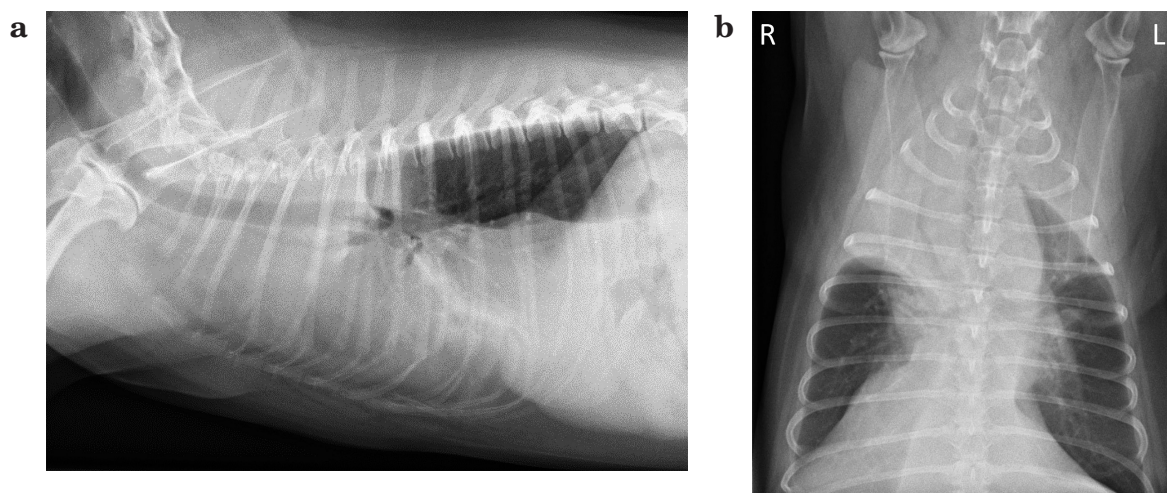


Fig. 2. Lateral (a) and ventrodorsal (b) thoracic radiograph the next day of first reference. There was mild pleural effusion and atelectasis of the right anterior lobe of the lung.

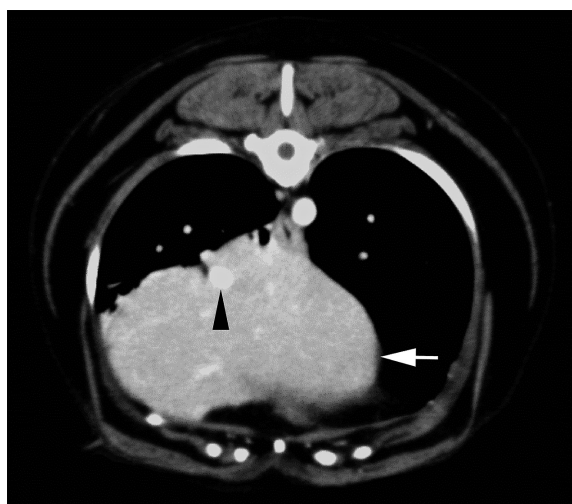


Fig. 3. A computed tomography scan shows a homogeneous, well-defined soft-tissue mass (arrow) that encircles caudal vena cava (arrow head).

diaphragm, muscle, fascia, subcutaneous tissue, and skin were closed using standard procedures.

Surgically removed tissue was submitted for histopathological examination. Microscopically, it consisted of normal hepatic parenchyma with lymphangiectasis. No abnormalities of vessel structures and no neoplastic features were noted. No complications were observed during the postoperative period, and clinical signs such as intrathoracic fluid accumulation and coughing disappeared immediately after surgery.

An intrathoracic ectopic liver is a rare finding,

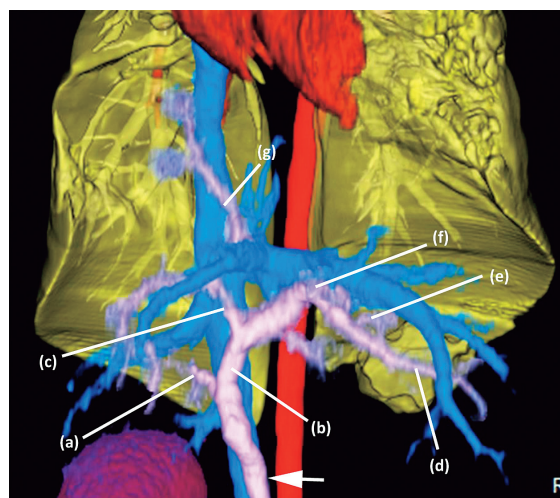


Fig. 4. Three-dimensional computed tomography image. The portal vein (arrow) divided into each branches. (a) right branch, (b) left branch, (c) central branch, (d) left lateral branch, (e) left medial branch, (f) quadrate branch. (g) portal vein which connected to the intrathoracic mass.

and a diagnosis via noninvasive procedures is challenging without CT. Potential differential diagnoses include a pulmonary mass, a chest wall mass, and diaphragmatic herniation. The density of ectopic liver tissue is similar to that of normal liver tissue. Tracking the portal vein via CT helps distinguish the liver lobes. The canine portal vein generally divides into a right and left branch. The right branch supplies the caudate process and the right lateral lobe. The left branch

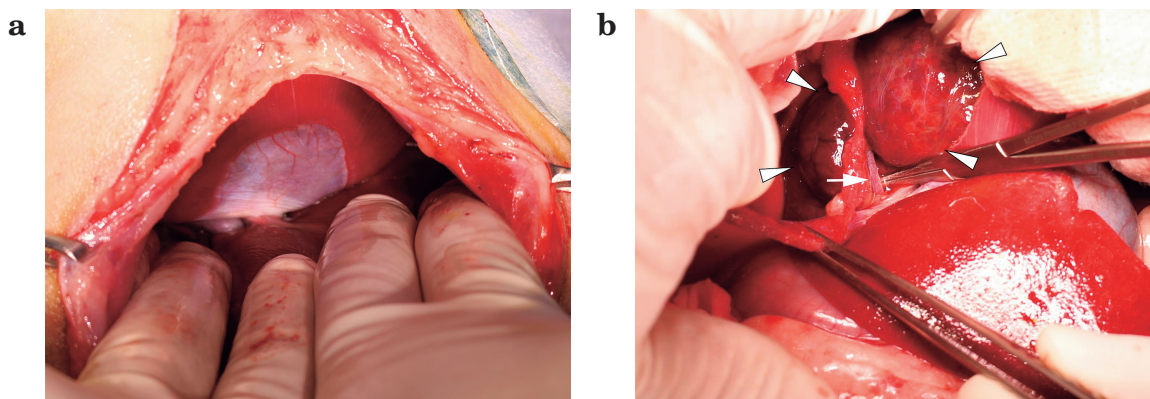


Fig. 5. Intraoperative findings of the intrathoracic ectopic liver. (a) The diaphragm was intact and there are no evidence of dehiscence or rupture. (b) The intrathoracic ectopic liver (arrow head) encircled and attached to the caudal vena cava (arrow). It could be manually rotated around the caudal vena cava. The diaphragm was intact.

usually divides into a central branch that supplies the right medial lobe and papillary process, and ultimately divides into the left lateral, left medial, and quadrate branches, which supply their respective lobes¹²⁾. In this case, all branches of the portal vein were present in the abdominal cavity, and an additional branch diverging from the central branch continued to the intrathoracic mass.

In the dog in our study, the intrathoracic liver tissue might be a congenital abnormality as she had no history of chest trauma that might have damaged the diaphragm. The possible mechanisms of intrathoracic ectopic liver development in humans are congenital abnormality, acquisition secondary to traumatic diaphragmatic hernia, and acquisition secondary to hematogenous dissemination of liver tissue following a heart transplantation procedure^{2,13)}. The liver begins as a bud from a ventral outgrowth of the most caudal part of the foregut in the fourth week of embryogenesis and is always in close proximity to the diaphragm^{2,15)}. The diaphragm arises from the transverse septum, a mesodermal plate that encloses the two pleuroperitoneal canals that will separate the thoracic and abdominal cavities when fully developed^{14,15)}. There are several possible explanations of an isolated heterotopic liver nodule in the chest. The most probable is the formation of an isolated liver lobe due to

atrophy or regression of its original connection to the orthotopic liver. Another possibility is the development of an entirely separate liver bud in the foregut^{2,15)}.

The dog in our case developed more severe clinical symptoms than those previously reported^{5,8,10)}. Patients with intrathoracic ectopic or accessory liver tend to have mild clinical signs, because of its congenital nature^{14,15)}. In human patients, clinical symptoms including chest pain, hemoptysis, and dry cough have been reported^{6,14)}. Animals with an intrathoracic ectopic liver occasionally exhibit coughing, anorexia, and exercise intolerance; pleural effusion has not been reported previously^{5,8,10)}. In this case, the examination process or unusual environment might induce the rotation of ectopic liver portion and the pleural effusion. It suggests that even an ectopic liver tissue is a congenital abnormality, it can cause a critical situation.

In our case, the pleural effusion was a modified transudate. There was no abdominal fluid accumulation, suggesting that the cause of the effusion was venous circulatory insufficiency, perhaps due to exudation from the intrathoracic ectopic liver tissue. At the time of surgery, the mass was able to rotate around the caudal vena cava via the region attaching it to the diaphragm. Strangulation of the hepatic vein in the ectopic liver may have occurred when the

mass rotated, and this may have caused the portal hypertension in the intrathoracic ectopic liver. In addition, other possible cause of pleural effusion is that the vena cava was compressed by the intrathoracic ectopic liver and partially obstructed. Because the intrathoracic ectopic liver lobe had same blood supply as normal liver lobes, theoretically, compression of vena cava can cause hypertension in the intrathoracic ectopic liver lobe. However we did not detect abdominal effusion when pleural effusion was found.

The coughing resolved immediately after surgery; this may reflect the decompression of the accessory lung lobe, following removal of the mass. There is a report of a dog which has the hyperemic and consolidated accessory lung lobe with intrathoracic ectopic liver tissue that diagnosed by exploratory surgery¹⁰. The dog in this report showed coughing and the clinical sign was resolved after surgery as in our case. The ectopic liver may be a congenital abnormality that preceded the coughing and its location may determine whether clinical signs appear.

In conclusion, there are very few case reports of an intrathoracic ectopic liver in veterinary medicine. To our knowledge, this is the first report of a canine case of pleural effusion associated with an intrathoracic ectopic liver. This anomaly has not been recognized as a severe clinical problem in previous reports; however, pleural effusion can cause severe dyspnea. Therefore, an ectopic liver may require surgical removal even when the animal exhibits no clinical signs.

References

- 1) Babu R, Van der Avoult A. Ectopic intrathoracic liver. *Pediatr Surg Int* 17, 461-462, 2001.
- 2) Beiler HA, Sergi C, Wagner G, Zachariou Z. Accessory liver in an infant with congenital diaphragmatic hernia. *J Pediatr Surg* 36, E7, 2001.
- 3) Choi SU, Kim HK, Kim J. Heterotopic supradiaphragmatic liver combined with intralobar pulmonary sequestration. *Ann Thorac Surg* 85, 1809-1810, 2008.
- 4) Collan Y, Hakkiluoto A, Hastbacka J. Ectopic liver. *Ann Chir Gynaecol* 67, 27-29, 1978.
- 5) Dhaliwal RS, Lacey JK. Ectopic hepatic parenchyma attached to the diaphragm: stimulating a pulmonary mass in a cat. *J Am Anim Hosp Assoc* 45, 39-42, 2009.
- 6) Han S, Soyly L. Accessory liver lobe in the left thoracic cavity. *Ann Thorac Surg* 87, 1933-1934, 2009.
- 7) Hifumi T, Kawaguchi H, Yamada M, Miyoshi N. Intrathoracic ectopic liver in a cow. *J Vet Med Sci* 76, 711-713, 2014.
- 8) Hifumi T, Mashita T, Harasaki Y, Ano N, Nomura K, Yasuda J, Kawaguchi H, Miyoshi N. Intrathoracic ectopic liver in a dog. *J Jpn Vet Med Assoc* 68, 64-67, 2015.
- 9) Jones BR, Alley MR, Cribb SB. Pericardial ectopic liver in a cat. *NZ Vet J* 34, 106-108, 1986.
- 10) Lande R, Dvorak L, Gardiner DW, Bahr A. Ectopic intrathoracic hepatic tissue and accessory lung lobe aplasia in a dog. *J Am Anim Hosp Assoc* 51, 342-345, 2015.
- 11) Martinez CA, de Resende HC Jr, Rodrigues MR, *et al.* Gallbladder-associated ectopic liver: A rare finding during a laparoscopic cholecystectomy. *Int J Surg Case Rep* 4, 312-315, 2013.
- 12) Mayhew PD, Weisse C. Liver and biliary system. In: Tobias KM, Johnston SA, editor. *Veterinary Surgery Small Animal*. Tobias KM, Johnston SA. eds. Saunders, Philadelphia. pp. 1601-1603, 2012.
- 13) Mehta RI, Lai CK, Kee S, Fishbein MC. Intrapulmonary ectopic liver after orthotopic heart transplantation. *Arch Pathol Lab Med* 134, 1060-1062, 2010.
- 14) Rendina EA, Venuta F, Pescarmona EO, Martelli M, Ricci C. Intrathoracic lobe of the liver. Case report and review of the literature. *Eur J Cardiothorac Surg* 3, 75-78, 1989.
- 15) Tancredi A, Cuttitta A, de Martino DG, Scaramuzzi R. Ectopic hepatic tissue misdiagnosed as a tumor of lung. *Updates Surg* 62, 121-123, 2010.