Laparoscopic resection of paraaortic/paracaval neurogenic tumors: Surgical outcomes and technical tips.

Running title: Laparoscopic surgery for neurogenic tumors.

Takashige Abe[1], Ataru Sazawa[2], Toru Harabayashi[3], Yuichiro Oishi[1], Naoto Miyajima[1], Kunihiko Tsuchiya[1], Satoru Maruyama[1], Hiromi Okada[4], Nobuo Shinohara[1]

[1]Department of Urology, Hokkaido University Graduate School of Medicine, Sapporo, Japan

[2]Department of Urology, Obihiro-Kosei General Hospital, Obihiro, Japan

[3]Department of Urology, Hokkaido Cancer Center, Sapporo, Japan

[4]Department of Surgical Pathology, Hokkaido University Hospital, Sapporo, Japan

Address correspondence to: Takashige Abe, Department of Urology, Hokkaido University Graduate School of Medicine, North-15, West-7, North Ward, Sapporo 060-8638, Japan

Tel.: +81-11-7161161 Ext.5949 Fax: +81-11-7067853

E-mail: takataka@rf6.so-net.ne.jp

Conflict of interest: None.

Key words: neurogenic tumor, paraganglioma, laparoscopic surgery

Abstract

Background: Due to variations in location and size, laparoscopic surgery for paraaortic or paracaval neurogenic tumors is challenging. We evaluated the surgical outcomes, as well as surgical tips and tricks.

Methods: Between 2000 and 2015, 25 procedures were performed in 24 patients. One patient underwent second surgery due to the recurrence of paraganglioma. Data were collected on the tumor diameter, tumor location, perioperative outcomes, pathology, and last known disease status. Regarding the operative procedures, we reviewed the operative charts or videos to identify surgical tips and tricks.

Results: The median tumor diameter was 5.0 cm (range, 1.5-10). The tumor location was suprahilar in 10, hilar in 6, and infrahilar in 9. Regarding the approach, a transperitoneal approach was selected in 24 cases and retroperitoneal approach in 1. The median operative time and blood loss were 208 minutes (range, 73-513) and 10 mL (range, 0-1,020), respectively. No patient required blood transfusion or conversion to open surgery. Pathological examination revealed paraganglioma in 12, ganglioneuroma in 7, and schwannoma in 6. At the last follow-up, 23 patients were free of disease, while one patient developed metastatic multiple recurrence of paraganglioma 54 months after the second laparoscopic surgery. A review of the surgical records revealed several tips and tricks, including taping the vena cava/ renal vein (n=2) being helpful for detaching a retrocaval tumor from these great vessels, or

rotating the kidney to provide a favorable operative view of tumors behind the renal hilum (n=2). In recent cases, 3D-CT was helpful for preoperative planning.

Conclusion: Laparoscopic resection of paraaortic or paracaval neurogenic tumors is feasible in experienced hands. Surgeons should be familiar with detaching maneuvers around great vessels and the mobilization of adjacent organs. Careful preoperative planning is mandatory.

Introduction

Based on the accumulated experiences of laparoscopic extirpative surgeries including retroperitoneal lymph node dissection, the indication of laparoscopic surgery has now broadened to the management of rare retroperitoneal tumors. Although there have been small case series or anecdotal reports showing successful outcomes of laparoscopic management of paraaortic or paracaval neurogenic tumors [1-7], these tumors could arise anywhere around great vessels, and surgeons need to be familiar with surgical tips and tricks.

The present study describes the authors' experience and surgical "tips and tricks" for the laparoscopic resection of paraaortic or paracaval neurogenic tumors.

Patients and Methods

After institutional review board approval, we reviewed our prospectively maintained database. Between 2000 and 2015, 25 laparoscopic procedures were performed in 24 patients with paraaortic/paracaval neurogenic tumors. One female patient underwent second surgery due to the recurrence of paraganglioma around the vena cava. Regarding preoperative radiological assessments, abdominal CT and MRI were performed based on the surgeons' decision. In patients with suspected paraganglioma based on their symptoms and laboratory data, metaiodobenzylguanidine (MIBG) scintigraphy was performed to rule out multiple diseases. Very recently, PET-CT was also carried out in selected cases. Taking these radiological findings together, we made a preoperative diagnosis (paraganglioma: n=13, other benign neurogenic tumors: n=12). Preoperative assessment of each patient's general condition was carefully performed. Preparation including α-adrenergic blockade in paraganglioma patients was also performed. Generally speaking, we considered a laparoscopic approach for this disease entity if the tumor was considered to be a benign neurogenic tumor with a size of less than 10 cm. In the present cohort, surgeries were performed mainly by three surgeons (TA, AS, and HT).

Procedures

Patients with paraaortic tumors were placed in the right flank position, and those

with paracaval or interaortocaval tumors were placed in the left flank position. Although the surgical approach (transperitioneal or retroperitoneal) and port locations were determined based on the tumor location and surgeons' preference, we prefer a transperitoneal approach because of the wider space and greater number of landmarks compared to a retroperitoneal approach. Figure 1 shows the port positions. In cases with suprahilar/hilar tumors, subcostal placement was selected (Figure 1a), and in those with infrahilar tumors, ports were placed in a diamond shape, as shown in Figure 1b. Recently, we actively construct preoperative 3D-CT images in order to clarify the relationship between the tumor location and adjacent vessels for surgical planning, although we don't have strict prospective guidelines for 3D-CT construction.

Analysis

From the database and medical charts, data were collected on the tumor diameter, tumor location, perioperative outcomes, pathology, and last known disease status. Postoperative complications were graded according to the modified Clavien system [8]. Regarding the operative procedures, we reviewed the operative notes or surgical videos to identify tips and tricks.

Results

Surgical outcomes

Table 1 shows a summary of the patients' characteristics. The median patient age was 36 years (range, 14-78), and the median tumor diameter was 5.0 cm (range, 1.5-10). Figure 2 shows a summary of the tumor location. The tumor location was suprahilar in 10, hilar in 6, and infrahilar in 9. Regarding the surgical approach, a transperitoneal approach was selected in 24 cases and retroperitoneal approach in 1. Table 2 shows a summary of the patients' outcomes. The median operative time and blood loss were 208 minutes (range, 73-513) and 10 mL (range, 0-1,020), respectively. Although intraoperative injury of the vena cava and serosa of the duodenum occurred in the same patient, they could be repaired laparoscopically. No patient required blood transfusion or conversion to open surgery. Macroscopically, all tumors were resected without capsular disruption. Regarding the postoperative complications, depression (n=1, Grade 2), hypoglycemia (n=1, Grade 2), and chylous leakage (n=1, Grade 1) were observed, and all events could be managed conservatively. The median postoperative hospital stay was 8 days (range, 5-13). Pathological examination revealed paraganglioma in 12, ganglioneuroma in 7, and schwannoma in 6. In one patient with a preoperative diagnosis of paraganglioma, the final pathology was schwannoma. In 19 patients, the surgical margin was negative, while heat denaturation was detected in a limited area in 6 patients (ganglioneuroma: n=3, paraganglioma: n=3). At a median

follow-up of 37.5 months (range, 1-155), 23 patients were free of disease. Regarding disease recurrence, one female patient underwent two laparoscopic surgeries when she was 17 and 24 years old. On pathological examination, the surgical margin was negative in both surgeries. Thereafter, she underwent open surgery for the second recurrence when she was 25 years old. Although these diseases comprised a single mass around the vena cava, she further developed multiple metastasis when she was 28 years old (54 months after the second laparoscopic surgery), and we finally diagnosed her with malignant paraganglioma.

Technical tips and tricks

In order to clarify technical tips and tricks, we reviewed the operative notes and surgical videos. Notes were available in all cases, and video records in 14 cases. In the two cases with retrocaval tumors, taping the vena cava and renal vein and lifting them were helpful to obtain a favorable operative view (Figure 3, Video clip 1). In 2 cases with tumors located behind the renal hilum, rotating the kidney was helpful to approach the tumor (Figure 4, Video clip 2). In recent cases, 3D-CT effectively showed the relationship between the tumor and adjacent major vessels, and was helpful for preoperative planning (Figure 5, Video clip 3). In our experience, desmoplastic change around the tumor was frequently encountered and meticulous detachment from the adjacent structures was required (Video clip 3, and Figure 6, Video clip 4).

Discussion

In the present study, no patients required open conversion or blood transfusion, and postoperative complications could be conservatively managed. Regarding the median postoperative hospital stay of 8 days, it reflects universal health coverage in Japan, where patients (except for elderly people and children) need to pay just 30% of the total cost, allowing longer hospital stays, and patients prefer discharge after the removal of staples (about 1 week after surgery). Finally, all but one patient were disease-free at the last follow-up. Although we consider that our experience further supported the feasibility of laparoscopic resection for paraaortic or paracaval neurogenic tumors with low comorbidity, we identified several issues that remained unresolved in the treatment of this disease entity.

Regarding the surgical approach, Walz et al. previously reported their experiences of laparoscopic or retroperitoneoscopic surgery for 27 paragangliomas, advocating a retroperitoneal approach for tumors caudal to the renal hilum and a transabdominal approach for those superior to the renal hilum [9]. In the treatment of adrenal tumors, several researchers also reported that a retroperitoneal approach was associated with a shorter operative time, lower blood loss, lower postoperative pain, and faster recovery [10, 11]. In contrast, as described above, we prefer a transperitoneal approach because of the wider space and greater number of landmarks compared to a retroperitoneal approach. Several surgical tips, including taping great vessels in the case of a tumor

located behind the vena cava (Video clip 1), and mobilization of organs such as the liver or kidney (Video clip 2) could offer a favorable view around the tumor. As shown in Figure 5, 3D-CT effectively showed the relationship between the tumor and great vessels, and it was helpful for preoperative surgical planning. At present, we select a retroperitoneal approach in cases with a previous history of upper abdominal surgery.

In the present series, all tumors were removed without disruption macroscopically, and 23 patients were free of disease at a median follow-up of 37.5 months (range, 1-155). However, heat denaturation was detected in a limited area in 6 patients (ganglioneuroma: n=3, paraganglioma: n=3). As described above, desmoplastic tissue was frequently encountered in the presence of this disease entity. For example, as shown in Video clip 4, there was marked adhesion between the tumor and duodenum /inferior mesenteric artery, and meticulous detachment using bipolar forceps was required, which might have resulted in heat denaturation. A sealing device like Ligasure® was also used, and the use of these recent laparoscopic sealing devices might also cause cautery artifacts. Although we believe that cautery artifacts in the present cases do not mean incomplete resection, there is still room for improving our technique to achieve a completely negative margin. Some might argue that complete resection including adjacent organs should have been performed to achieve a negative surgical margin because, especially in paraganglioma, the incidence of malignancy is 20-30% [12]. It remains unknown whether a cautery artifact on the tumor surface influences

the long-term outcome, although the present 6 patients were free of recurrence at a median of 33.5 months (range, 12-59) follow-up. At present, we believe that an excellent magnified view and fine dissection under laparoscopy will facilitate both complete resection and improved postoperative convalescence. As described above, although we have to improve our surgical technique, we prefer laparoscopic tumor resection given that apparent tumor invasion to adjacent vital organs and/or major vessels was not detected by either preoperative imaging or intraoperative observation. If apparent invasion is encountered intraoperatively, we consider open conversion to allow more radical en bloc resections. Preoperative assessment of a patient's general condition and preparation are also important, especially in paraganglioma cases.

In the present cohort, as described above, one female patient underwent two laparoscopic surgeries when she was 17 and 24 years old. On pathological examination, the surgical margin was negative in both surgeries. Thereafter, she underwent open surgery for the second recurrence when she was 25 years old. Although these diseases comprised a single mass around the vena cava, she further developed multiple metastasis when she was 28 years old (54 months after the second laparoscopic surgery), and we finally diagnosed her with malignant paraganglioma. The focus points of most previous studies were the postoperative recovery and short-term outcome after laparoscopic resection of paraganglioma [2-7]. Although the long-term outcome after laparoscopic remains unknown due to the rarity of this disease,

we consider that laparoscopic surgery did not adversely affect her disease outcome.

Our study had several potential limitations. Firstly, this was a small retrospective study. Secondly, as described above, further follow-up is still needed to establish that laparoscopic resection does not have a deleterious effect on the long-term outcome, especially in paraganglioma cases. Thirdly, our study could not answer the question of whether laparoscopic surgery is feasible for malignant retroperitoneal tumors. However, we consider that our study further supports the feasibility of laparoscopic resection of paraaortic or paracaval neurogenic tumors in experienced hands, and we offer several surgical tips and tricks.

Conclusions

Laparoscopic resection of paraaortic or paracaval neurogenic tumors is feasible. Surgeons should be familiar with dissection around great vessels and the mobilization of adjacent organs. Careful preoperative planning is mandatory.

Disclosures

Takashige Abe, Ataru Sazawa, Toru Harabayashi, Yuichiro Oishi, Naoto Miyajima, Kunihiko Tsuchiya, Satoru Maruyama, Hiromi Okada, and Nobuo Shinohara have no conflict of interest regarding financial ties to disclose.

References

1. Chung L, O'Dwyer PJ (2013) Laparoscopic resection of paraaortic or paracaval lesions: feasibility and outcome. Surg Endosc 27:4153-4156

2. Goers TA, Abdo M, Moley JF, Matthews BD, Quasebarth M, Brunt LM (2013) Outcomes of resection of extra-adrenal pheochromocytomas/paragangliomas in the laparoscopic era: a comparison with adrenal pheochromocytoma. Surg Endosc 27:428-433

3. Misra MC, Bhattacharjee HK, Hemal AK, Bansal VK (2010) Laparoscopic management of rare retroperitoneal tumors. Surg Laparosc Endosc Percutan Tech 20:e117-122

4. Mitchell J, Siperstein A, Milas M, Berber E (2011) Laparoscopic resection of abdominal paragangliomas. Surg Laparosc Endosc Percutan Tech, pp e48-53

5. Hwang J, Shoaf G, Uchio EM, Watson J, Pacak K, Linehan WM, Walther MM (2004) Laparoscopic management of extra-adrenal pheochromocytoma. J Urol 171:72-76

6. Wang J, Li Y, Xiao N, Duan J, Yang N, Bao J, Li Y, Mi J (2014) Retroperitoneoscopic resection of primary paraganglioma: single-center clinical experience and literature review. J Endourol 28:1345-1351

7. Nozaki T, Iida H, Morii A, Fujiuchi Y, Okumura A, Fuse H (2013) Laparoscopic resection of adrenal and extra-adrenal pheochromocytoma. J Endourol 27:862-868

8. Clavien PA, Sanabria JR, Strasberg SM (1992) Proposed classification of complications of surgery with examples of utility in cholecystectomy. Surgery 111:518-526

9. Walz MK, Alesina PF, Wenger FA, Koch JA, Neumann HP, Petersenn S, Schmid KW, Mann K (2006) Laparoscopic and retroperitoneoscopic treatment of pheochromocytomas and retroperitoneal paragangliomas: results of 161 tumors in 126 patients. World J Surg 30:899-908

10. Barczynski M, Konturek A, Nowak W (2014) Randomized clinical trial of posterior retroperitoneoscopic adrenalectomy versus lateral transperitoneal laparoscopic adrenalectomy with a 5-year follow-up. Ann Surg 260:740-747; discussion 747-748

11. Constantinides VA, Christakis I, Touska P, Meeran K, Palazzo F (2013) Retroperitoneoscopic or laparoscopic adrenalectomy? A single-centre UK experience. Surg Endosc 27:4147-4152

12. O'Riordain DS, Young WF, Jr., Grant CS, Carney JA, van Heerden JA (1996) Clinical spectrum and outcome of functional extraadrenal paraganglioma. World J Surg 20:916-921; discussion 922

Table 1. Patients' characteristics.

	n=25
Age, years	Median 36 (range, 14-78)
Sex (n=24)	
Male	12
Female	12
Tumor size, cm	Median 5.0 (1.5-10)
Tumor location	
Suprahilar	10
Hilar	6
Infrahilar	9
Surgical approach	
Transperitoneal	22
Retroperitoneal	1
Transperitoneal plus retroperitoneal balloon dilation	2

Table 2. Patients' outcomes

	n=25
Operative time, minutes	Median 208 (range, 73-513)
Blood loss, mL	Median 10 (range, 0-1020)
Intraoperative complication	
Injury of vena cava	1
Injury of duodenum	1
Postoperative complication	
Depression	1 (Grade 2)
Hypoglycemia	1 (Grade 2)
Chylous leakage	1 (Grade 1)
Postoperative hospital stay, days	Median 8 (range, 5-13)
Pathology	
Paraganglioma	12
Ganglioneuroma	7
Schwannnoma	6
Margin	
Negative	19
Positive	6

Figure Legends.

Figure 1. Schemes of port positions. In cases with suprahilar/hilar tumors, subcostal placement was selected (Figure 1a), and in those with subhilar tumors, ports were placed in a diamond shape, as shown in Figure 1b.

Figure 2. Summary of tumor location. The tumor location was suprahilar in 10, hilar in 6, and infrahilar in 9.

Figure 3. During evaluation for hypertension, a 61-year-old male was found to have a 5-cm retrocaval paraganglioma (a: CT, blue arrow). The vena cava and renal vein were secured by tapes (b: intraoperative view). VC=Vena cava. LRV=Left renal vein.

Figure 4. A 36-year-old female was incidentally found to have a 4.8-cm tumor located in the right renal hilar area (a: CT, blue arrow). Laboratory investigation findings were normal, and the preoperative diagnosis was a benign neurogenic tumor. In this location, rotating the kidney was helpful to approach the tumor (See Video clip 2). RRV=Right renal vein.

Figure 5. During evaluation for hypertension, a 20-year-old female was found to have a 3.9-cm paraganglioma located in the left renal hilar area. 3D-CT clerarly revealed a feeding artery which originated from the left renal artery (a: 3DCT, blue arrow, b: intraoperative view, blue arrow). Desmoplastic change around the tumor was noted and meticulous detachment was required (See Video clip 3).

Figure 6. During evaluation for hypertension, a 14-year-old male was found to have a 8.5-cm paraganglioma located in the interaortocaval area. In this case, desmoplastic change around the tumor was noted and meticulous detachment was required to detach the duodenum from the tumor (a: CT, blue arrow).

Figure 1.

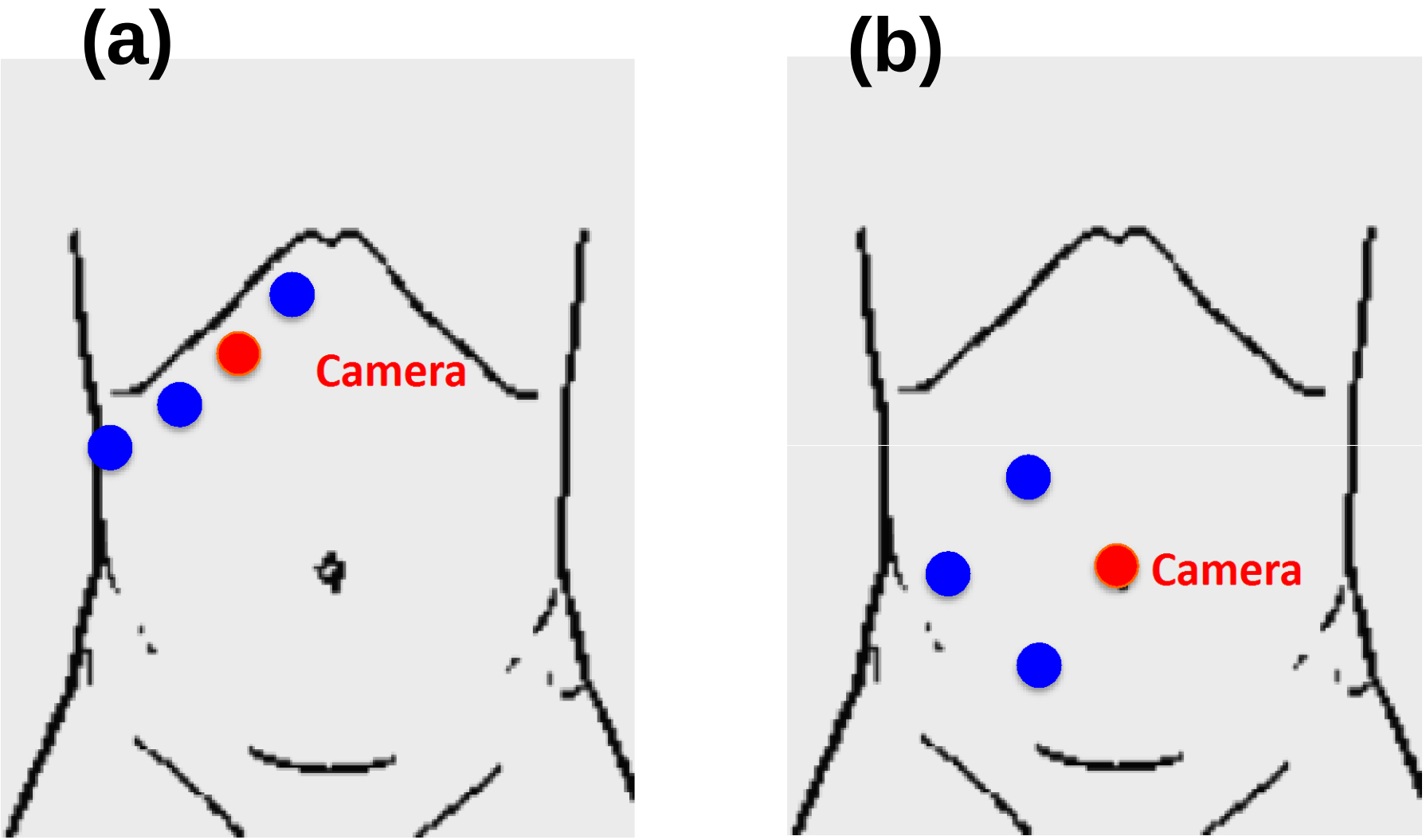

Figure 2. Summary of tumor location

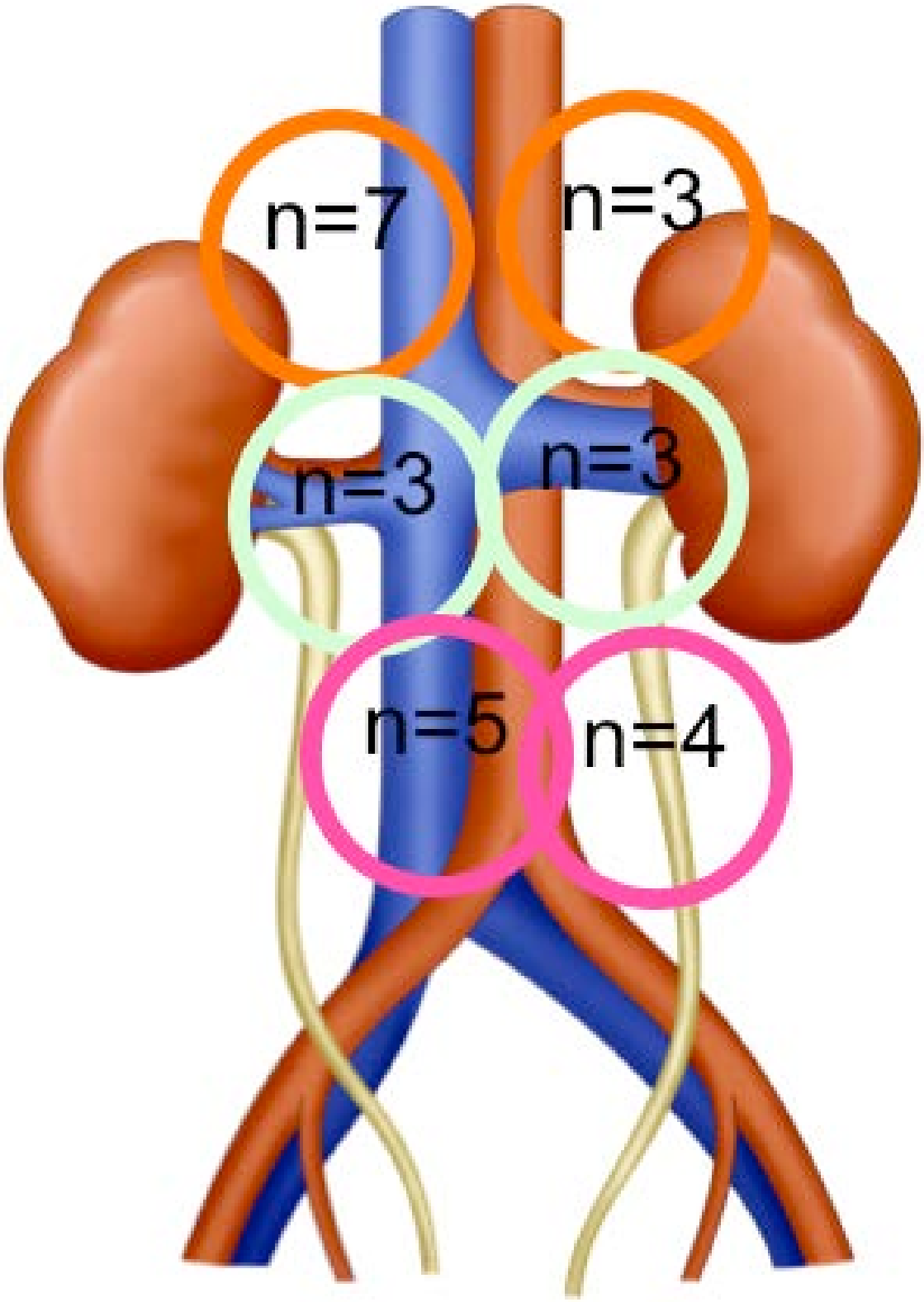

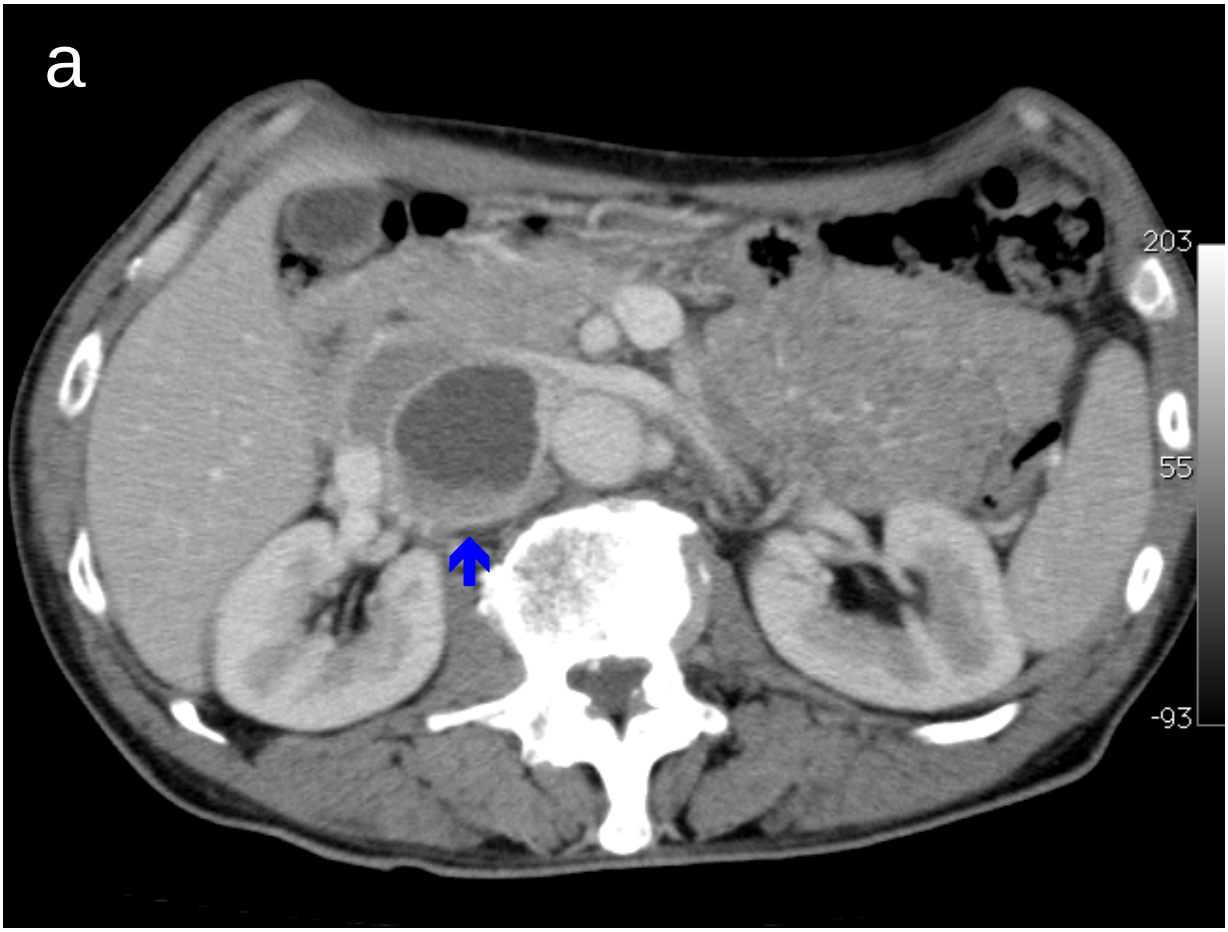
a
203
55
-93

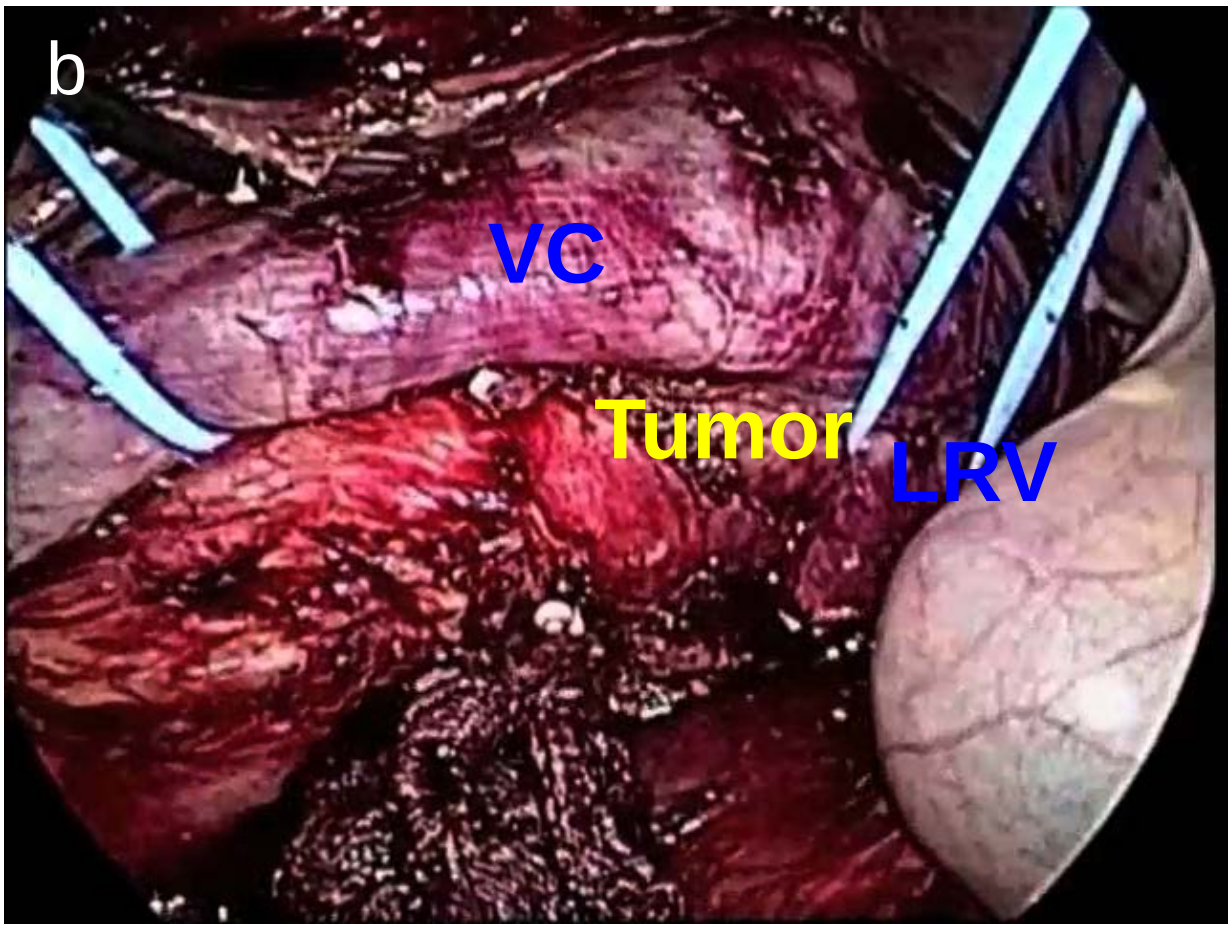
b
VC
Tumor
LRV


a
215
40
-135

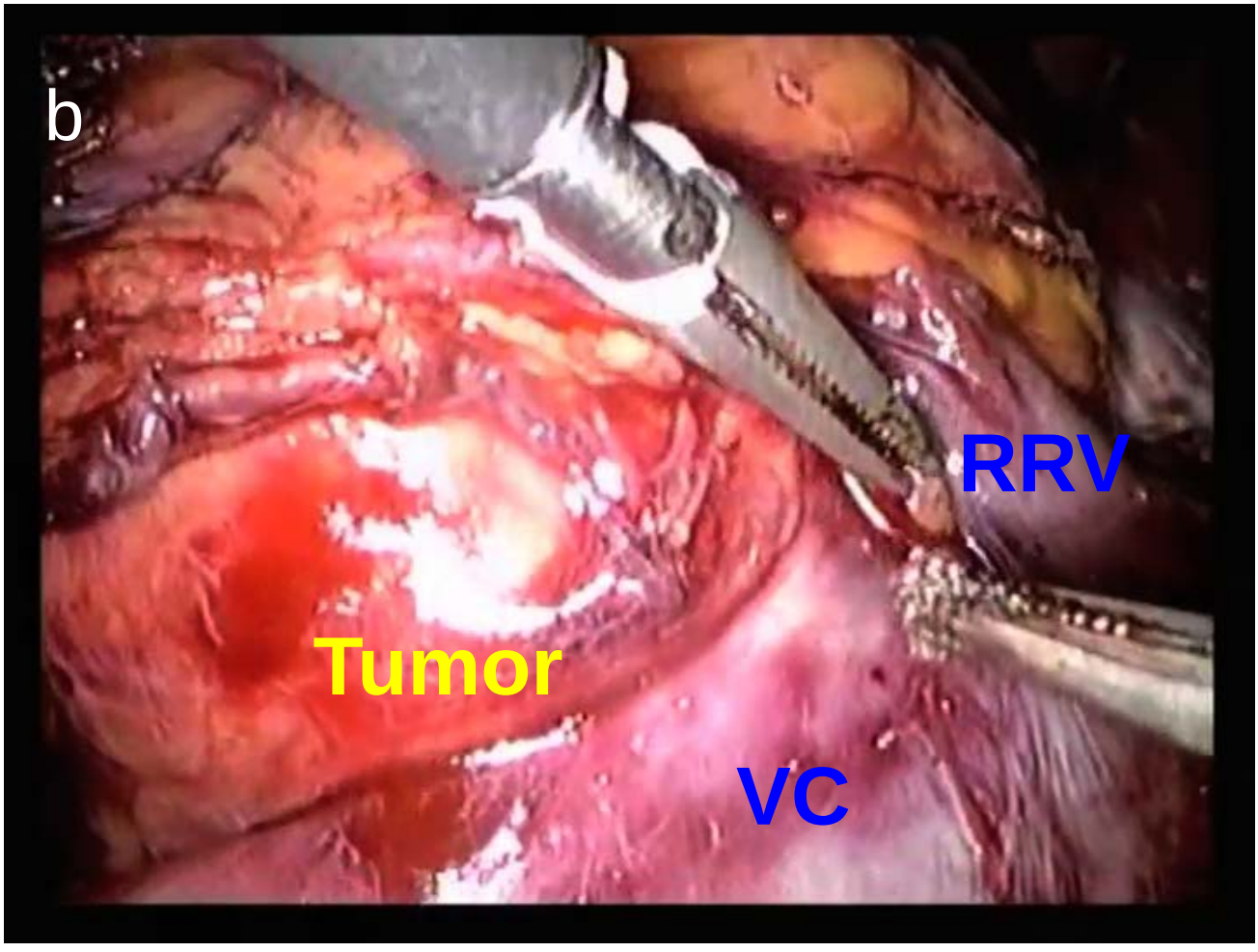
b
RRV
Tumor
VC

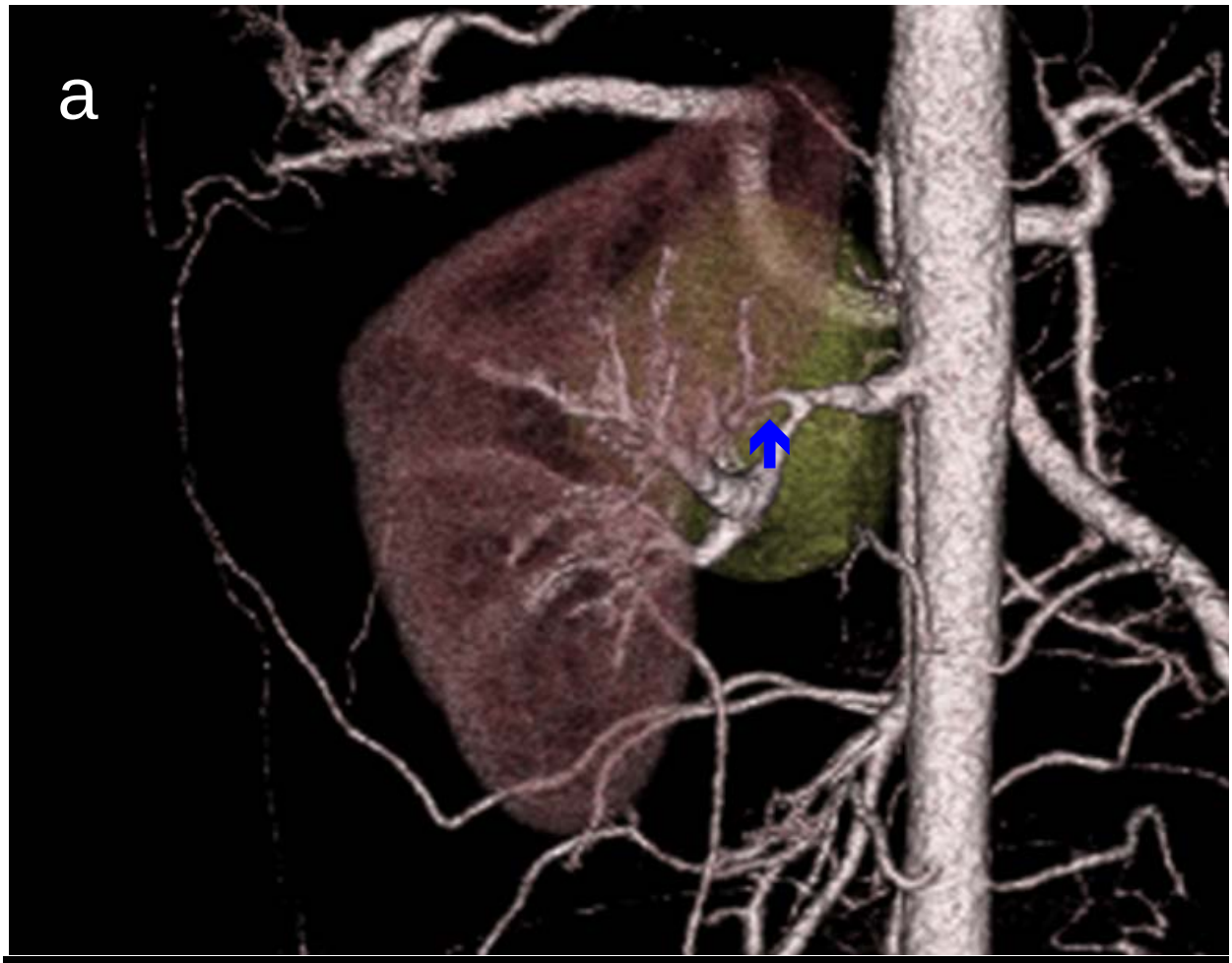
a

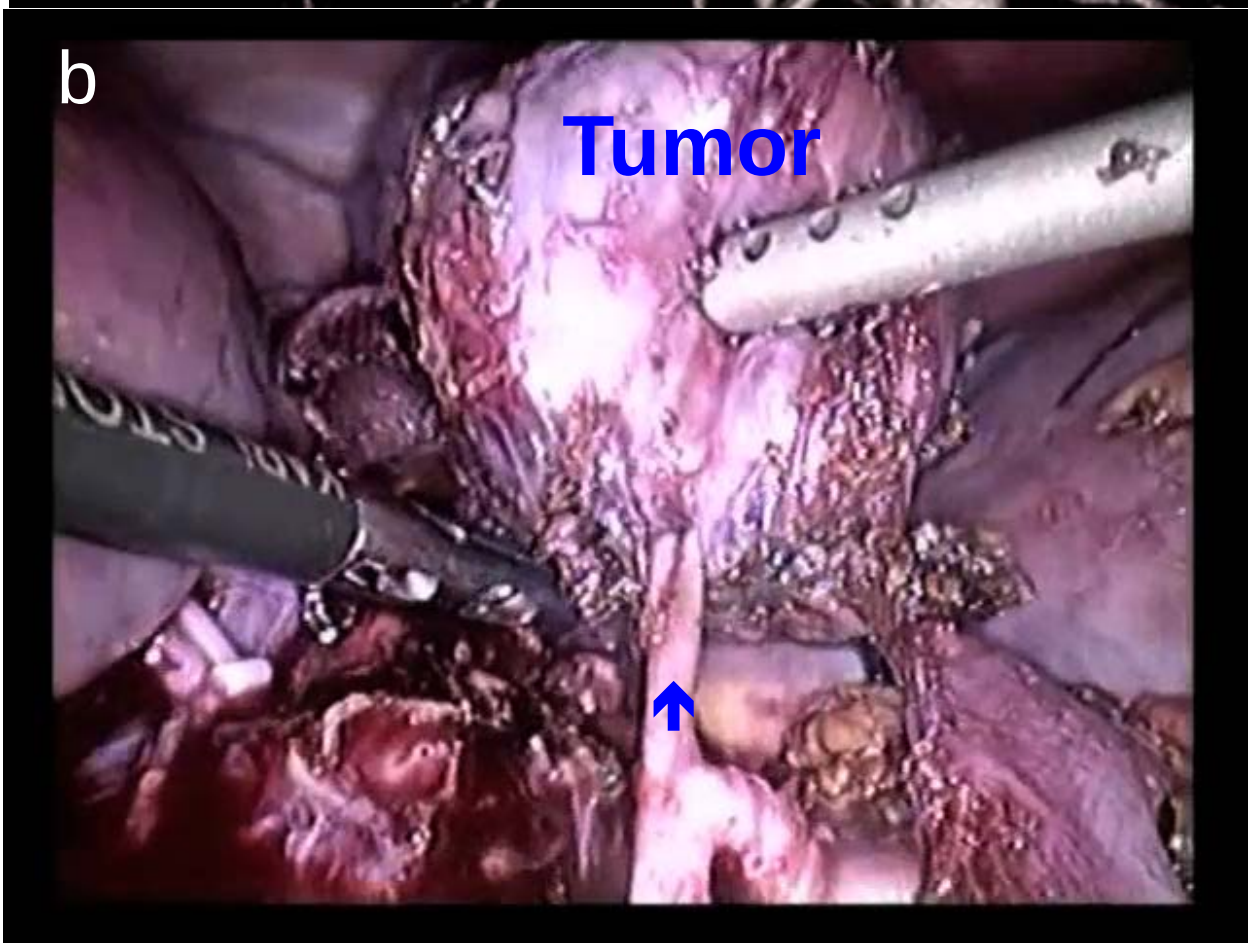
b
Tumor

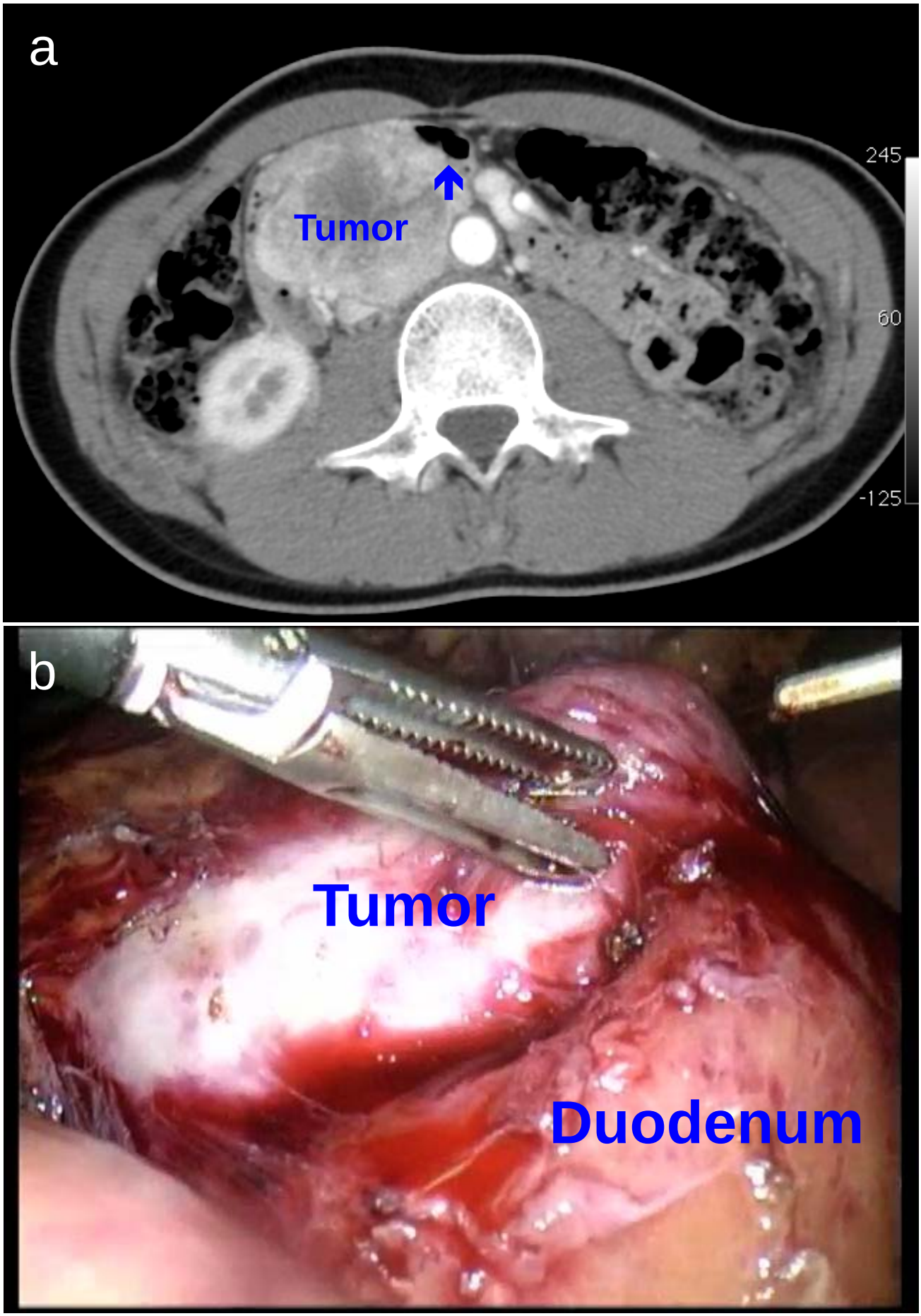
a
Tumor
245
60
-125
b
Tumor
Duodenum